

Introduction to Orthopedic Oncology

James C. Wittig, MD
Assistant Professor of Orthopedic Surgery
NYU-Hospital for Joint Diseases
Hackensack University Medical Center

Classification of Musculoskeletal Tumors

- Musculoskeletal Tumors are rare types of tumors when compared to all types of tumors that occur throughout the body
- Most musculoskeletal tumors originate from mesenchymal type tissue or from cells that are derived from mesoderm
- An embryo or fetus is composed of three layers of cells: Ectoderm (outer layer); Mesoderm (middle layer); Endoderm (inner layer)
- The mesoderm is the layer that normally forms all of the connective tissues in the body, including bone, muscle, cartilage, fibrous tissue, tendons, ligaments blood vessels, nerves, blood cells

Classification of Musculoskeletal Tumors

- When uncontrolled division or growth of a mesodermal or mesenchymal cell occurs it results in the production of a tumor
- These mesodermal tumors can form tissue that resemble normal mesodermal tissues like bone (osteoid), cartilage or fibrous tissue
- Hence, these tumors are often named according to the normal type of mesodermal tissue that they resemble or the type of tissue they are producing
- There are both benign and malignant (cancerous) types of tumors. Cancerous types of mesenchymal or mesodermal tumors are termed **Sarcomas**

Classification of Musculoskeletal Tumors

- For example, bone producing (osteoid producing) tumors fall into the category of Osseous Tumors. A type of benign osseous tumor is called an Osteoblastoma. The malignant or cancerous type of Osseous Tumor is called an **Osteosarcoma**
- Similarly, a type of benign cartilage producing tumor is called an Enchondroma. A malignant cartilage producing tumor is called a **Chondrosarcoma**.
- Mesenchymal or Mesodermal tumors can arise from muscle or the soft tissues of an extremity or from bone. For example, an Osteosarcoma which is a malignant bone producing tumor can originate from either a bone or from muscle or from the soft tissues in between the muscles. It more commonly arises from a bone but can also arise from a muscle. Although it produces bone itself, it does not have to develop from bone and can also develop from soft tissues.

Classification of Musculoskeletal Tumors

- Similarly, a Fibrosarcoma is a malignant fibrous tissue producing tumor. Fibrous tissue is typically thought of as a soft tissue of the body. Fibrosarcoma most commonly arises from the soft tissue of the body but can also originate from a bone.
- Tumors that arise from the endodermal or ectodermal cells of the body usually do not originate from the bones or soft tissues of the body. They usually involve the musculoskeletal system by spreading or metastasizing to a bone or muscle. These types of malignant or cancerous tumors are termed **Carcinomas**. Carcinomas constitute more common tumors like breast, prostate, kidney, lung,, thyroid, gastrointestinal cancers.

Classification of Musculoskeletal Tumors

- The next three slides demonstrate a general classification scheme for mesenchymal tumors and sarcomas that originate from the musculoskeletal system, bones and soft tissues.
- It is important to memorize these classification systems.

Bone Tumors

<u>Category</u>	<u>Benign</u>	<u>Malignant</u>
Osseous	Osteoma Osteoid Osteoma Osteoblastoma	Osteosarcoma Intra medullary Conventional Telangiectatic Low Grade Intraosseous Juxtacortical/ Surface Parosteal Periosteal High Grade Surface Intracortical Secondary osteosarcoma Paget's Osteosarcoma Radiation Induced Bone Infarct Osteogenesis Imperfecta
Cartilaginous	Enchondroma Osteochondroma Chondroblastoma Chondromyxofibroma	Chondrosarcoma Conventional/Intra medullary Clear cell Mesenchymal Dedifferentiated Juxtacortical/Periosteal Secondary Osteochondroma Multiple Enchondromas Ollier's disease Maffucci's Syndrome
Fibrous	Fibrous dysplasia Fibrocartilaginous Dysplasia Osteofibrous Dysplasia Non Ossifying Fibroma Benign Fibrous Histiocytoma Fibroxanthoma Desmoplastic Fibroma (Desmoid/Fibromatosis)	Fibrosarcoma Malignant Fibrous Histiocytoma
Small Round Blue Cell	Eosinophilic Granuloma Infection	Ewing's Sarcoma/PNET Lymphoma Multiple Myeloma
Giant Cell	Giant Cell Tumor	

<u>Category</u>	<u>Benign</u>	<u>Malignant</u>
Vascular	Hemangioma Lymphangioma Glomus Tumor	Hemangioendothelioma Angiosarcoma Hemangiopericytoma Kaposi's sarcoma
Neurogenic	Schwannoma	
Cystic	Aneurysmal Bone Cyst Primary ABC Secondary ABC Unicameral Bone Cyst Intraosseous Ganglion	
Myogenic		Leiomyosarcoma Rhabdomyosarcoma
Miscellaneous	Lipoma Parosteal Lipoma	Liposarcoma Adamantinoma Chordoma Chondroid Chordoma
Metastatic Lesions		Lung Breast Kidney Thyroid Prostate Gastrointestinal
Synovial	Chondromatosis Pigmented Villonodular synovitis Synovial lipoma Hemangioma Chondrosarcoma	

Soft Tissue Tumors

<u>Category</u>	<u>Benign</u>	<u>Malignant</u>
Fibrous/Myofibroblastic	Fibromatosis/Desmoid Elastofibroma Solitary Fibrous Tumor	Fibrosarcoma
Fibrohistiocytic	Benign Fibrous Histiocytoma Dermatofibrosarcoma Protuberans	MFH Pleomorphic Myxoid Inflammatory
Lipomatous	Lipoma Hibernoma	Liposarcoma Well Differentiated Myxoid Round Cell Pleomorphic
Smooth Muscle	Leiomyoma	Leiomyosarcoma
Skeletal Muscle	Rhabdomyoma	Rhabdomyosarcoma Embryonal Alveolar Pleomorphic
Vascular	Hemangioma Glomus	Hemangioendothelioma Hemangiopericytoma Angiosarcoma
Synovial	PVNS GCT Tendon Sheath	Malignant PVNS
Neural	Schwannoma	Malignant Peripheral Nerve Sheath Tumor MPNST
Extraskeletal Osseous/ Cartilaginous	Myositis Ossificans Chondroma	Osteosarcoma Chondrosarcoma Myxoid Mesenchymal
Miscellaneous	Myxoma	Clear Cell Sarcoma Synovial Sarcoma Alveolar soft Part Sarcoma Epithelioid Sarcoma Ewing's Sarcoma/PNET Desmoplastic Small Cell Tumor

Normal Tissues vs Tumors

- In order to be able to diagnose abnormal tissue or a tumor/cancer, it is important to understand the microscopic characteristics of the normal tissues of the body.
- The normal tissues of the body consist of epithelial tissue, connective tissue, muscle and nervous tissue. They each have a characteristic microscopic appearance.
- In general, normal tissues have an orderly arrangement of cells. The cells are similar size and shape. The tissue is hypocellular. The nucleus is small. There are no mitotic figures. There are no necrotic or dead areas in the tissue.
- Tumors usually demonstrate a haphazard or disorderly arrangement of cells. The cells are usually different sizes and shapes (cellular pleomorphism). The nuclei are usually large and there is usually less cytoplasm than in a normal cell. There may be mitotic figures in malignant/cancerous tumors. There may also be necrotic or dead areas associated with cancerous tumors. Malignant tumors have more bizarre features than benign tumors, more haphazard arrangement, more pleomorphism.

Benign/Normal Tissue

- Hypocellular (Low Cellularity/High Matrix)
- Cells Arranged in an Orderly Manner
- No Mitoses
- Low Nuclear to Cytoplasmic Ratio (Small Nuclei)
- Uniform Nuclei
- Minimal to No Cellular Pleomorphism

Malignant Tumors

- Hypercellular (Low Matrix)
- Cellular Pleomorphism
- Mitoses
- High Nuclear/Cytoplasmic Ratio (Large Nuclei/Minimal Cytoplasm)
- Dark Nuclei
- Haphazard Arrangement of Cells
- Crowding of Cells
- Necrosis

Normal Tissues

■ 4 Tissue Types in the Body

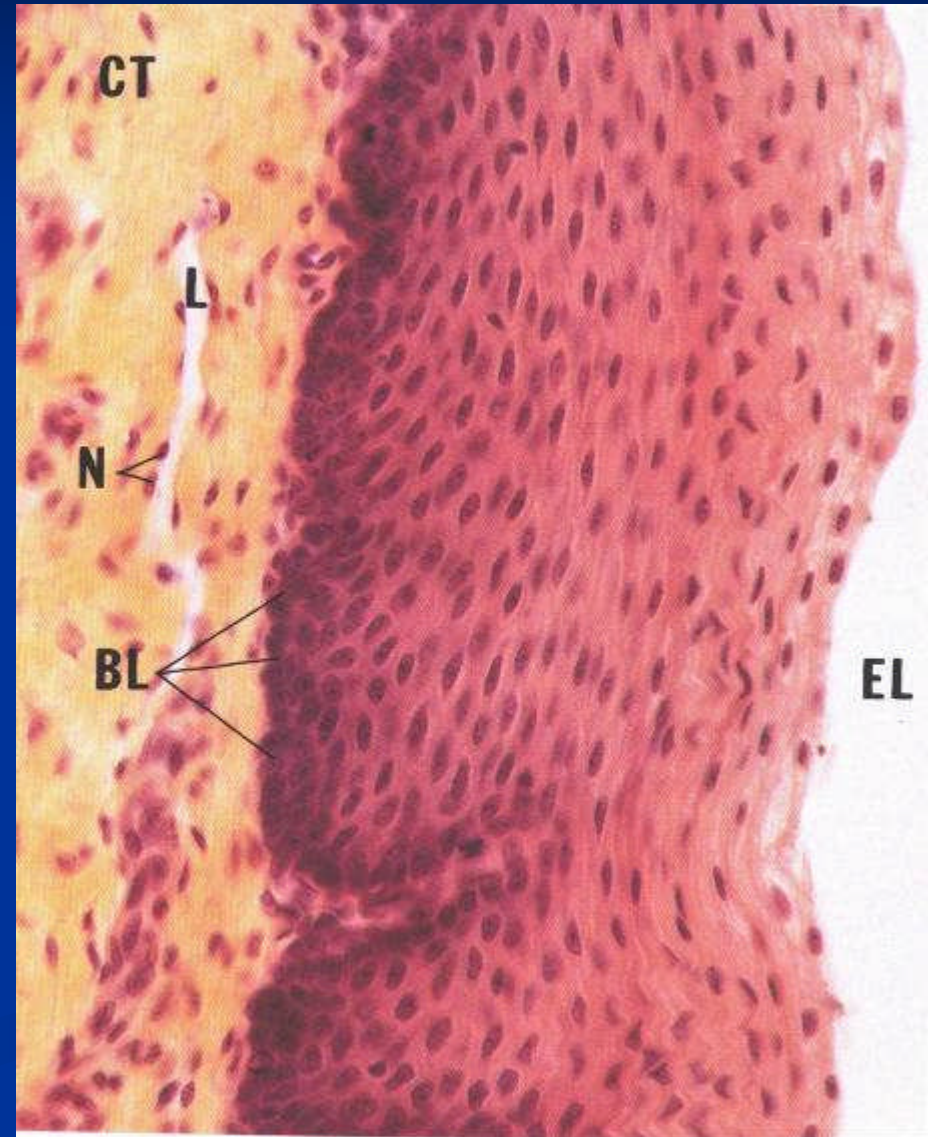
- Epithelial Tissue
- Connective Tissue
 - Bone
 - Cartilage
 - Fibrous Connective Tissue
 - Tendons, Ligaments
 - Fat
 - Fascia covering muscle, nerves and blood vessels
 - Blood Cells
- Muscle
- Nervous Tissue

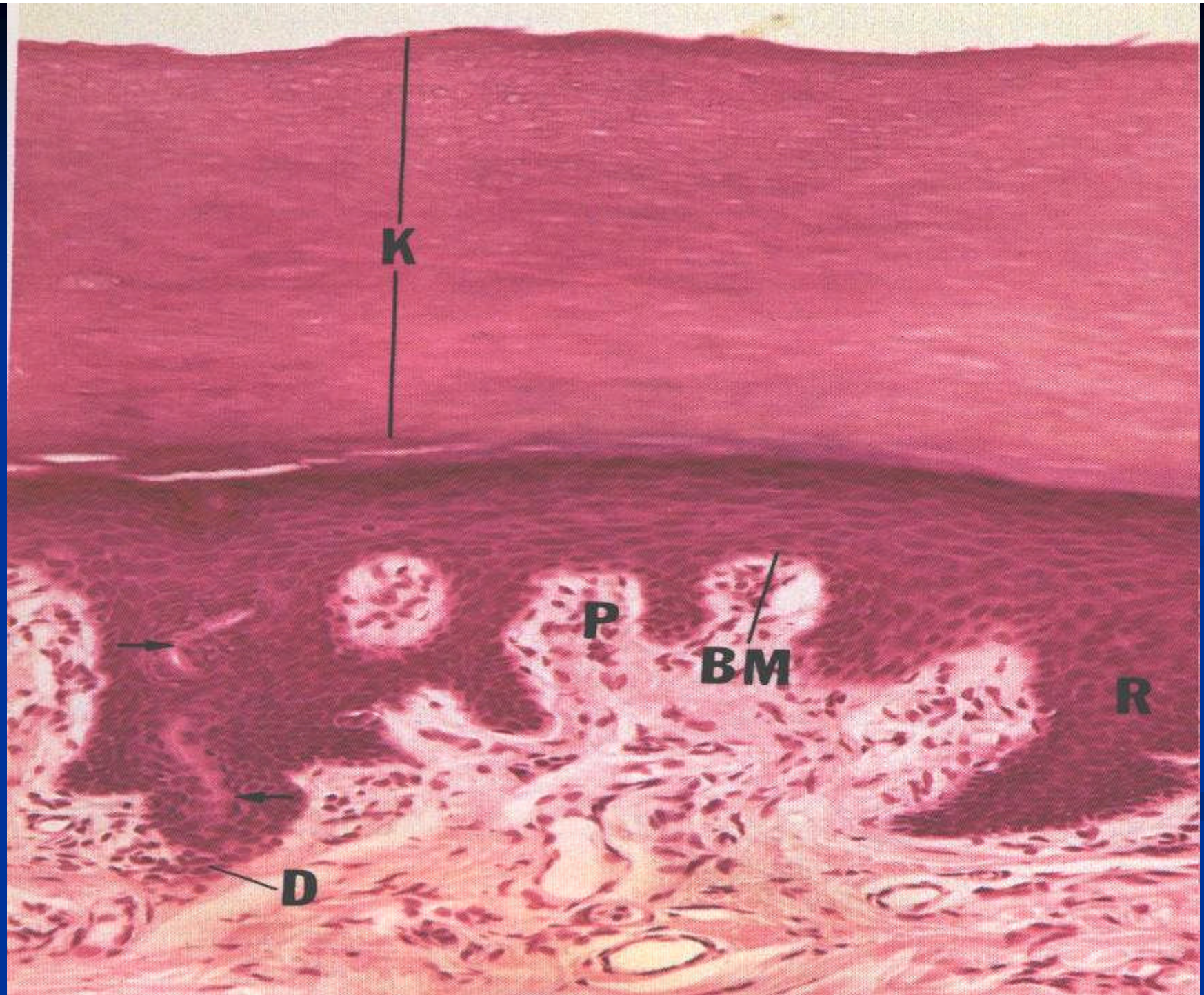
Epithelial Tissue

- Closely packed cells with little or no intercellular material in extracellular space
- Form membranes or occur as secretory elements known as glands; Also forms the skin.
- Classification of types of epithelial tissue:
 - Squamous, Cuboidal, Columnar
 - Simple (single layer)
 - Stratified (2 or more layers)

Skin

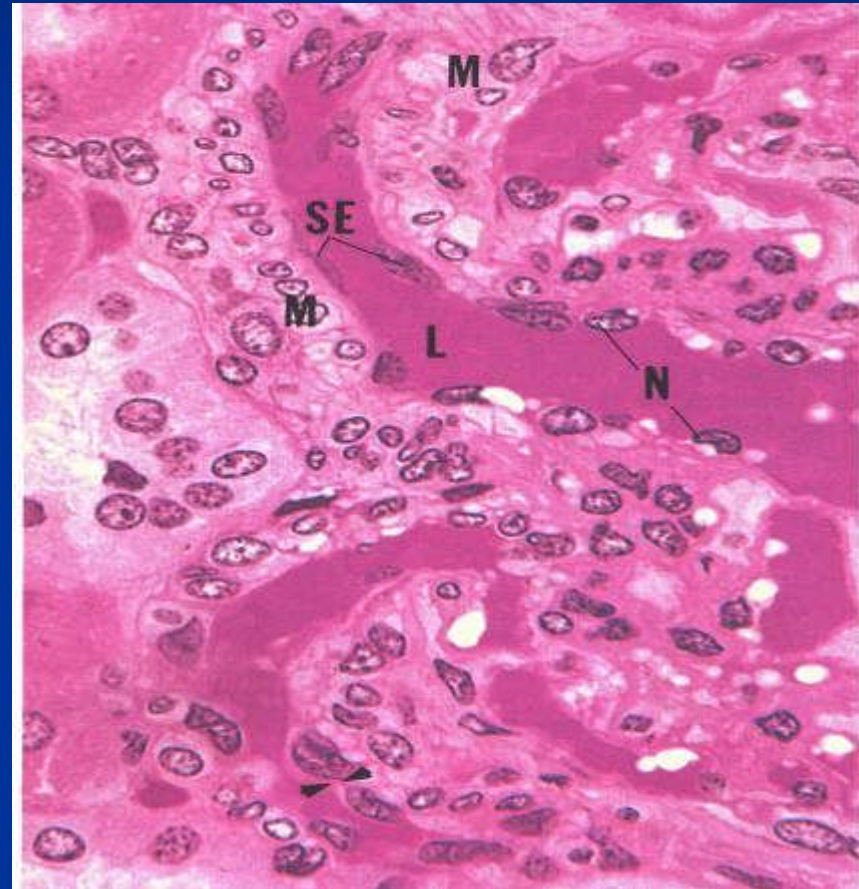
- Stratified Squamous Epithelium
- Normal
- Very Orderly Arranged
- Cells neatly stacked on top of each other
- Minimal cellular pleomorphism
- Uniform nuclei
- Abundant cytoplasm





Normal Kidney

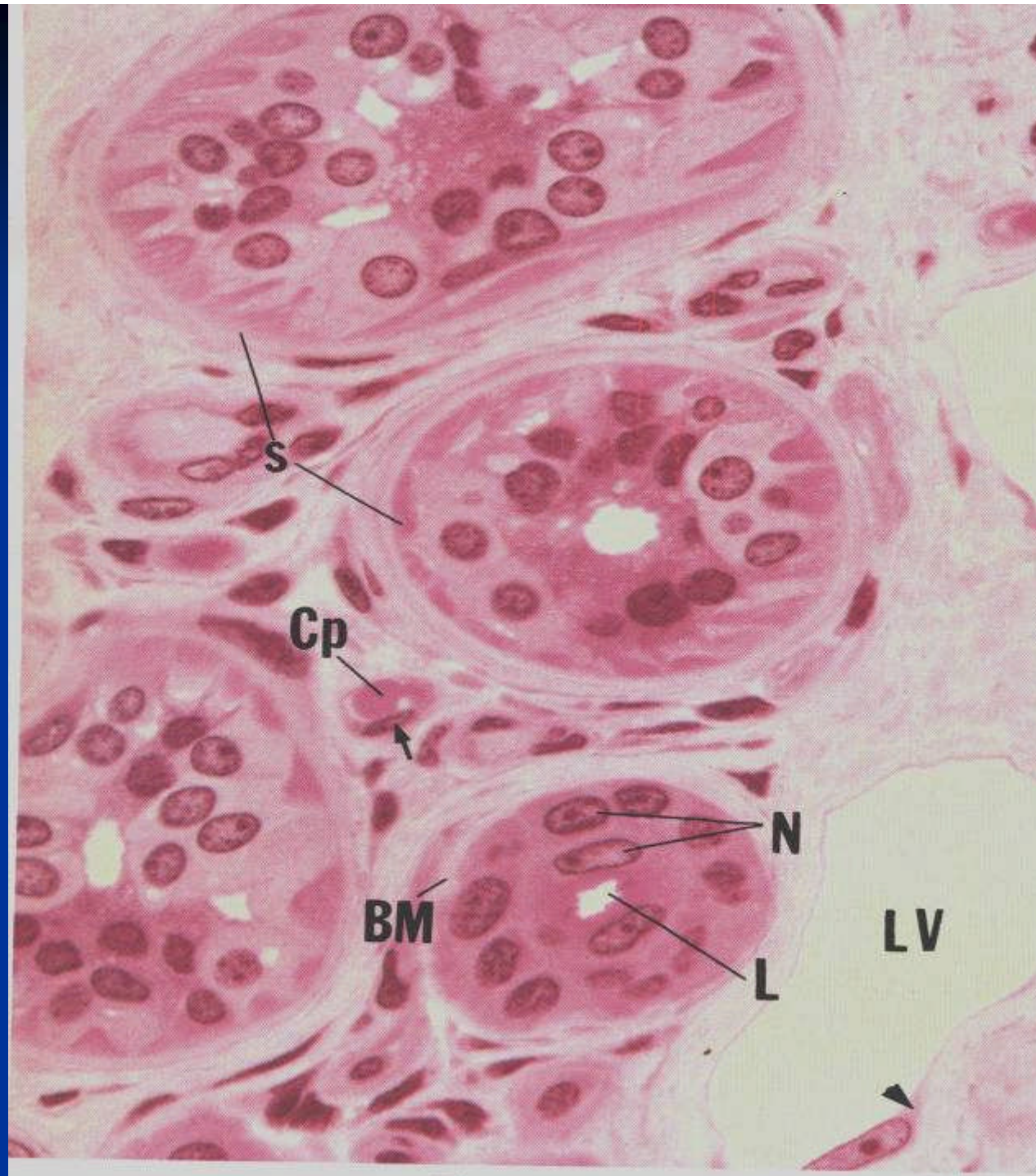
- The kidney is composed of simple cuboidal epithelium that forms tubules
- The cells are arranged orderly and are not packed on top of each other. The cells look similar and have abundant cytoplasm. “L” is the lumen of the tubule where the fluid/urine passes. “N” is a nucleus

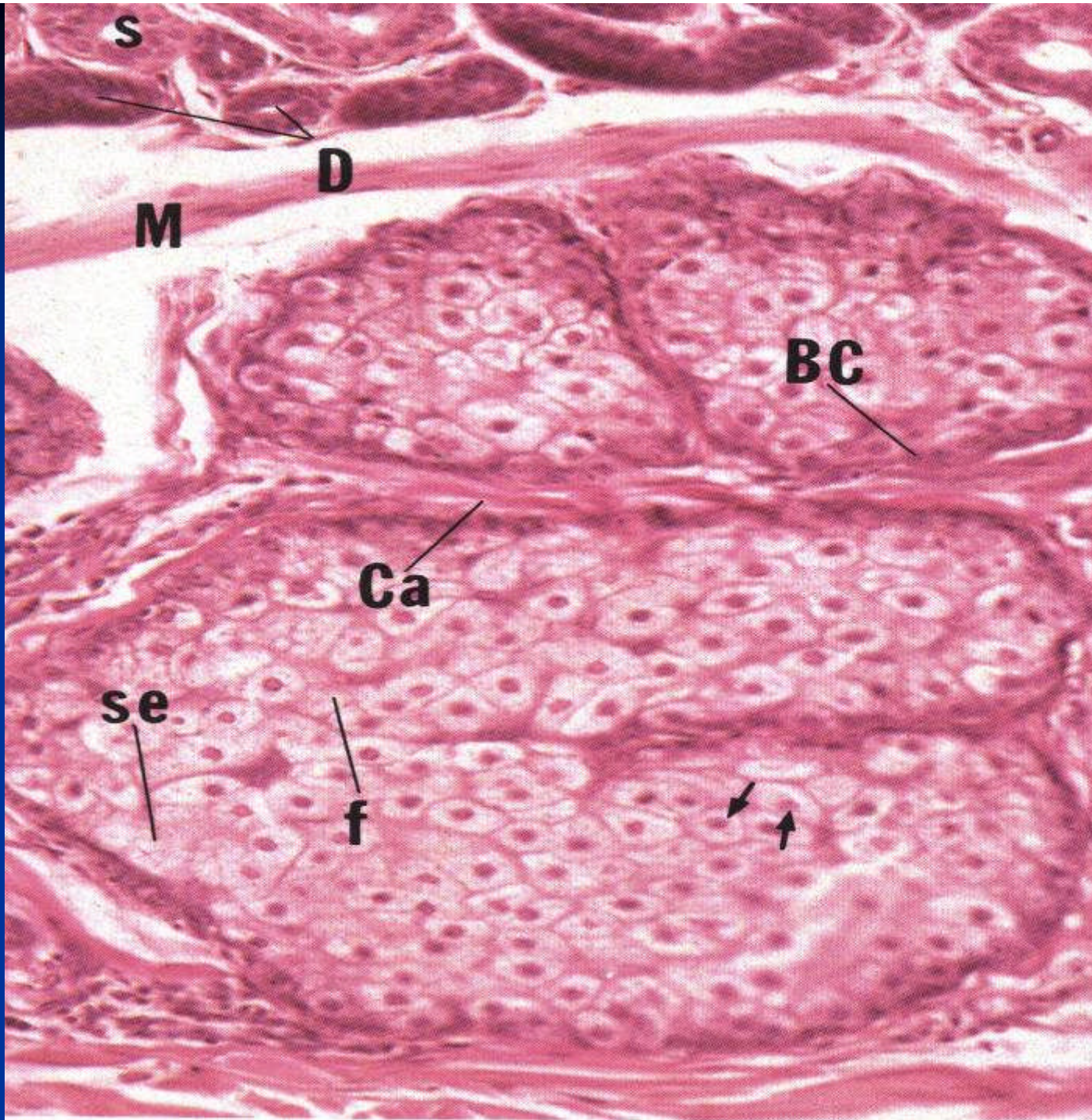


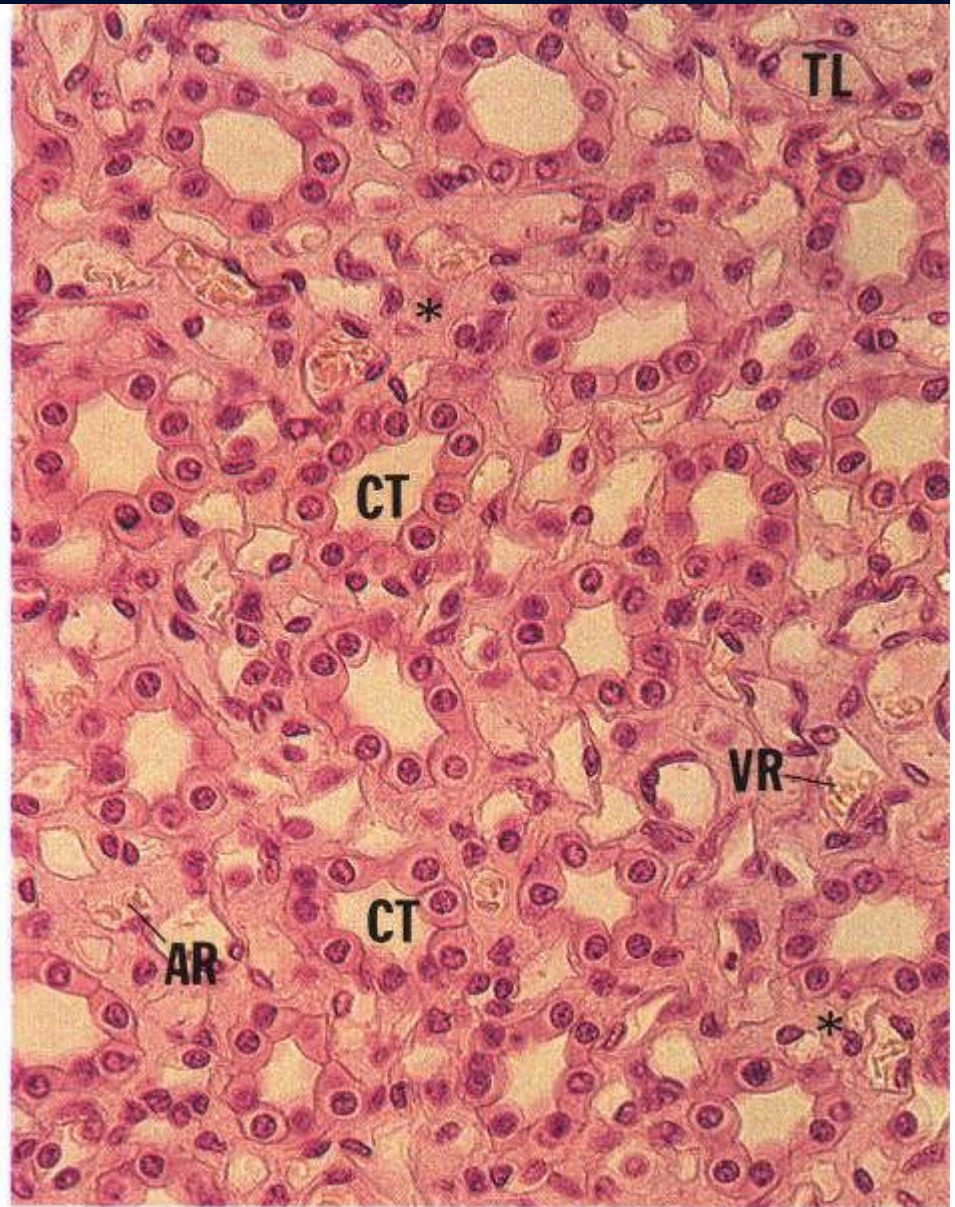
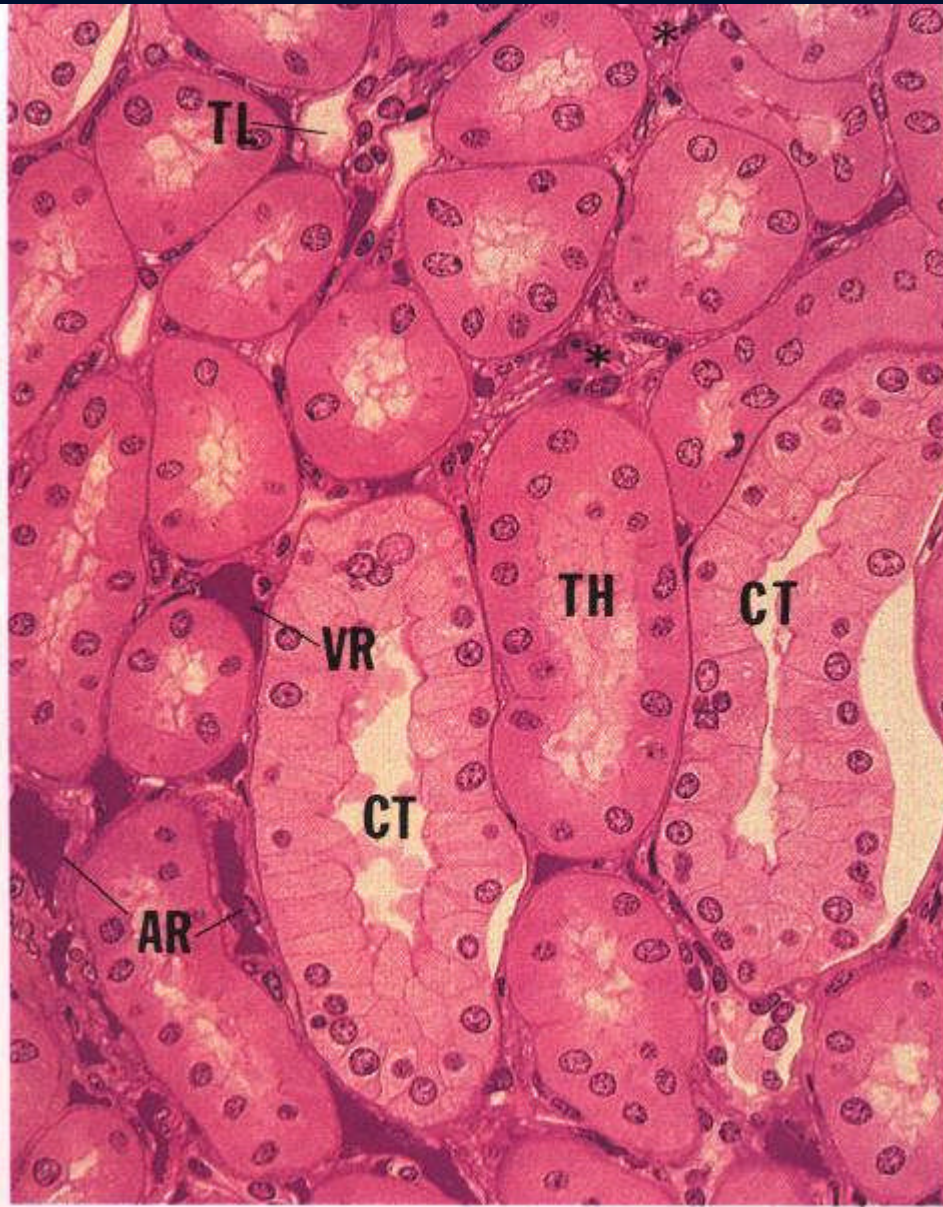
Epithelial Tissue

■ Glands

- Most glands are formed by epithelial down growths into connective tissue
- The next three slides are examples of normal glands formed by epithelial cells.
- The cells typically form round tubular like structures with a lumen. The cells of a gland all function together to secrete substances or fluid into the lumen of the gland. In a normal gland the cells are orderly arranged, There may be more than one layer of cells. The nucleus is distinct and the cells are similar in size and shape. Examples of glands include breast, thyroid, prostate, salivary, parathyroid, sweat glands. Uncontrolled growth of these cells can lead to cancers of the breast, prostate, thyroid, etc. These are types of carcinomas.

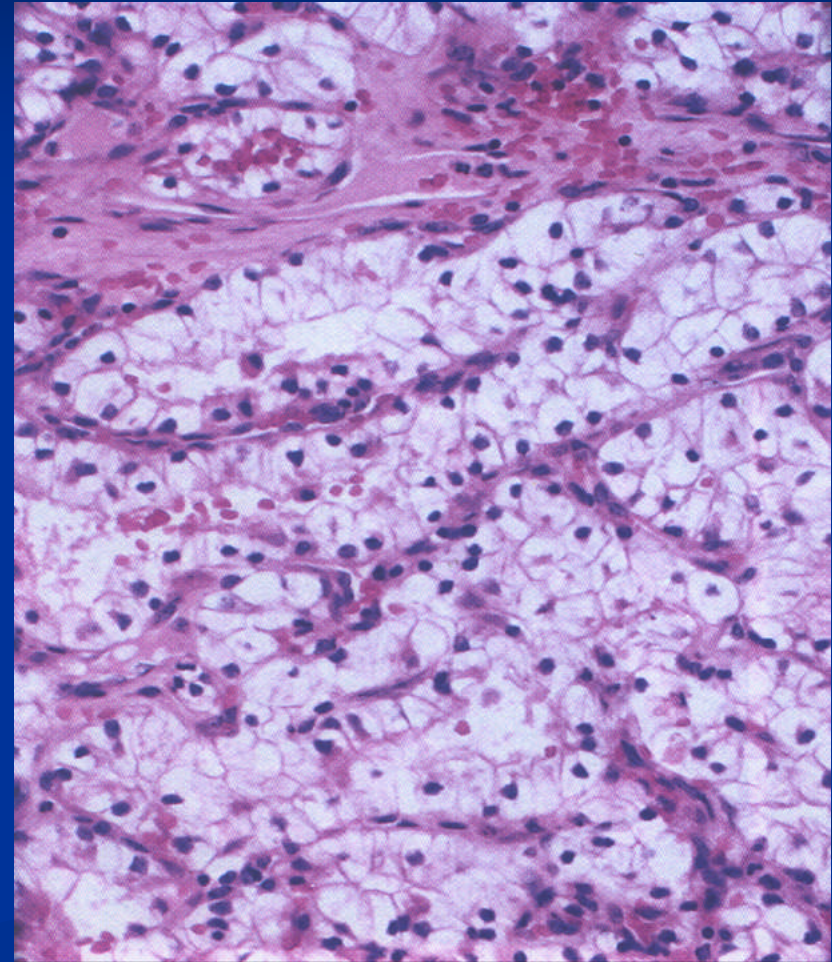




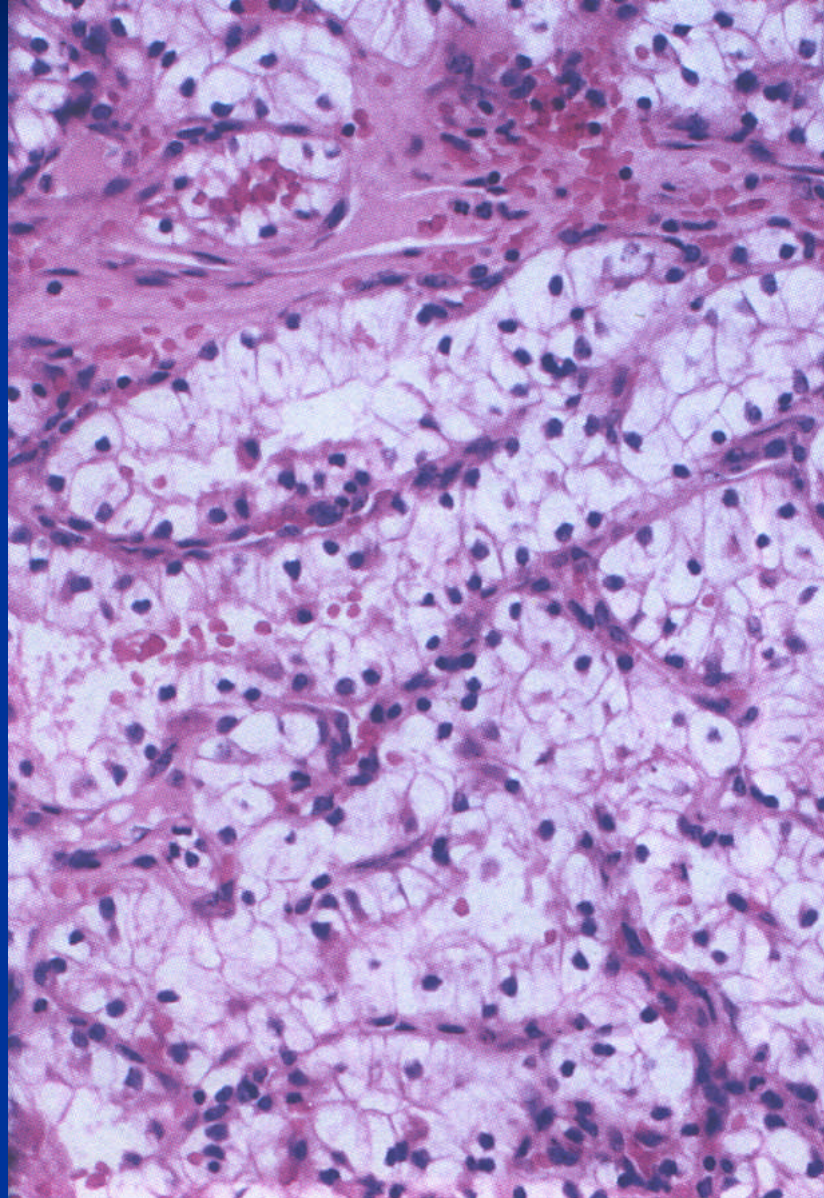


Kidney Cancer (Renal Cell Carcinoma)

- Notice that the cells are cuboidal or columnar like in shape suggestive of a carcinoma
- The cells are disorganized and stacked on top of each other; they appear crowded
- Some cells lack nuclei and some have multiple nuclei
- The lumen are lacking in certain areas
- All these characteristics are consistent with a cancerous tumor/carcinoma



Renal Cell Carcinoma

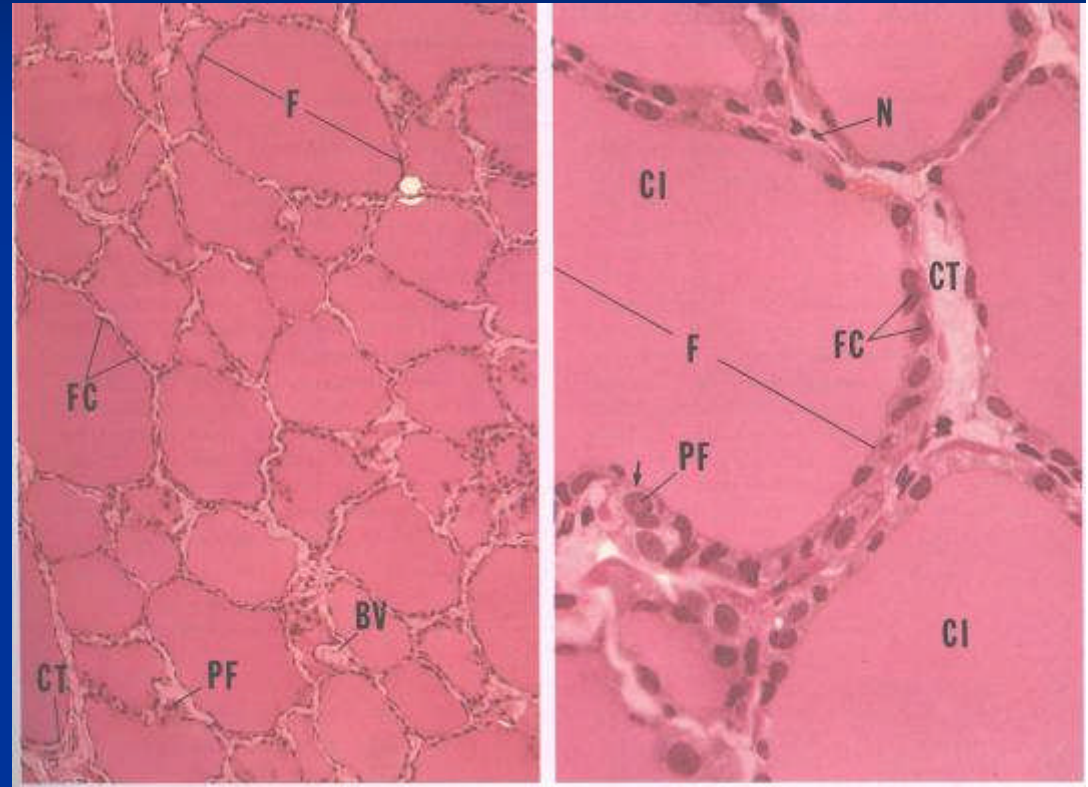


Examples of Normal Epithelial Type Tissues and Their Cancerous Counterparts

- The following several slides show examples of normal epithelial type tissues and their malignant counterparts
- Please take notice of the differences in cellular architecture between benign and malignant tumors

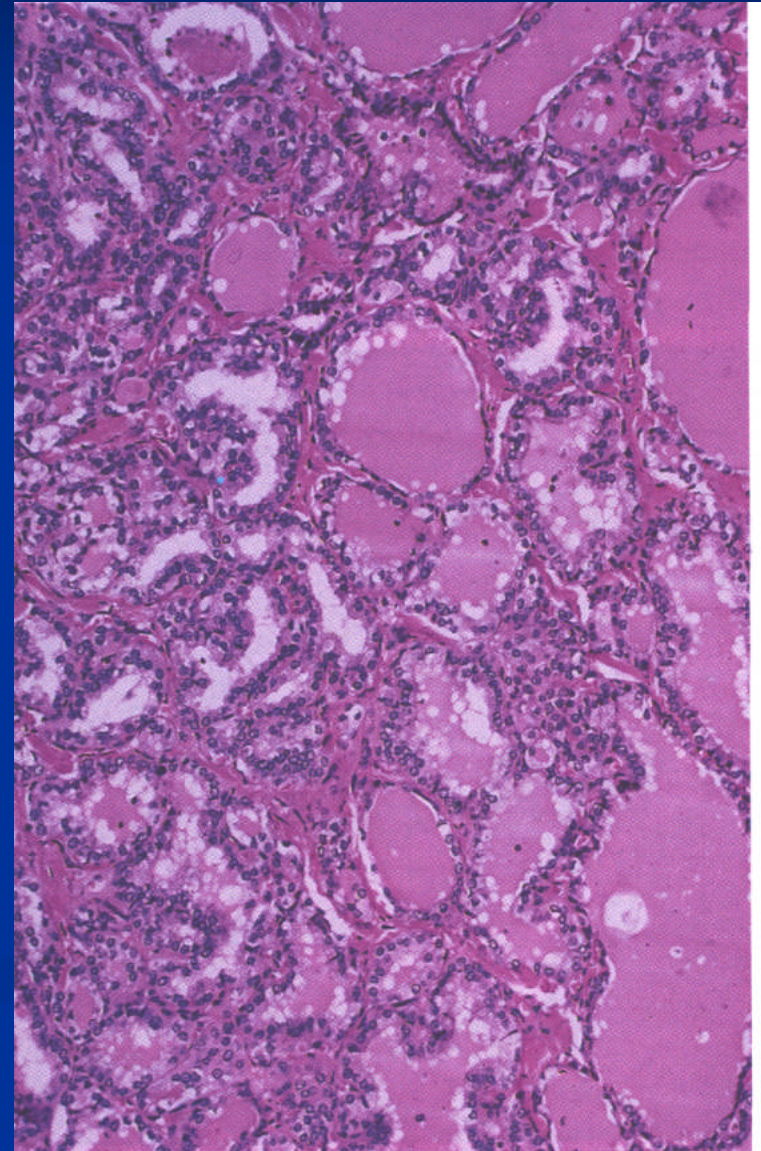
Normal Thyroid Gland

- Normal thyroid
- Orderly arrangement of cells and follicles
- Follicles contain thyroglobulin (pink material)
- No mitoses
- One layer of cells around follicle

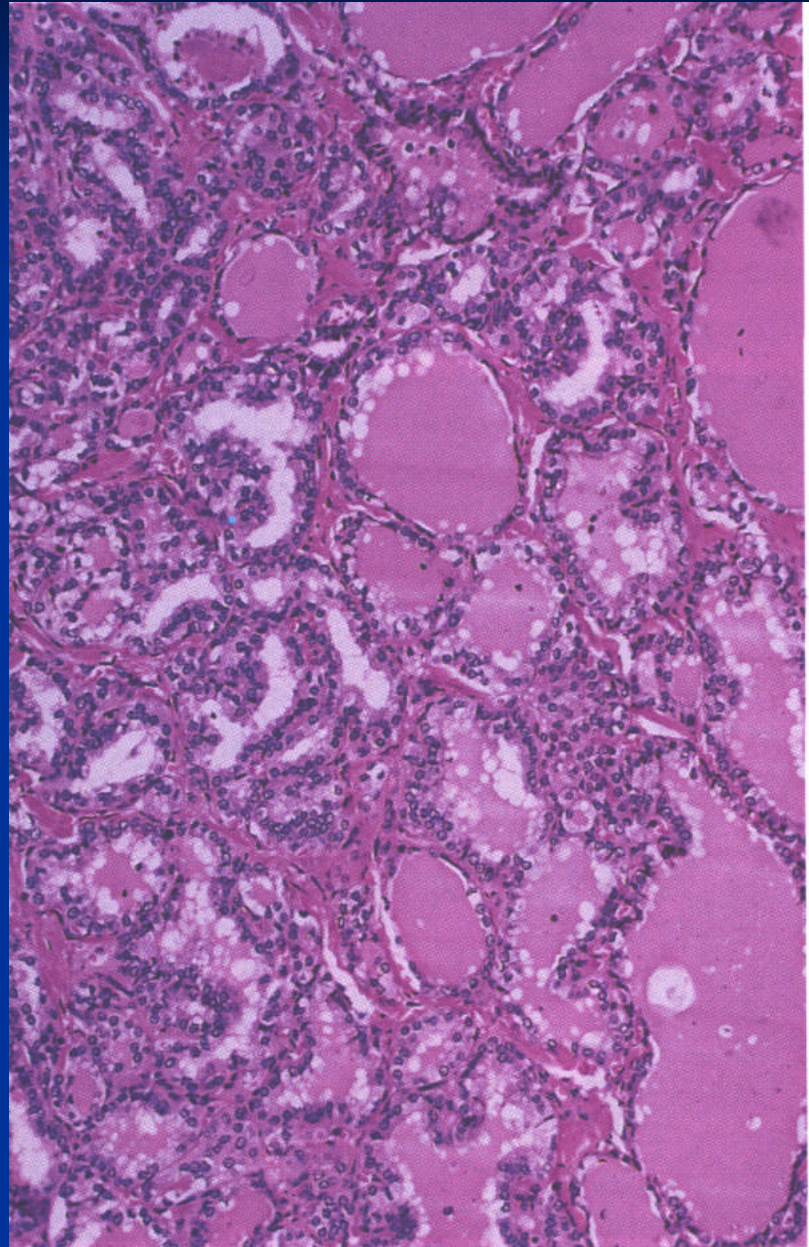


Thyroid Cancer

- Cells are crowded and packed on top of each other
- Cellular pleomorphism
- Follicles are arranged haphazard and not all follicles contain thyroglobulin
- Very dark nuclei



Thyroid Carcinoma



Connective Tissue

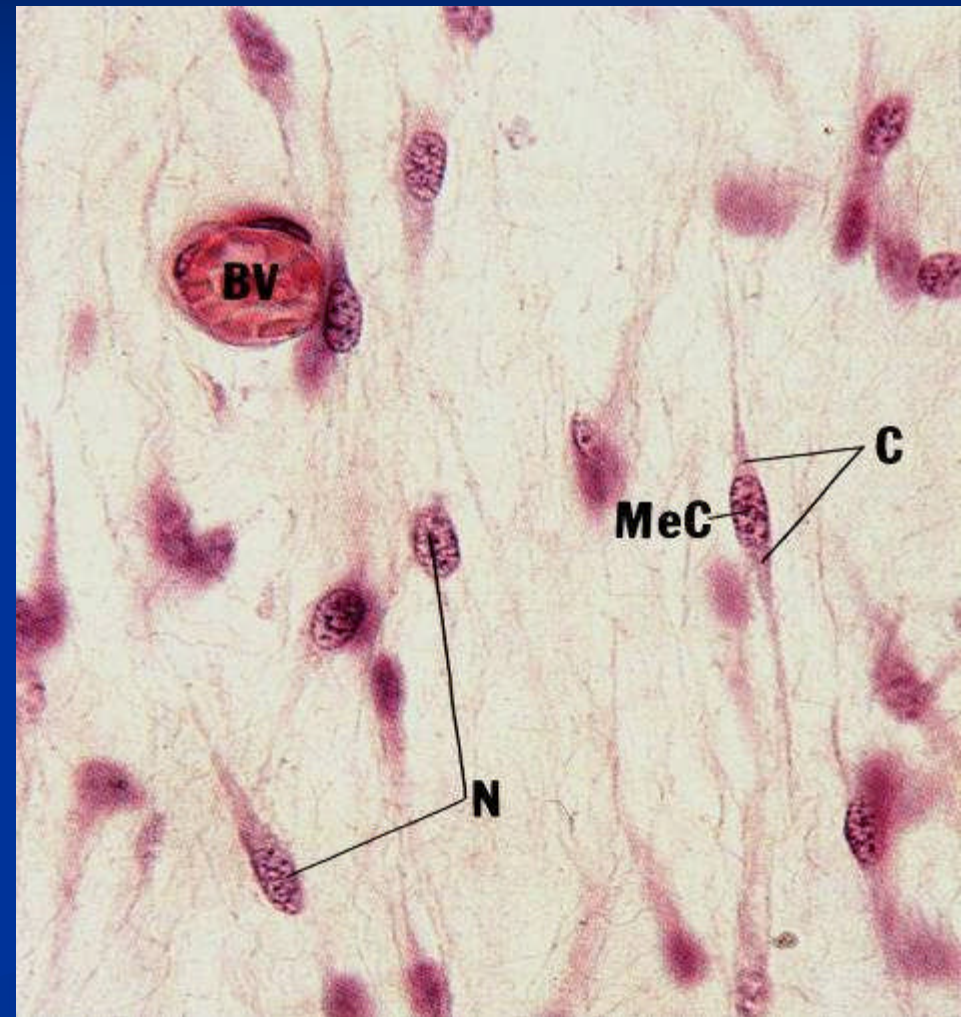
- Composed mainly of intercellular material (matrix) with a limited number of cells (hypocellular/small number of cells)
- Classified mostly on basis of material components rather than cellular constituents
- Classification:
 - Embryonic Connective Tissue
 - Adult Connective Tissue

Connective Tissue

- Embryonic Connective Tissue
 - Mesenchyme—derived from mesoderm
 - Mucous/Myxoid

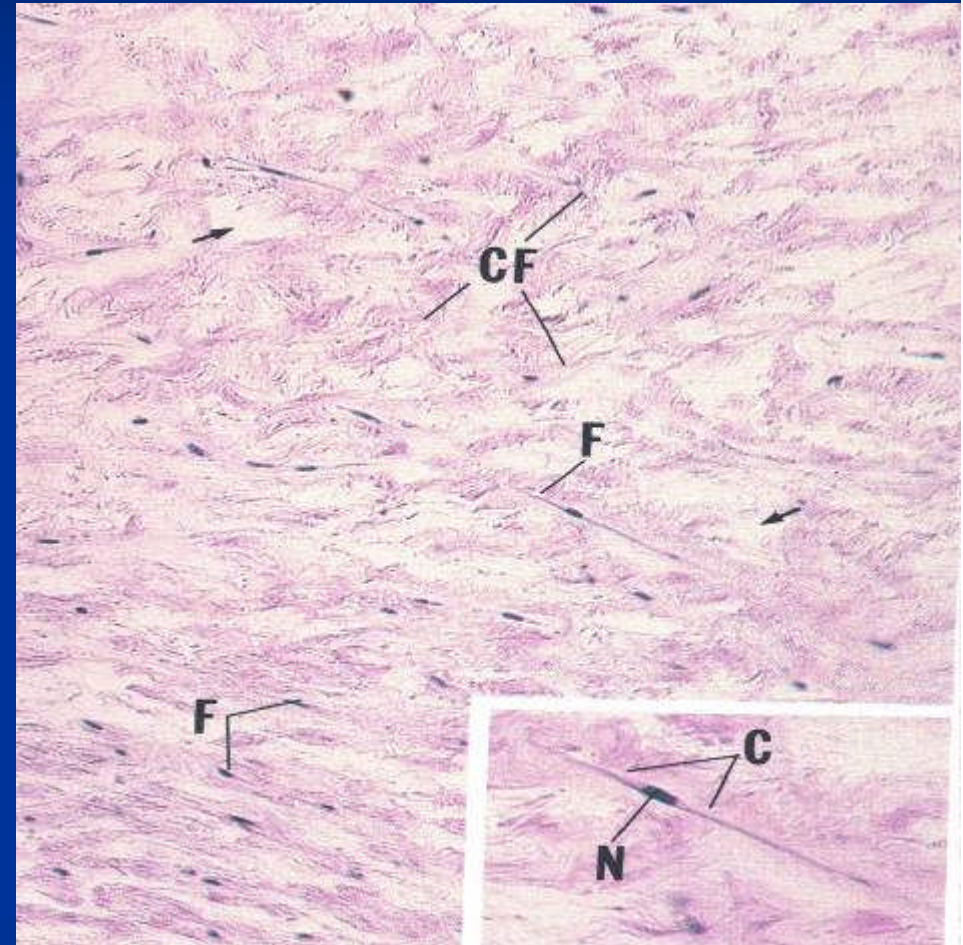
Embryonic Connective Tissue

- Cells are spindle shaped or cigar shaped
- The nucleus is large in comparison to the cytoplasm
- These cells are primitive mesenchymal cells that form the connective tissues in the body (bone, cartilage, tendons, ligaments, etc)
- Sarcomas develop from mesenchymal type cells



Myxoid or Mucous Type Tissue

- Myxoid tissue produces a mucous-like substance that is composed of mucopolysaccharides and glycosaminoglycans
- The tissue stains a bluish color because of the mucous
- The tissue appears loose and not very dense almost like wisps of cotton candy
- Notice the low cellularity, small nuclei and slender spindled shape of the cells consistent with benign connective tissue



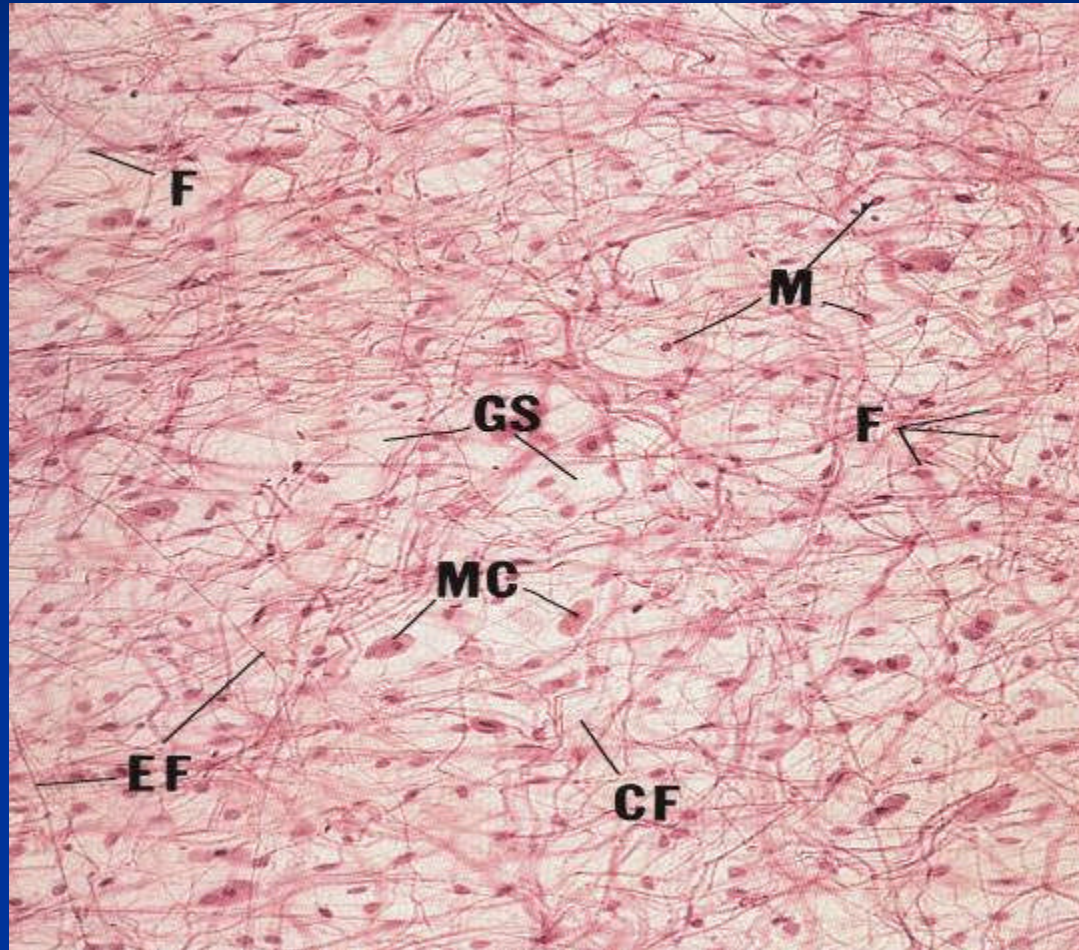
Connective Tissue

- Adult Connective Tissue
 - Connective Tissue Proper
 - Loose (areolar)
 - Reticular
 - Adipose
 - Dense Irregular
 - Dense Regular
 - Collagenous
 - Elastic
 - Specialized Connective Tissue
 - Supporting (Bone, Cartilage)
 - Blood

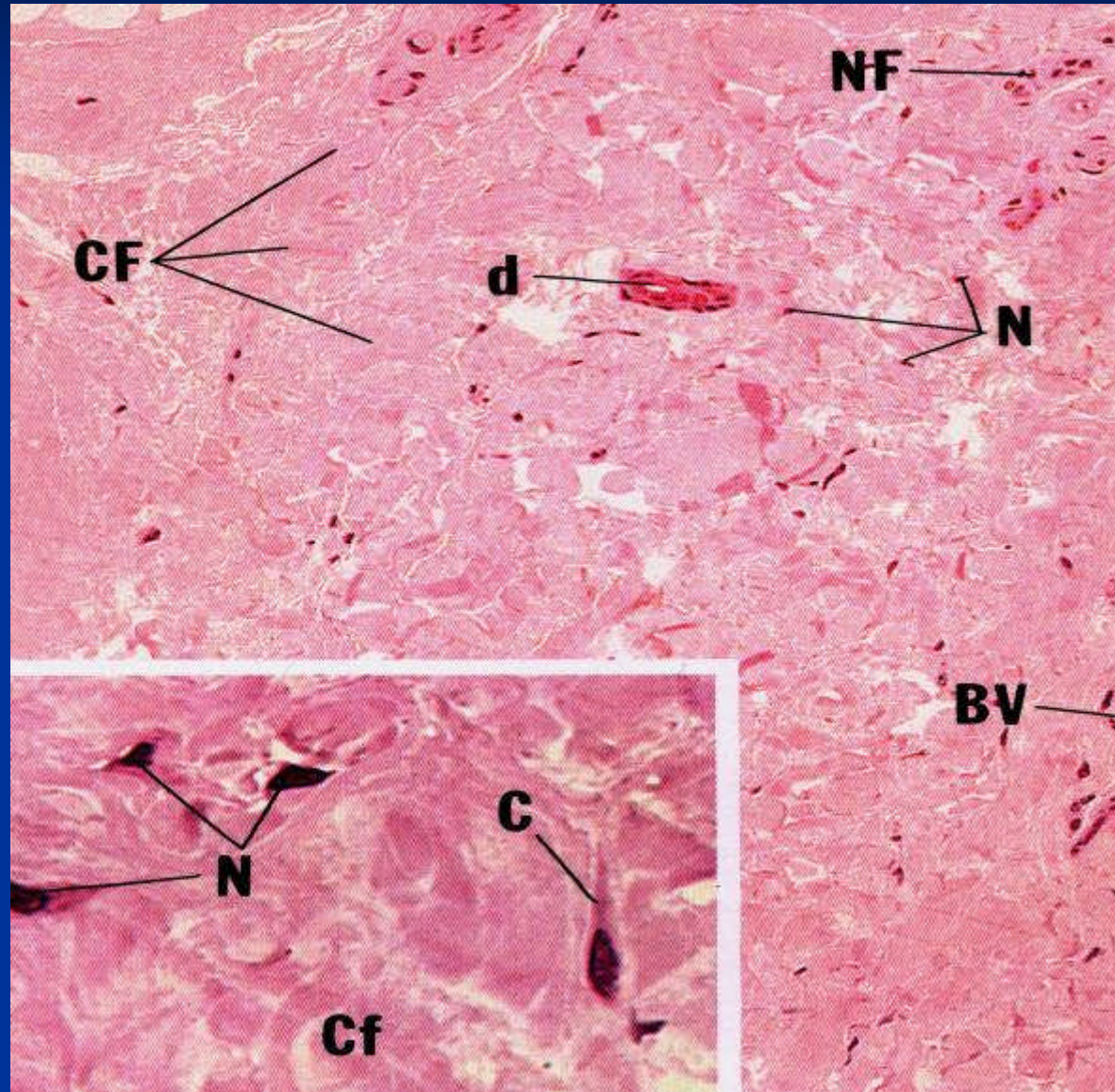
Normal Connective Tissue

- The next three slides demonstrate normal, benign connective tissue. Please take notice of the low cellularity, high matrix content (intercellular material), no mitoses, orderly arrangement of cells, lack of cellular pleomorphism, small nuclei—all characteristics of benign tissue
- The fourth slide is a sarcoma, derived from a primitive connective tissue cell; it is hypercellular; the nuclei are large and cigar shaped; the cells are crowded and arranged haphazardly; there is disorganization—all characteristics of a cancerous tumor of connective tissue origin or a sarcoma

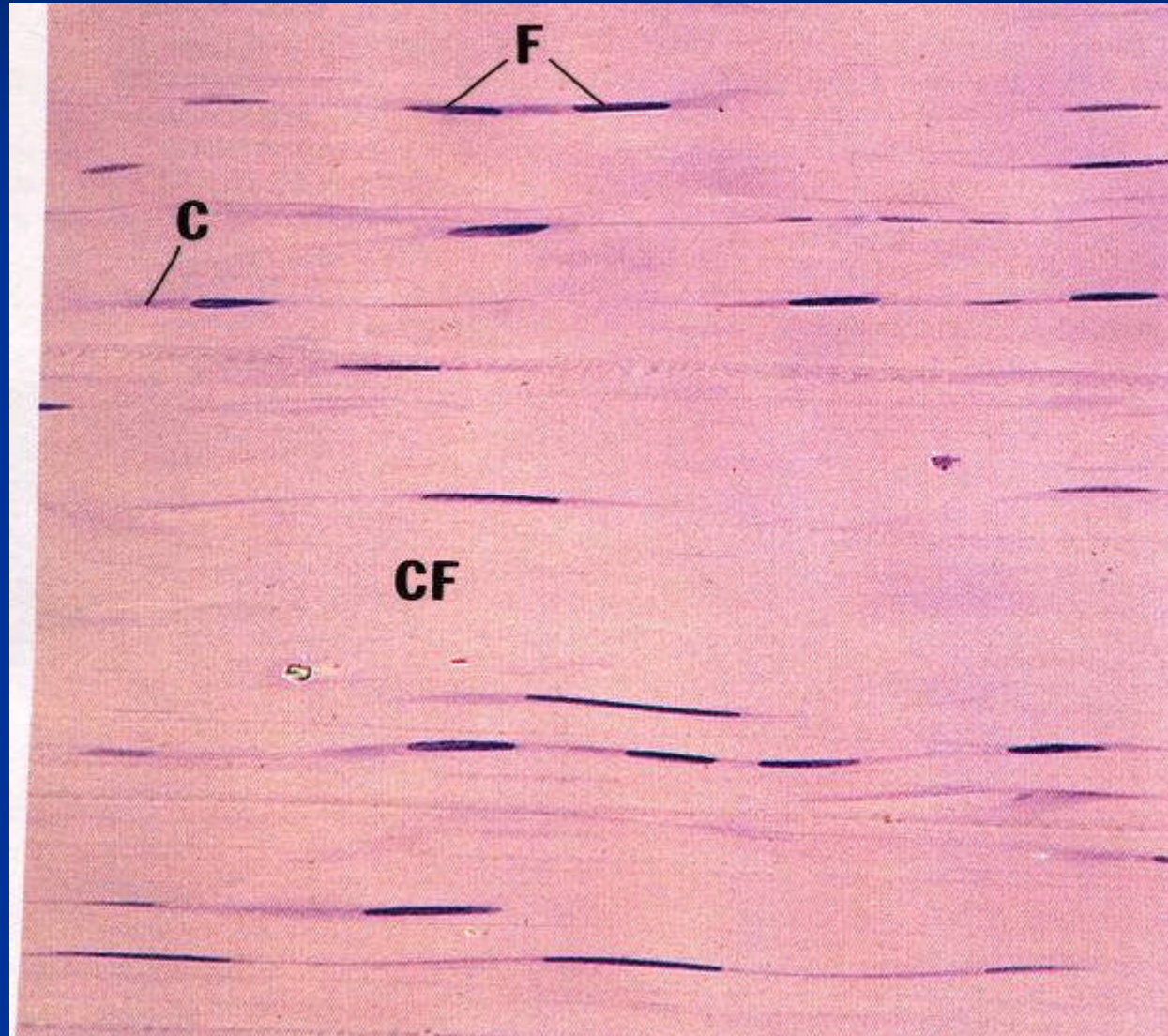
Loose Connective Tissue



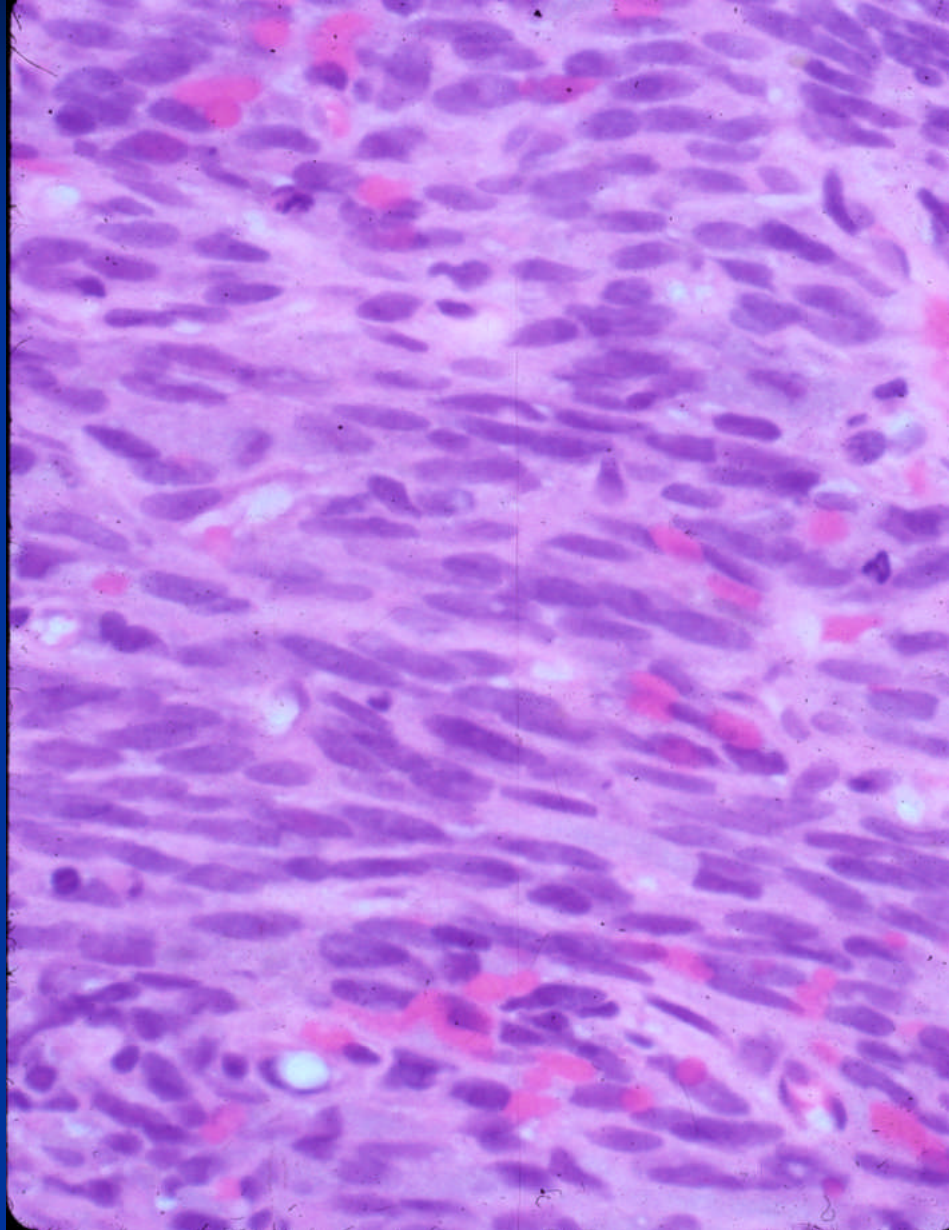
Dense Irregular Connective Tissue



Dense Regular Connective Tissue Tendon

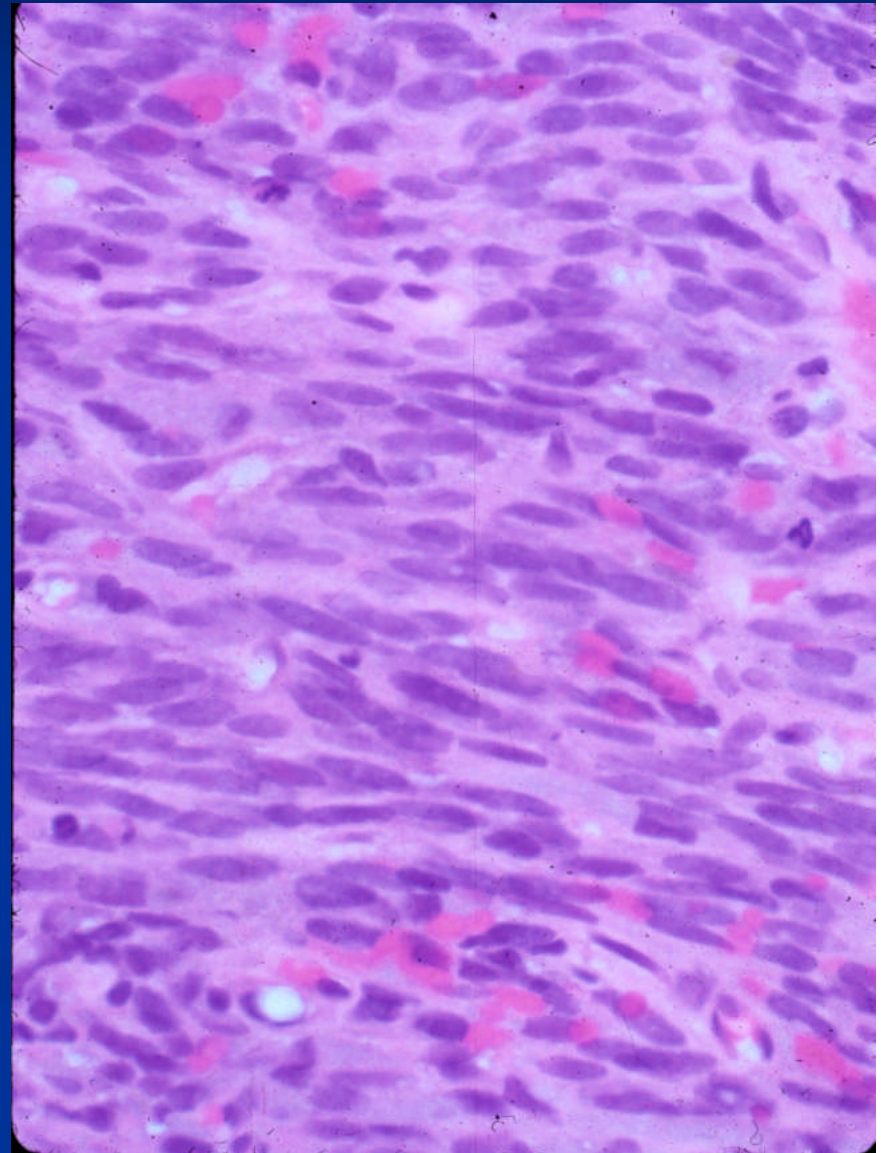


Sarcoma/Fibrosarcoma



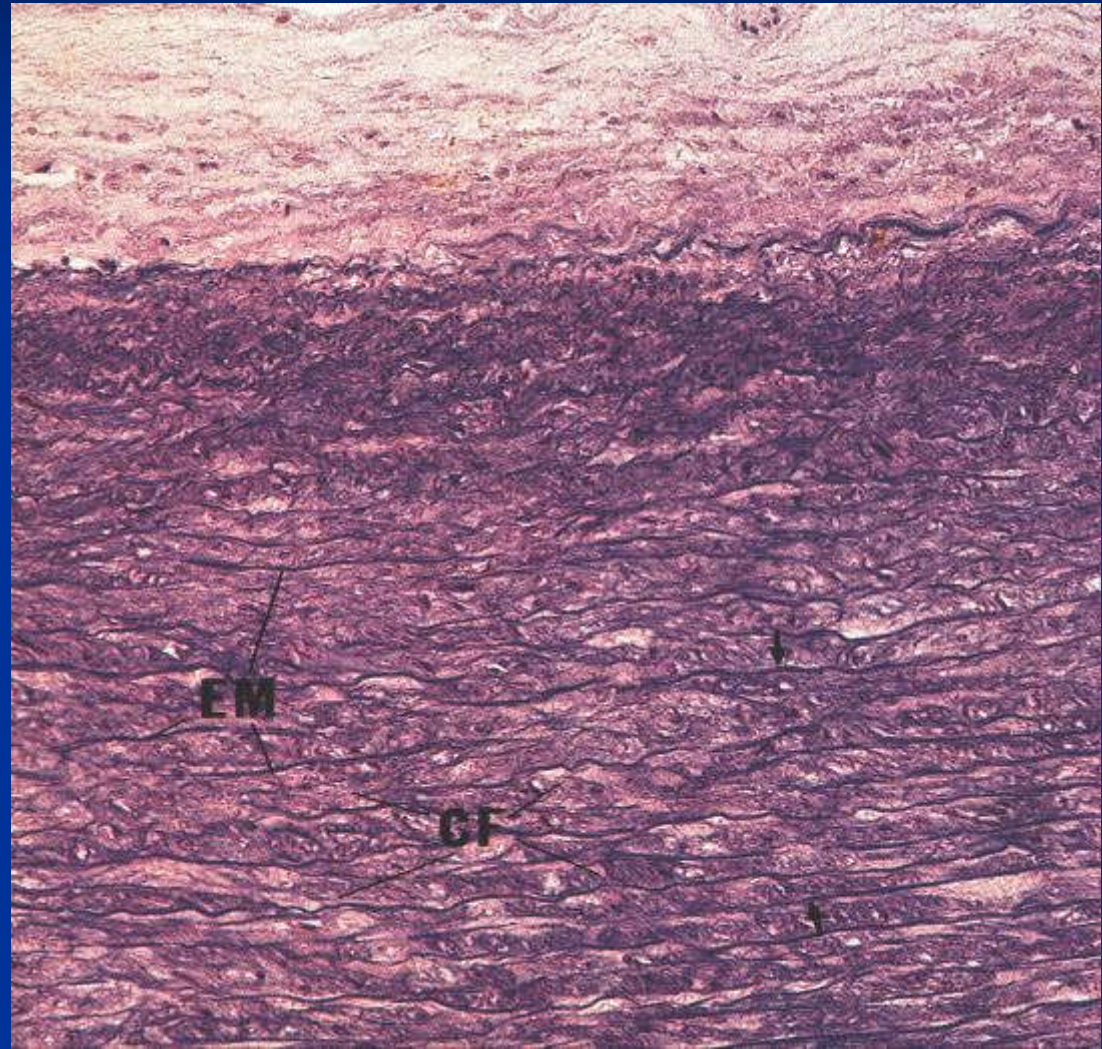
Fibrosarcoma / Malignant Spindle Cell Tumor

- Sarcoma—Cancer
- Large Nuclei and Small amount of Cytoplasm
- Nuclear Pleomorphism
- Hypercellular and Crowded
- Disorganized Architecture
- Mitotic Figures
- Small Amount of Matrix



Elastic Connective Tissue

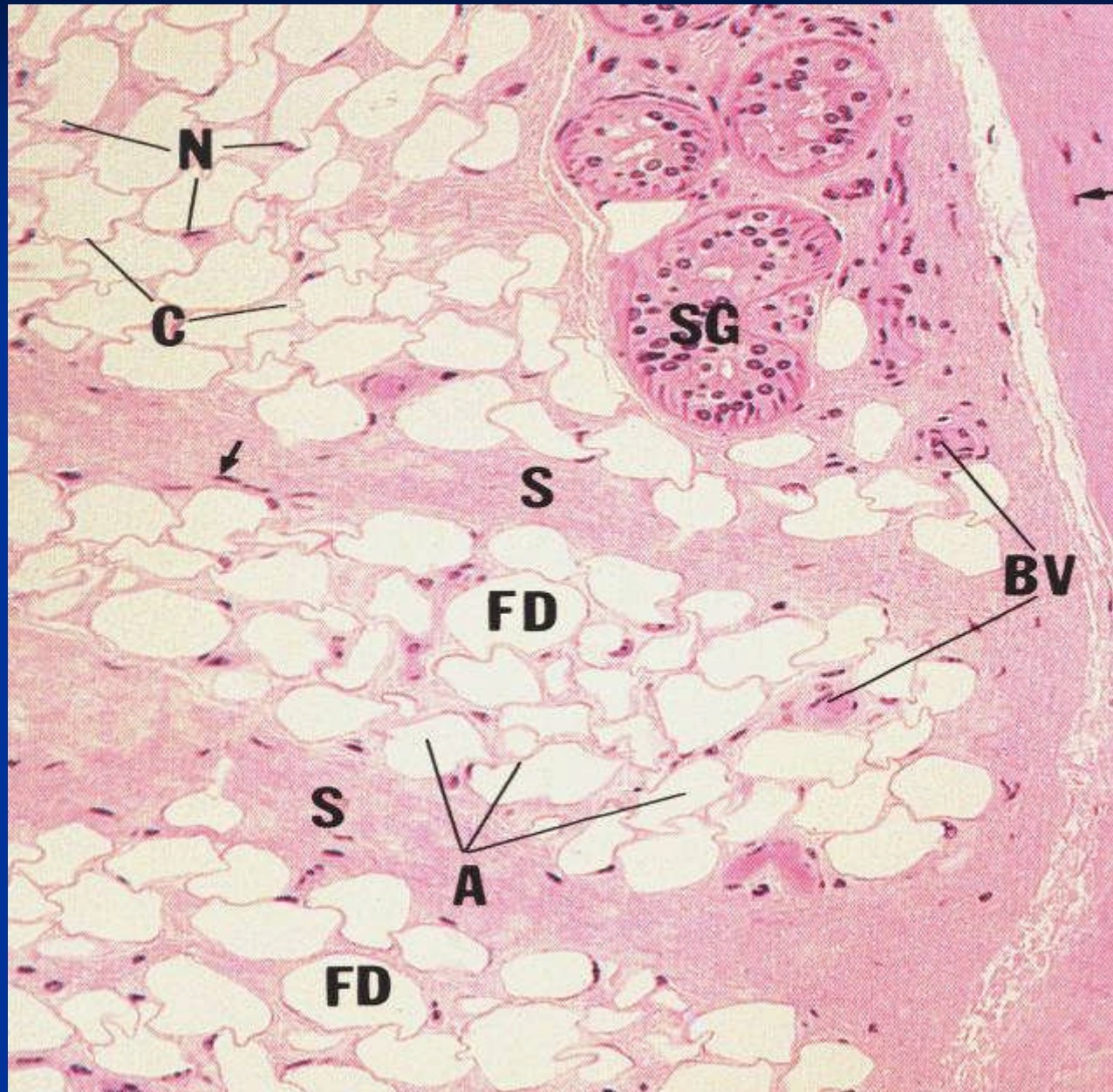
- The dark stained wiry and wavy fibers are elastic (elastin) fibers produced by the fibroblasts
- Elastofibromas are benign soft tissue tumors that are composed of cells that produce elastin fibers



Adipose/Fatty Tissue

- The cells of normal mature adipose tissue have a large cytoplasm that contains the lipids
- The nucleus is small, eccentric and compressed up against the cell membrane
- There are no mitotic figures
- The cells appear organized and are similar size and shape

Adipose/Fat Tissue



Cartilage

■ 3 Types of Cartilage

■ Hyaline

- Articulating surfaces of bone

■ Elastic

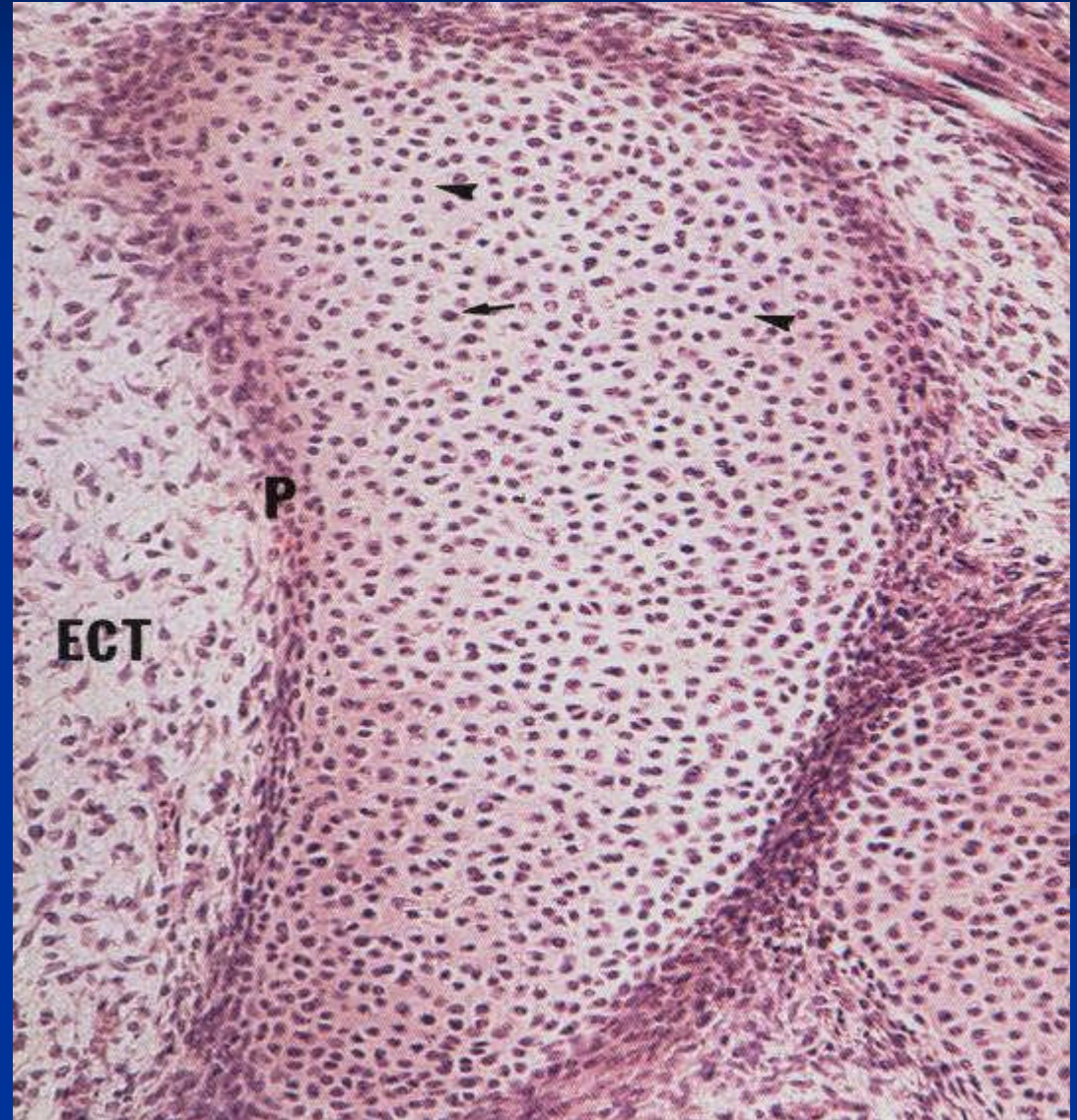- Epiglottis, Ear

■ Fibrocartilage

- Symphyses, eustacian tube, intervertebral discs, tendon insertions

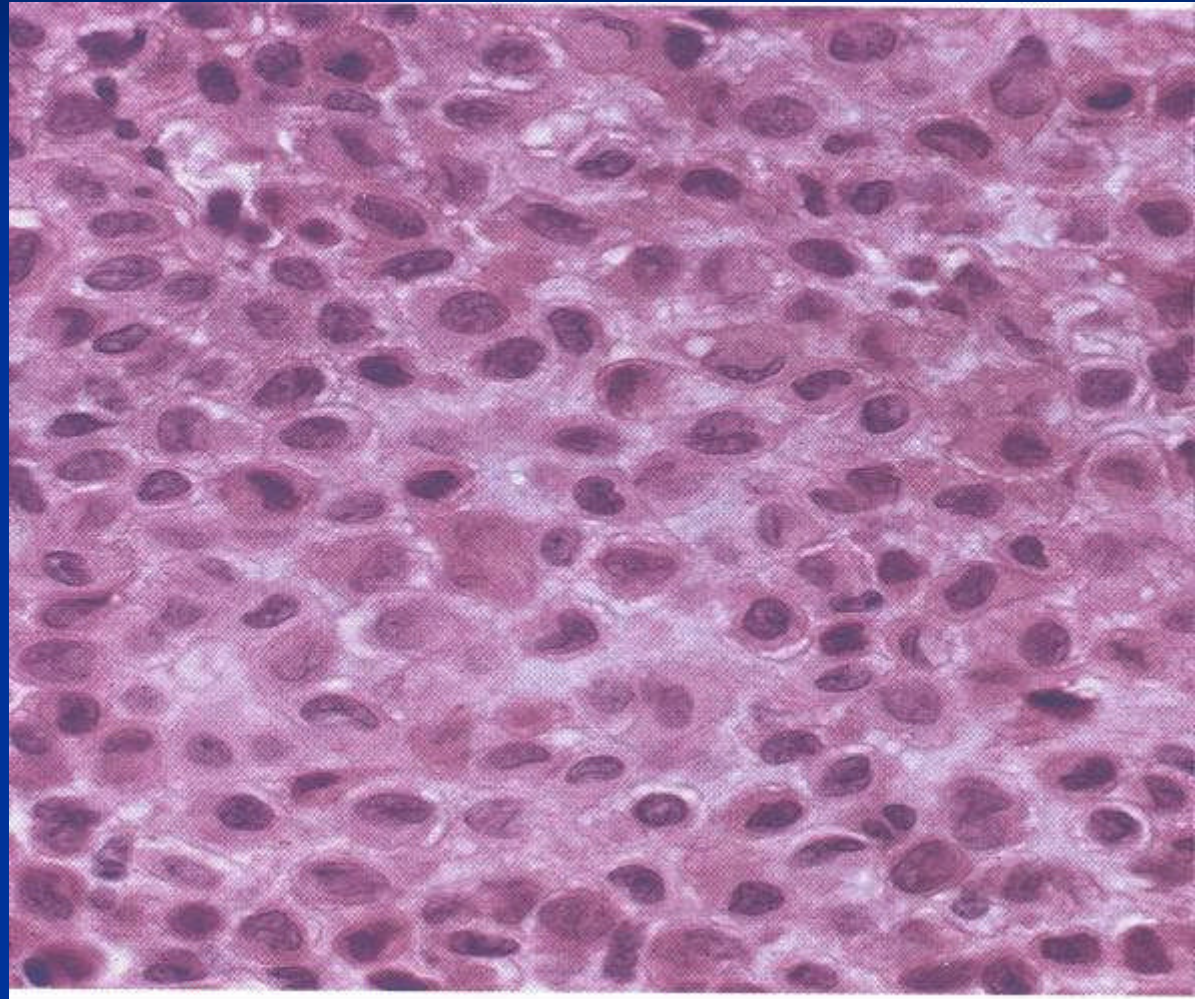
Fetal Chondroblasts of Femur

- Nuclei are Uniform
- Large Nuclei with Plump Cytoplasm
- Appears Organized
- No Mitoses



Chondroblastoma

- A chondroblastoma is a benign bone tumor
- It is composed of immature chondroblasts that resemble fetal hyaline chondroblasts
- They have a thick cell membrane, large, often bean shaped nucleus and plump cytoplasm
- The cells are uniform and there are no mitoses

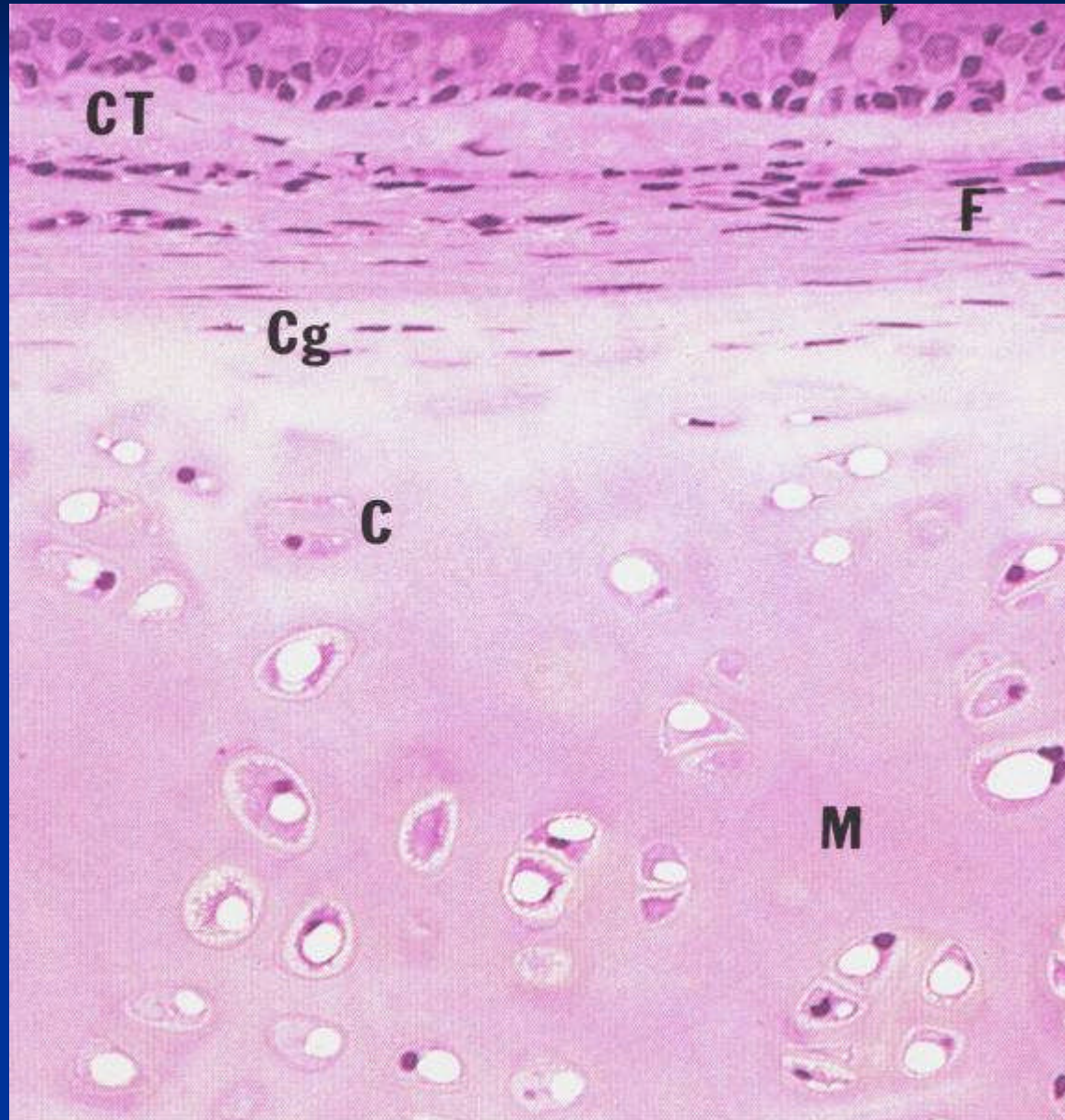


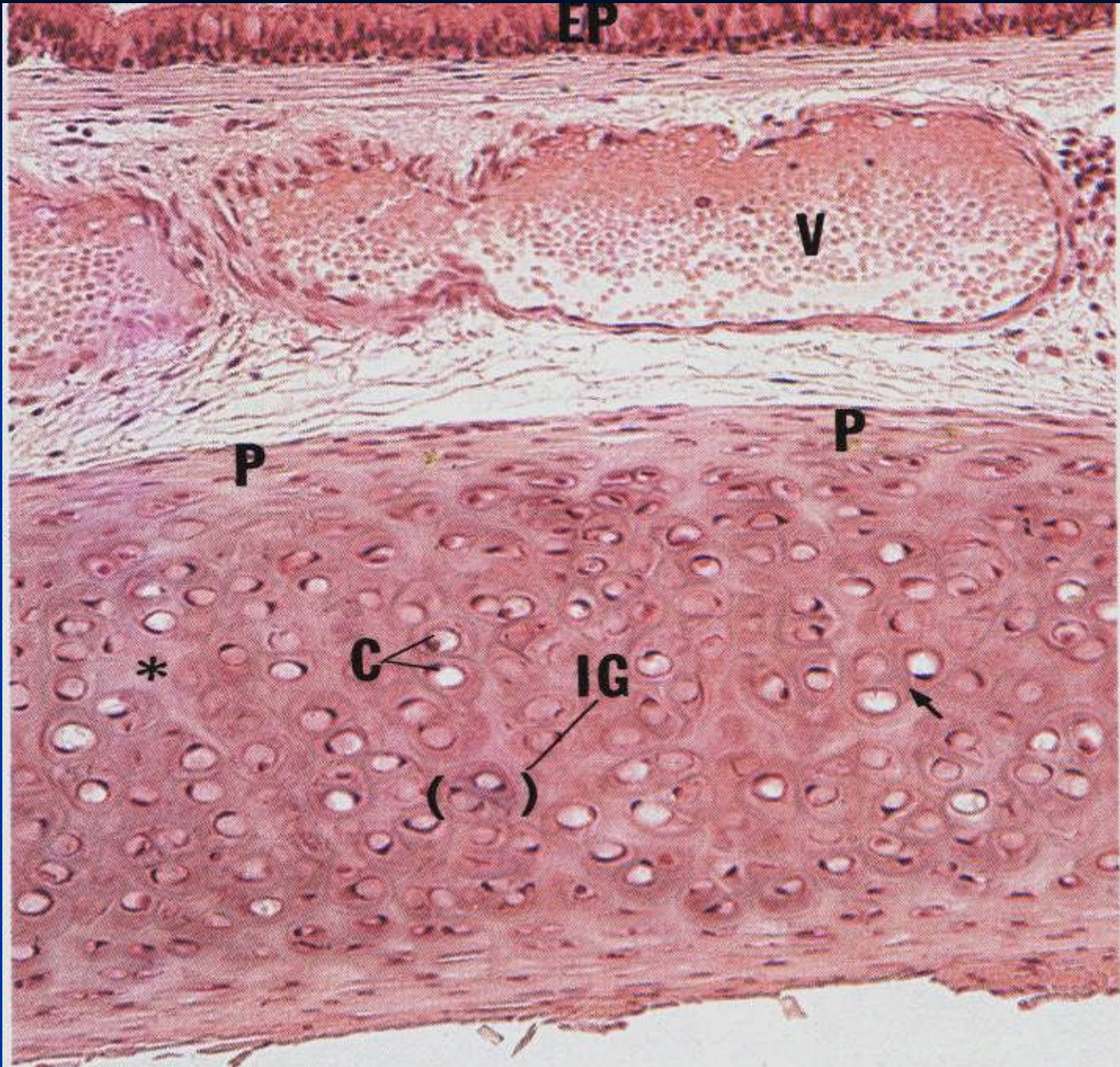
Cartilage

■ Characteristics:

- Non vascular, strong and pliable
- Matrix: glycosaminoglycans in which fibrous and cellular elements are embedded
- Fibers: collagen or collagen and elastic
- Cells: Chondrocytes embedded in spaces (Lacunae)
- Matrix appears smooth and glassy because the fibers are fine and are masked by the glycosaminoglycans; the orientation of the fibers leads to its glassy appearance under a microscope
- Normal Cartilage is hypocellular; the cells are orderly placed; there are no mitoses

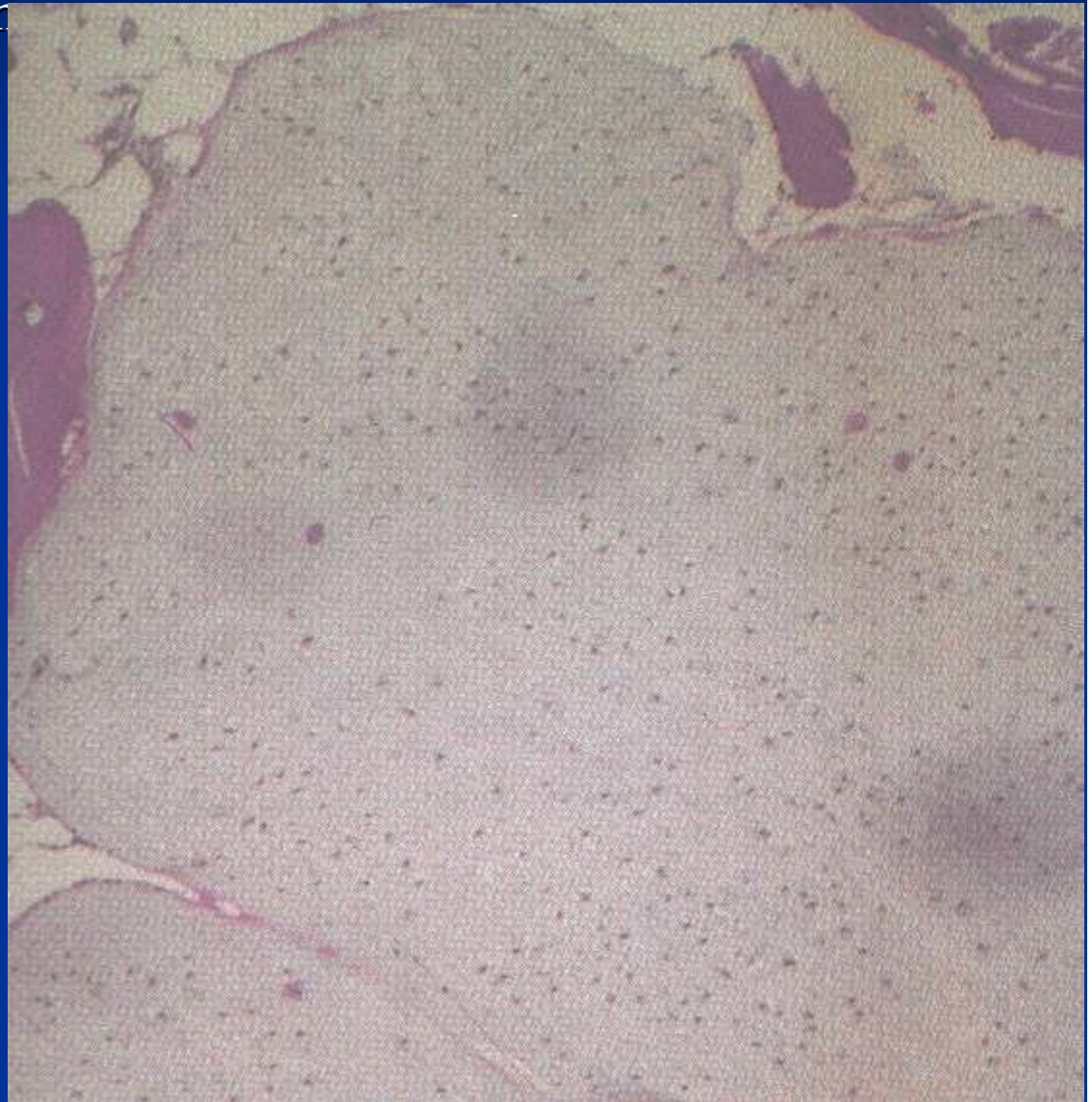
Hyaline Cartilage



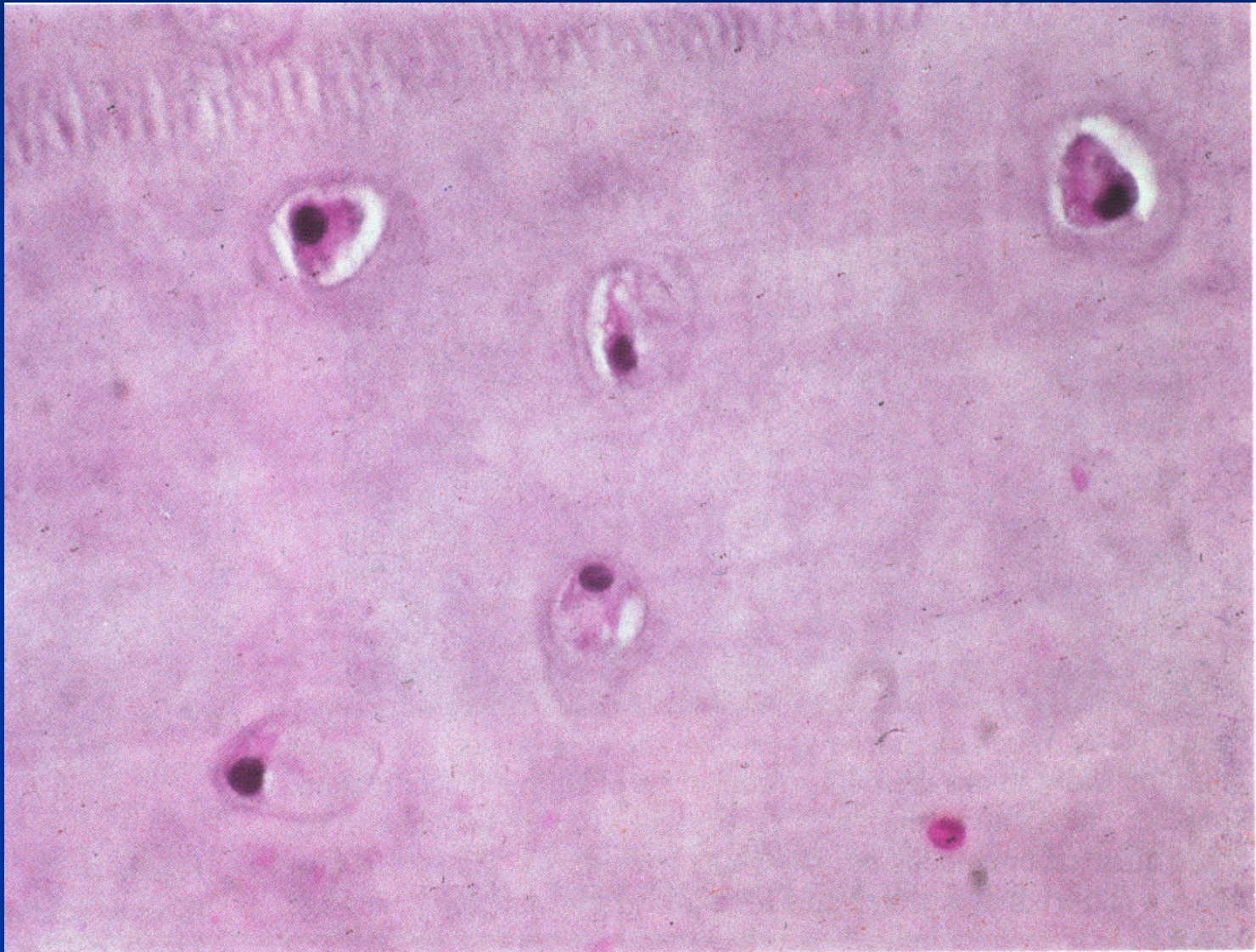


Enchondroma

- An enchondroma is a benign bone tumor composed of cartilaginous tissue
- Cartilage also grows in lobules
- Cells are in lacunae
- It is hypocellular
- Cells are small and orderly placed; Nuclei are small and similar size and shape
- Matrix stains bluish due to glycosaminoglycans

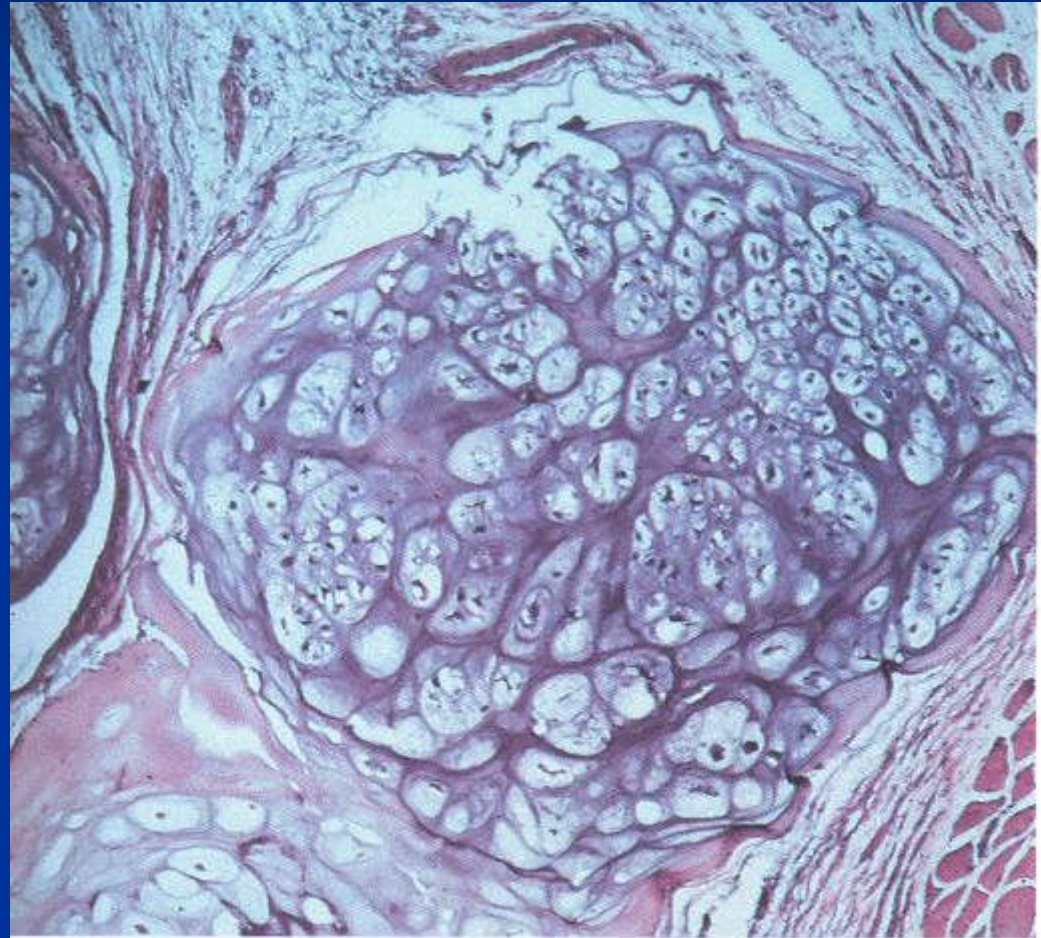


Enchondroma

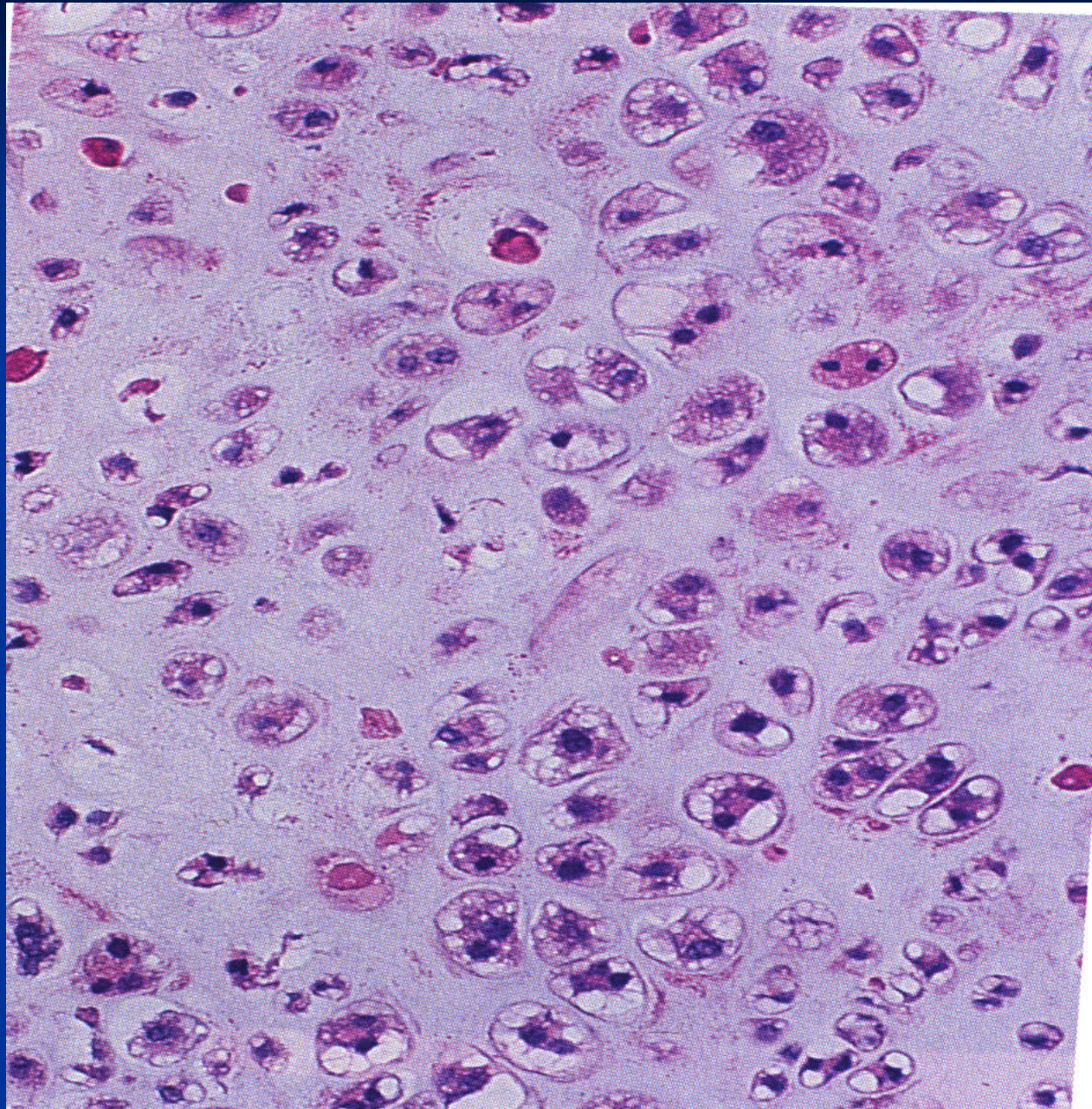


Chondrosarcoma

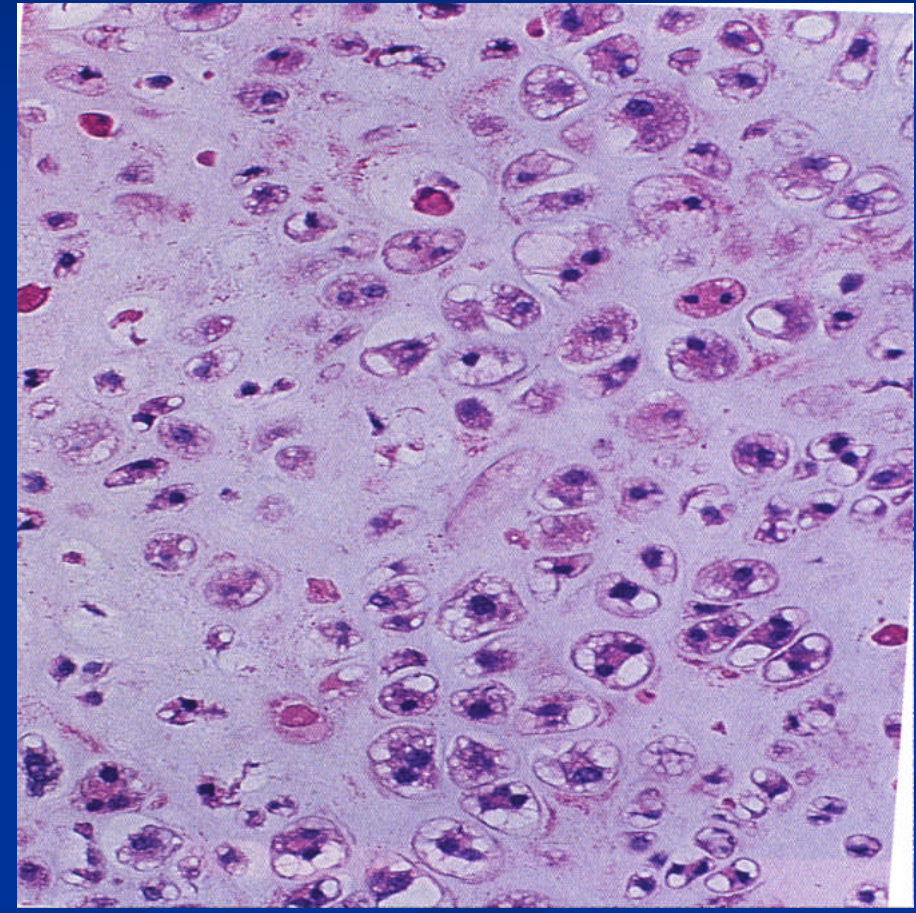
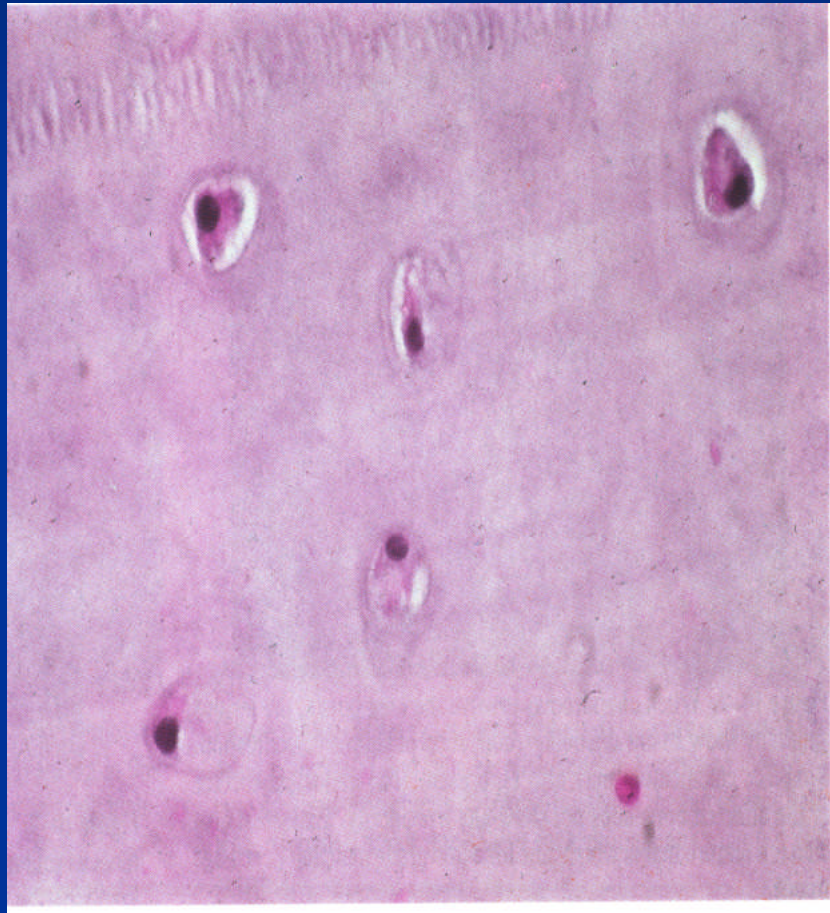
- In a chondrosarcoma (malignant cartilage tumor) the cells are in lacunae but are large, bizarre in shape and pleomorphic
- The tumor is hypercellular
- Cells are crowded
- There may be mitotic figures
- The cartilage may entrap or invade bone
- Binucleated or multinucleated cells often exist



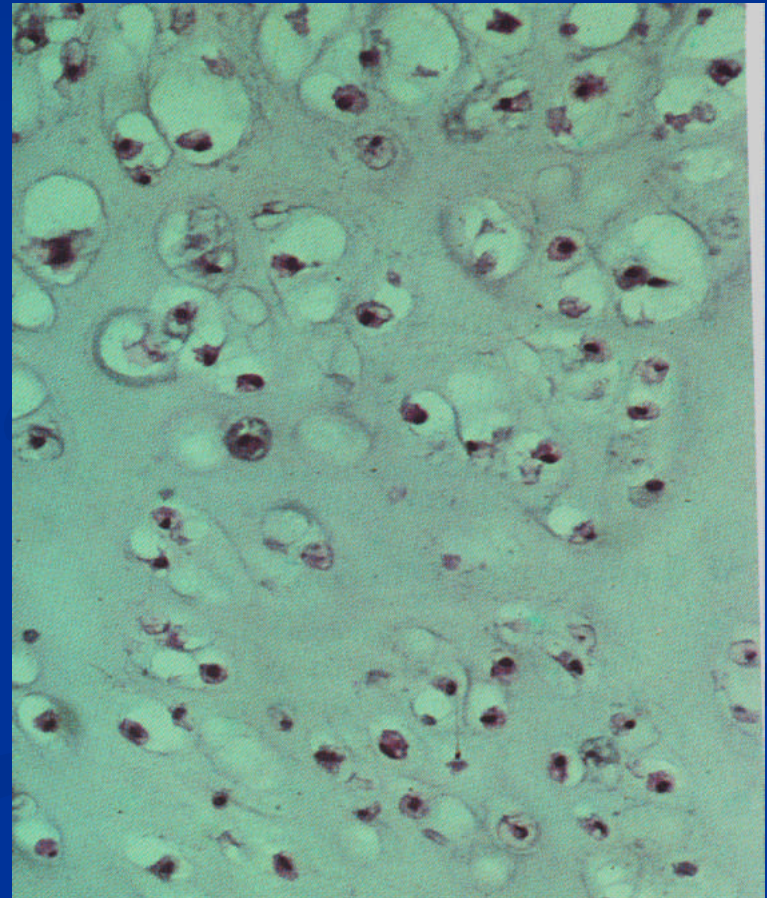
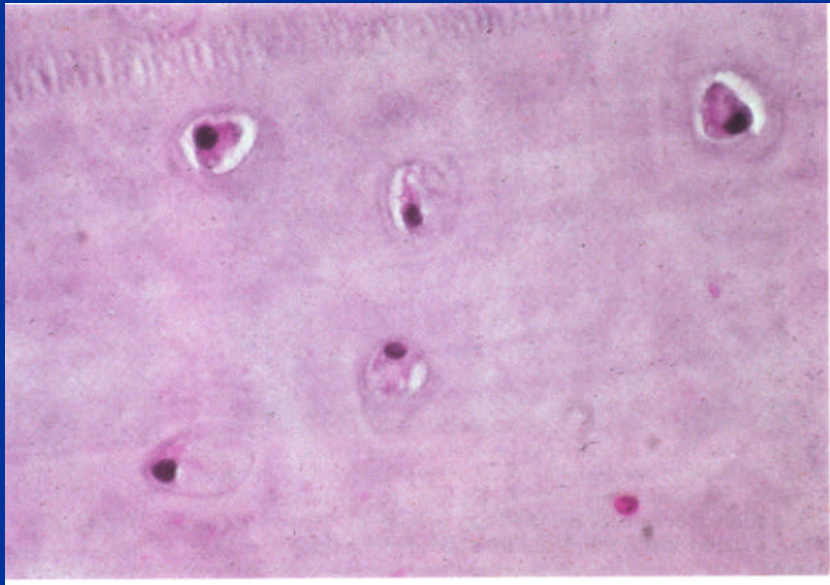
Chondrosarcoma



Enchondroma/Chondrosarcoma



Enchondroma/Chondrosarcoma



Bone

- Vascular Connective Tissue
- **Types**
 - Dense or Compact (Cortical)
 - Sponge-like or Cancellous

Bone

■ Cells

- Osteoblasts—immature cells that make bone
- Osteocytes—mature cells that maintain bone homeostasis
- Osteoclasts---mature multinucleated cells that resorb bone
- Bone is in a constant state of flux where bone is being resorbed by osteoclasts and new bone layed down by osteoblasts

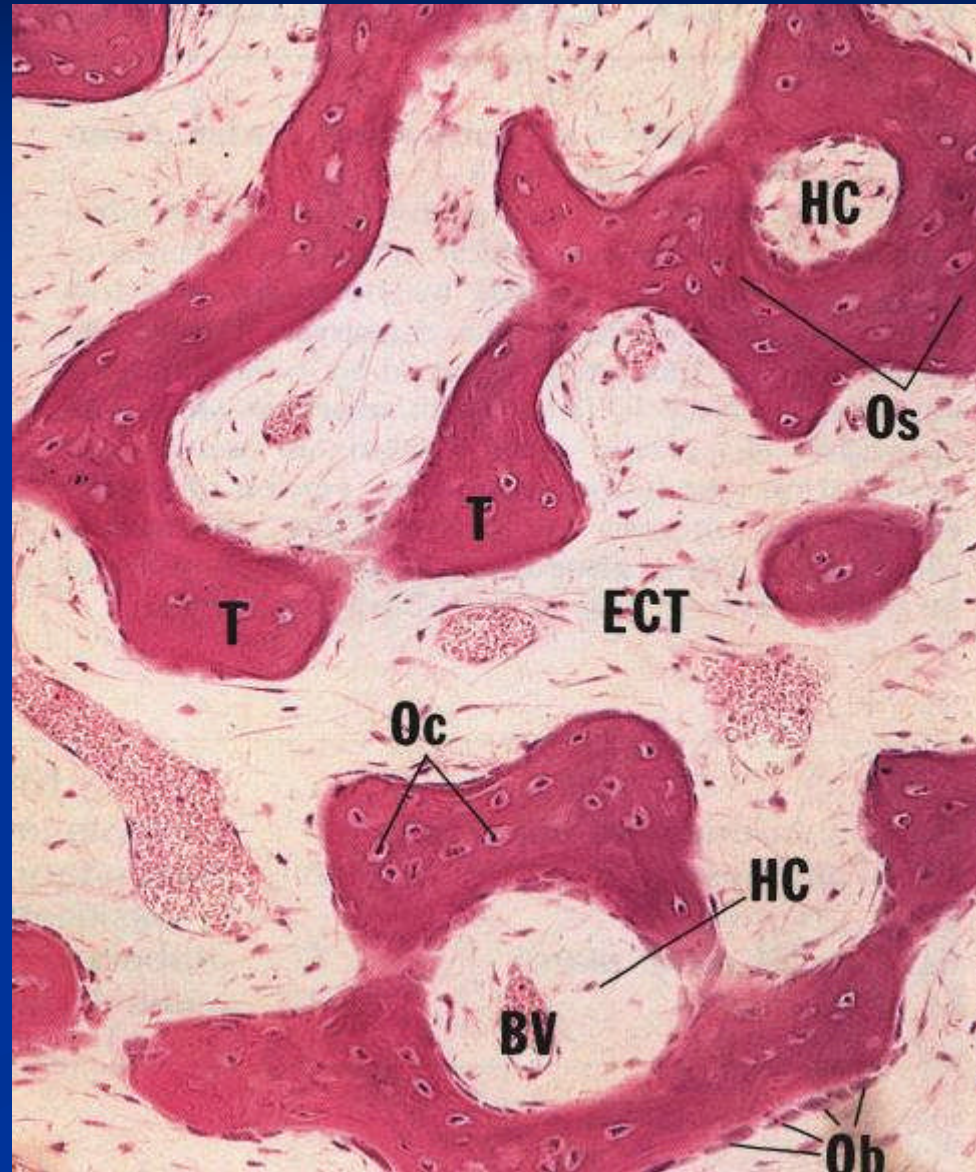
- **Osteoid** is immature bone composed of collagen before it becomes calcified. Osteoblasts produce osteoid which is usually layed down on pre-existing bone. The osteoid ultimately becomes calcified and reorganized into a mature form of bone (either trabeculae or becomes incorporated into a haversion system). **Bone producing tumors like osteosarcoma, osteoblastoma and osteoid osteoma are characterized by their production of osteoid.**

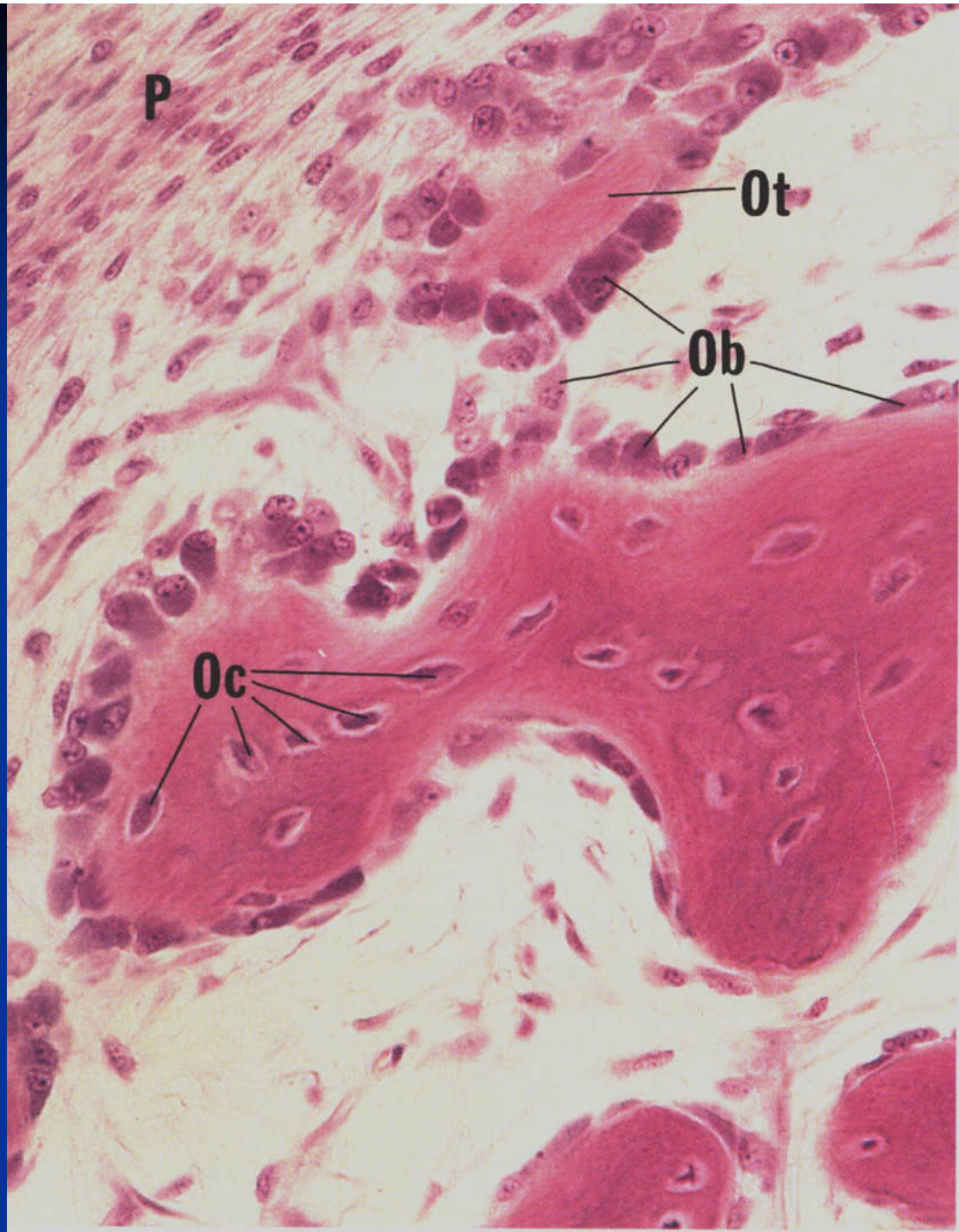
Bone

- **A Bone is composed of Cancellous Bone and Cortical Bone.**
- **Cancellous (Forms medullary canal/in the center of bone where the marrow exists)**
 - Large open spaces surrounded by thin anastomosing plates of bone (trabeculae)

Cancellous/Trabecular Bone

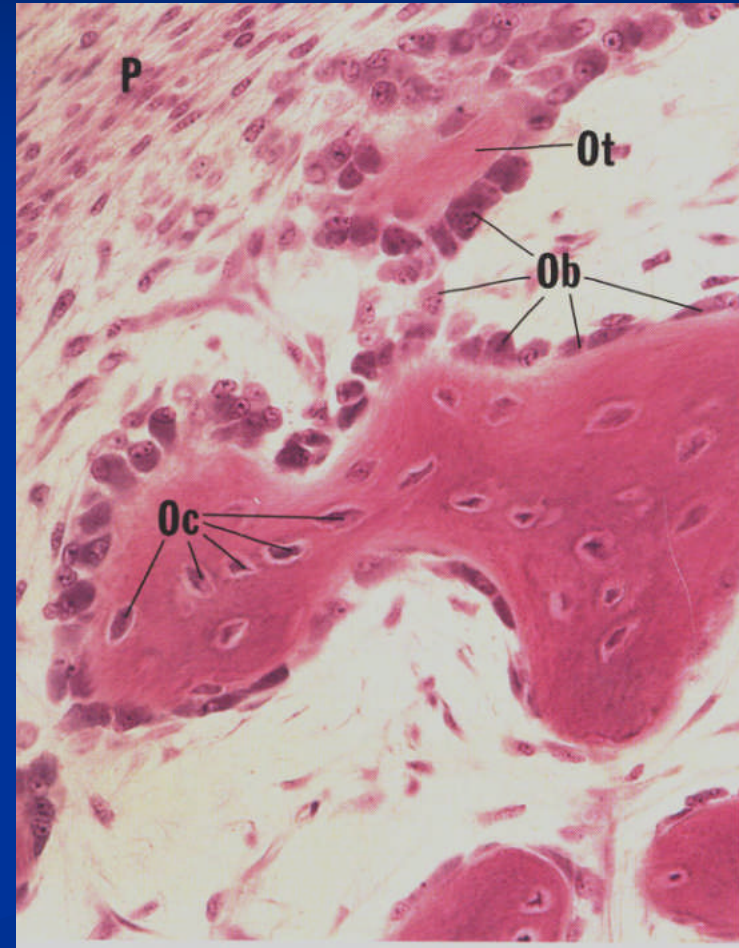
- The trabeculae (T) consist of narrow interconnecting plates of bone
- The bone marrow fills the space between the trabeculae
- The trabeculae are narrow so they do not need blood vessels in the center of them (The blood vessels are in the marrow)
- Ob = osteoblast;
- Oc = osteocyte





Normal Bone Trabecula

- The Osteoblasts (Ob) are plump and similar size and shape. They have a prominent nucleus. They are laying down osteoid on a pre-existing piece of bone. The osteoid is not calcified and therefore appears as a clear area between the osteoblasts and pre-existing bone (stains red or dark pink)
- The osteoblasts ultimately become incorporated into the bone and become less active. Once they become incorporated into the bone they become the osteocytes (Oc). The osteocytes are smaller, less plump and sit in lacunae (spaces) within the bone.



Bone

■ Compact bone (Cortical bone)

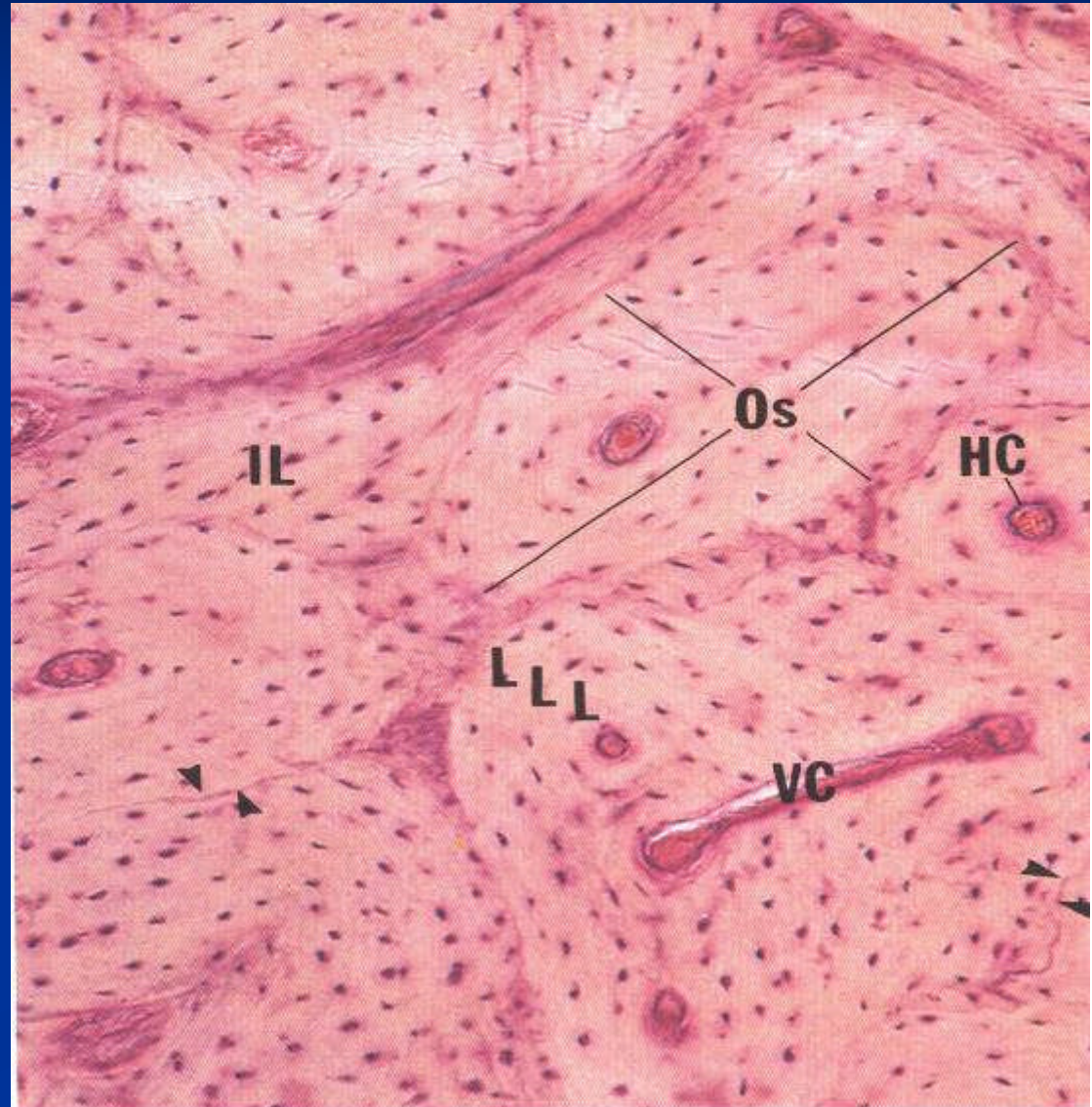
- Denser than cancellous bone
- Organized into lamellae
- Spaces are small
- Has blood vessels/haversian systems
- Cells: Osteoblasts, Osteocytes, Osteoclasts
- Osteocytes occupy lacunae
- Osteon (haversian Canal System): Haversian canal with surrounding lamellae of bone containing canaliculi radiating to it from the osteocytes trapped in lacunae
- Haversian canals: Parallel to long axis; Volkman's canals connect the haversian canals

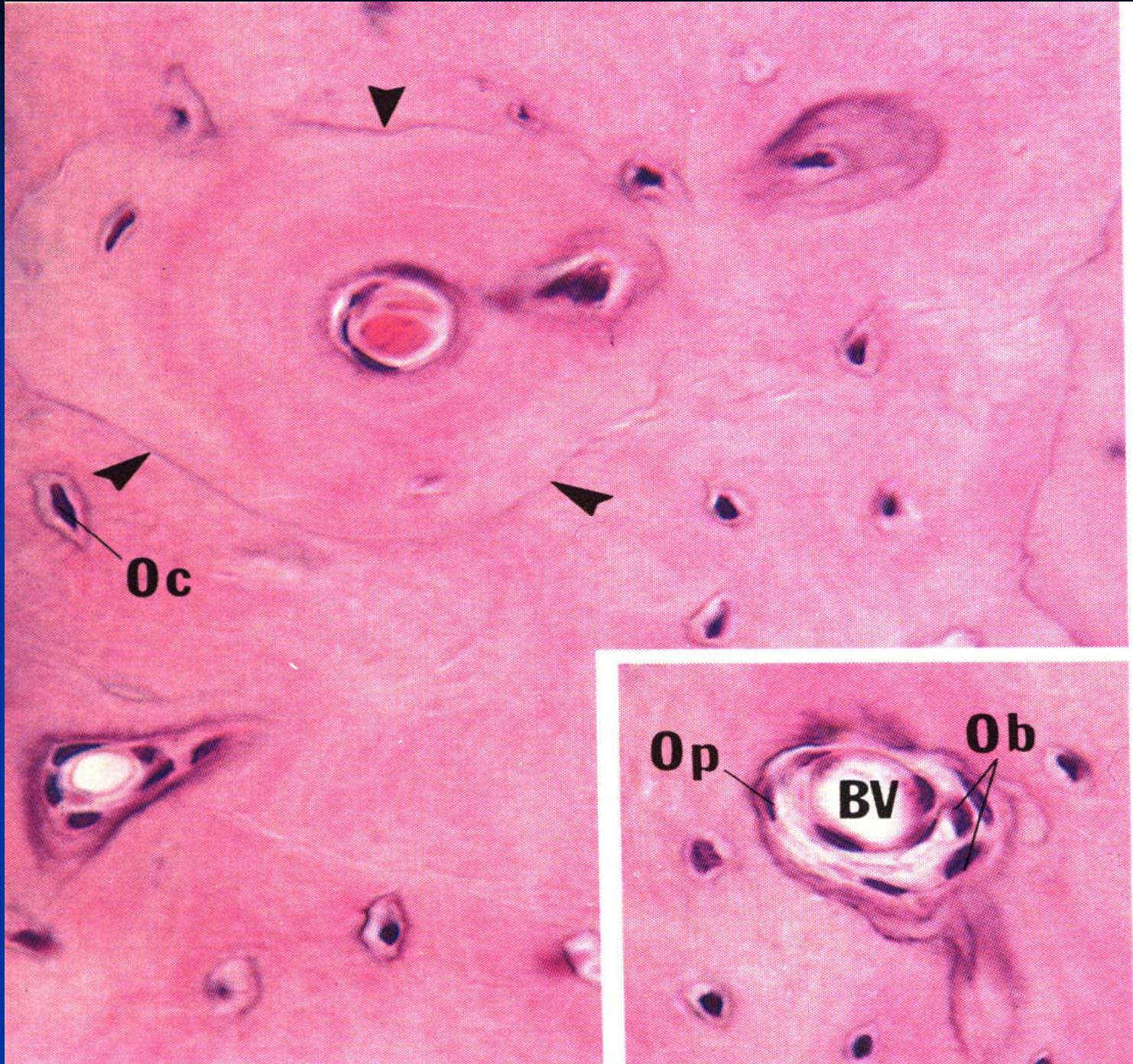
Bone

- **Compact Bone (Cortical Bone)**
- Bony lamellae are organized into 4 lamellar systems:
 - External circumferential lamellae
 - Internal circumferential lamellae
 - Interstitial lamellae
 - Osteons

Cortical Bone/Compact Bone

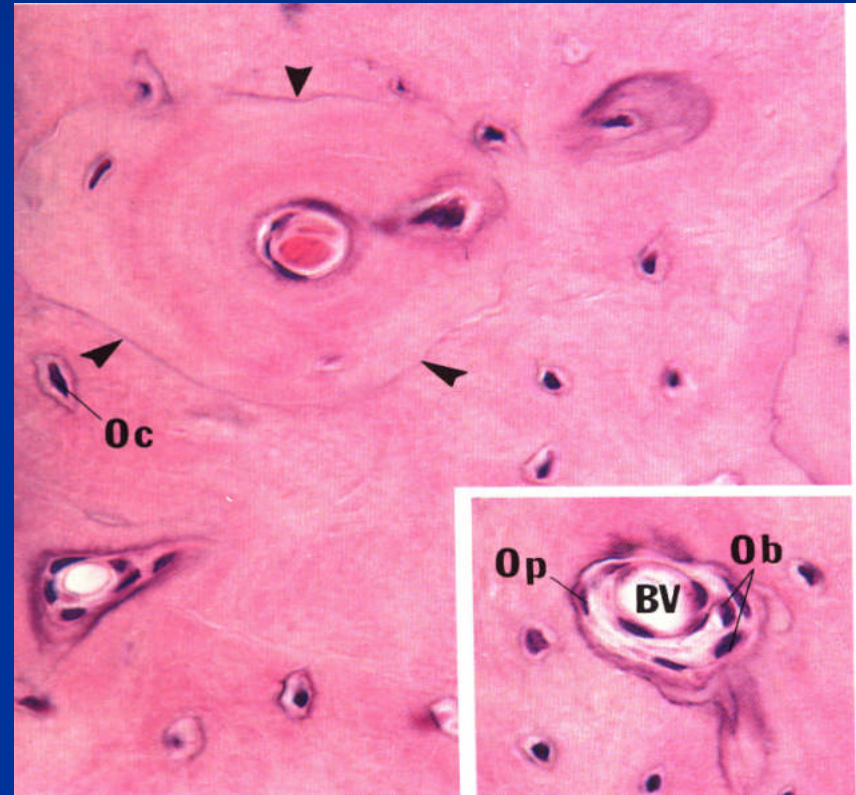
- Cortical bone is thick and needs blood vessels to distribute the nutrients to all areas and cells. The blood vessels run in the Haversian Canals (HC) and Volkmann's Canals (VC)
- The bone is oriented in a circumferential pattern around these canals.
- Os = Osteon
- L = Lamellae



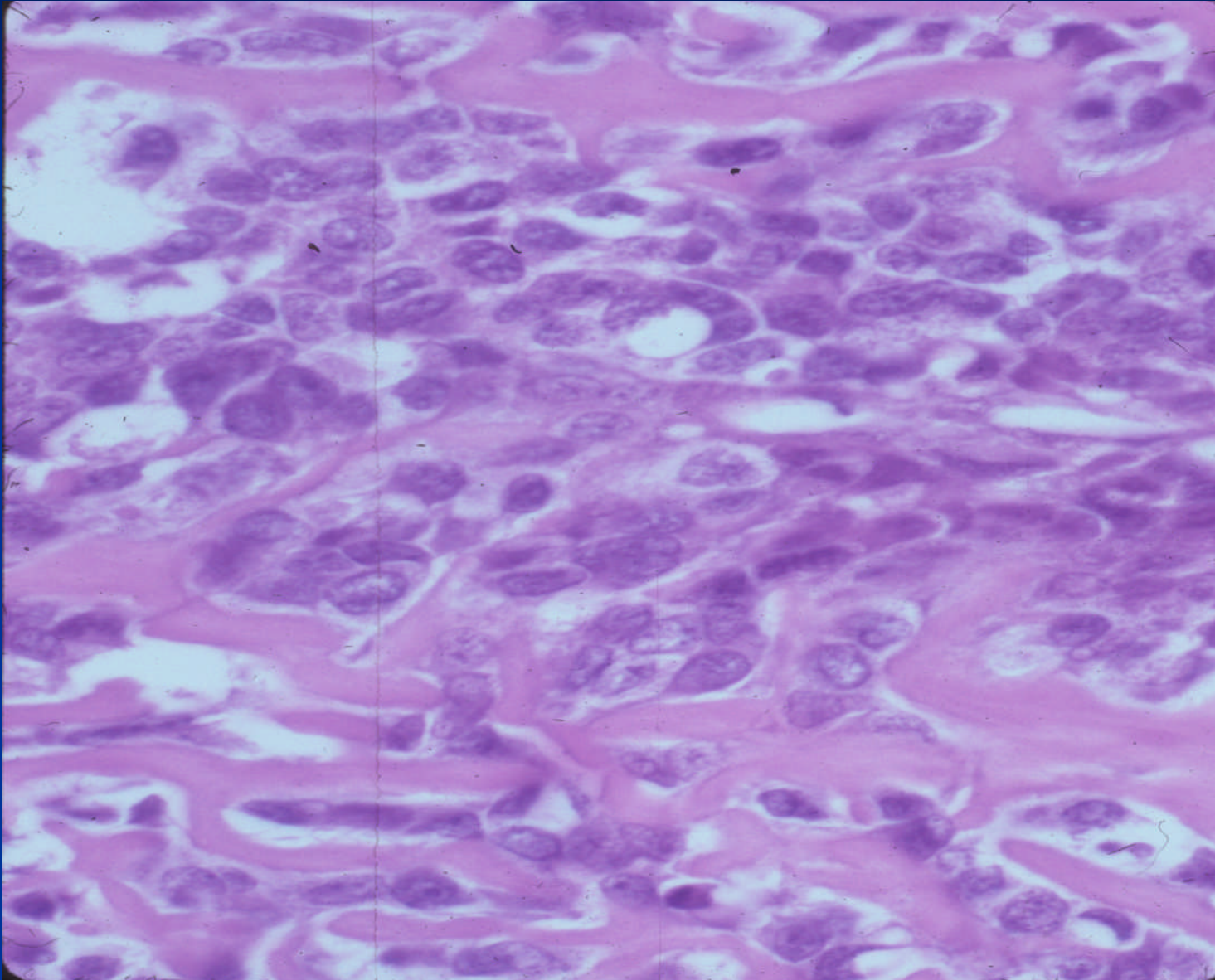


Cortical/Compact Bone

- Arrows = Cement Line
- Oc = Osteocyte
- Ob = Osteoblast
- BV = Blood Vessel

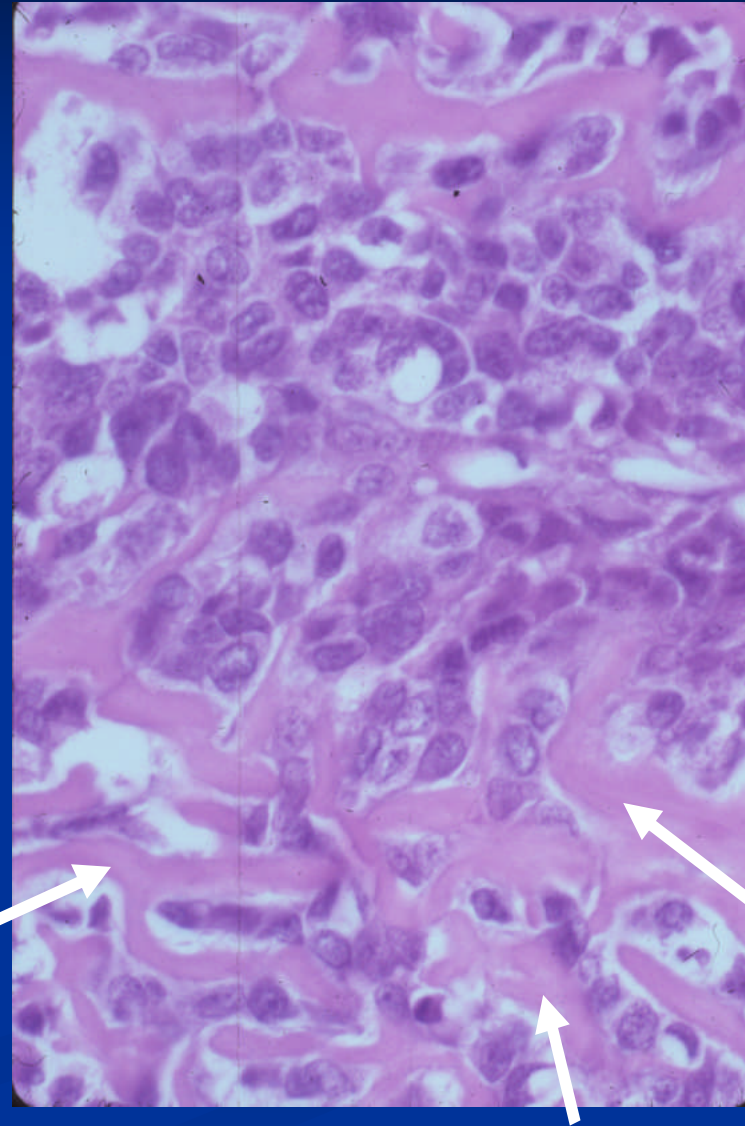


Osteosarcoma (High Grade)

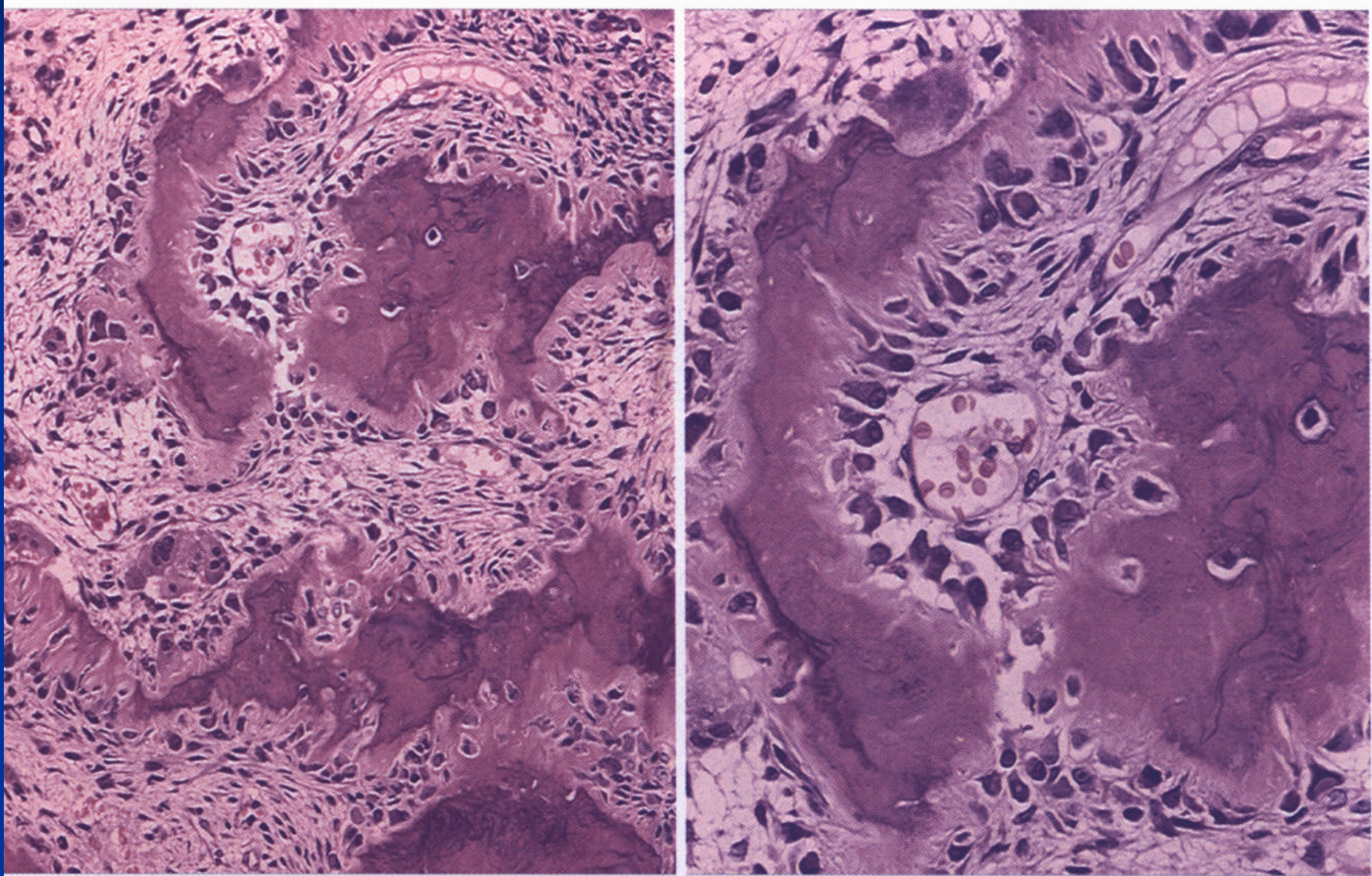


Osteosarcoma (High Grade)

- An osteosarcoma is a high grade sarcoma that produces immature bone or osteoid
- The cells are pleomorphic, and spindle shaped like a sarcoma. It is hypercellular and the cells appear crowded and disorganized
- The cells are laying down **osteoid** in a haphazard, disorganized, lace like manner (arrows; pink lace-like, amorphous substance)

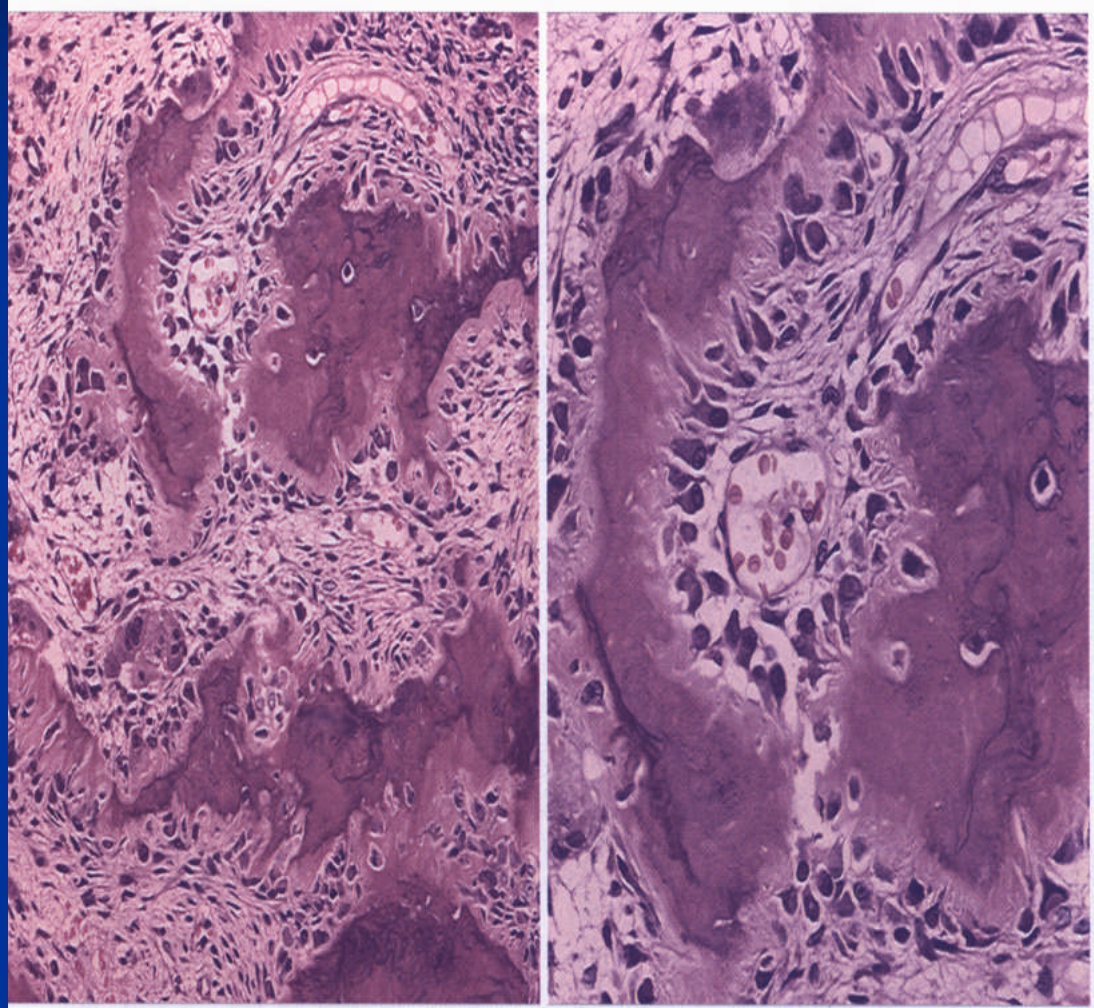


Osteoblastoma



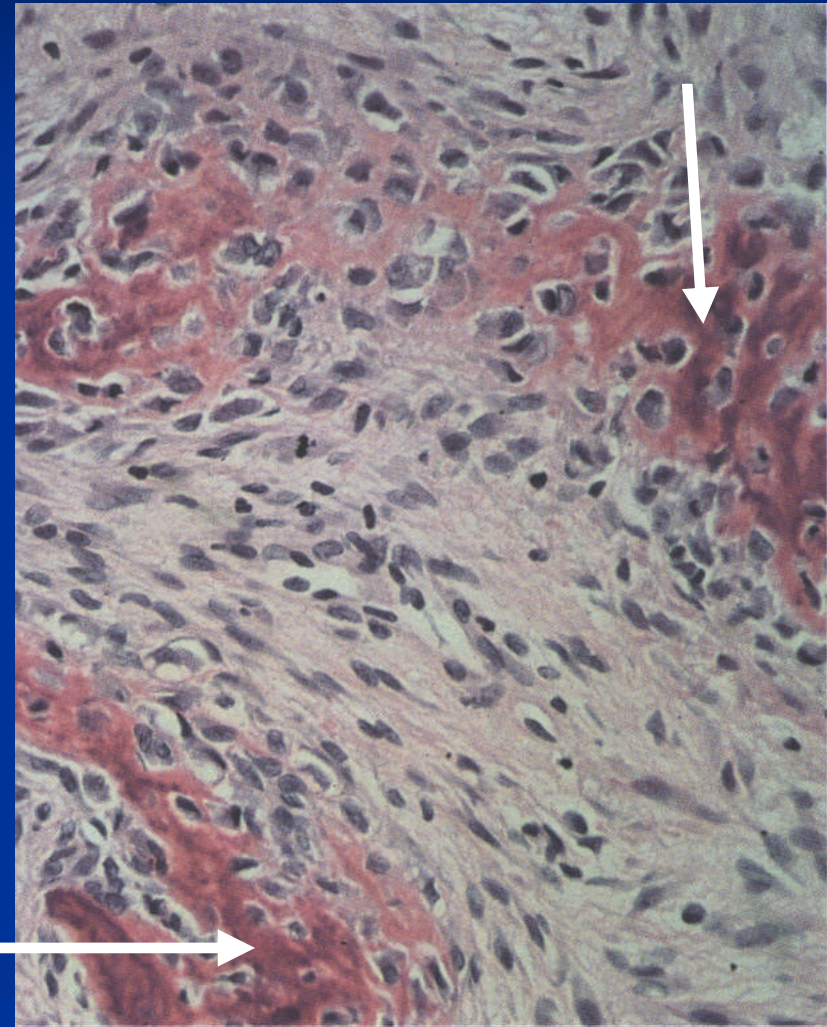
Osteoblastoma

- An osteoblastoma is a benign, bone forming tumor
- There are osteoblasts that appear plump and similar size and shape; no mitoses; no pleomorphism
- The osteoblasts are laying down bone and the bone/osteoid appears to be trying to form a shape like a normal trabecula of bone



Osteosarcoma (Low Grade)

- There are also low grade forms of osteosarcoma in which the cells are less bizarre, smaller and less pleomorphic. There are fewer mitoses. There is usually a fibrous matrix associated with a low grade osteosarcoma
- The key to diagnosis is identification of the osteoid (arrows)



Bone

- Histogenesis (Intramembranous and Endochondral)
 - Intramembranous Ossification
 - Arises in richly vascularized mesenchymal membrane
 - Mesenchymal cells differentiate into osteoblasts that elaborate bone matrix and form trabeculae
 - Trabeculae fuse and form cancellous bone
 - Remodeling yields compact bone
 - Primary or woven Bone: Newly formed bone—haphazard arrangement of collagen bundles—not as orderly as older bone
 - Woven bone is replaced via remodeling to form secondary or mature bone

Bone

■ Endochondral Ossification

- Responsible for formation of long and short bones
- Hyaline cartilage model is replaced by bone
- Invaded by periosteal bud that brings in blood vessels, mesenchymal cells and osteogenic cells
- Osteoblasts elaborate a bony matrix on calcified cartilage and forms a primary ossification center
- Secondary ossification center occurs in the epiphysi

Blood

- Erythrocyte
- Lymphocyte
- Monocyte
- Neutrophil
- Eosinophil
- Basophil
- Platelets

	Erythrocyte	Lymphocyte	Monocyte	Neutrophil	Eosinophil	Basophil	Platelets
Diameter							
Smear	7-8 μm	8-10 μm	12-15 μm	9-12 μm	10-14 μm	8-10 μm	2-4 μm
Section	6-7 μm	7-8 μm	10-12 μm	8-9 μm	9-11 μm	7-8 μm	1-3 μm
No./mm ³	5 \times 10 ⁶ -males 4.5 \times 10 ⁶ -females	1,500-2,500	200-800	3,500-7,000	150-400	50-100	250,000- 400,000
% of leu- kocytes		20-25	3-8	60-70	2-4	0.5-1	
Granules	None	Azuropilic only	Azuropilic only	Azuropilic and small specific (neutro- philic)	Azuropilic and large specific (eosino- philic)	Azuropilic and large specific (basophilic) granules (heparin and histamine)	Granu- lomere
Function	Transport of O ₂ and CO ₂	Immuno- logic response	Phagocy- tosis	Phagocy- tosis	Phagocy- tosis of antigen- antibody complexes and control of parasitic diseases.	Perhaps phagocy- tosis	Aggluti- nation and clotting
Nucleus	None	Large, round acentric	Large, kidney- shaped	Polymor- phous	Bilobed (sausage- shaped)	Large S- shaped	None

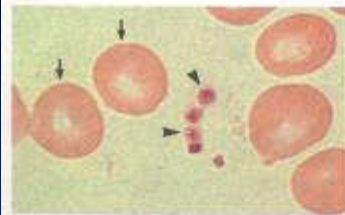


Figure 1. Red Blood Cells. Human. $\times 1325$.
Red blood cells (arrows) display a central clear region that represents the thinnest area of the biconcave disc. Note that the platelets (arrowheads) possess a central dense region, the granulomere and a peripheral light region, the hyalomere.

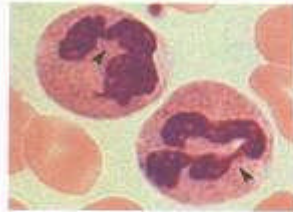


Figure 2. Neutrophils. Human. $\times 1325$.
Neutrophils display a somewhat granular cytoplasm and lobulated (arrowheads) nuclei.

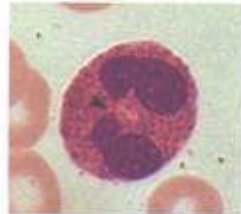


Figure 3. Eosinophils. Human. $\times 1325$.
Eosinophils are recognized by their large pink granules and their sausage-shaped nucleus. Observe the slender connecting link (arrowhead) between the two lobes of the nucleus.

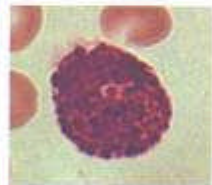


Figure 4. Basophils. Human. $\times 1325$.
Basophils are characterized by their dense, dark, large granules.

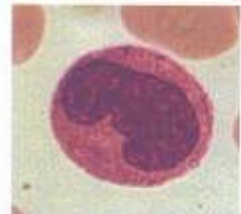
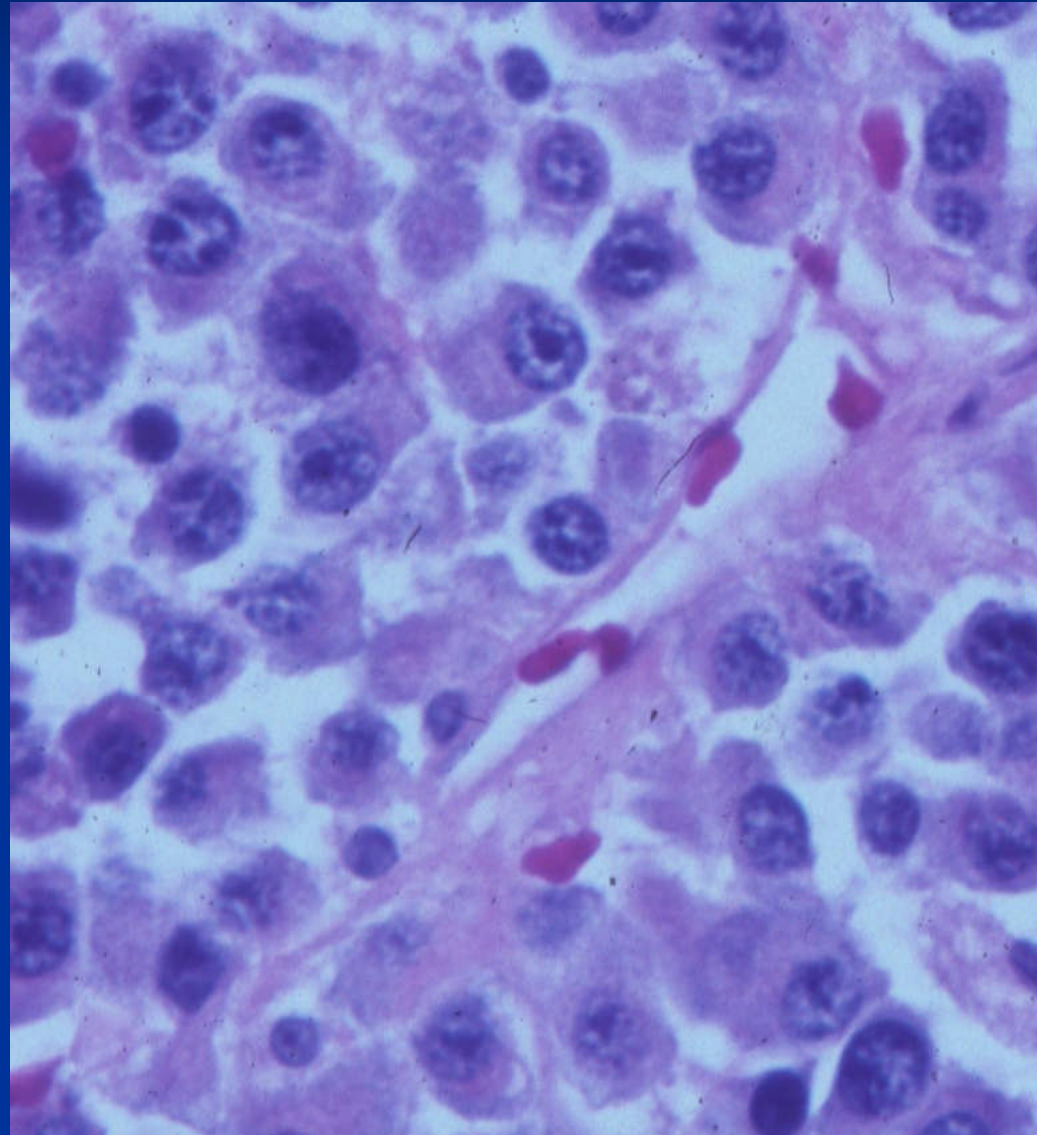


Figure 5. Monocytes. Human. $\times 1325$.
Monocytes are characterized by their large size, acentric, kidney-shaped nucleus, and lack of specific granules.

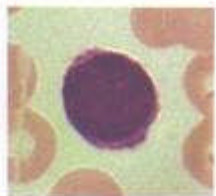

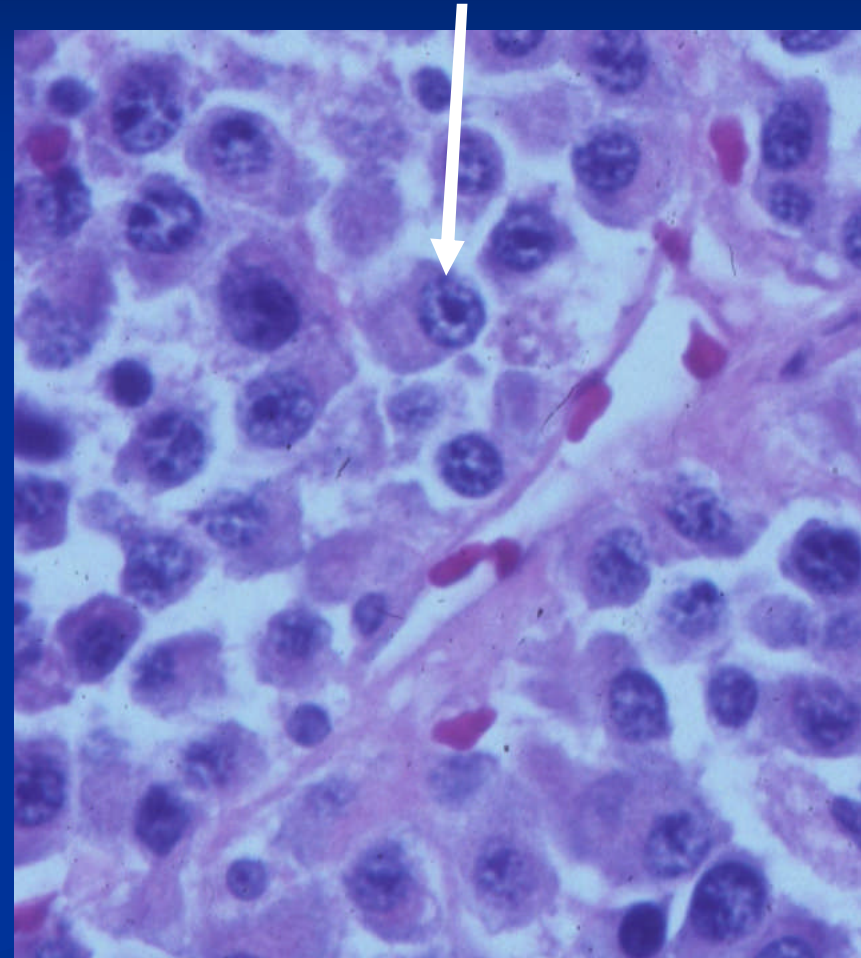
Figure 6. Lymphocytes. Human. $\times 1325$.
Lymphocytes are small cells that possess a single large, acentrically located nucleus, and a narrow rim of light blue cytoplasm.

Plasma Cells

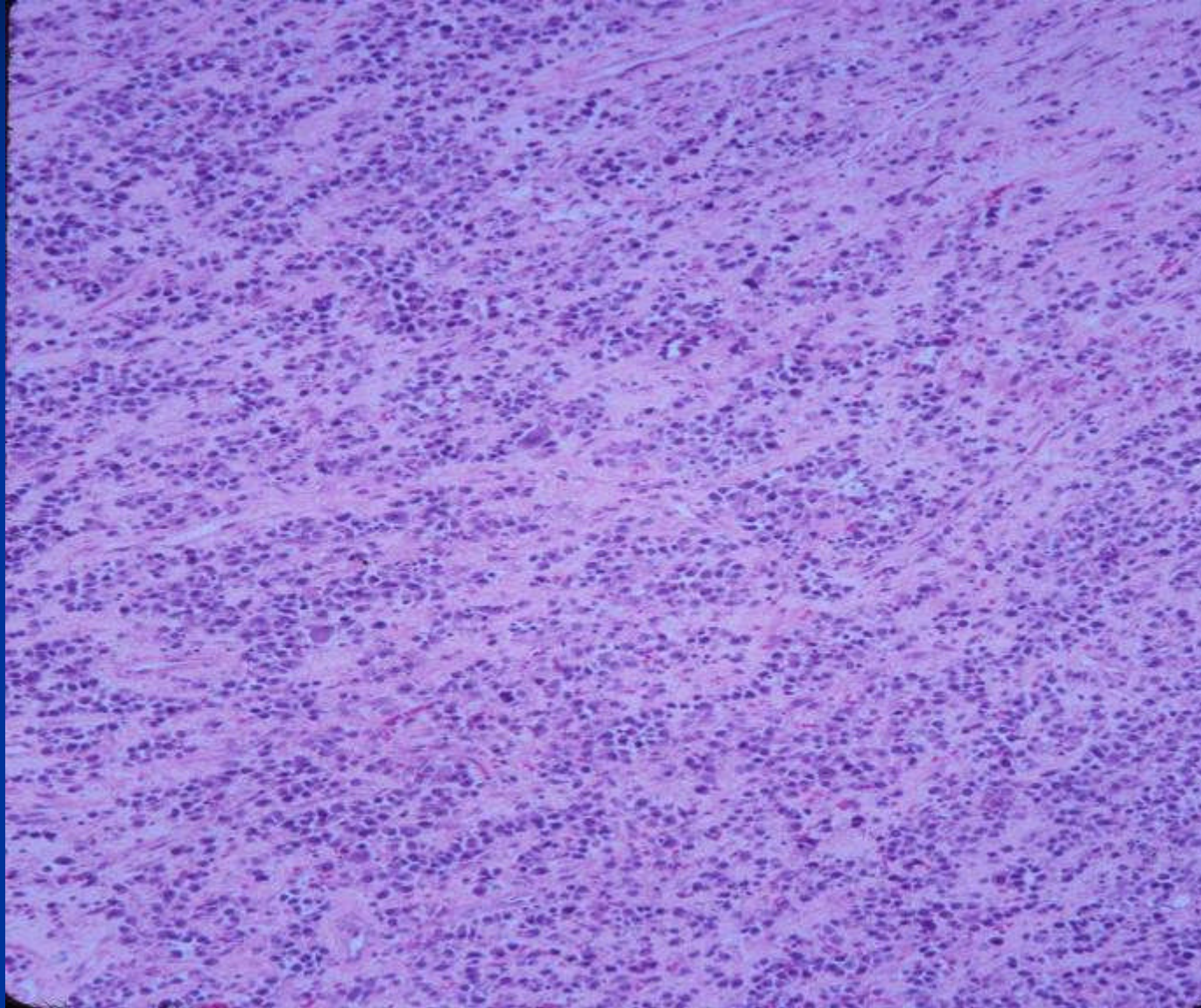


Plasma Cells

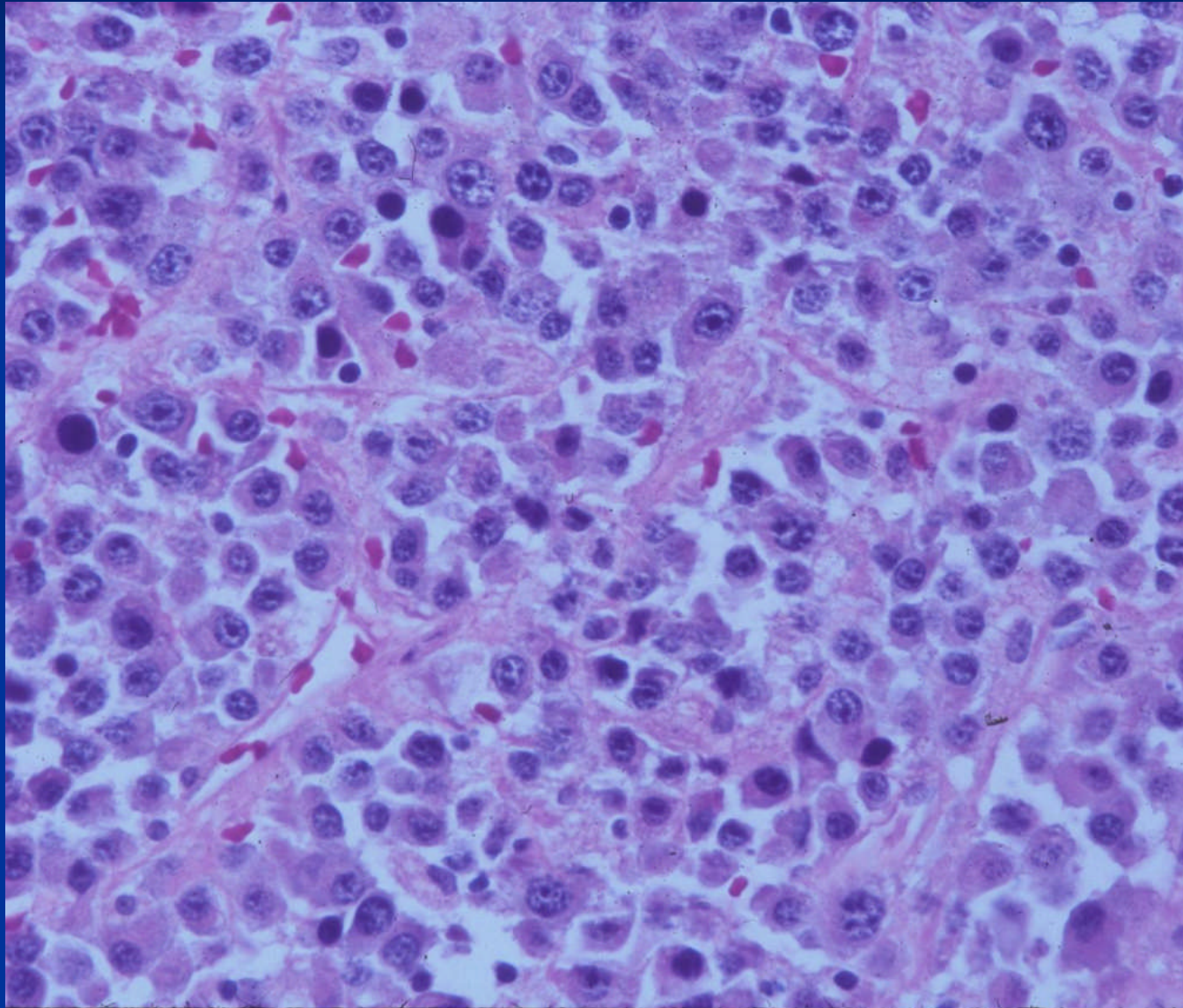
- **Characteristics:**
- Eccentric Nucleus
- Perinucler Halo
- Plump Cytoplasm
(making antibodies)
- Clockface nucleus



Myeloma (Plasma Cell Cancer)

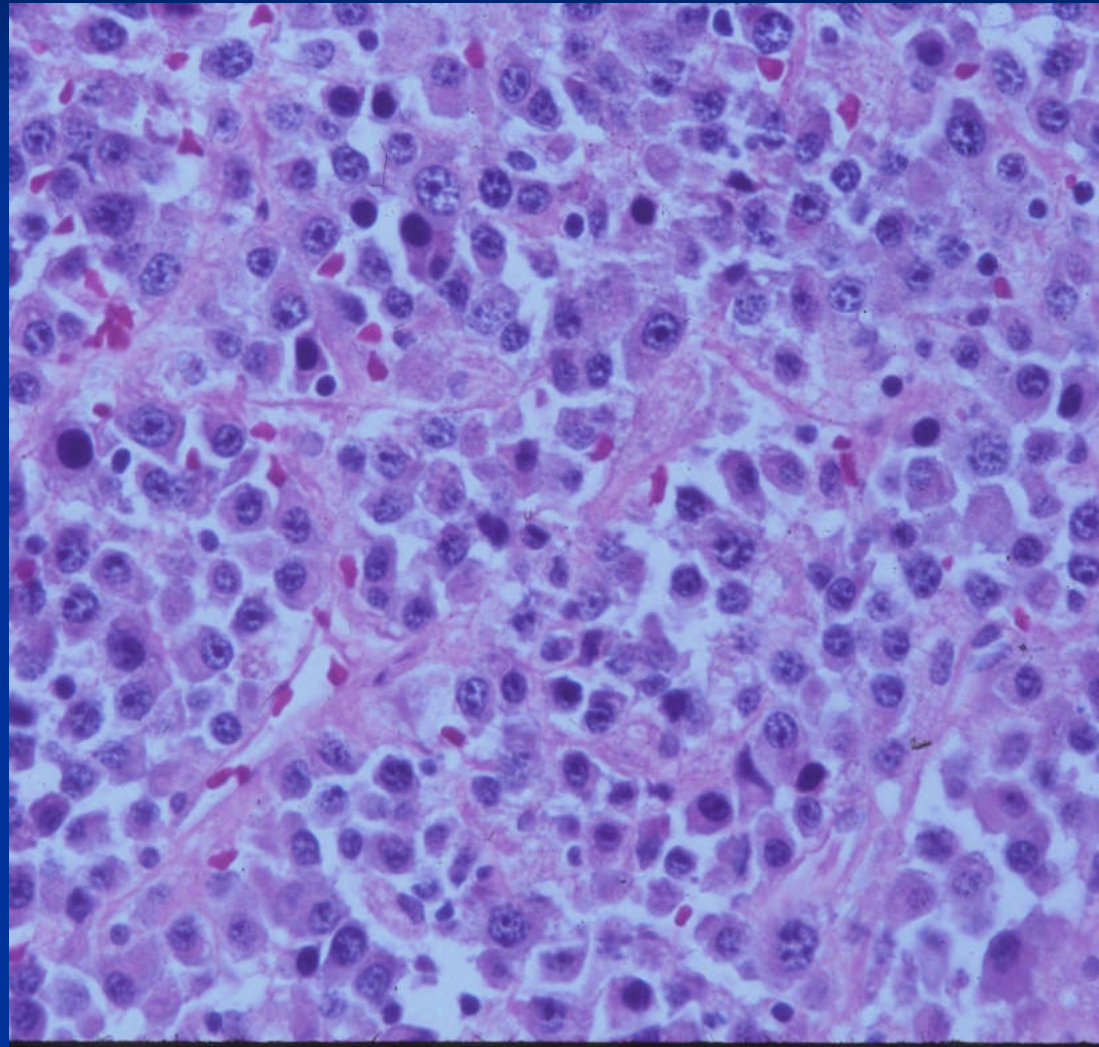


Myeloma



Myeloma


- Composed of plasma cells
- Cells have similar characteristics to normal plasma cells



Muscle


- Smooth Muscle
- Skeletal Muscle
- Cardiac Muscle

Skeletal Muscle

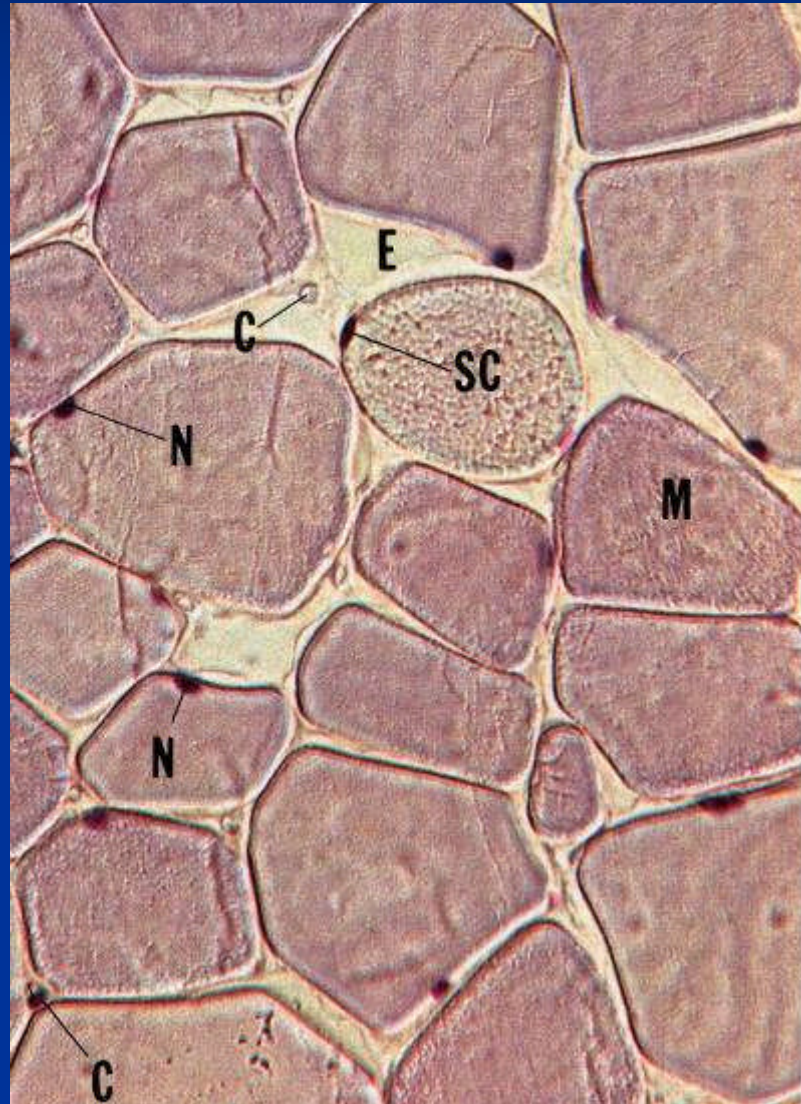


Skeletal Muscle

- Skeletal muscle has striations that consist of the actin and myosin filaments or contractile elements
- The nucleus is cigar shaped and sit eccentrically within the cell
- The majority of the cell consists of the contractile elements

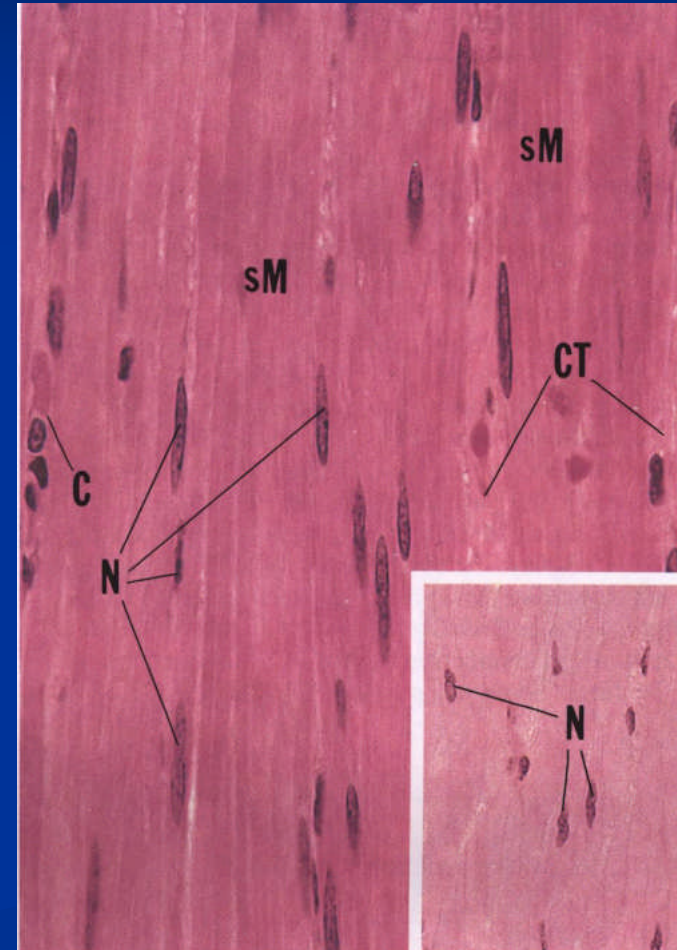


Skeletal Muscle—Cross Section

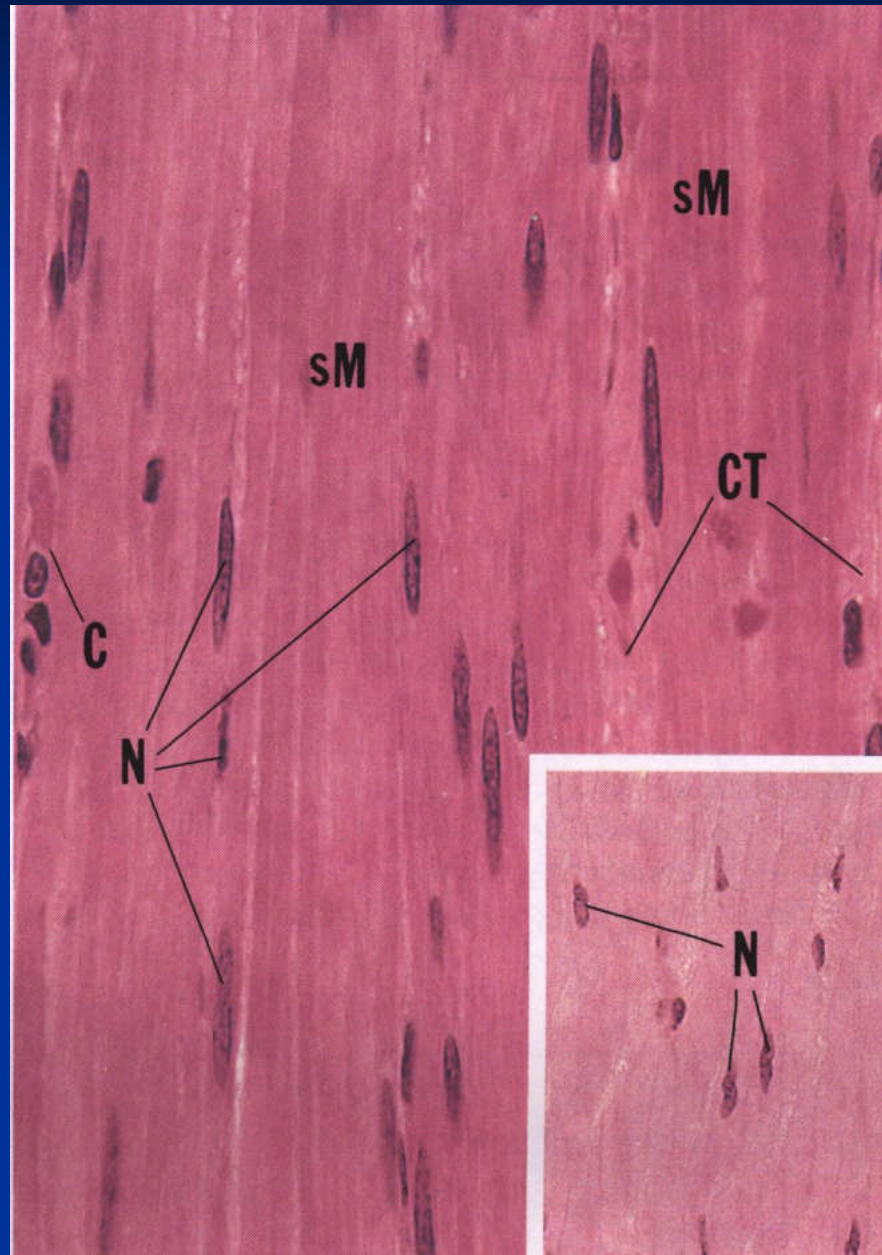


Smooth Muscle--Longitudinal

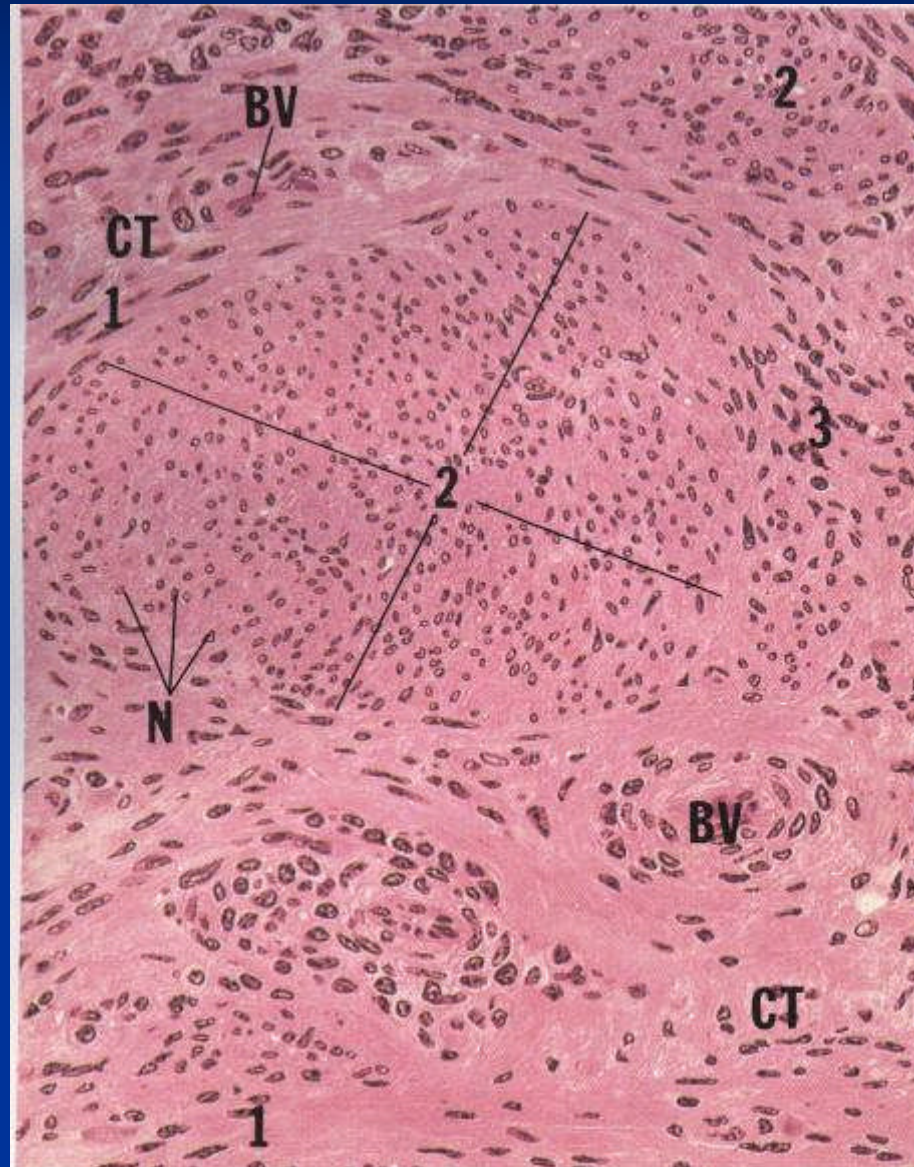
- Smooth muscle exists in the organs and blood vessels and is responsible for the contractile activities of these structures. For instance, in the digestive tract, it is responsible for propelling food through the tract
- The nuclei are long and slender/cigar shaped
- The nuclei of some of the cells have a cork screw appearance indicating that they were actively contracting



Smooth Muscle

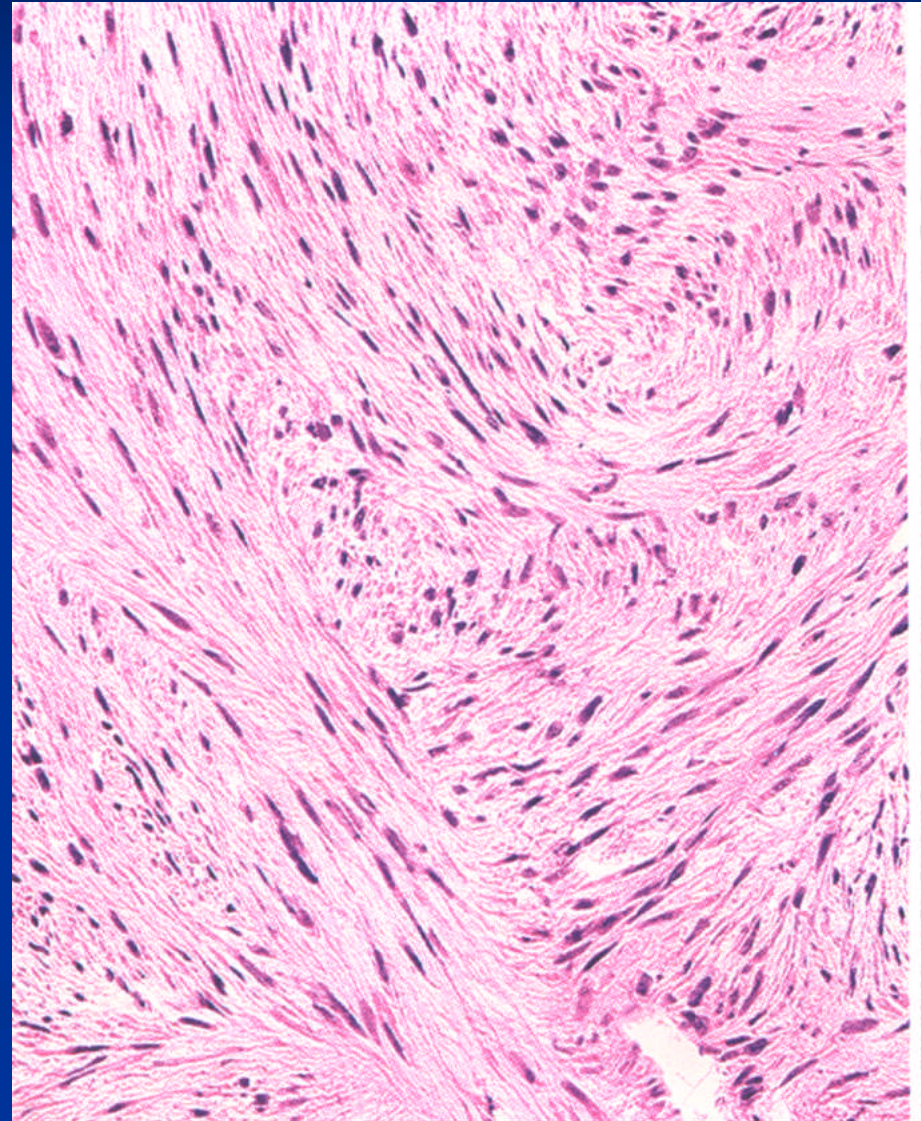


Smooth Muscle—Cross Section



Leiomyosarcoma

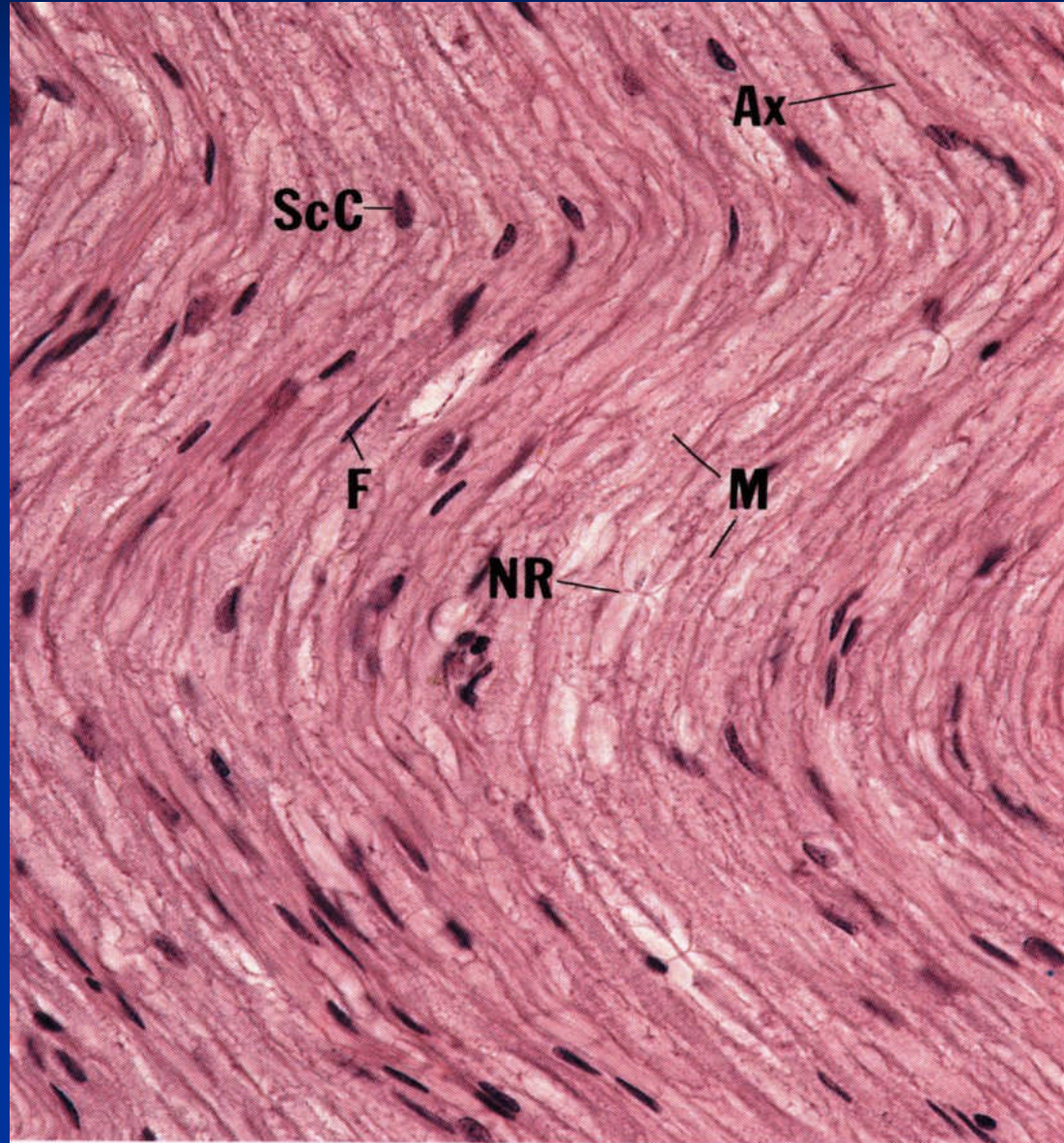
- A leiomyosarcoma is a sarcoma (cancer) of smooth muscle origin
- This is a very well differentiated example in which the long spindled cells and nuclei are apparent
- Often, it is only possible to tell that the tumor is of smooth muscle origin by performing specific immunochemical stains that identify the presence of smooth muscle actin



Nervous Tissue

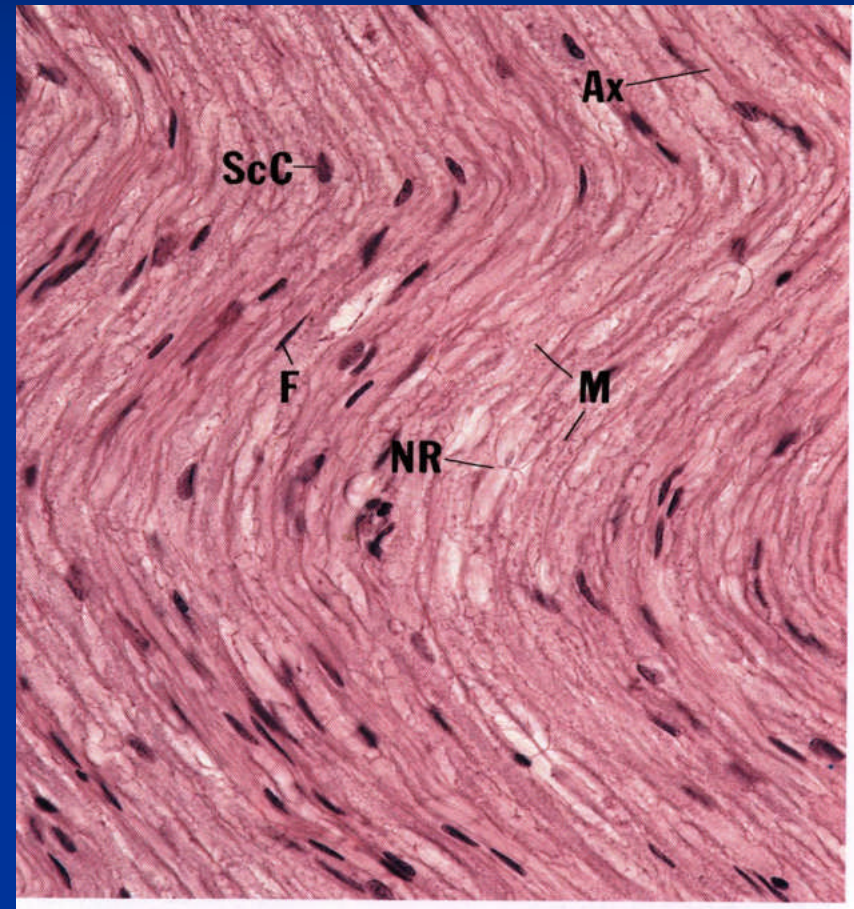
- Peripheral Nerves
- Sympathetic Ganglia

Peripheral Nerve

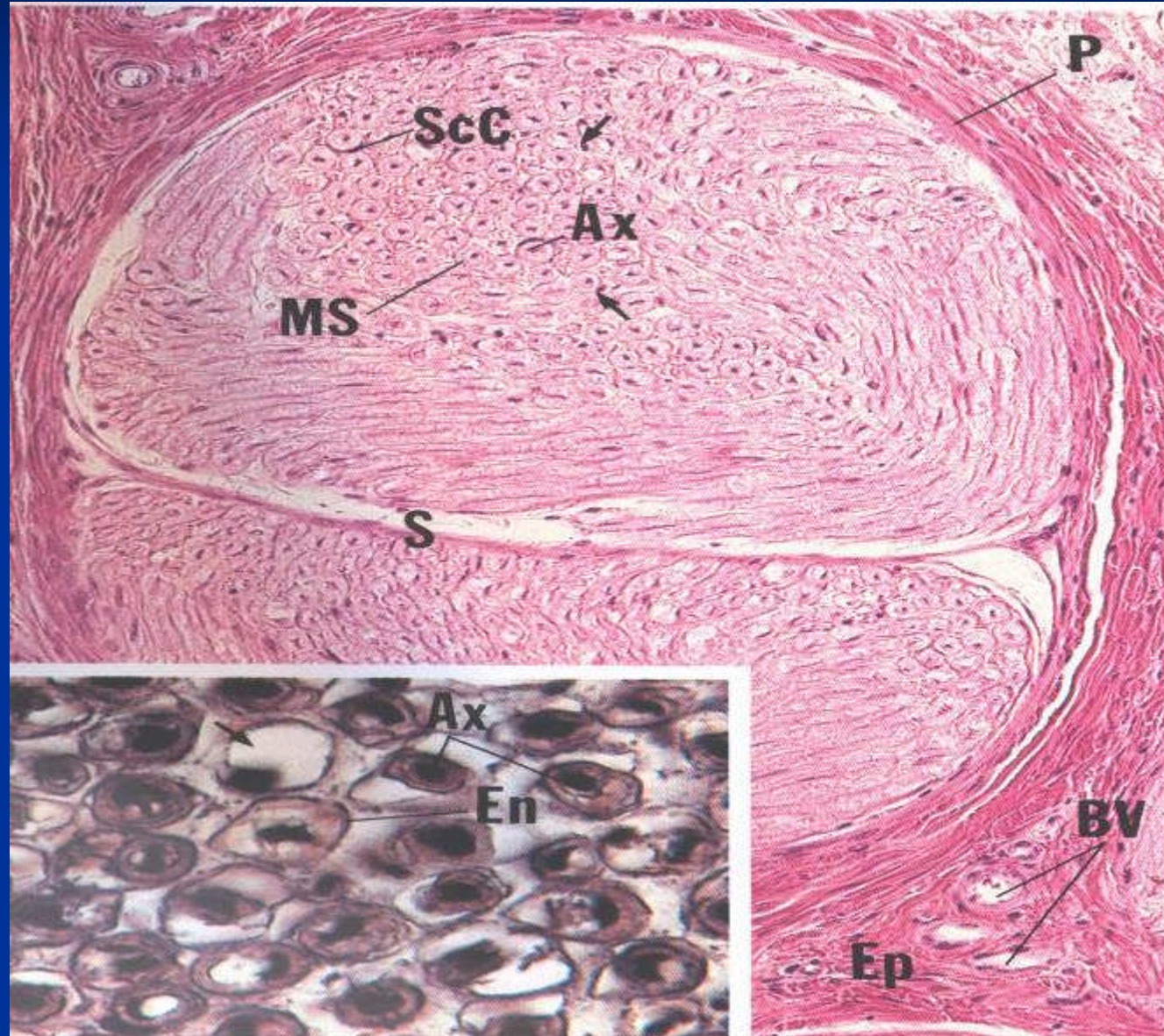


Peripheral Nerve

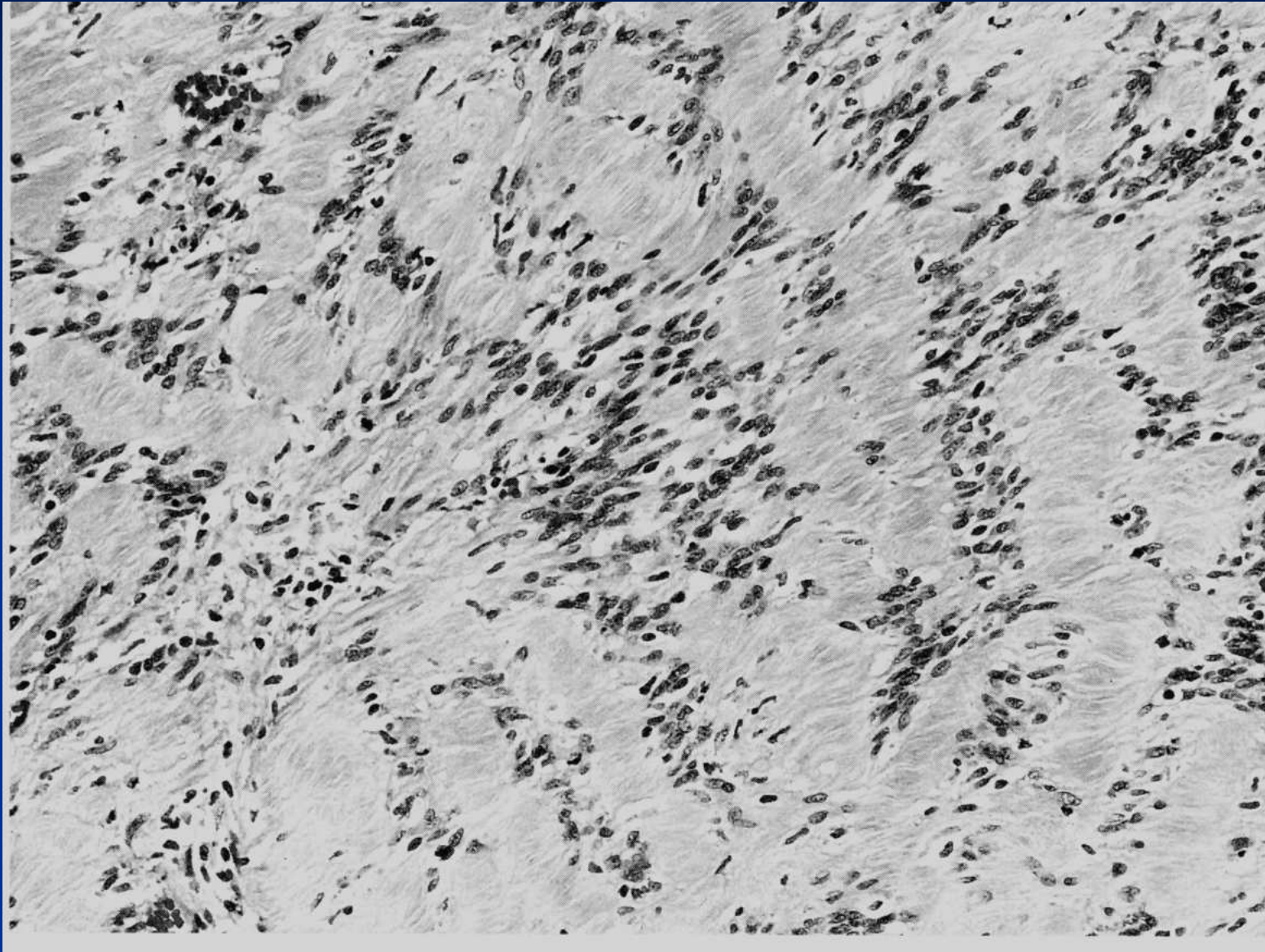
- A peripheral nerve consists of axons (Ax) that are surrounded by schwann cells (ScC). The nuclei that are seen are the nuclei of the schwann cells. The schwann cells provide an insulating layer (myelin; M) around the axon so that the conductivity through the nerve is rapid
- The schwann cells have a clear to light pink cytoplasm
- NR = Node of Ranvier
- MS = Myelin Sheath
- P = Perineurium



Peripheral Nerve—Cross section

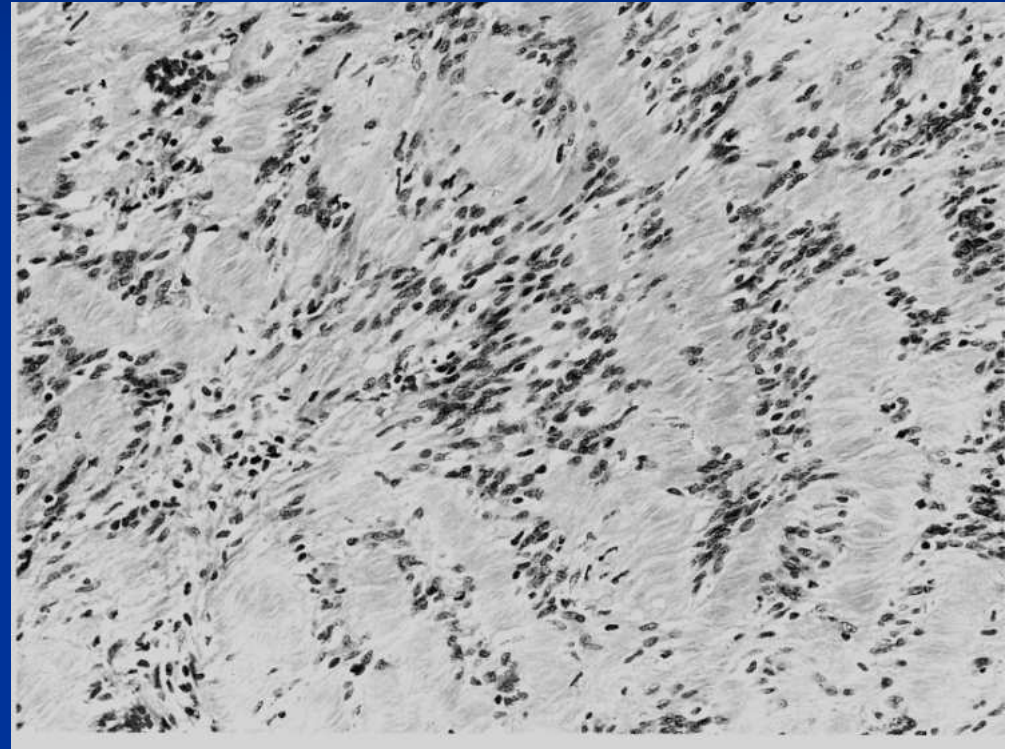


Schwannoma



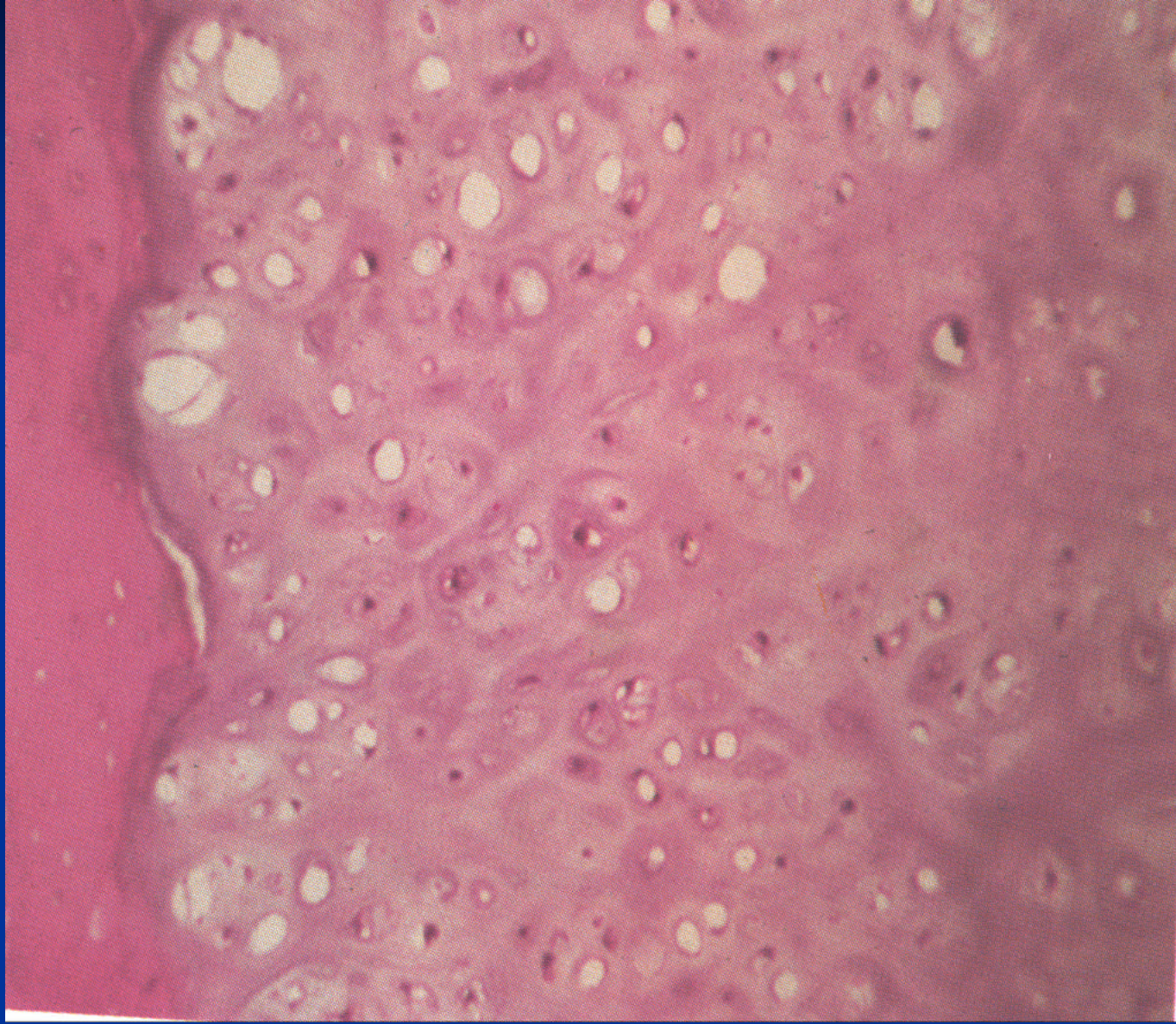
Schwannoma

- A schwannoma is a benign tumor that arises from a nerve. It arises from the nerve sheath or coating around the nerve.

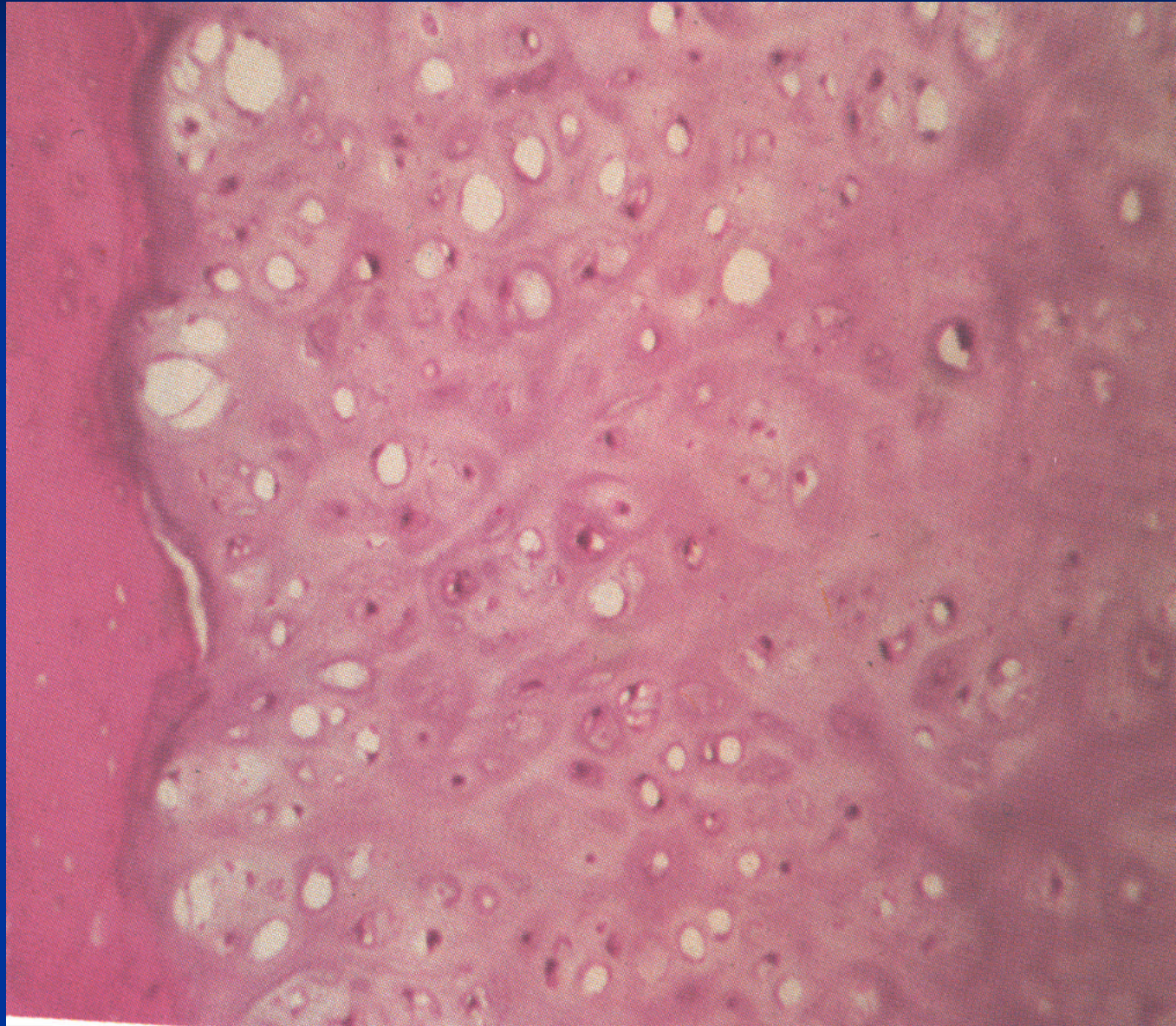


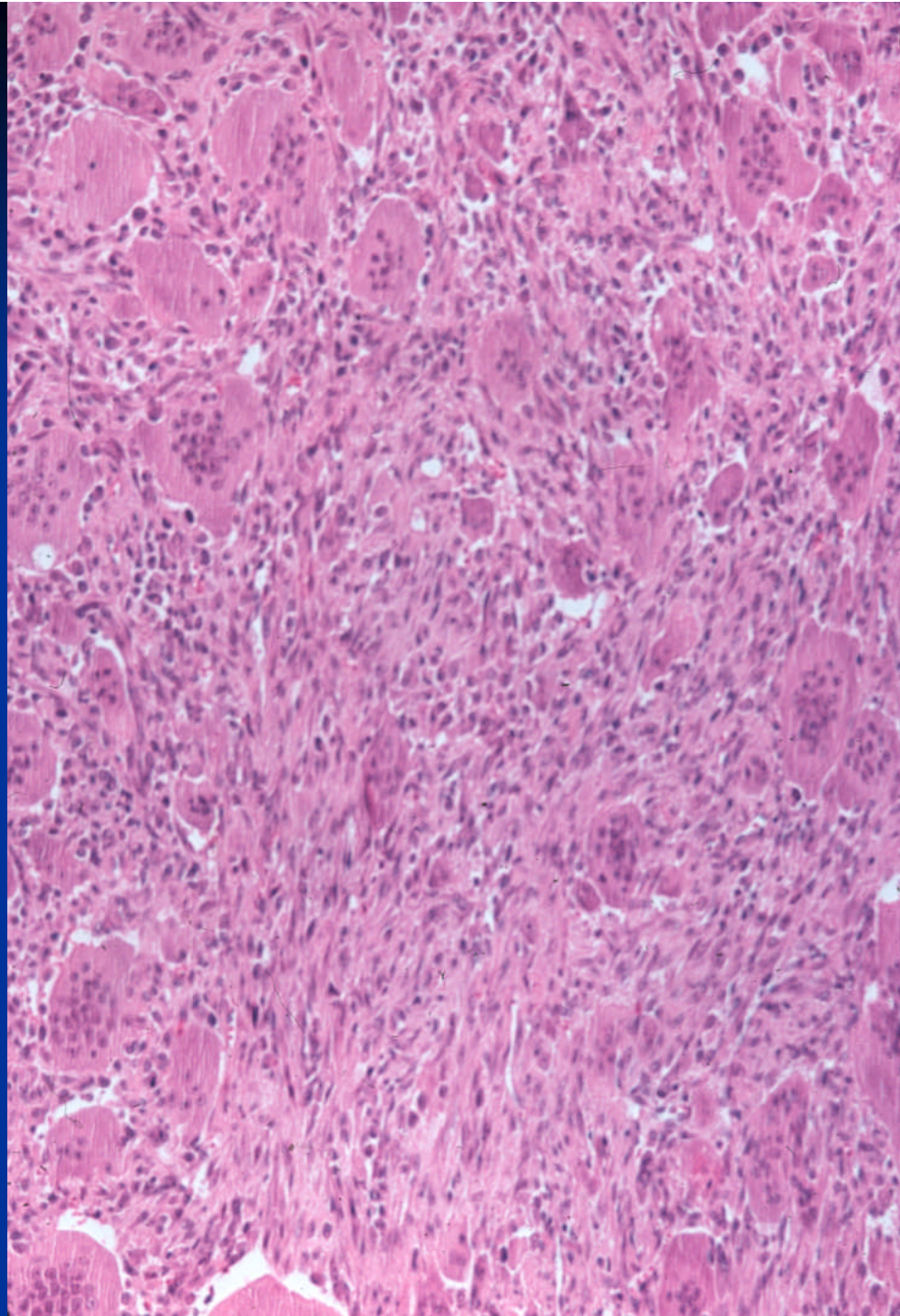
Unknown Examples

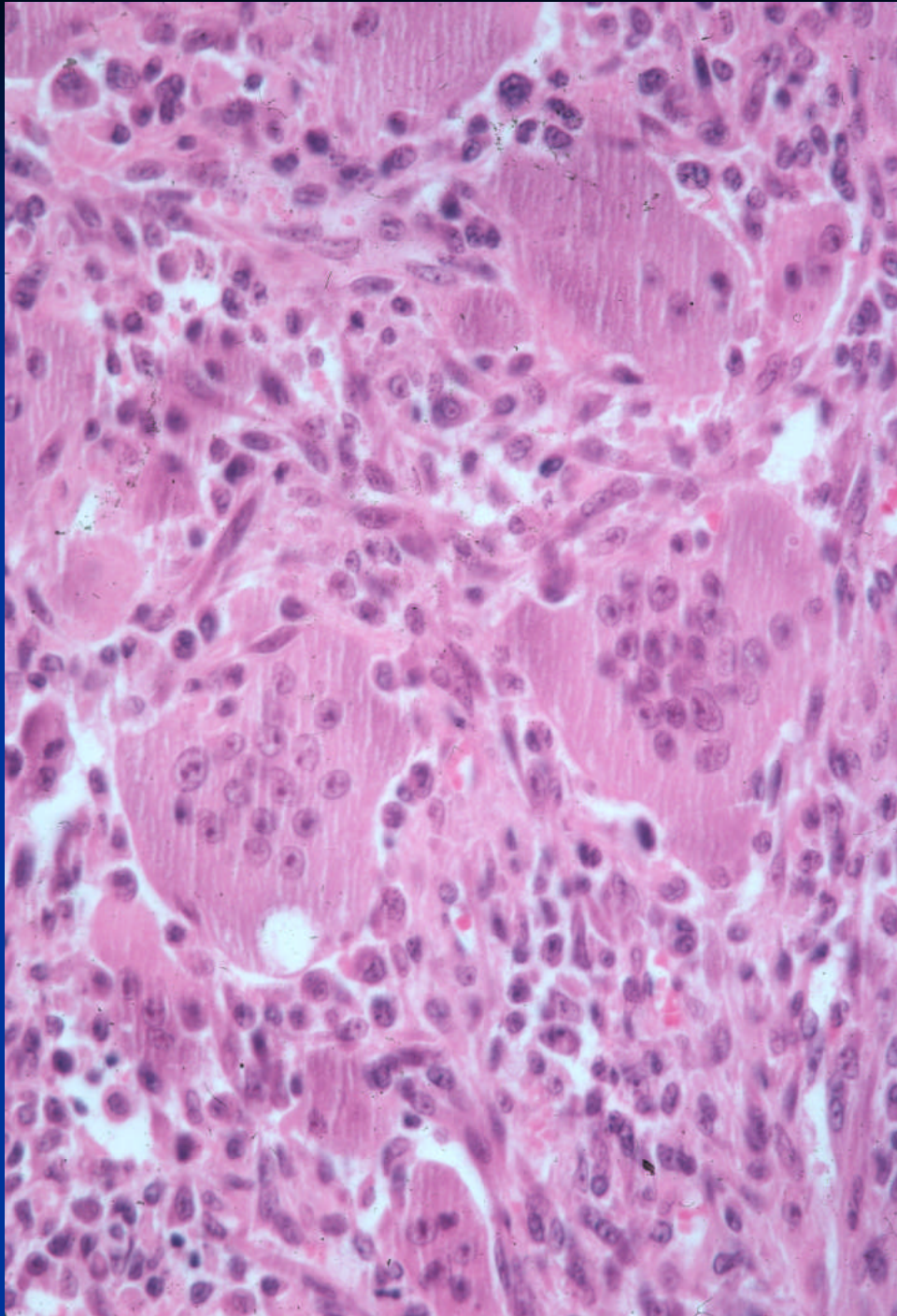
- The following slides demonstrate some common musculoskeletal neoplasms. First you are given an unknown and the slide that follows gives the diagnosis.
- Please first think about what broad category the tumor fits into (bone producing, cartilage, fibrous, nervous, small round blue cell, giant cell, vascular tumor, etc) and then whether it appears benign or malignant. This is a good approach for determining or narrowing the diagnosis.



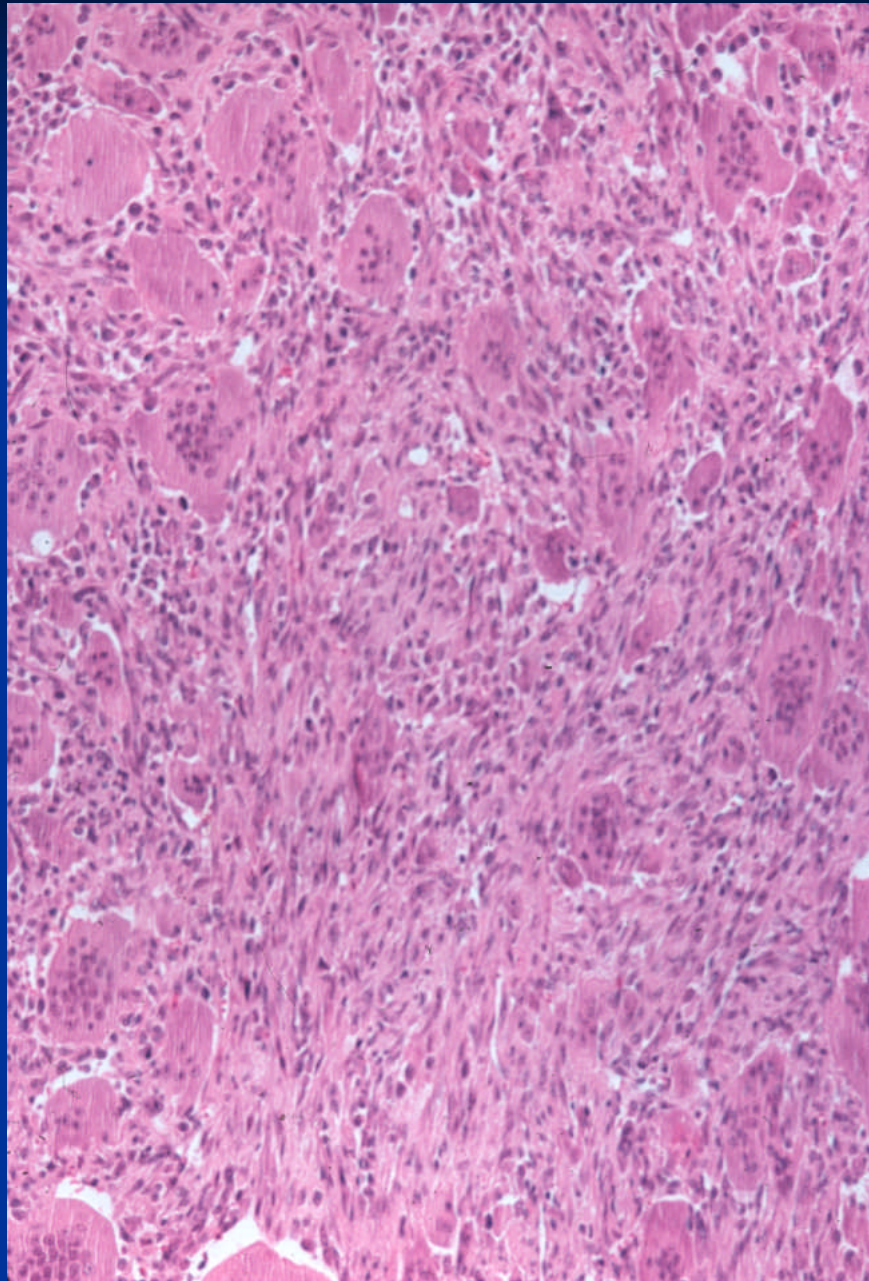
Chondroma



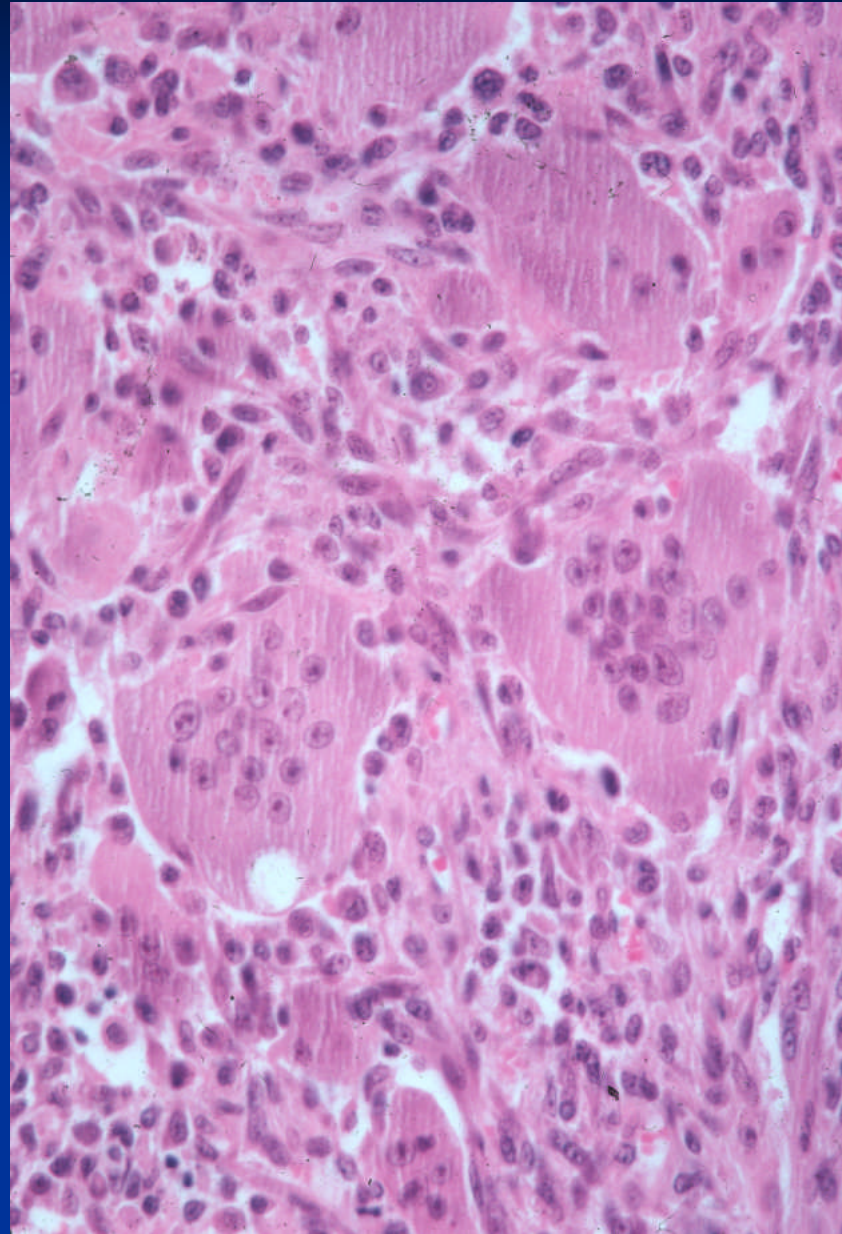


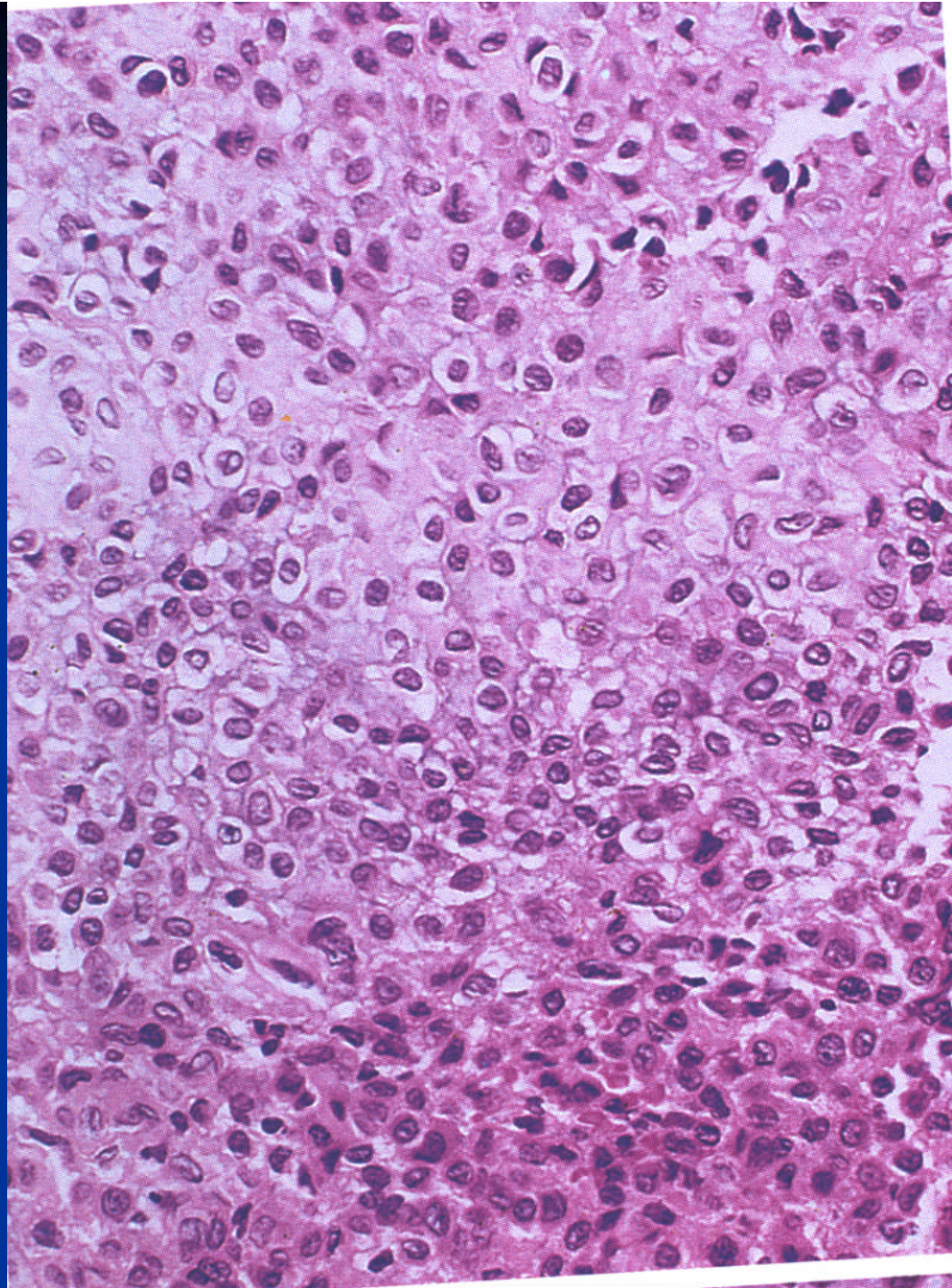


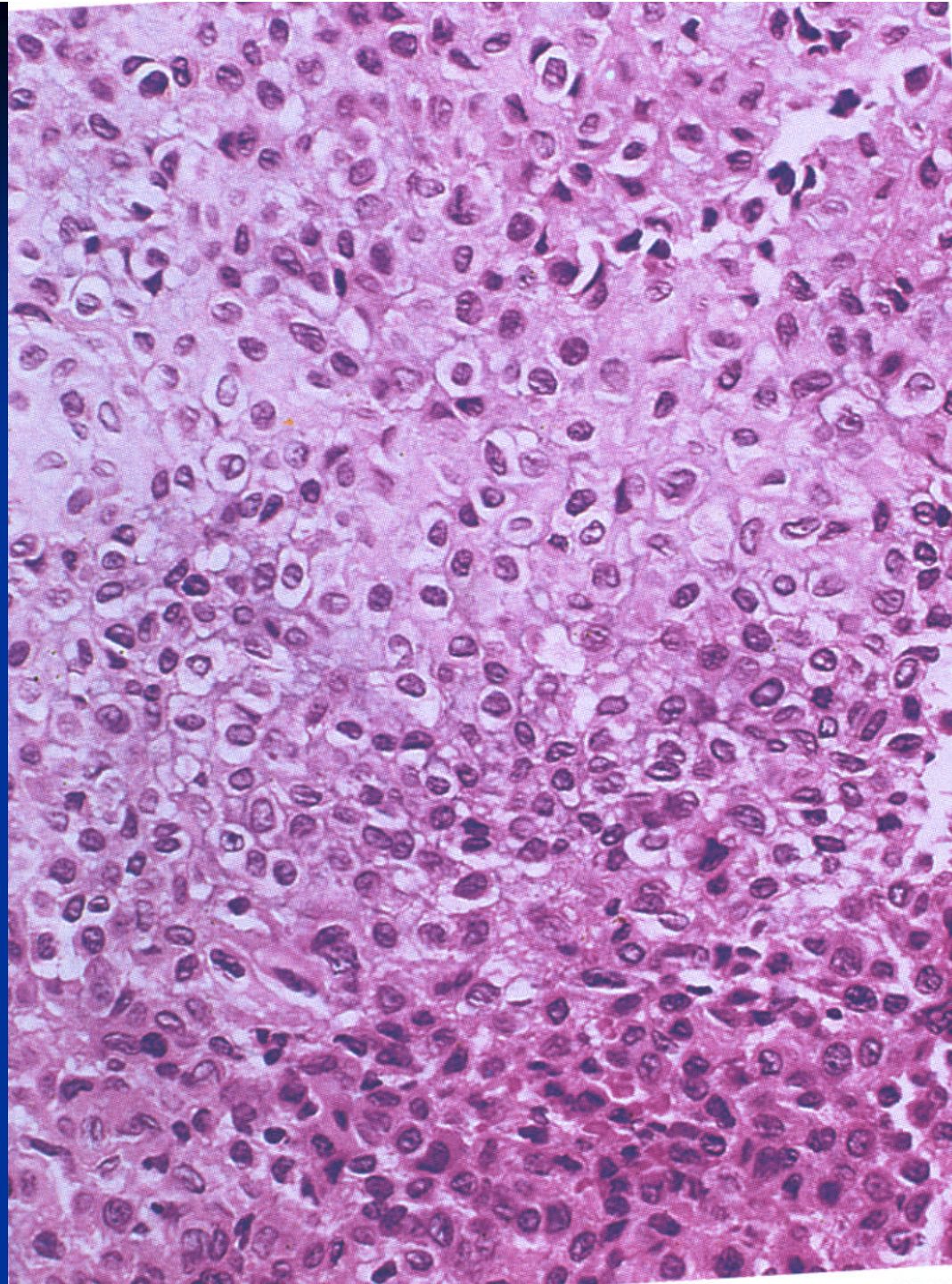
Giant Cell Tumor



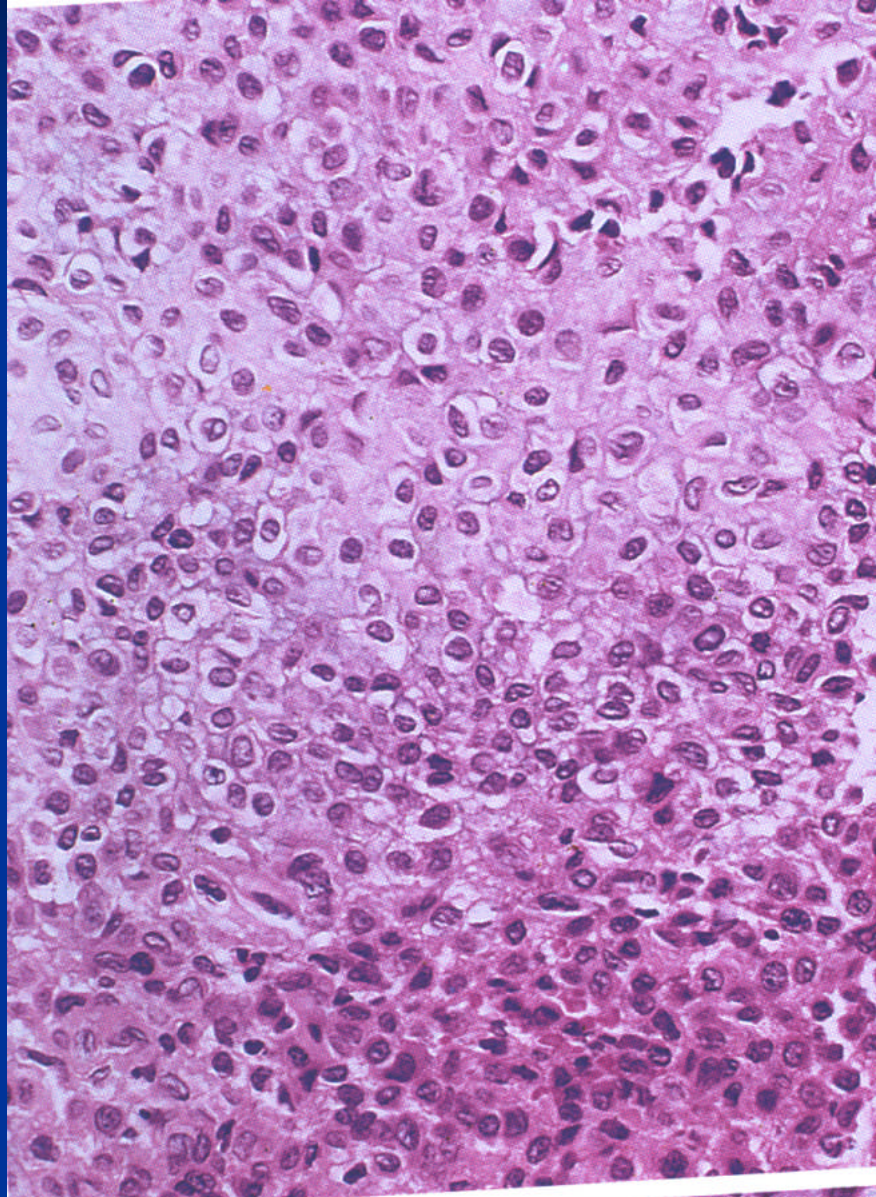
Giant Cell Tumor

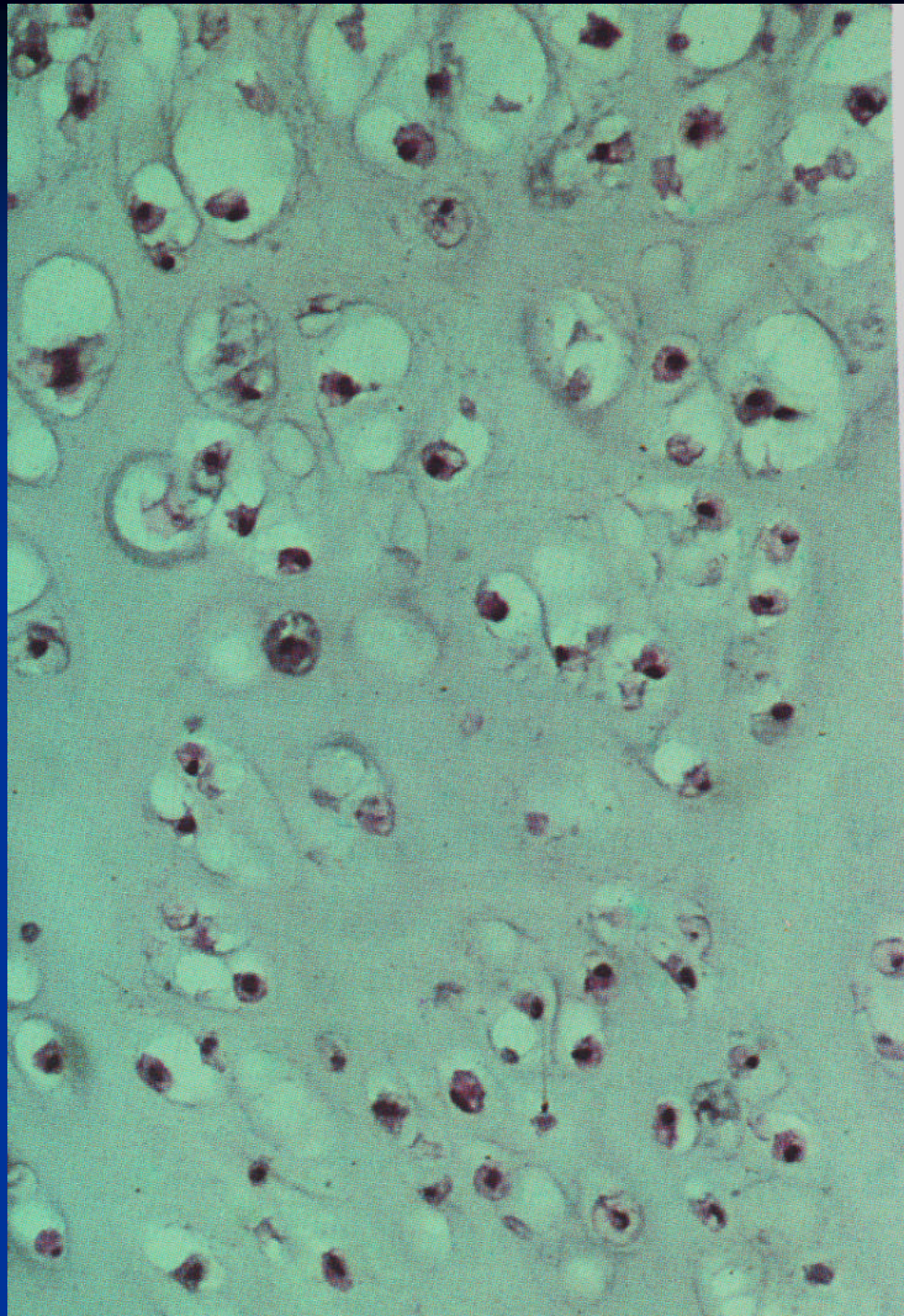




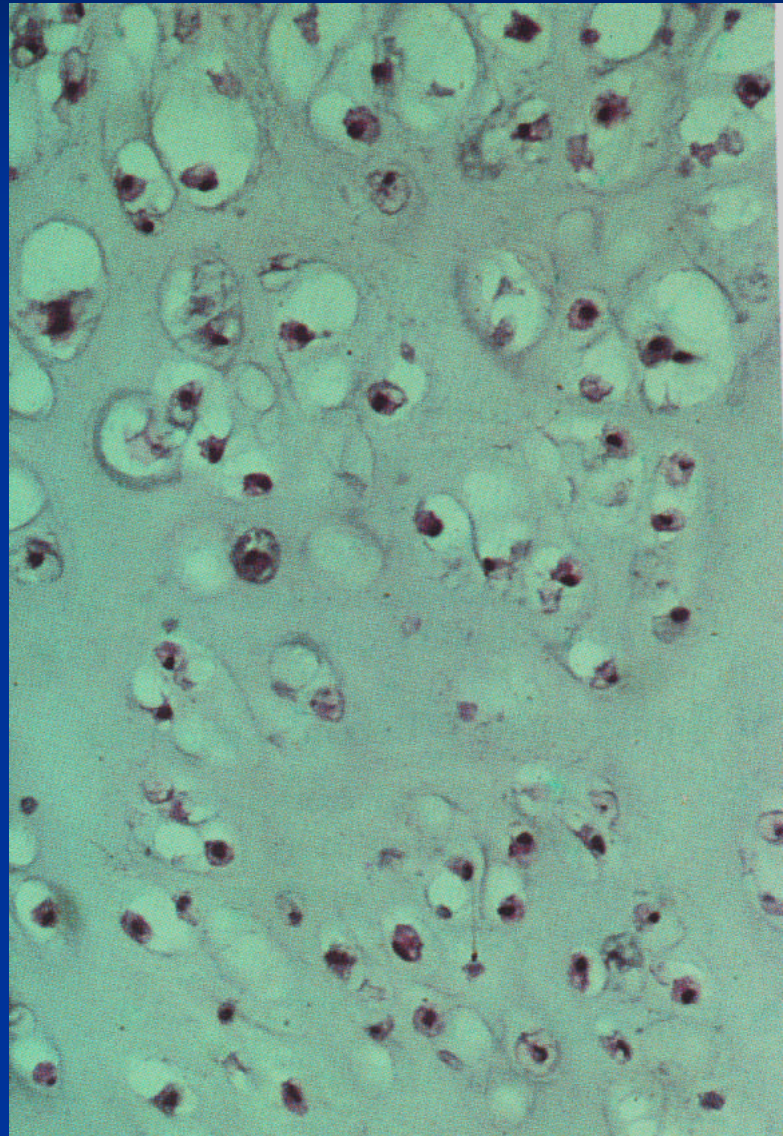


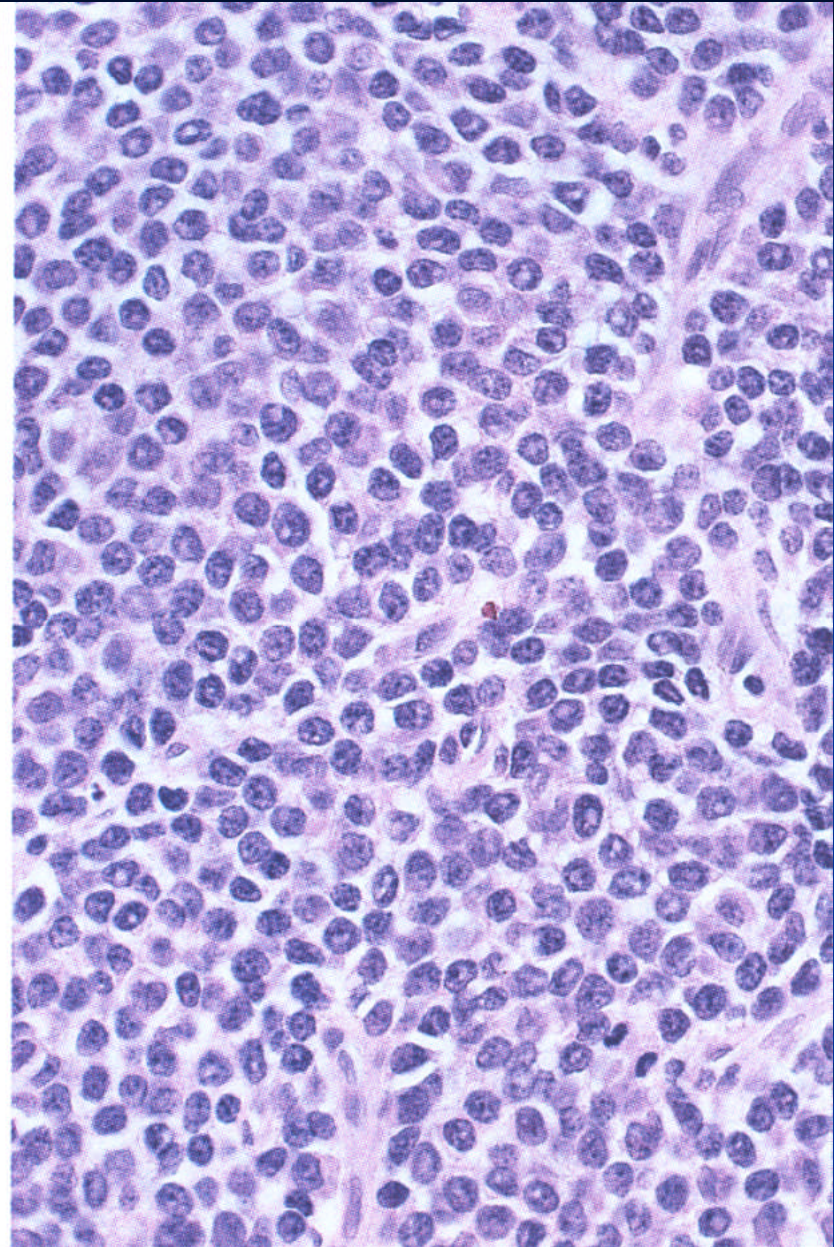
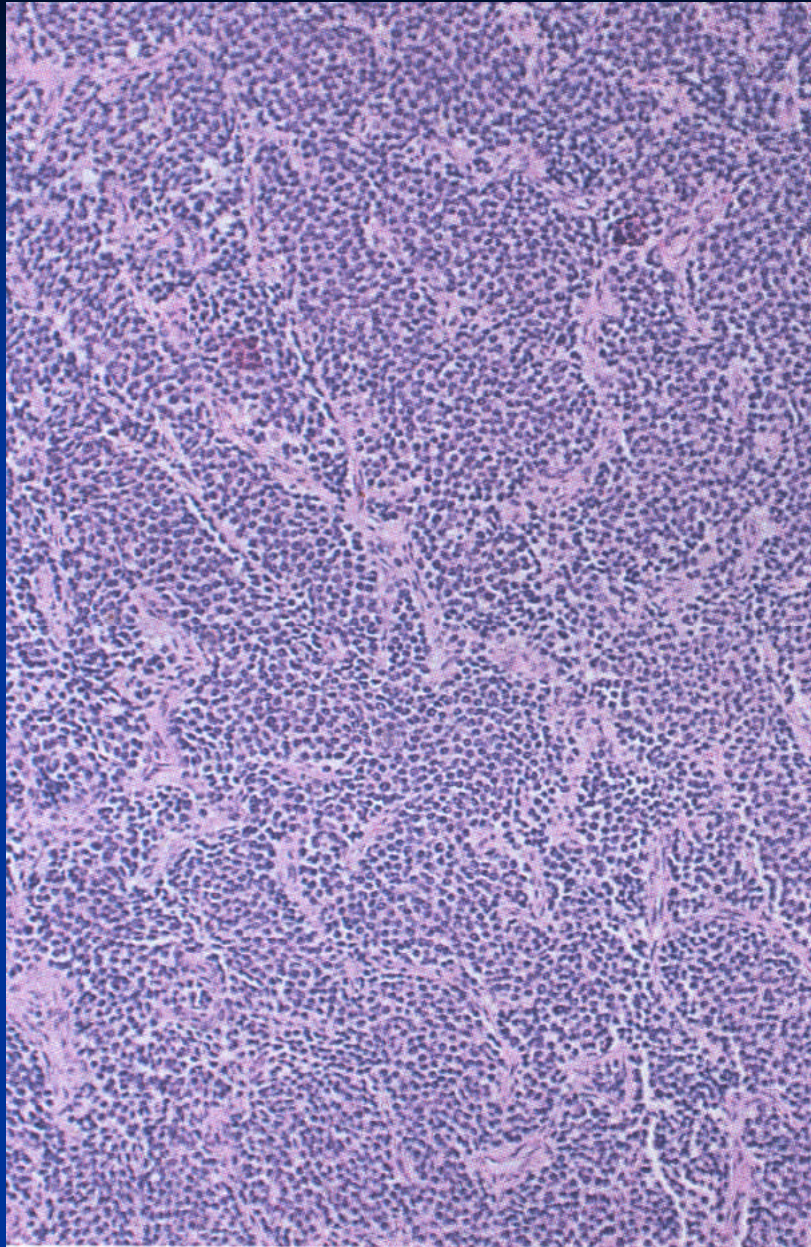
Chondroblastoma



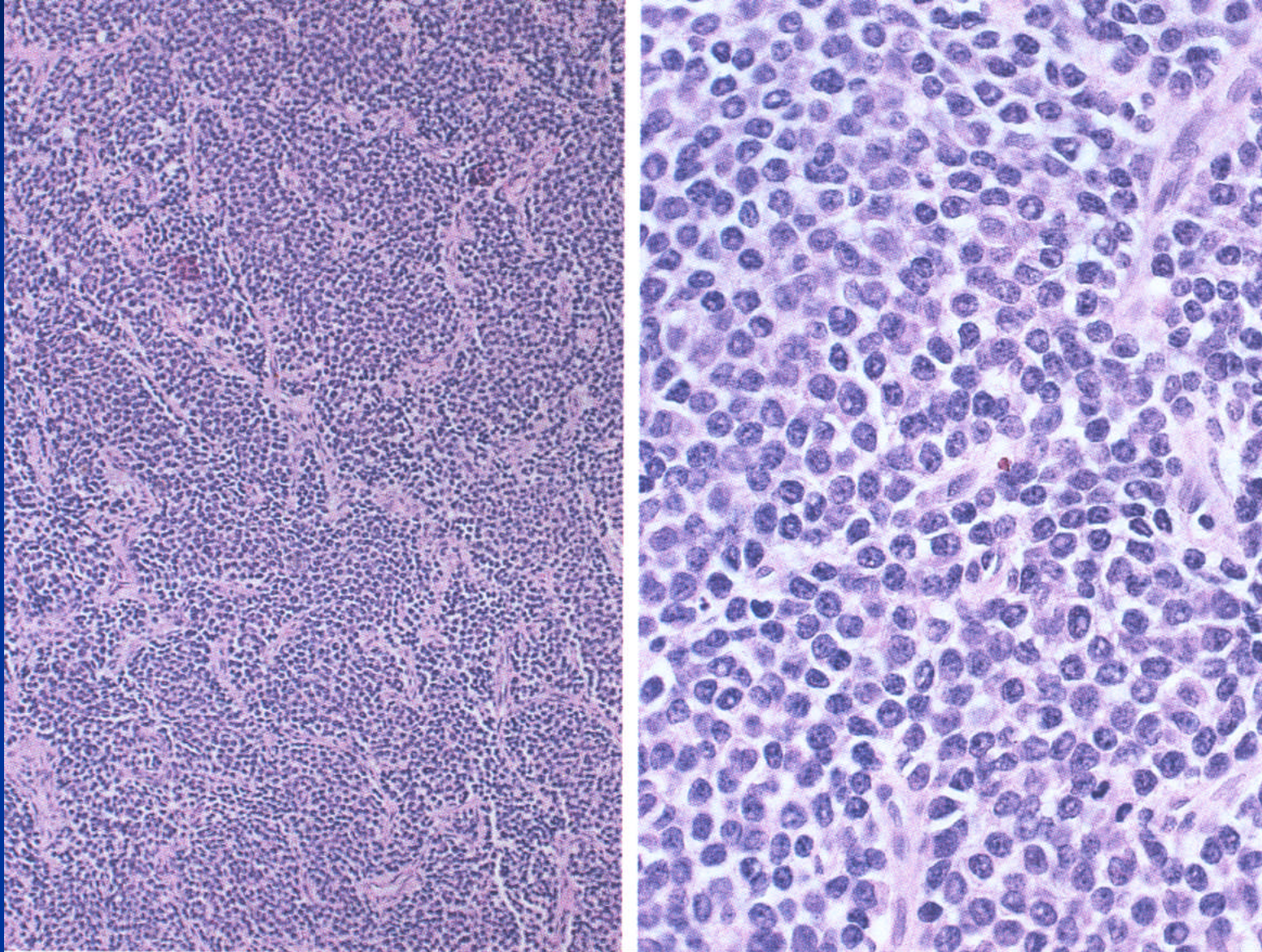


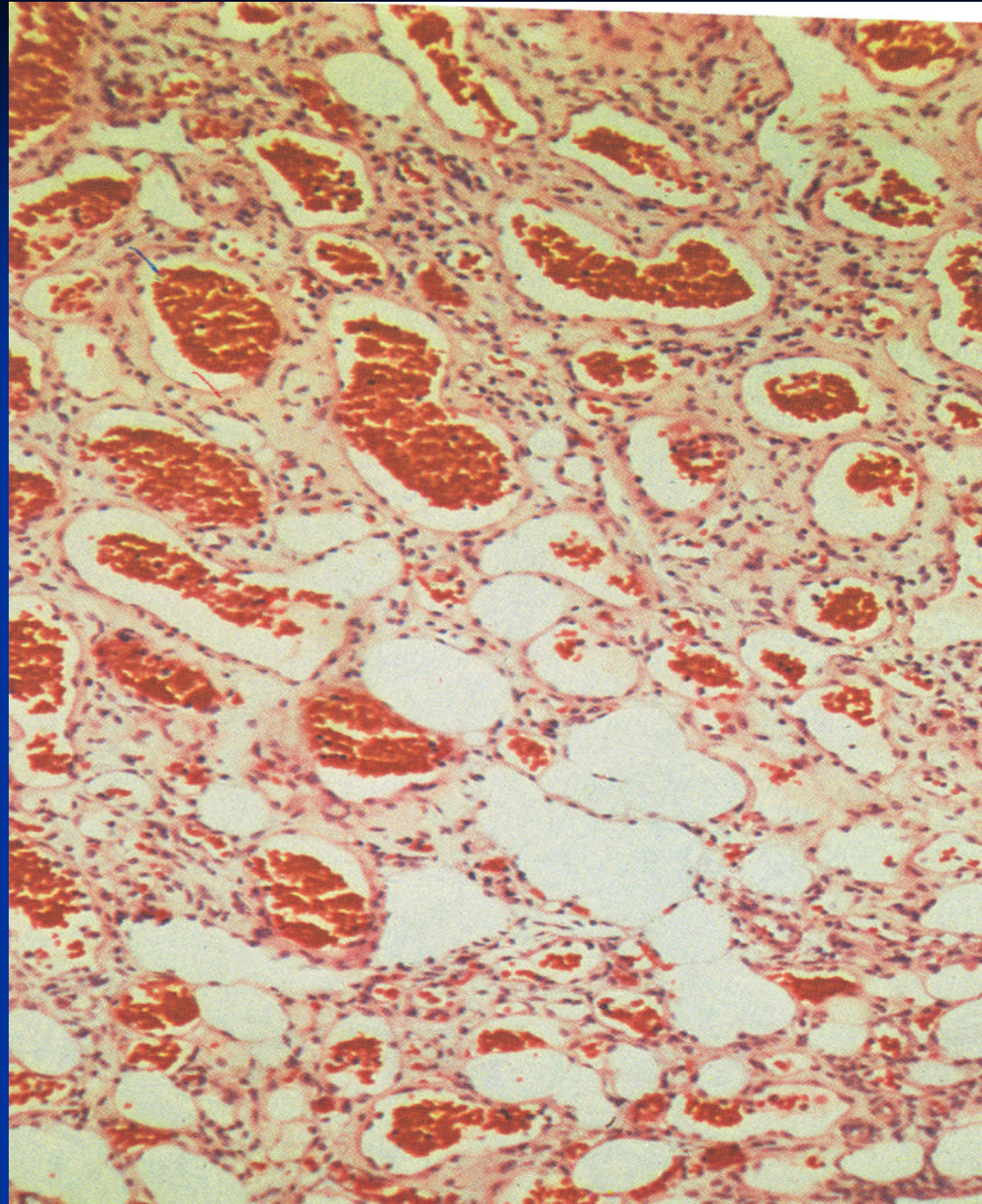
Chondrosarcoma



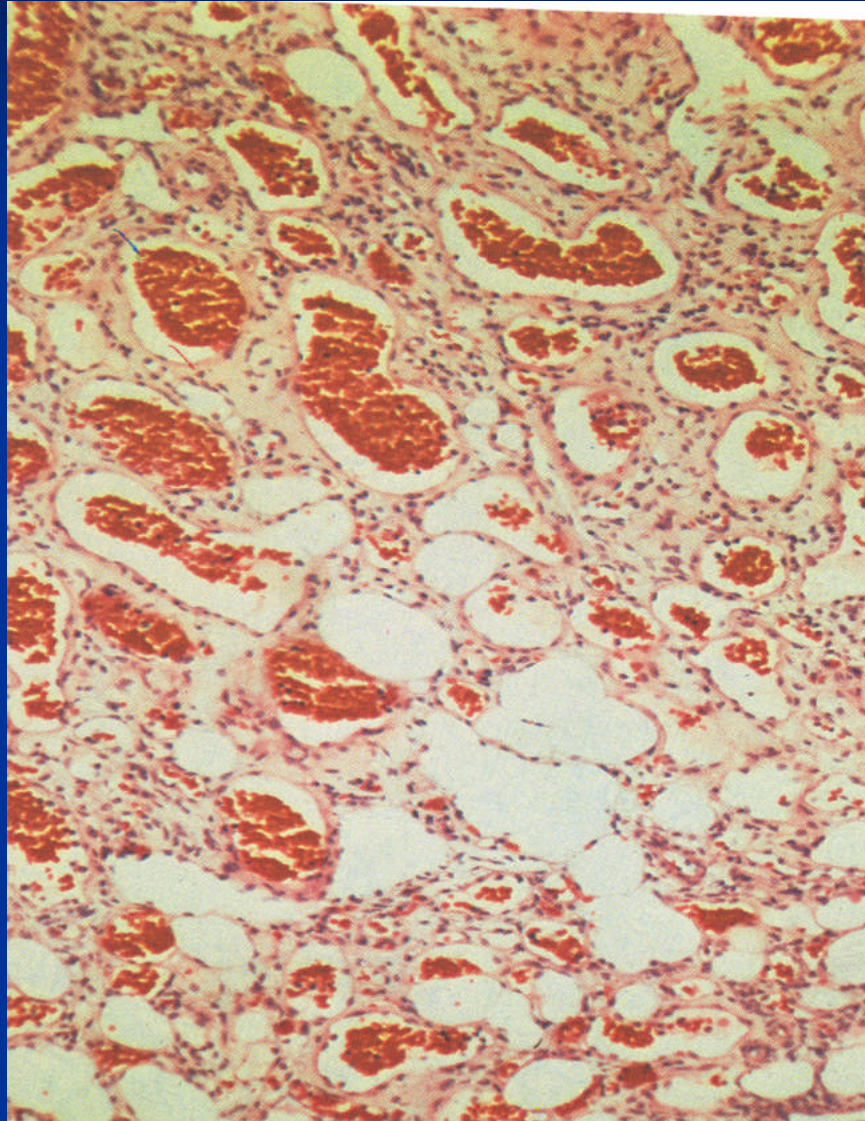


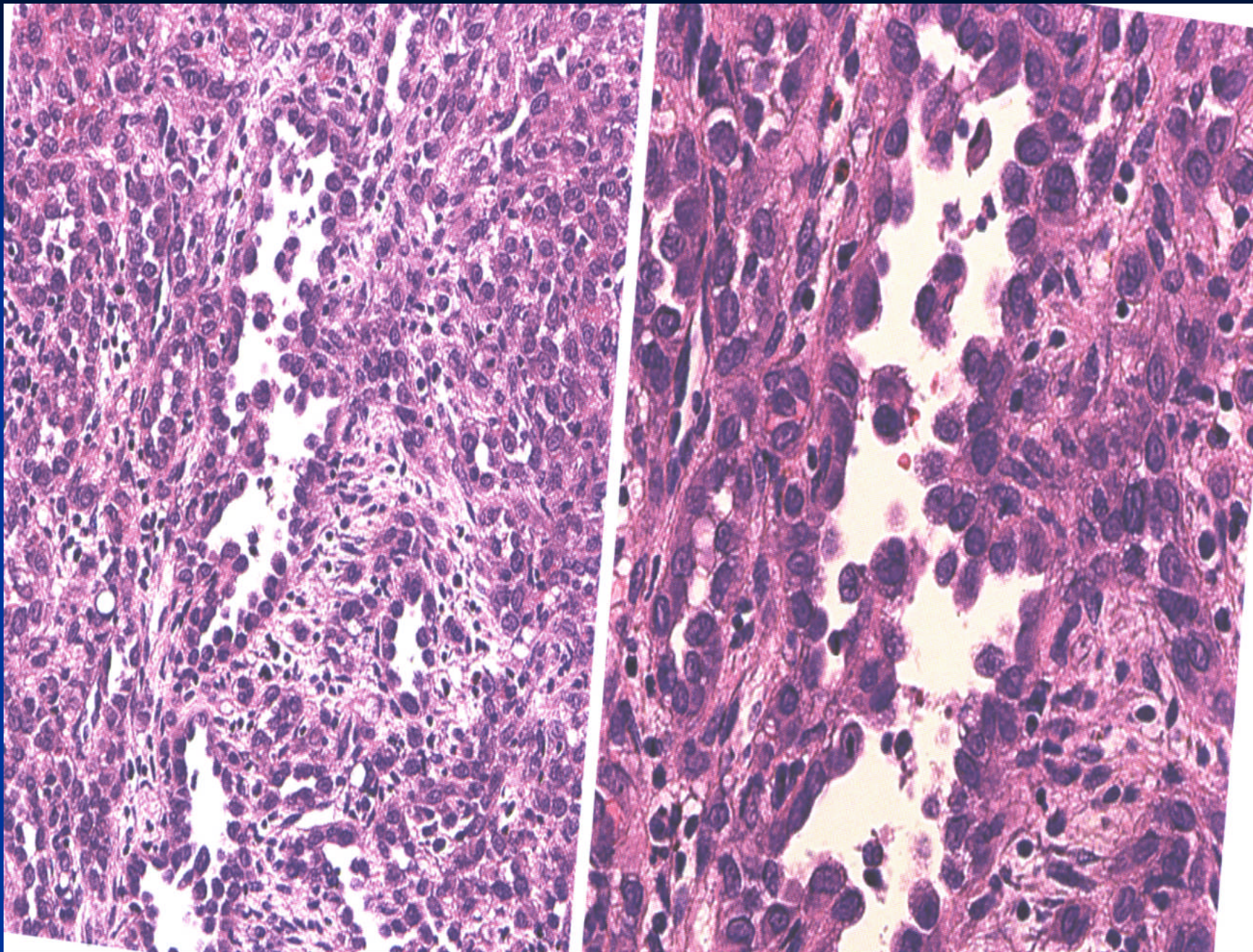
Ewing's Sarcoma



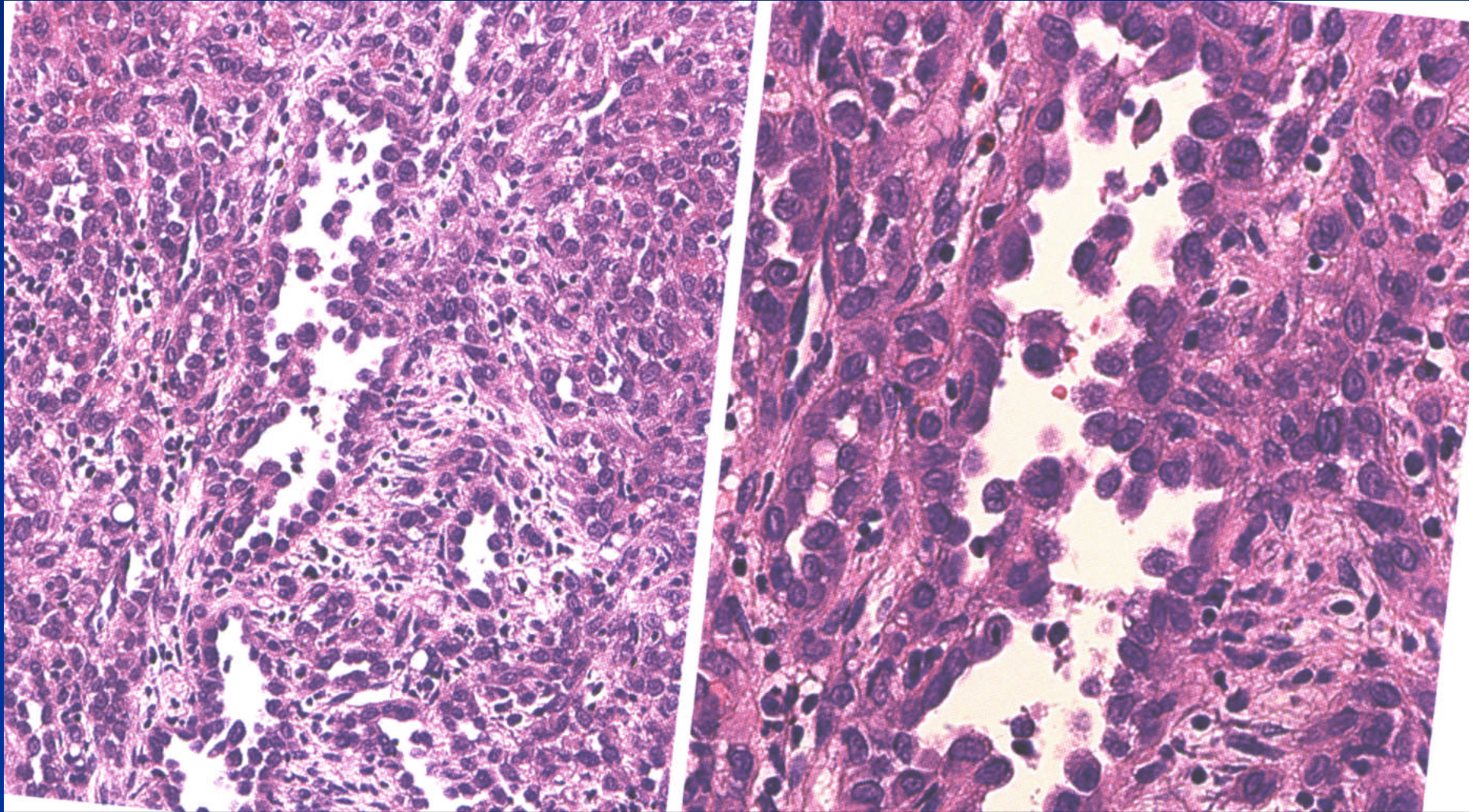


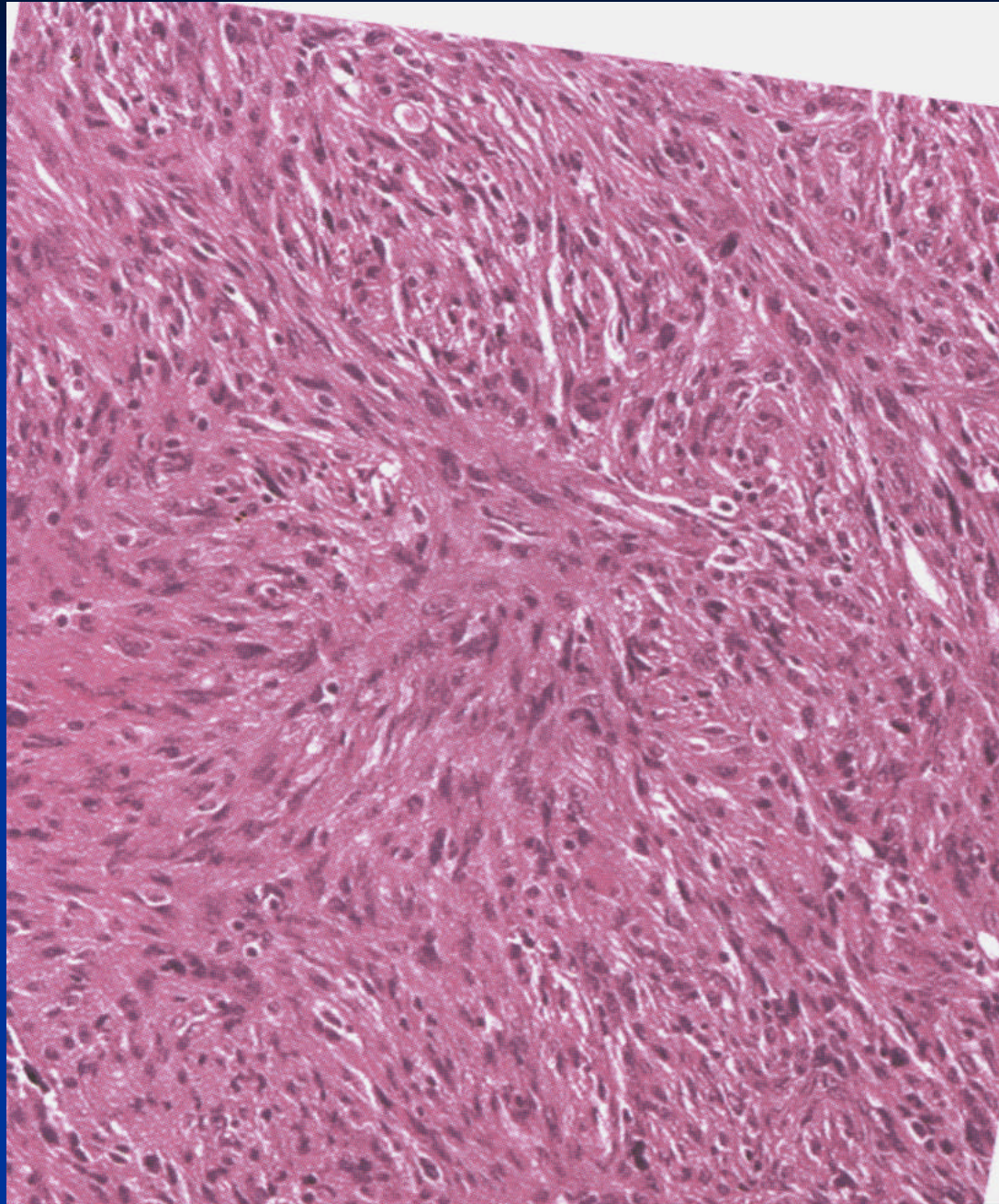
Hemangioma



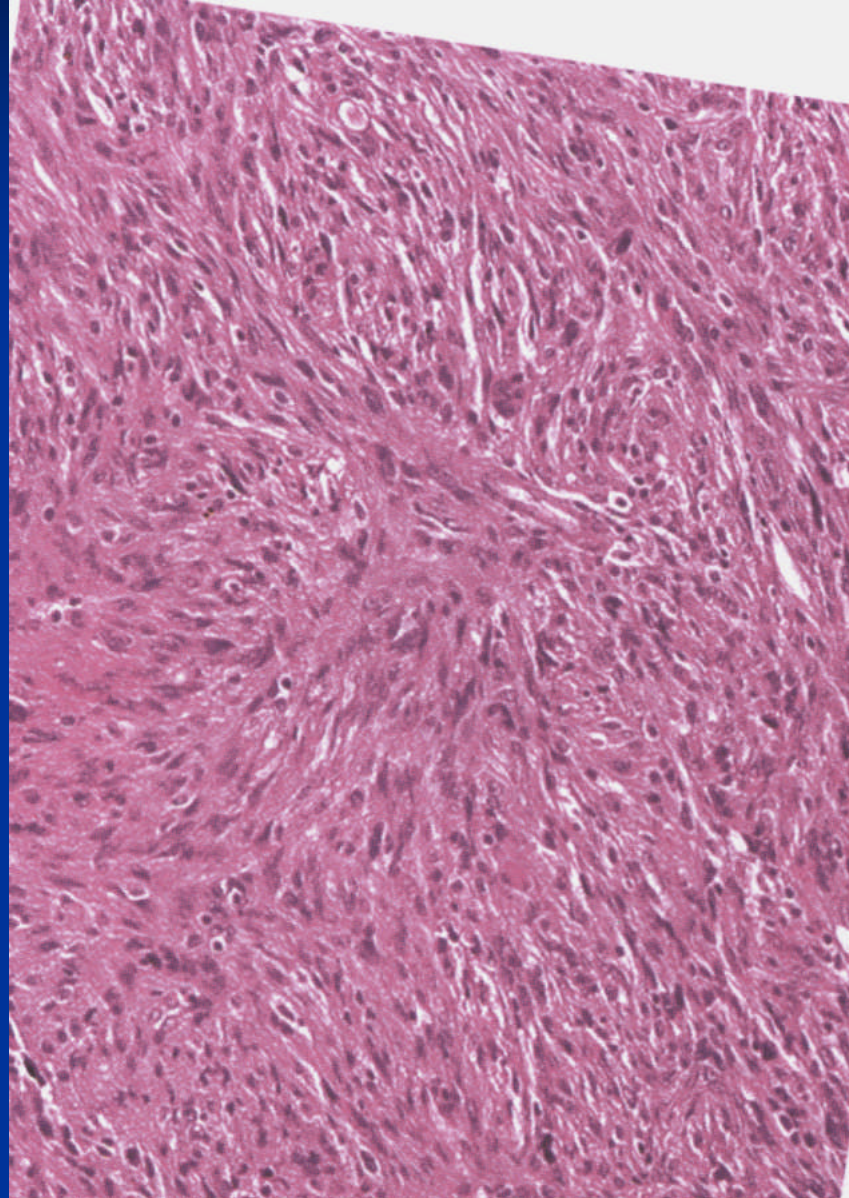


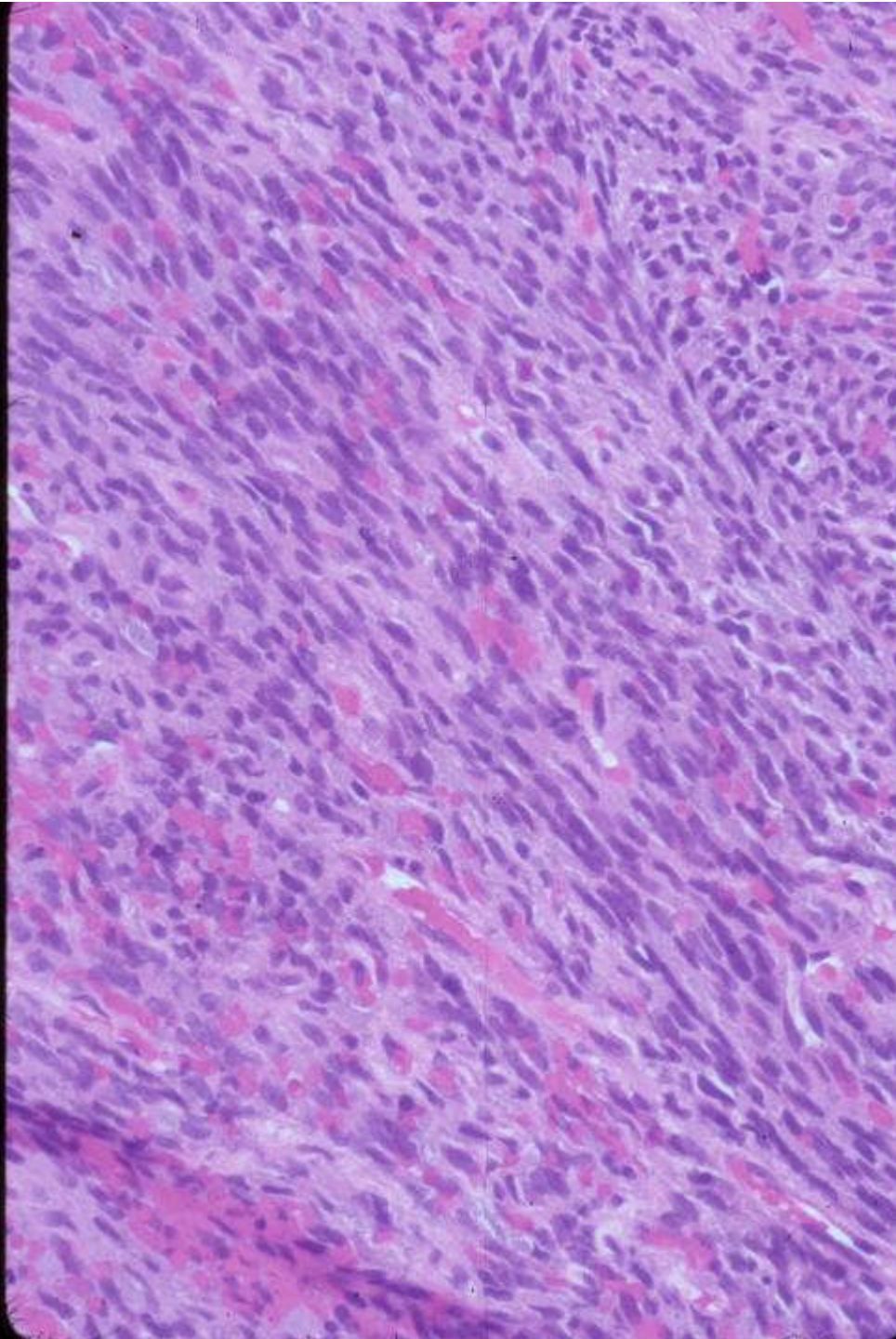
Hemangioendothelioma

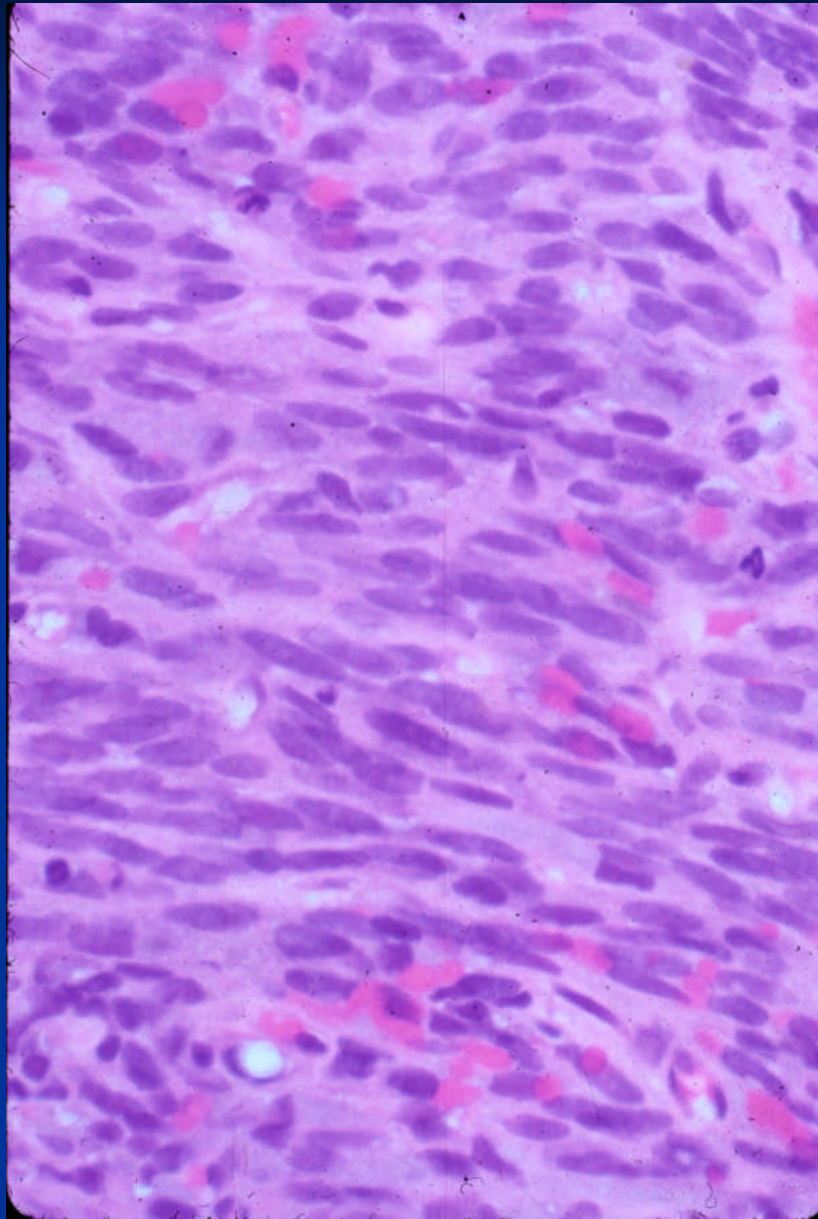




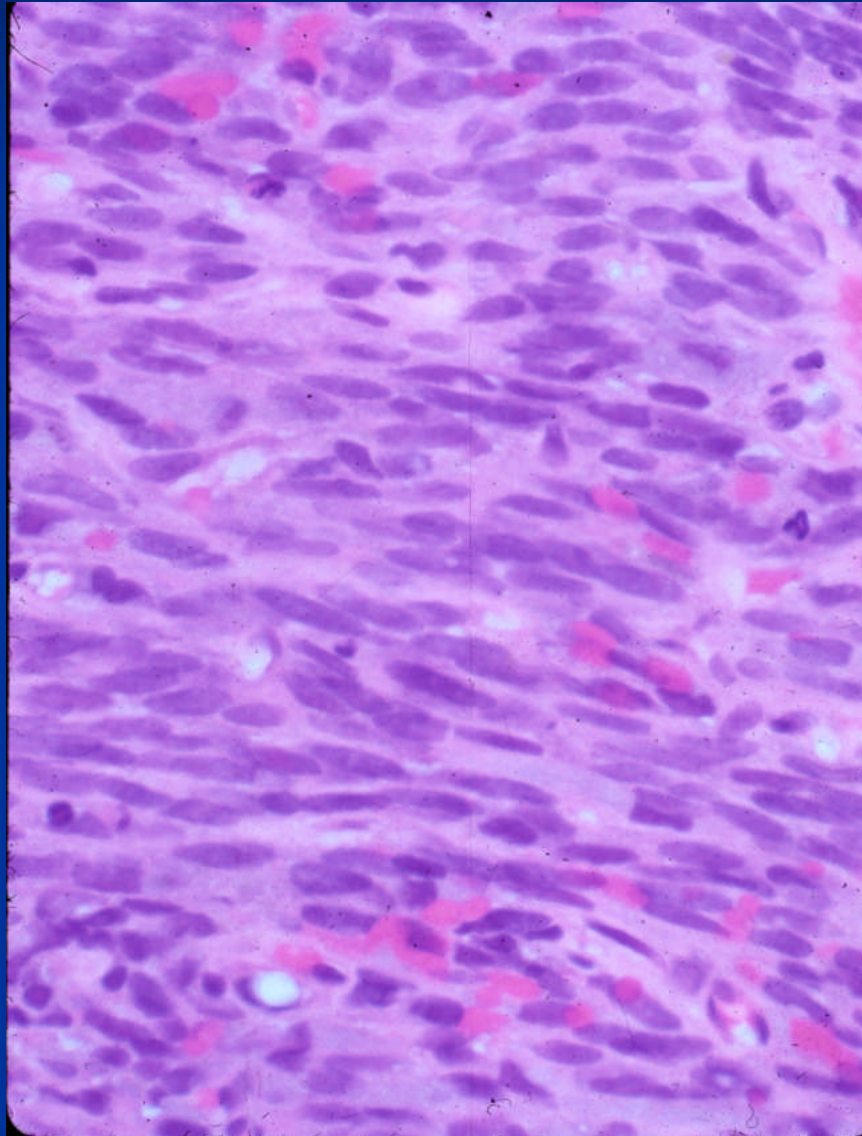
Nonossifying Fibroma





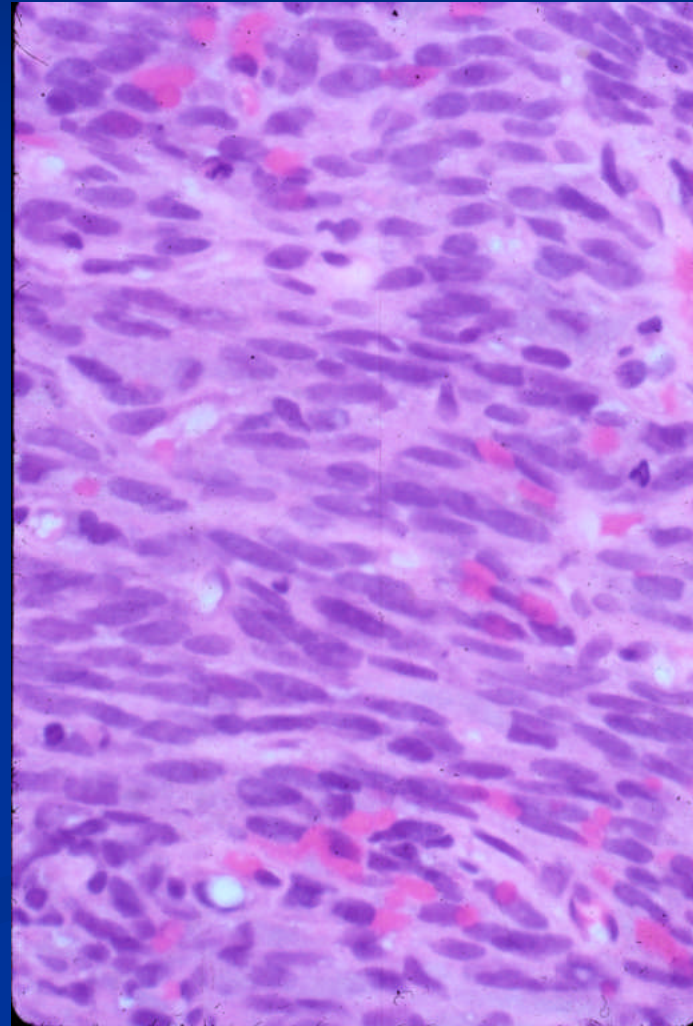
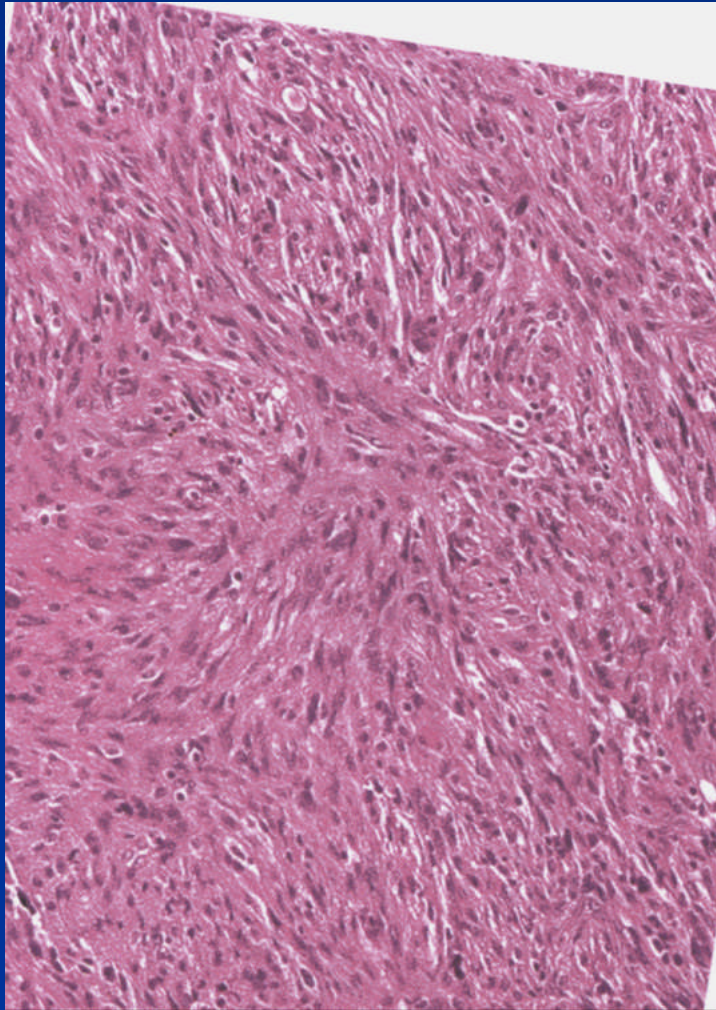


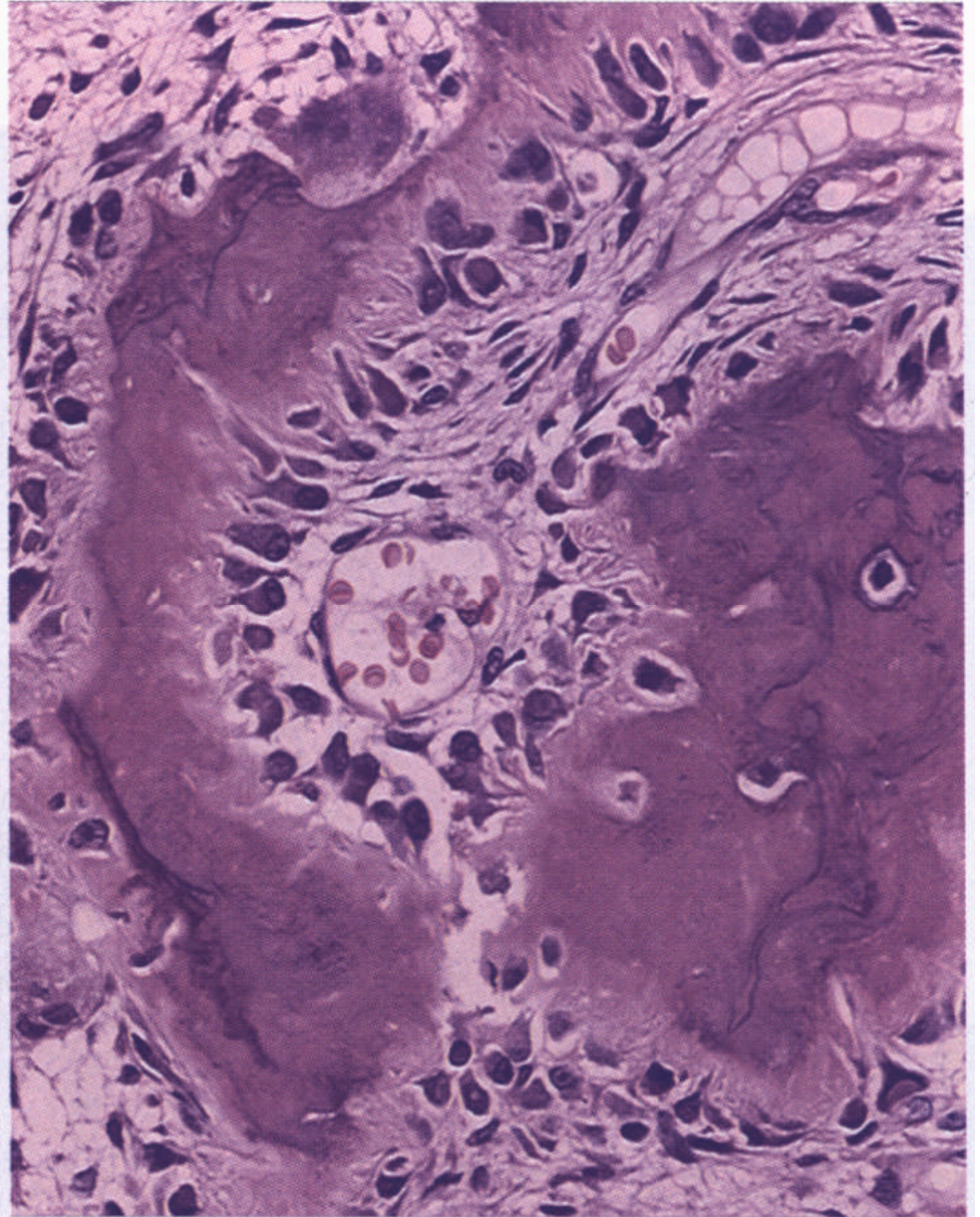
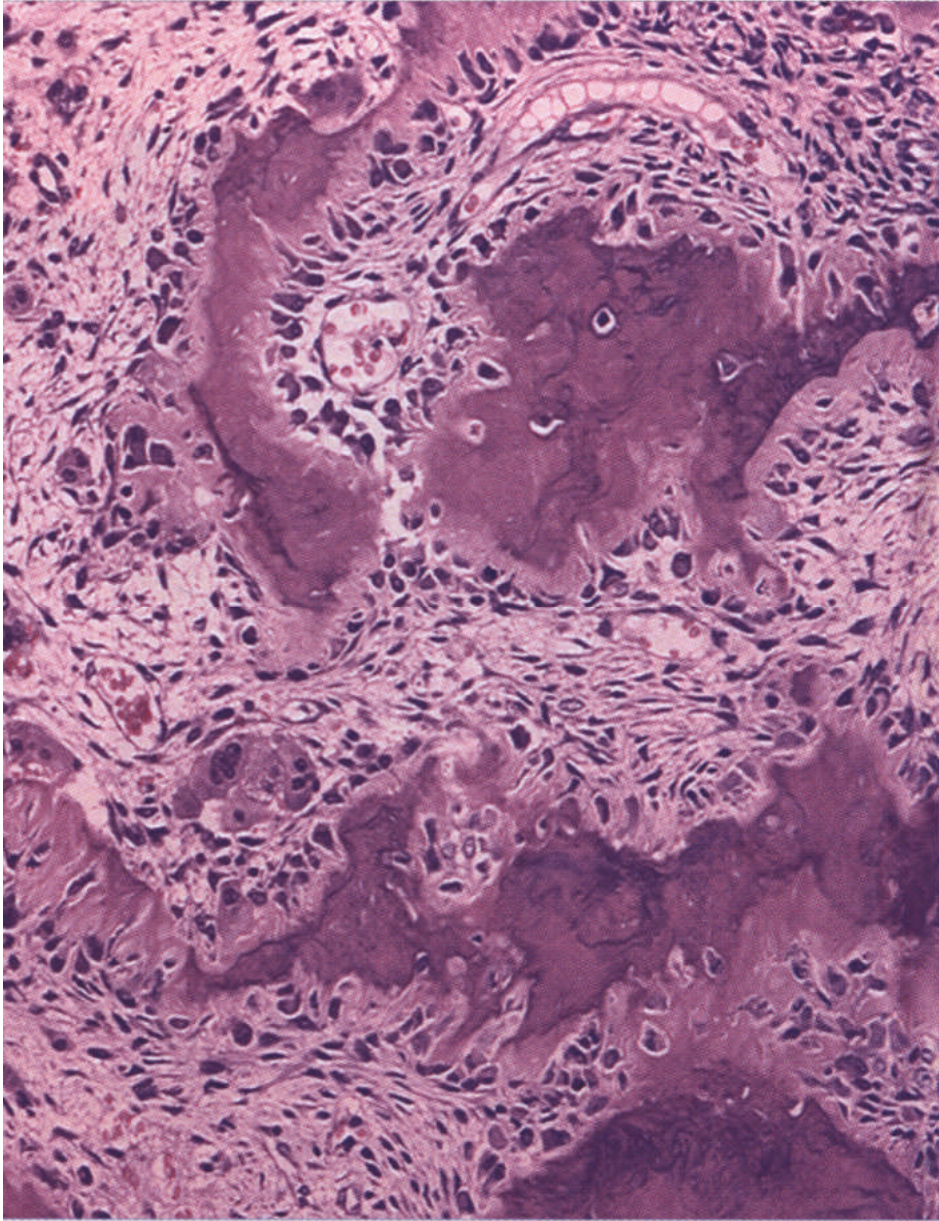
Fibrosarcoma



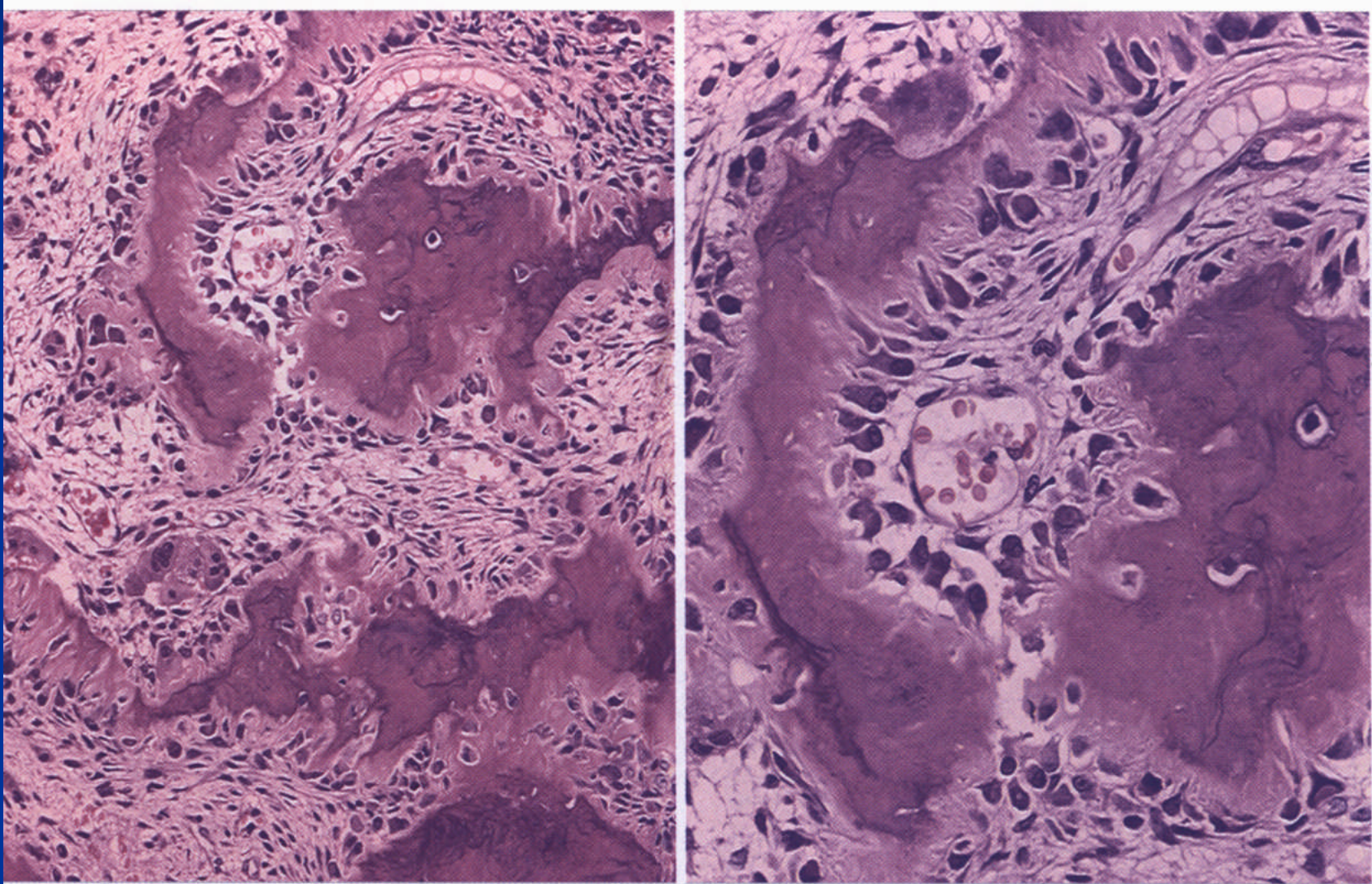
NOF / Fibrosarcoma

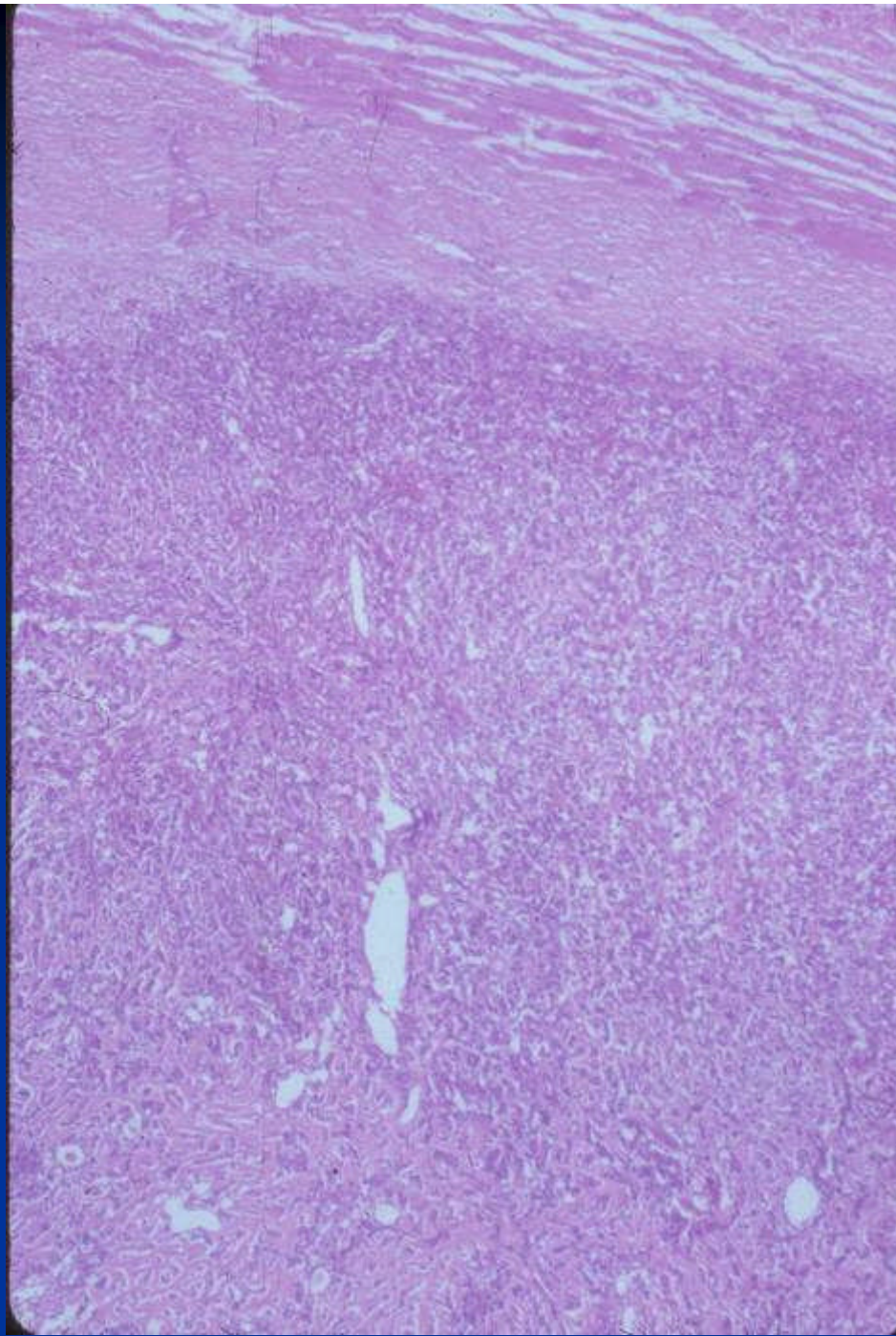
Benign / Malignant

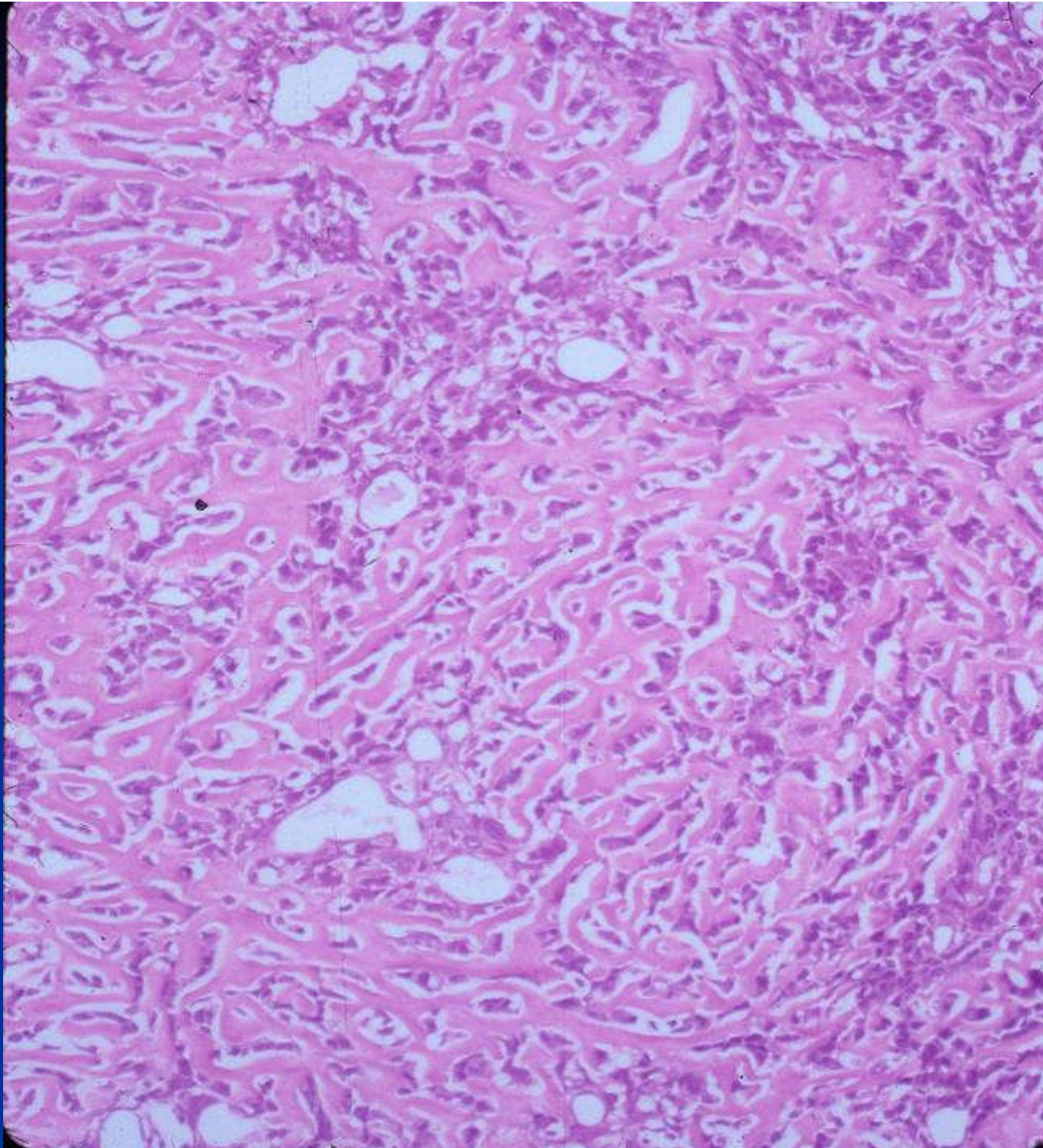


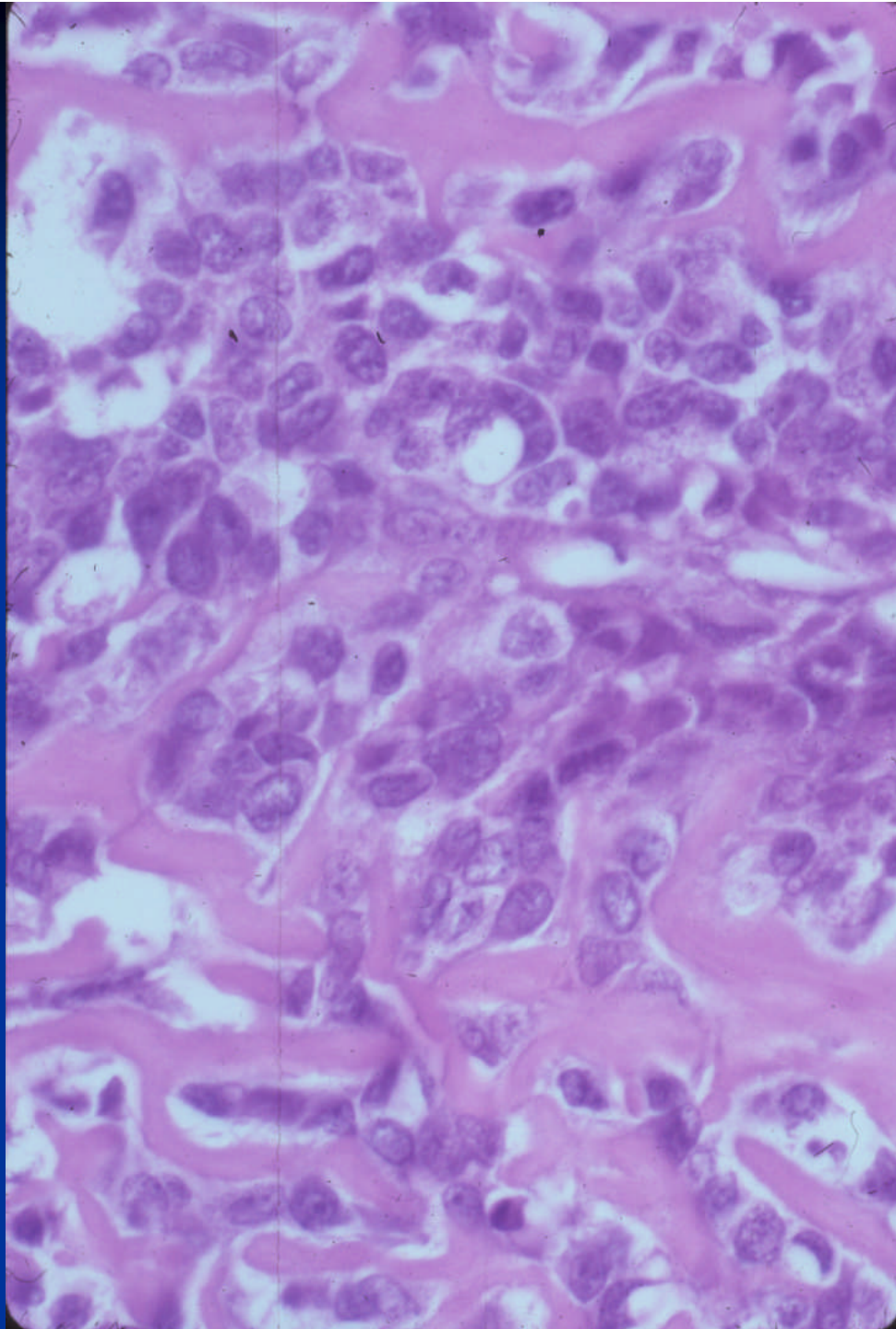


Osteoblastoma

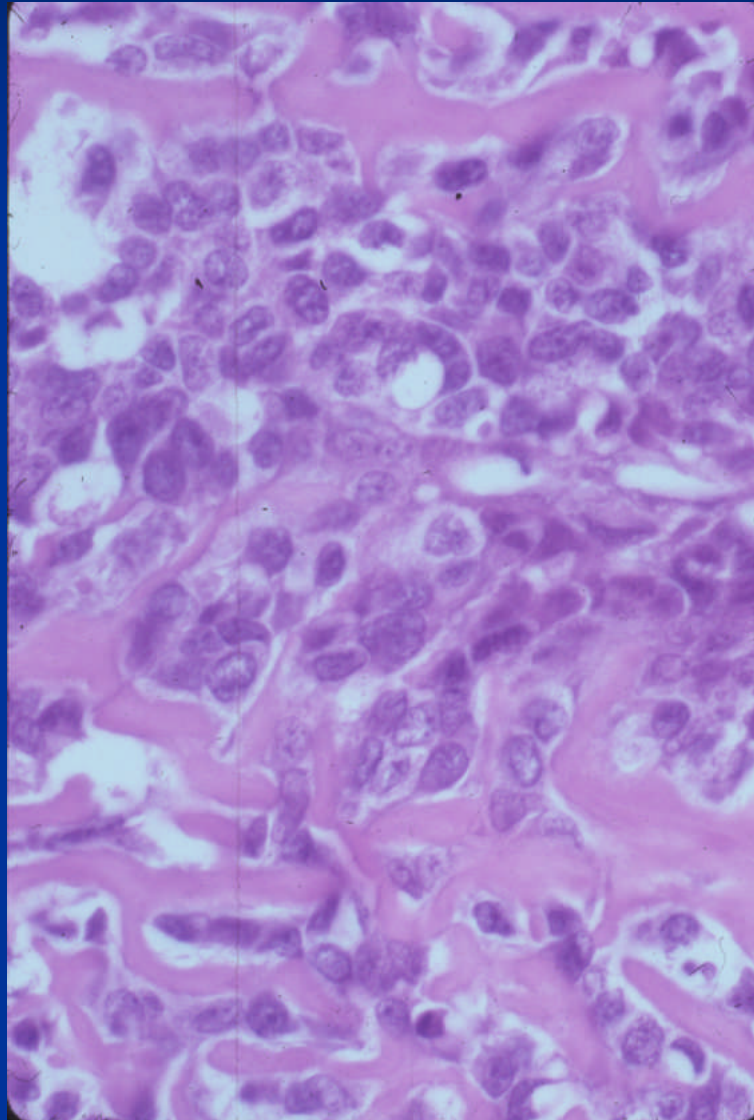


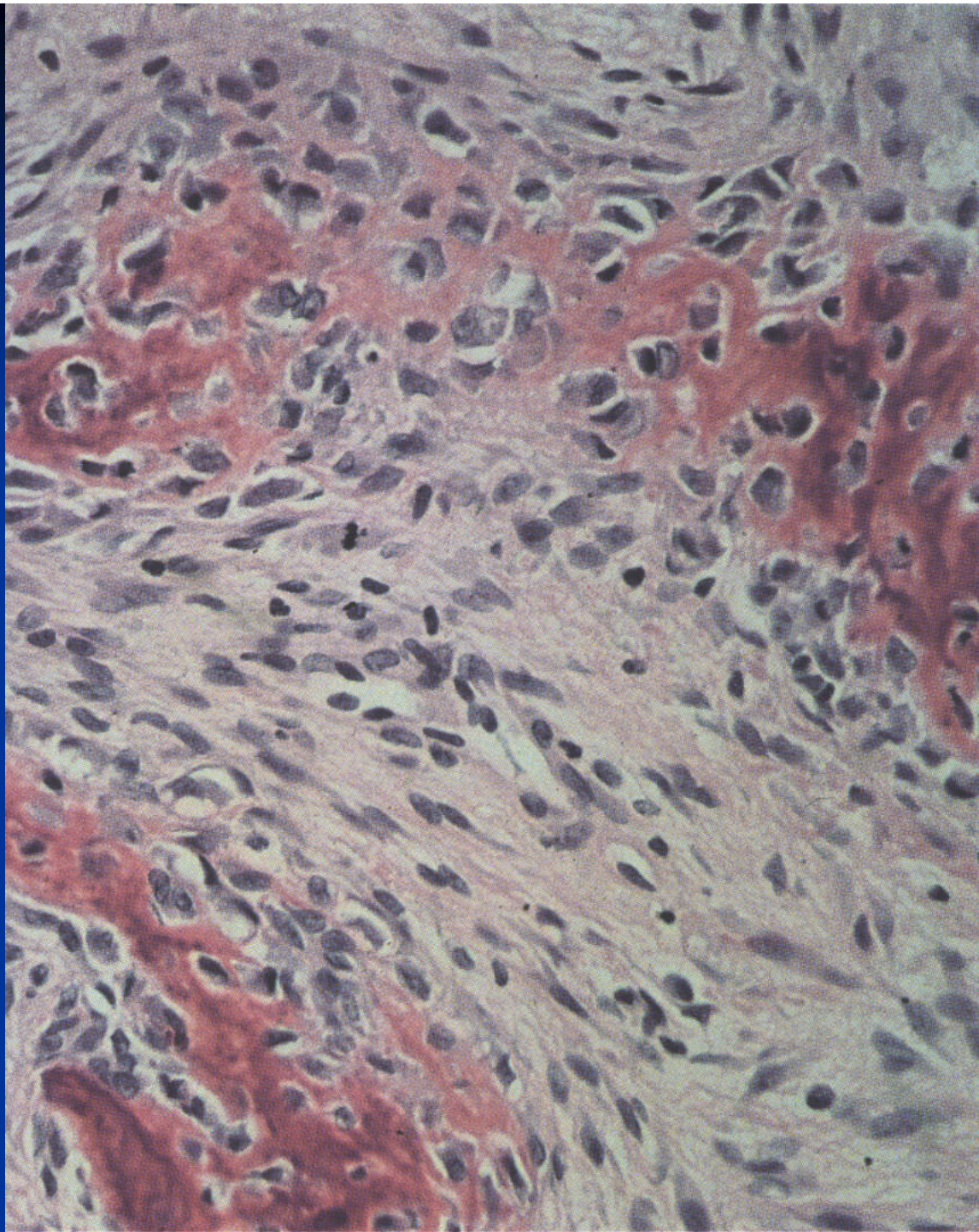




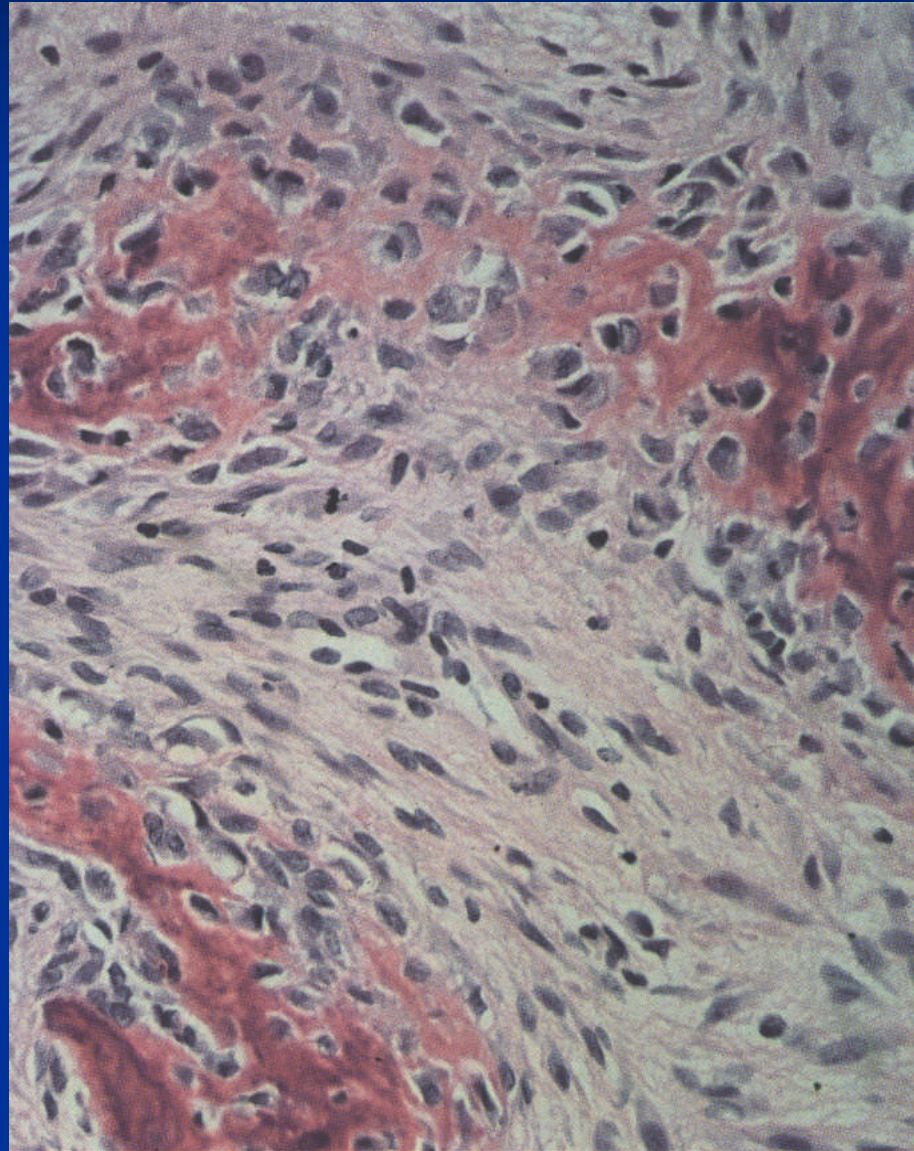


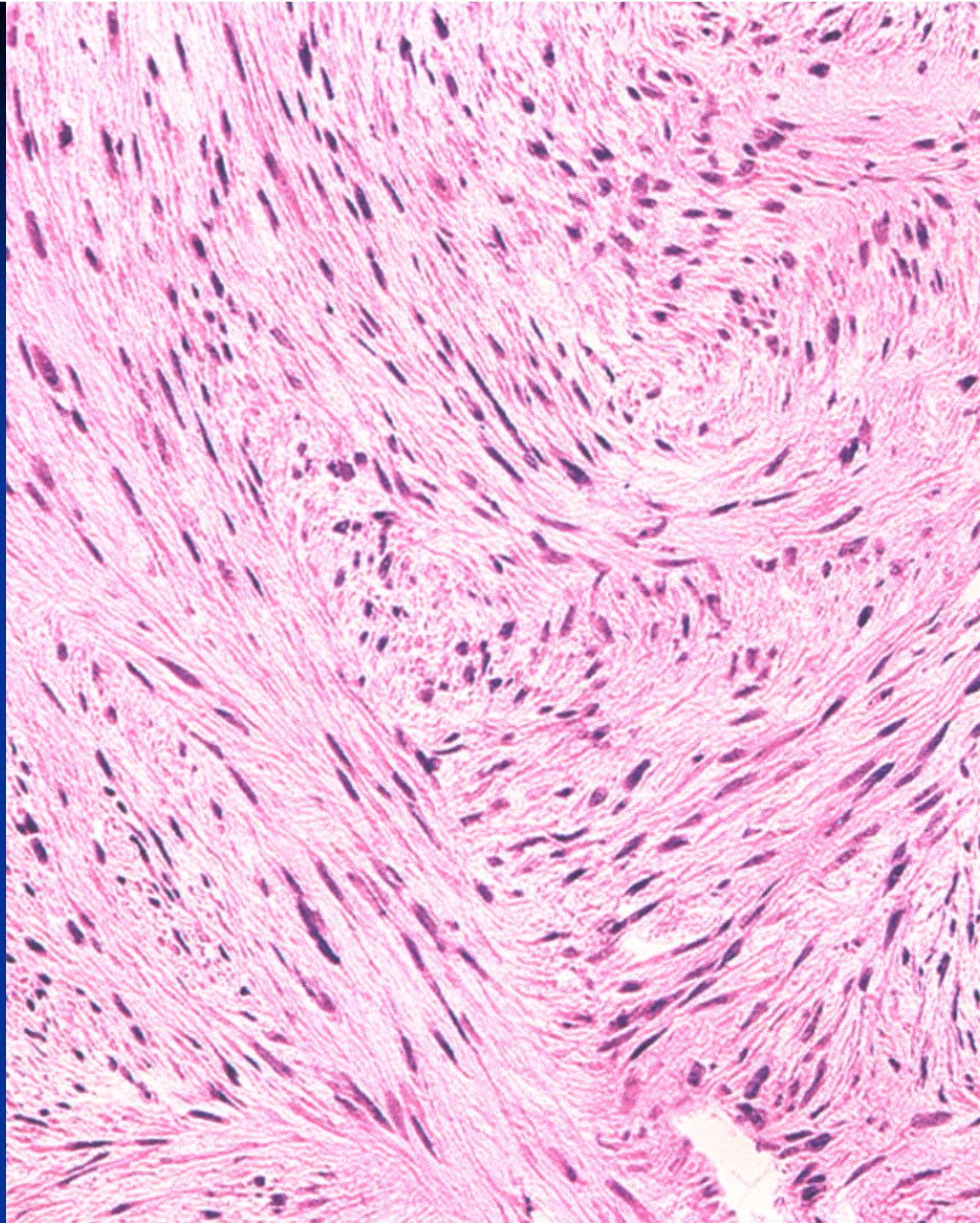
Osteosarcoma (High Grade)



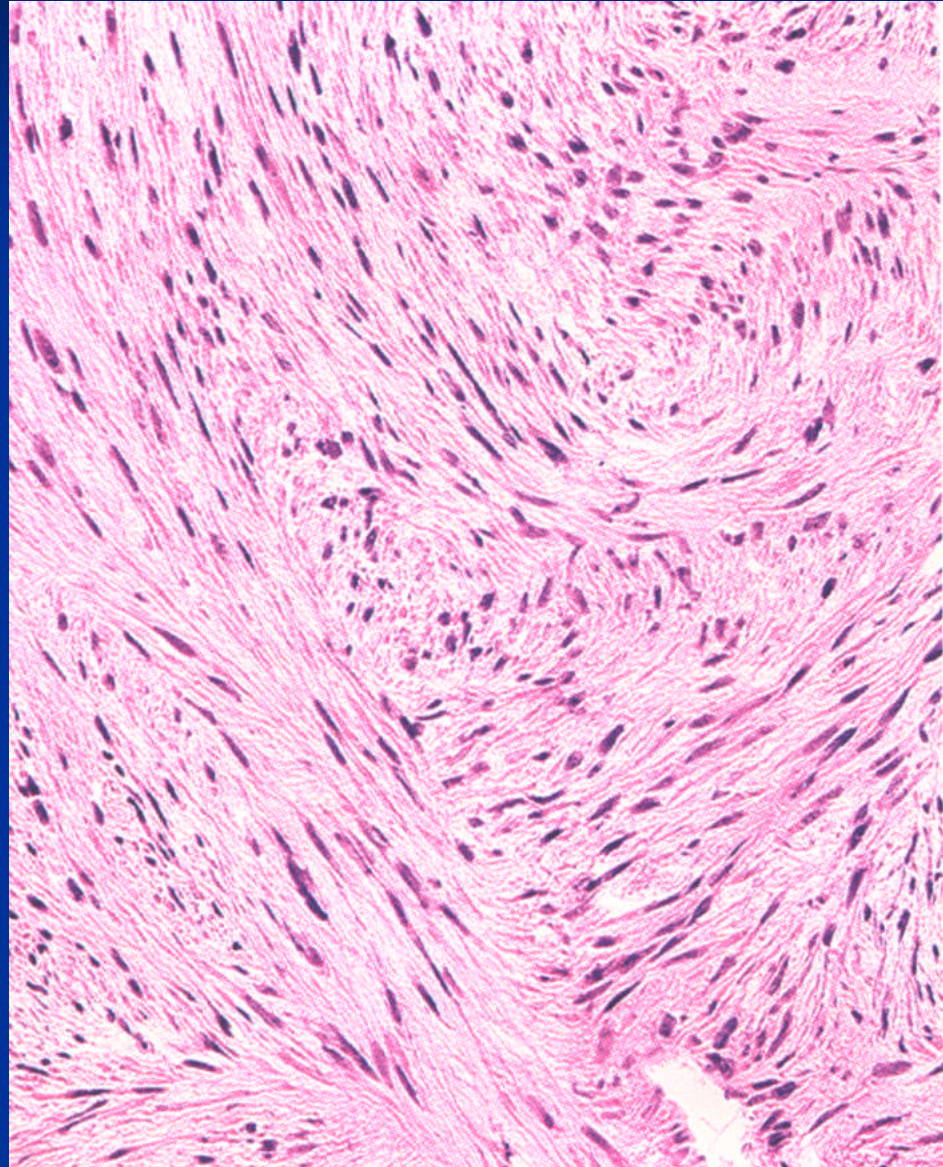


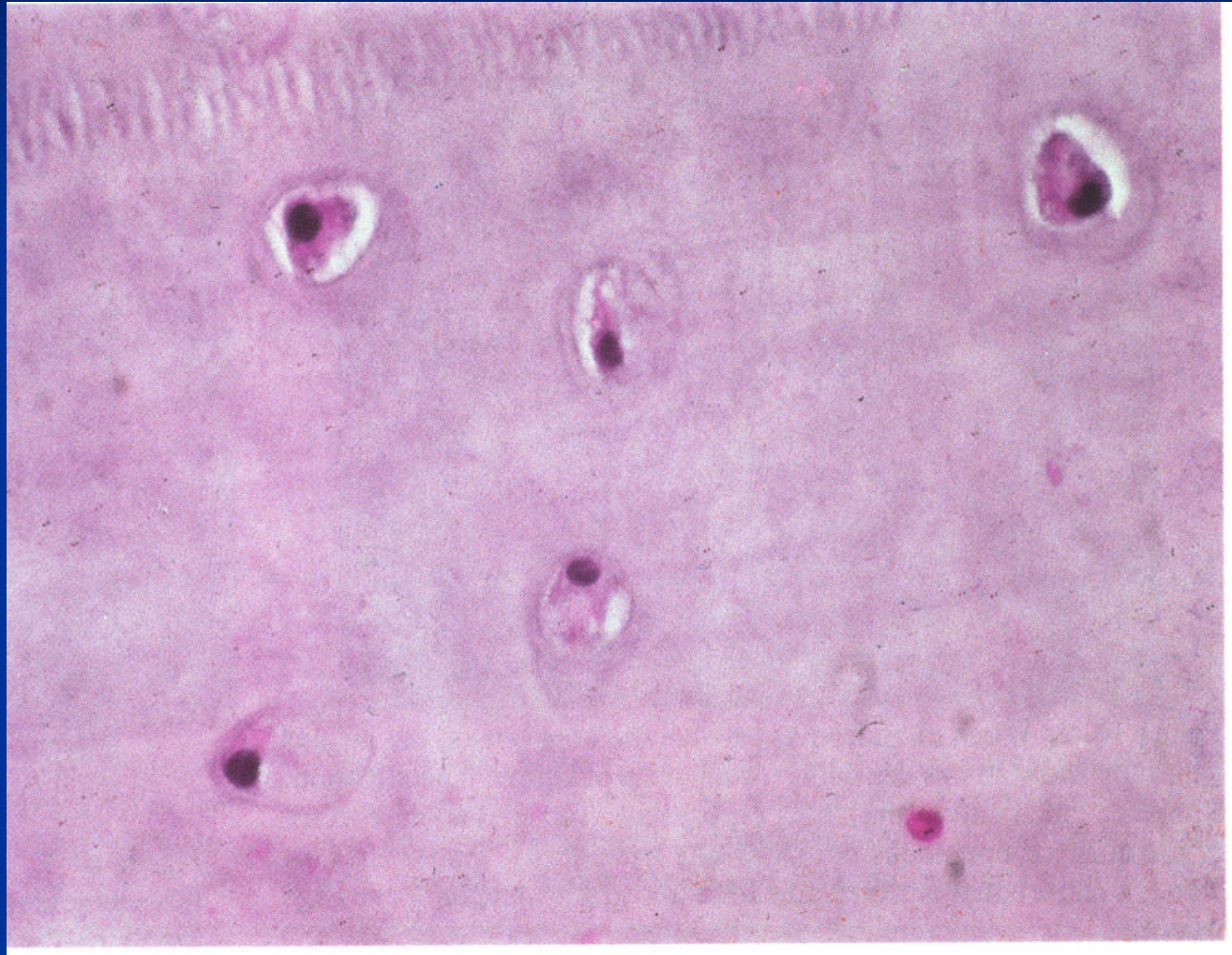
Osteosarcoma (Low Grade)



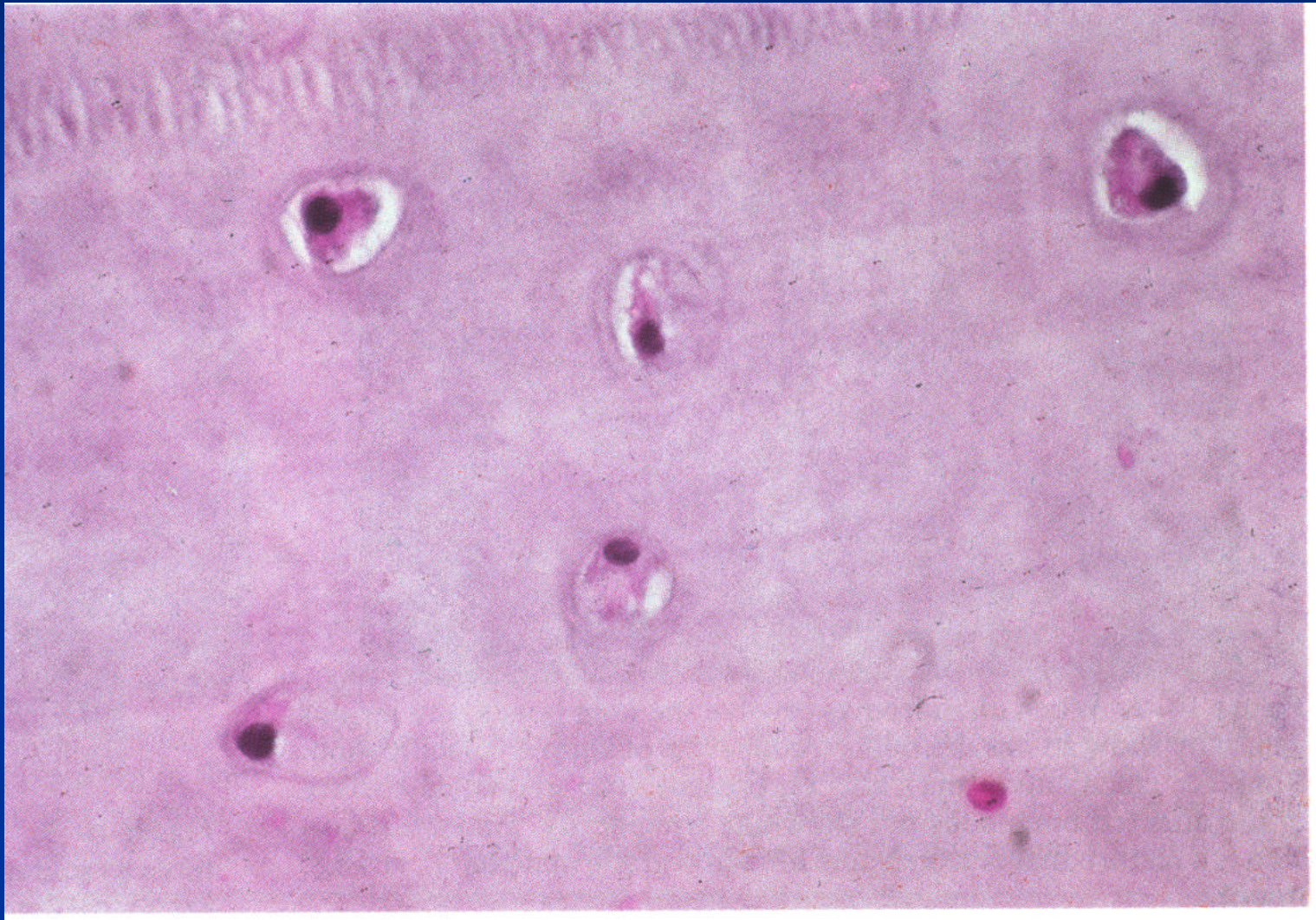


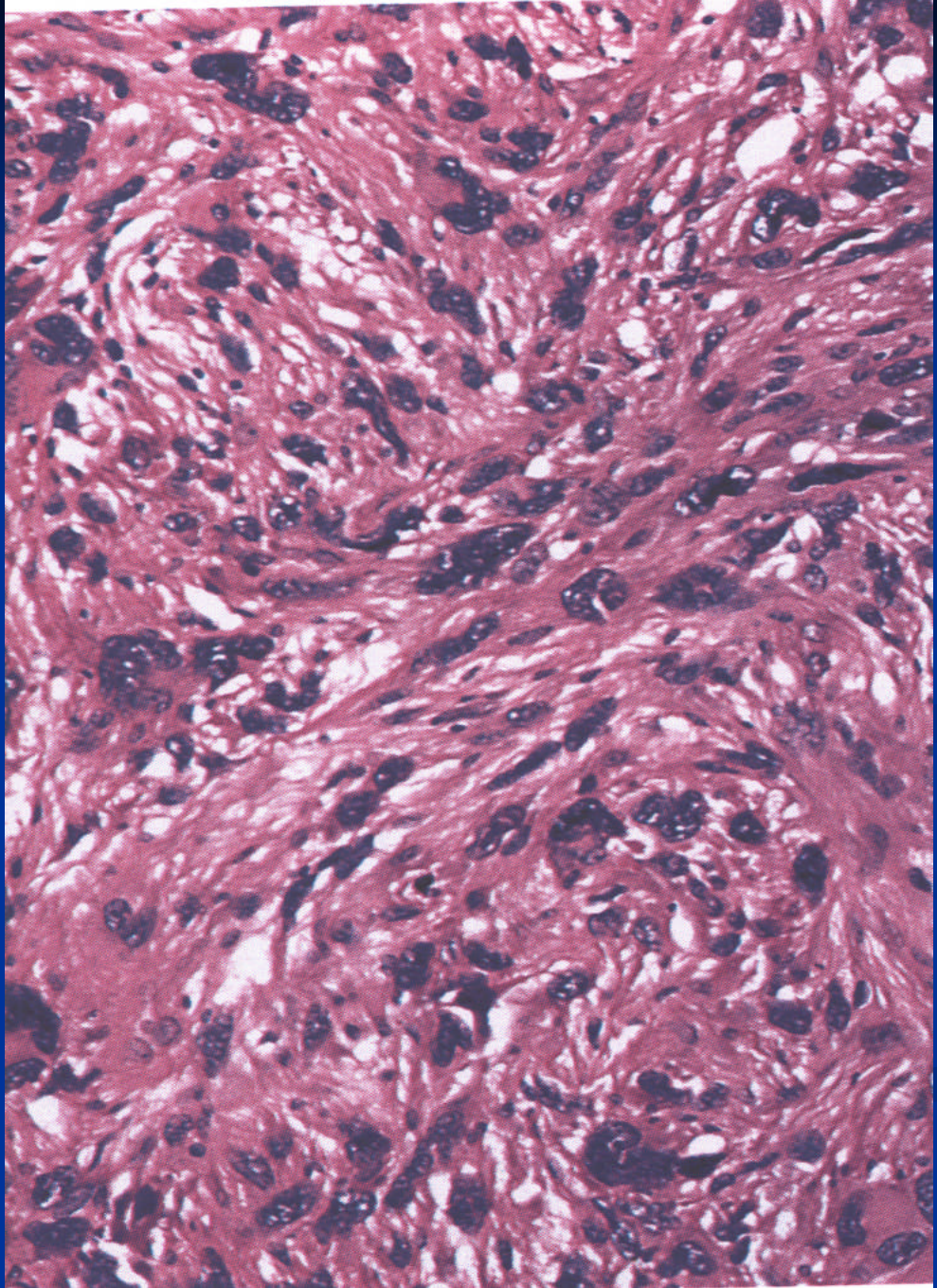
Leiomyosarcoma



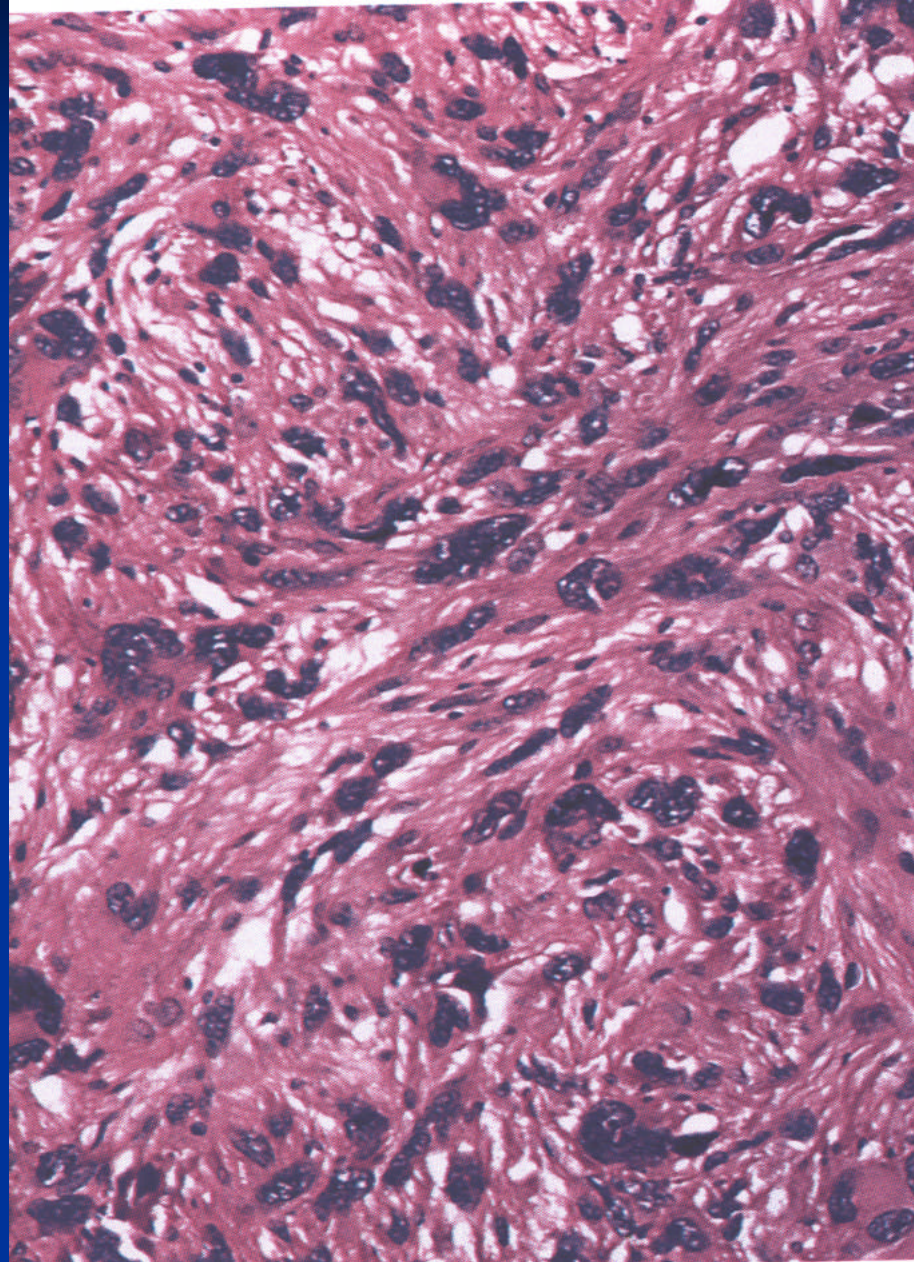


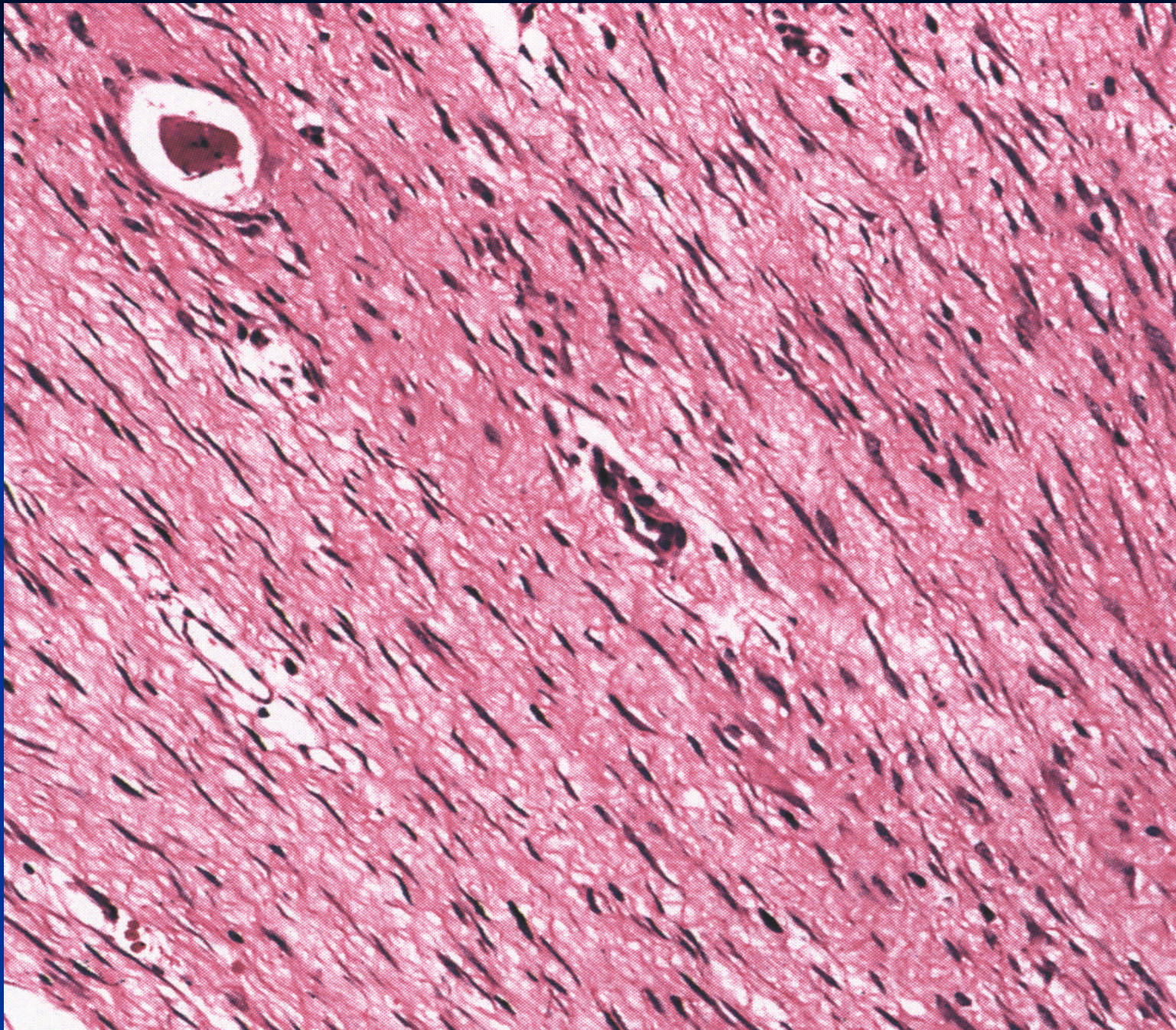
Enchondroma



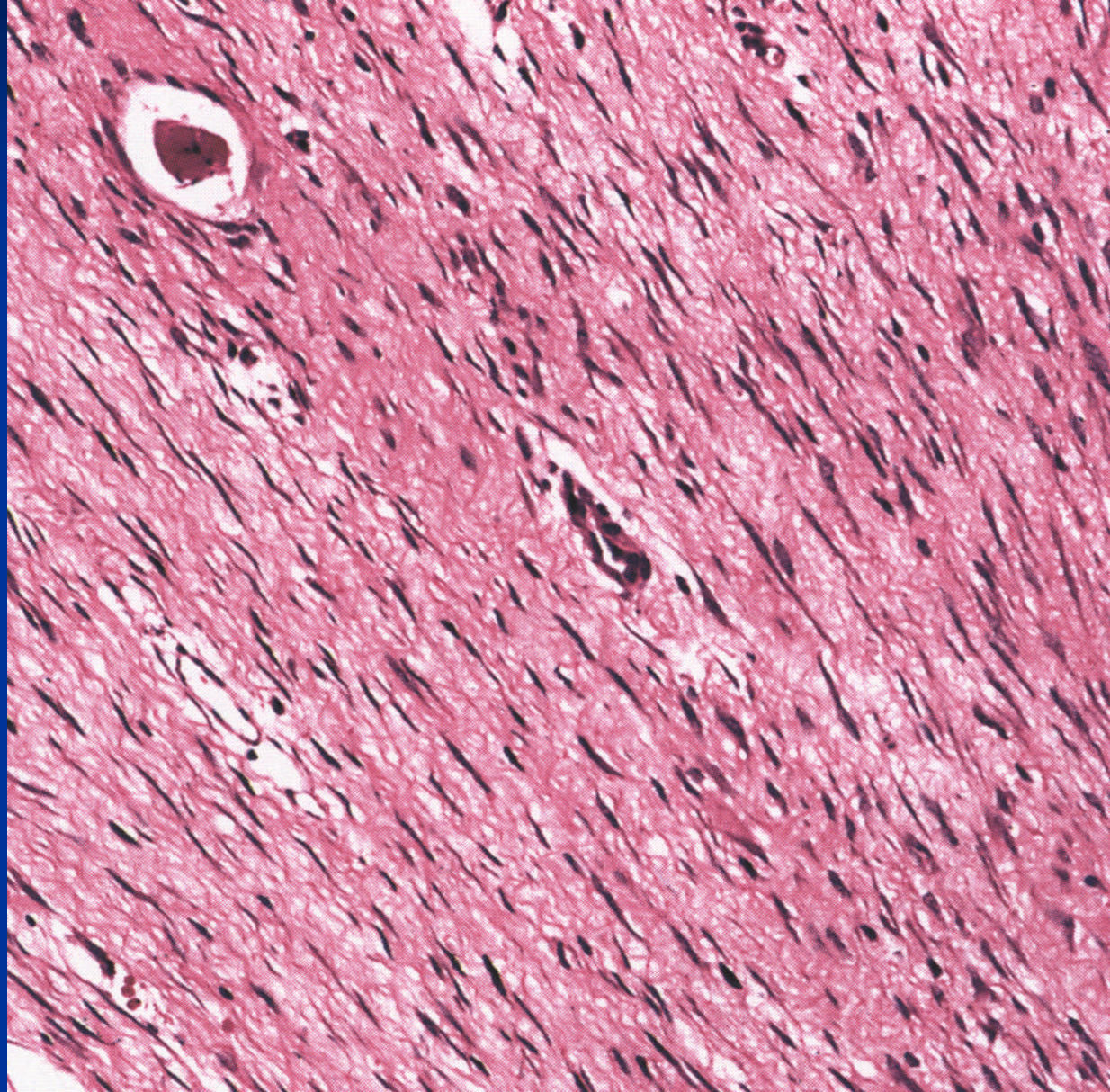


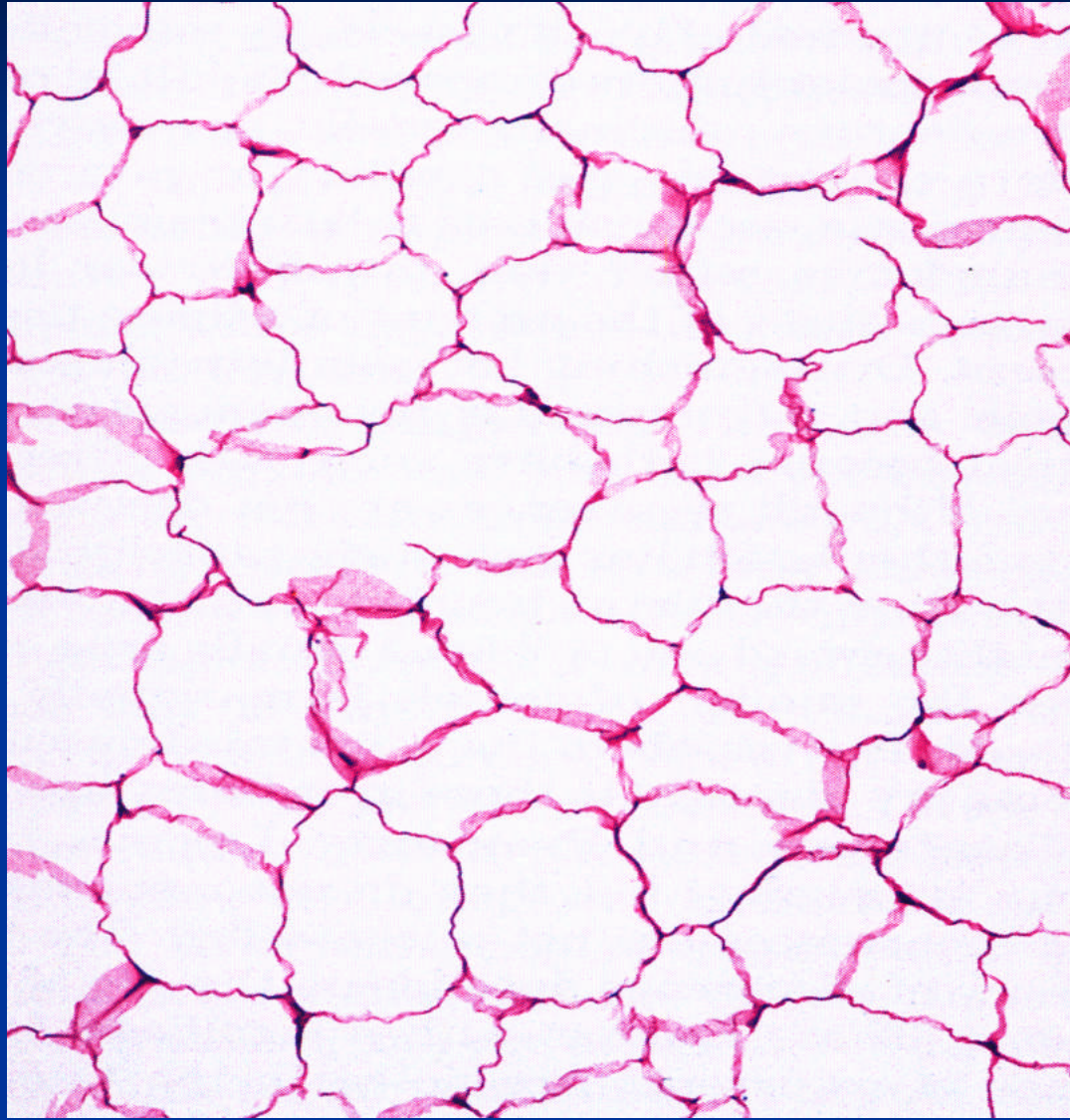
Malignant Fibrous Histiocytoma



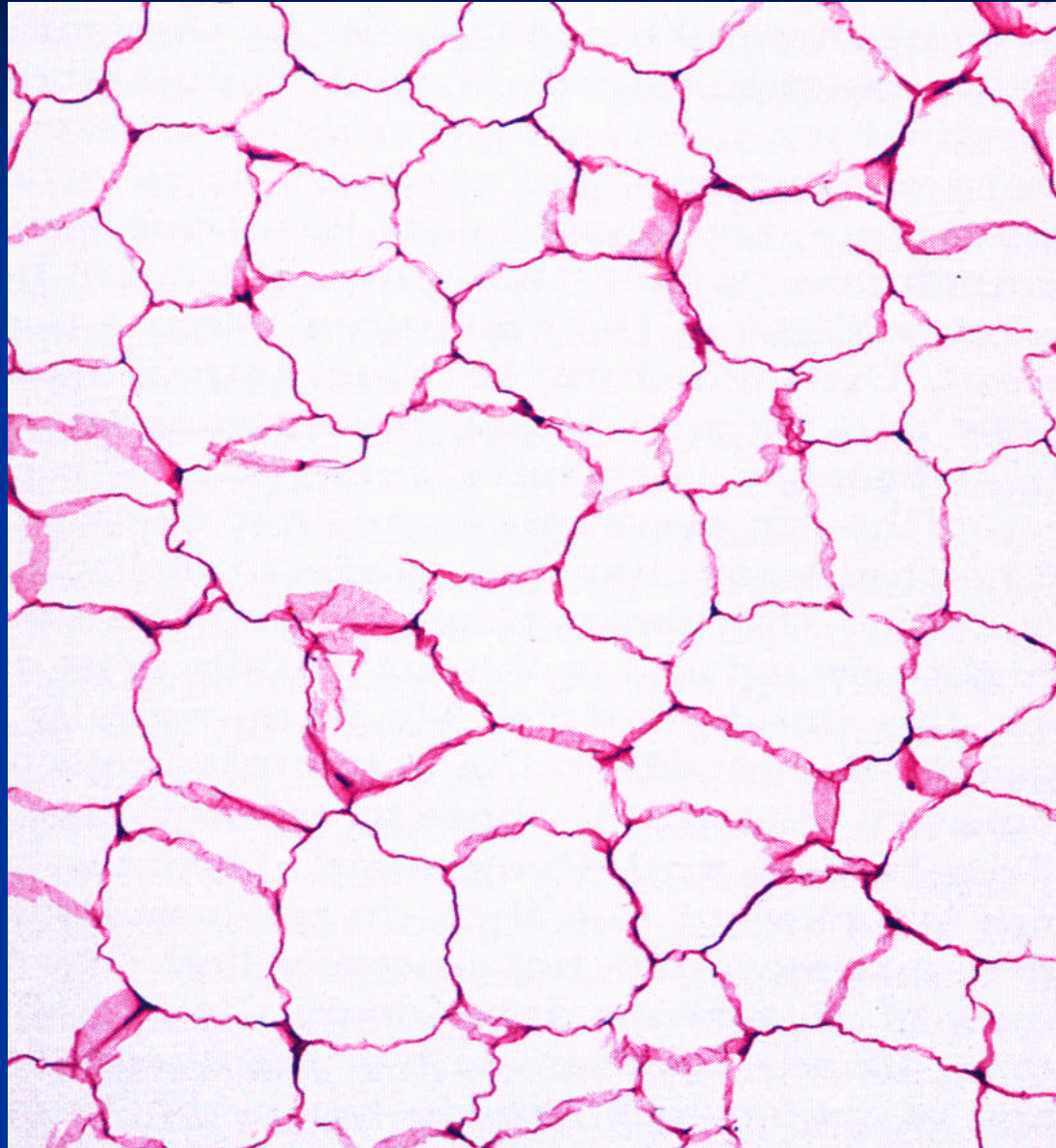


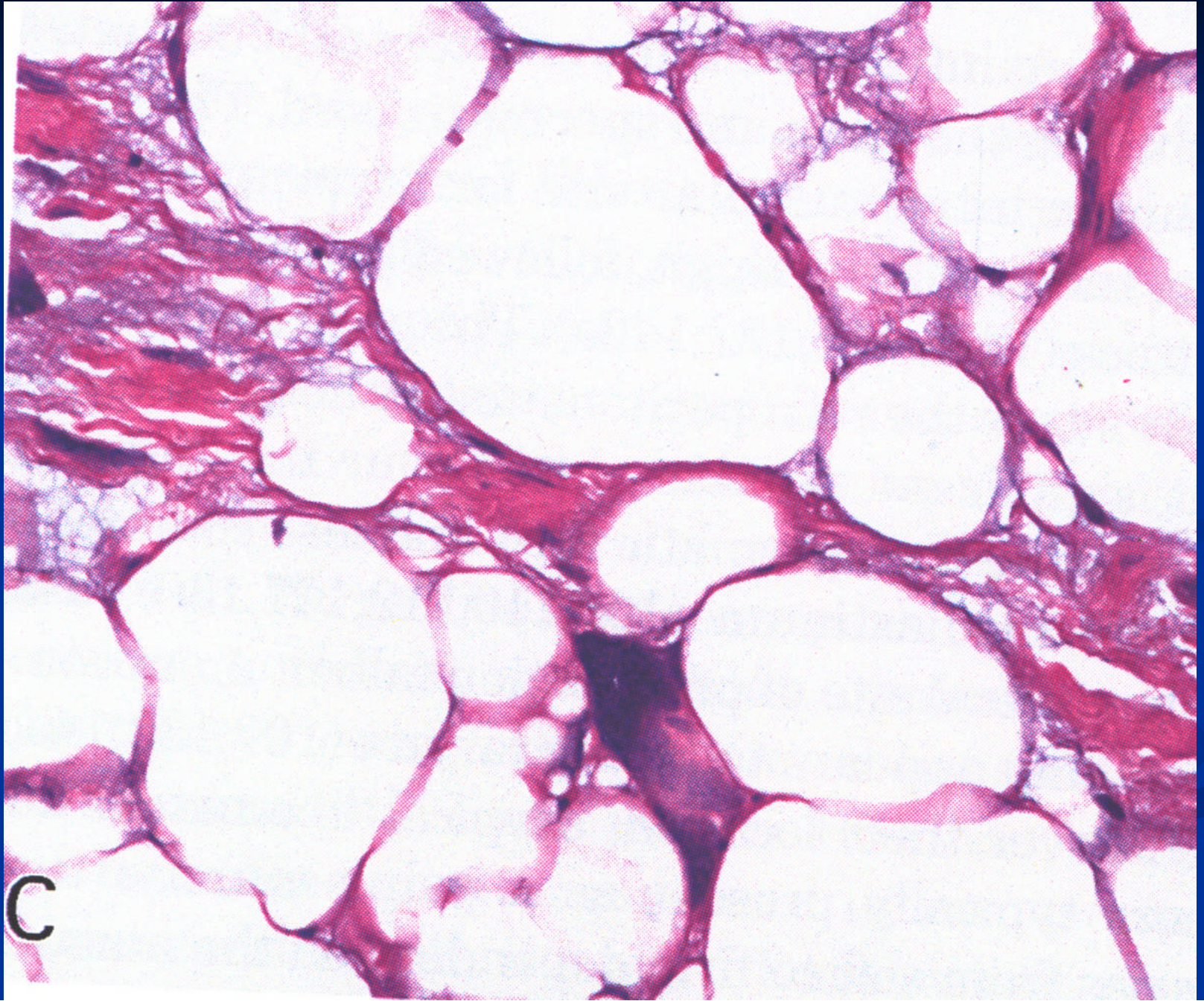
Fibromatosis / Desmoid / Desmoplastic Fibroma





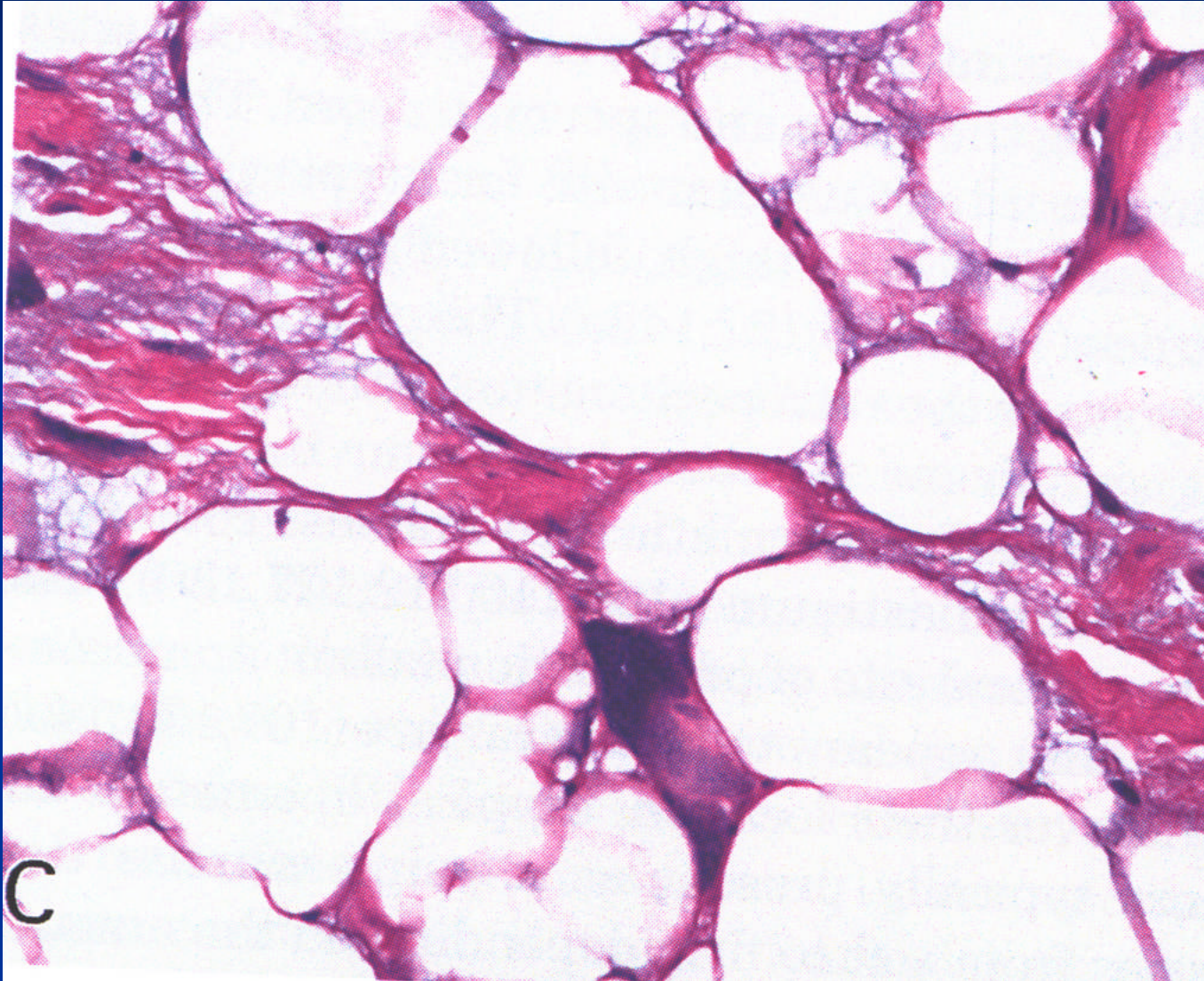
Lipoma



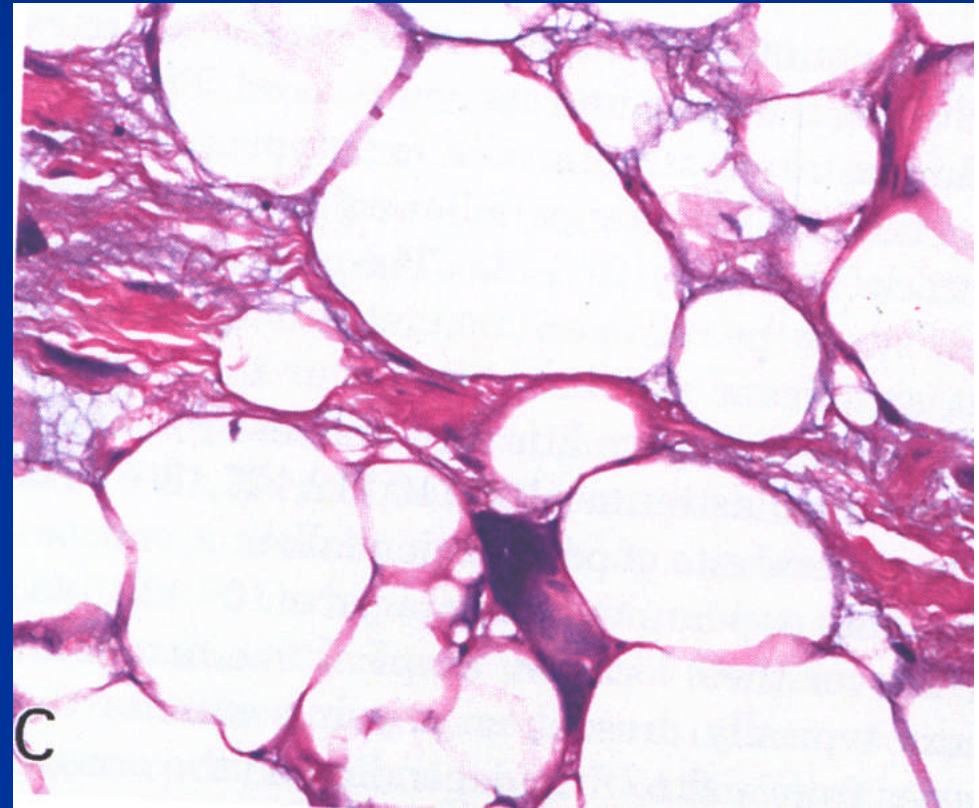
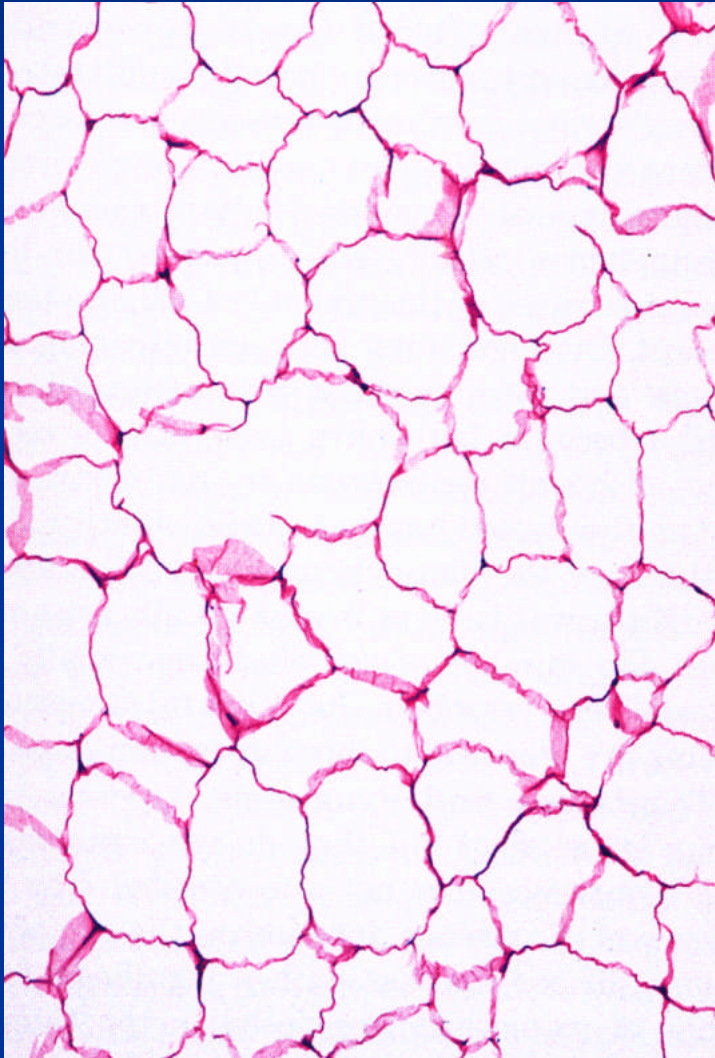


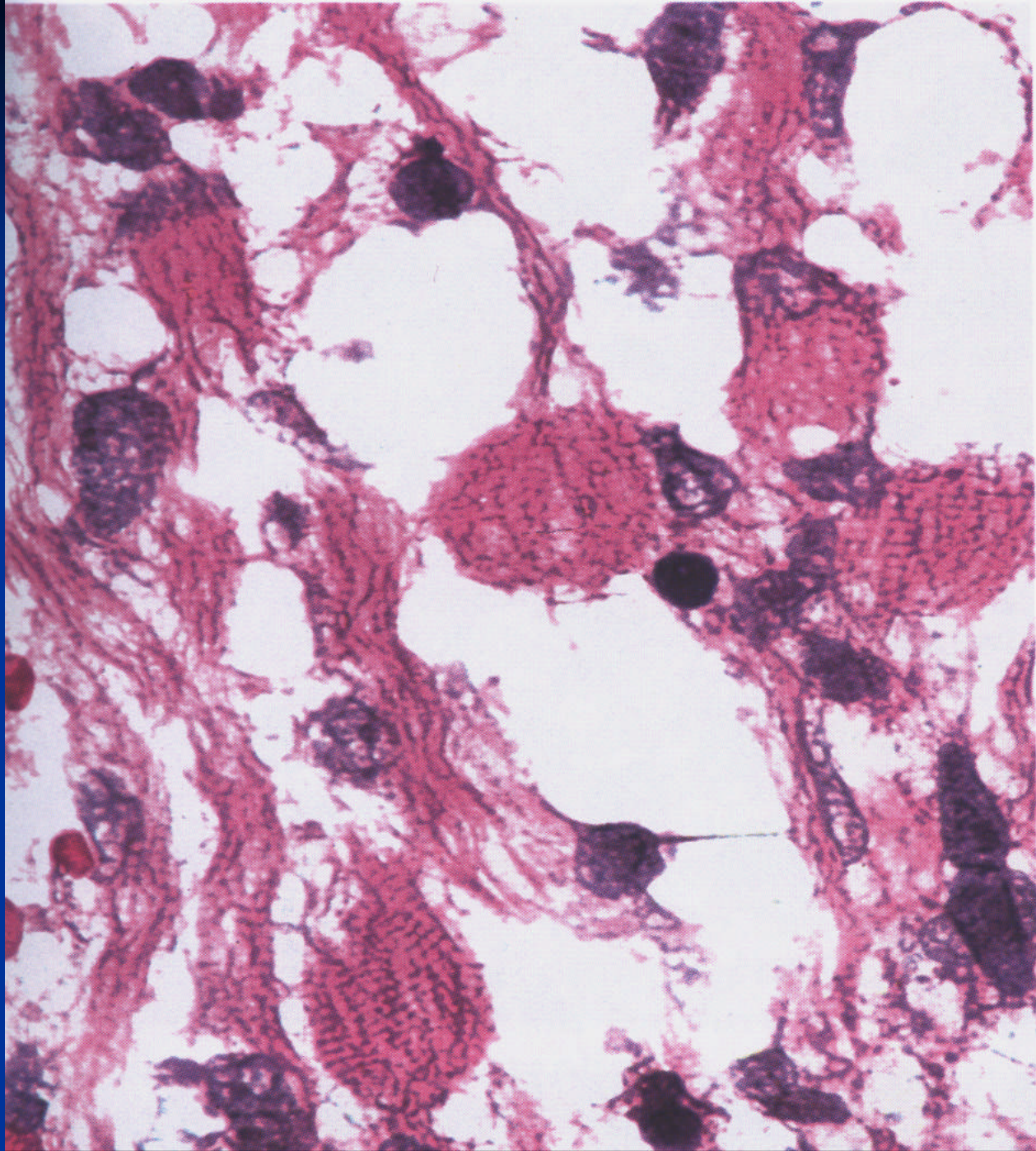
C

Well Differentiated Liposarcoma



Lipoma vs. Well Differentiated Liposarcoma





Rhabdomyosarcoma

- Striations consistent with Skeletal muscle origin

