

# 7

## Management of Abdominopelvic Sarcoma

Paul H. Sugarbaker

---

### OVERVIEW

The principles of management of all sarcomas that involve the abdominal and pelvic cavity are presented. The anatomic sites for the primary malignancy includes retroperitoneal sarcomas, pelvic side wall sarcomas, sarcomas arising from the abdominal viscera and sarcomas arising from the pelvic organs. All histologic types of sarcomas may be considered together when therapeutic options are being discussed. This presentation stresses surgical removal with an adequate margin of resection as the principal goal of management. The curative treatment of these cancers places great emphasis on the surgeon's knowledge of anatomy, technical skills, innovation and surgical courage. Systemic chemotherapy and radiotherapy have not shown reproducible efficacy. Complete clearance at the margins of resection and complete containment of tumor spillage remains the only reliable treatment option. Possible benefits of induction chemotherapy to reduce the size of advanced primary tumors prior to attempts at resection and intraperitoneal chemotherapy using heated cisplatin and doxorubicin for eradication of microscopic residual disease in the perioperative period are presented.

## INTRODUCTION

Sarcomas are unusual but not rare malignancies. They account for only 1% of adult solid tumors. These sarcomas appear most frequently between the fourth and sixth decades of life with a 2:1 male/female ratio. They can arise anywhere in the body with the lower extremity being the most common site. Incidence are as follows: lower extremities (46%), upper extremities (13%), retroperitoneum, pelvis and visceral (12%), truncal sarcomas (19%), and head and neck sarcomas (9%)<sup>1</sup> (Table 7.1). The presenting symptoms and signs of all sarcomas are nonspecific. With sarcomas involving the abdominal and pelvic cavity diagnosis is even more subtle because these tumors may progress for long time periods without causing overt symptoms.<sup>1</sup> Further confusion may arise when abdominal and pelvic sarcomas mimic the more common types of gastrointestinal malignancy. However, complete cancer resection of even large abdominal and pelvic sarcomas can be associated with long-term survival and even cure.

In the last decade treatment results with extremity soft-tissue sarcomas have improved dramatically. Both survival and quality-of-life benefits have occurred as a result of new treatment approaches based on multimodality treatment. Recently, patients with sarcomas that involve the abdominal or pelvic cavity have experienced improvements in therapy. Modern treatments require an aggressive pursuit of a multimodality approach involving meticulous surgery and regional chemotherapy. Further studies with innovative treatment options are required to achieve a better outcome with these malignancies.

The purpose of this chapter is to critically review the results of management of sarcomas that involve the abdominal and pelvic cavity and to make recommendations regarding current strategies for management.

## NATURAL HISTORY

### Retroperitoneal and Pelvic Sidewall Sarcomas versus Visceral Sarcomas

The natural history of retroperitoneal and pelvic sidewall sarcomas differs significantly from the more common abdominal and pelvic adenocarcinomas and from visceral sarcoma. These variations are important when planning treatment. A unique feature of many retroperitoneal and pelvic sidewall sarcomas concerns their large size at the time of diagnosis.<sup>1-4</sup> These fleshy tumors often push rather than invade into the surrounding structures. Their location deep within the body precludes palpation of the tumor mass early in the course of the disease. Consequently, these tumors often reach a large size prior to diagnosis (Table 7.2).

On the other hand, visceral sarcomas or adenocarcinomas are less likely to achieve this large size prior to diagnosis because they cause intestinal dysfunction.<sup>5</sup> The most common symptom is gastrointestinal bleeding (Table 7.3). Even though symptoms may arise earlier in the course of the disease, the anatomic location of these cancers is contiguous with the abdominal space. They frequently present with a regional disease process referred to as peritoneal sarcomatosis. For this reason, visceral (gastric, small bowel and colonic) sarcomas also carry a poor prognosis. A majority of gastrointestinal sarcomas (previously called leiomyosarcomas) are stromal sarcomas. The distribution of gastrointestinal stromal tumors is presented in Table 7.4.<sup>5</sup>

**Table 7.1** Soft-tissue sarcomas by site (percentages)

Head and neck	9
Trunk	19
Retroperitoneum, pelvic sidewall, visceral	12
Upper extremity	13
Lower extremity	46

**Table 7.2** Clinical presentation of retroperitoneal sarcomas (percentages)

Abdominal mass	80
Abdominal pain	60
Weight loss	35
Nausea, vomiting	20
Lower extremity edema	17
Urinary symptoms	3
Hypoglycemia	1

From ref. 4

**Table 7.3** Clinical presentation of gastrointestinal sarcomas (percentages)

Symptom	Gastric	Small bowel	Large bowel
Bleeding	45	54	28
Mass	42	23	65
Pain	36	57	43
Nausea/vomiting	33	–	–
Weight loss	6	15	–
Change bowel habit	–	15	48
Asymptomatic	11	–	–

From ref. 5.

**Table 7.4** Distribution of gastrointestinal stromal sarcoma (percentages)

Esophageal	5
Stomach	47
Small bowel	35
Colon	4
Rectum	17
<i>Total</i>	99

Modified from ref. 5.

### Tumor Biology of Hematogenous versus Lymphatic Dissemination

The tendency to disseminate to lymph nodes is markedly different for sarcomas than for adenocarcinomas. Epithelial cancers (squamous cell carcinomas and adenocarcinoma) metastasize through both the lymphatic route and the hematogenous route. In contrast, mesenchymal cancers frequently enter the blood stream, causing lung or liver metastases, but rarely result in lymph node metastases. Overall metastatic involvement of regional nodes is observed in only 13% of patients with soft-tissue sarcomas and in 7% of bone sarcomas at initial presentation.<sup>6</sup> Lymph node involvement by a sarcoma is unusual; when it occurs it indicates a dismal prognosis.

Direct evidence for the preferential hematogenous or lymphogenous dissemination of the two classes of tumors is based on numerous observations that regional lymph node metastases are more common in carcinomas than in sarcomas.<sup>7</sup> Although nodal metastasis do occur with sarcomas, they generate lymph node metastasis in a much smaller proportion of patients than do carcinomas. The explanation for this phenomenon from a tumor biology perspective has not yet been formulated. Are the observed differences in pattern of metastases due entirely to the properties of the cancer cells themselves? Could there be a greater destruction (metastatic inefficiency) of sarcomatous tumor emboli in lymphatics? Are the differences the consequence of a more intimate association of sarcomas than carcinomas with their vasculature? A new hypothesis is that the anatomic microenvironment of the primary tumor mass controls the proportion of tumors disseminating by hematogenous or by lymphatic routes.

Our knowledge of the intrinsic capabilities of sarcoma cells versus carcinoma cells to invade and then to metastasize is limited. We must accept that invasion must occur before metastases can occur. For both sarcomas and for carcinomas there must be sufficient invasion and sufficient progression for metastases to

result. From a histopathologic study of sarcomas and adenocarcinoma, both cancers have an intimate relationship with their blood supply. Breakdown of blood vessel walls and hemorrhage into tumor tissue may be a more impressive aspect of the histopathologic study of the sarcomas. Yet invasion of veins and venules is also a common pathologic finding with adenocarcinoma. The fact that both sarcomas and carcinomas disseminate via veins (hematogenous metastases) to distant capillary networks is not the issue. The discrepancy in patterns of dissemination concerns the relatively infrequent sarcomatous dissemination to lymph nodes.

Currently, no differences in the invasive capabilities of the primary tumor to penetrate capillary venules as opposed to lymphatic channels have been described. There is no reason to suspect that sarcomas selectively invade capillary venules versus lymphatic channels. Basic differences in the tumor biology of malignant mesenchymal versus malignant epithelial tumors do not explain the low rate of lymph node metastases observed for sarcomas.

Mesenchymal structures such as bone, striated muscle and smooth muscle have a very rich blood supply. It is not surprising that this blood supply is readily violated by tumor invasion, and venules are seeded by exfoliation of the cancerous process. However, mesenchymal structures have a severely limited lymphatic drainage system. From an evolutionary perspective the lymphatic system has evolved as a host defense against pathogens. Antigens gathered from epithelial (endodermal or ectodermal) structures are secured within the lymph nodes. Then through antigen processing, immunocyte selection and proliferation, a specific immune response is generated. There is a limited lymphatic supply for mesodermal structures because these soft tissues are rarely involved in host defense against invasion by pathogens. Lymphatic systems within the mesoderm are poorly developed, and what occurs may communicate less directly with the regional node groups that accompany the vasculature of the bowel or that drain to axilla or groin. The reduced lymphatic supply of bone, cartilage, muscle, fat and other mesenchymal tissues leads to a decreased exposure of lymphatic channels and lymph nodes to sarcoma metastases.

In summary, the hypothesis is that fewer lymph node metastases occur in patients with sarcomas because fewer lymphatic channels are at risk for invasion and embolization by the primary malignancy. [Table 7.5](#) relates the lymphatic supply of the tissue of origin of carcinomas and sarcomas to the incidence of lymph node metastases. Bone does not have lymphatic channels and therefore osteosarcoma rarely shows lymph node metastases. Rhabdomyosarcomas occur within

**Table 7.5** Relationship of lymphatic supply of the tissue of origin to the incidence of lymph node metastases

<i>Tumor type</i>	<i>Tissue of origin</i>	<i>Lymph supply tissue of origin (0–4+)</i>	<i>Lymph node metastases (%)</i>
Osteosarcoma	Bone	±	5
Liposarcoma	Fat	±	5
Gastrointestinal stromal tumor	Purkinje plexus	±	5
Rhabdomyosarcoma	Striated muscle	2+	20
Epithelioid sarcoma	Skin appendages	2+	20
Gastric carcinoma	Gastric epithelium	4+	50
Melanoma	Skin	4+	50

muscle. Muscle has an intermediate number of lymphatic channels and consequently there are moderate numbers of lymph nodes involved by this cancer. Epithelioid sarcomas involve lymph nodes relatively frequently. As predicted, these tumors are very common on the hands, involve the subcuticular dermis and have access to the rich lymphatic plexus at these sites. The higher incidence of metastases in epithelioid sarcomas is to be expected because of the rich lymphatic supply of the skin.

### Tumor Biology of Local–Regional Recurrence of Sarcoma

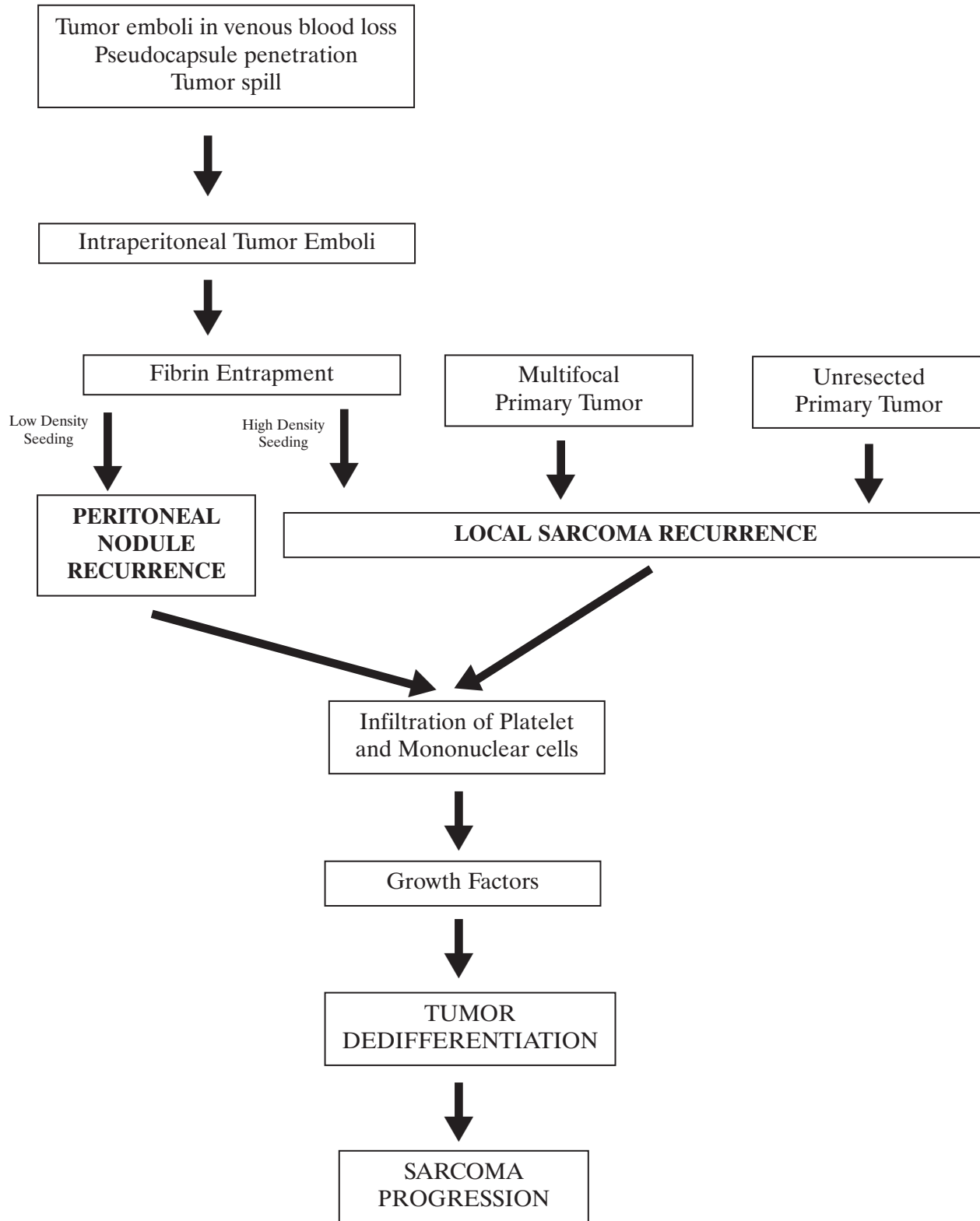
Another feature characteristic of the natural history of sarcomas involving the abdomen or pelvis is the alarmingly high local recurrence rate. The major site for surgical treatment failure is the same anatomic area from which the sarcoma was removed. Local recurrence is a component of treatment failure in nearly 100% of patients and is the only site of treatment failure in nearly 50% of patients.<sup>8,9</sup> One factor to be considered as a cause of local recurrence is a multifocal primary tumor (Figure 7.1). This phenomenon may be especially prominent with retroperitoneal liposarcoma. A second factor that will cause local recurrence is small foci of tumor (satellite nodules) present at a distance from the primary sarcoma. Narrow margins of resection may cause cancer persistence of these satellite sarcoma deposits within the resection site. With time these small foci of cancer will progress; also, their growth may also be promoted by the wound-healing process. However, in a majority of patients the high rate of local and regional recurrence comes about as a result of sarcoma seeding at the resection site and on peritoneal surfaces. Intraperitoneal sarcoma emboli may occur as a result of: (1) sarcoma penetration of the peritoneal layer with release of tumor emboli into the peritoneal space

preoperatively; (2) sarcoma emboli in venous blood that is lost into the abdomen at the time of surgery; (3) surgical trauma that causes a sarcoma spill into the abdominal cavity. These free intra-abdominal tumor emboli become entrapped in fibrinous exudate that floods the traumatized surfaces involved in the surgical dissection. This outpouring of serosanguinous fluid is the first phase of the wound-healing process. After the fibrin becomes organized into a coagulum, tumor cells are trapped at the wounded site. Platelets and mononuclear cells infiltrate the fibrinous matrix and release copious amounts of growth factors. These soluble mediators result in the proliferation of normal cells and modulate the healing process.

Recurrence at the resection site of a visceral sarcoma or retroperitoneal and pelvic sidewall sarcoma usually has a fusiform gross appearance. This characteristic progression along the narrow margins of resection is most frequently caused by high-density sarcoma seeding of intraperitoneal cancer cells. Sarcoma emboli are also likely to adhere at a lower density to traumatized peritoneal surfaces where they become covered by a fibrinous exudate. These peritoneal surface implants progress as individual sarcoma nodules that may be widely distributed throughout the abdomen and pelvis. In summary, high-density seeding of sarcoma emboli at the resection site results in local recurrence that has a fusiform gross appearance. Low-density seeding of sarcoma emboli on peritoneal surfaces causes sarcomatosis. These nodules will usually occur within adhesions because the sarcoma emboli were entrapped at that site by fibrin.

The growth factor stimulation as a result of wound healing results in accelerated local progression of the sarcoma emboli; also, further sarcoma dedifferentiation may result from the exposure of sarcoma cells to growth factors.<sup>10</sup> It is well established that the invasive potential of sarcomas may dramatically increase over time as a result of multiple reoperations.

### Mechanisms of Local Recurrence and Peritoneal Sarcomatosis



**Figure 7.1** Factors contributing to the high rate of local recurrence of sarcomas involving the abdominal and pelvic cavity.

### Tumor Biology of Peritoneal Sarcomatosis

After resection site recurrence the second most common site for abdominal or pelvic sarcoma recurrence are the peritoneal surfaces.<sup>8,9</sup> In some patients sarcoma seeding of the peritoneum will have occurred prior to resection of the primary tumor and is documented upon exploration of the abdomen. In the reoperative setting, peritoneal sarcomatosis results from tumor emboli in venous hemorrhage or from tumor spill that occurred with a prior sarcoma resection.<sup>11</sup> As implied from Figure 7.1, the distribution of sarcomatosis favors sites of prior peritoneal trauma. Sarcoma deposits are expected to grow out from single cancer cells trapped within abdominal adhesions. Of course, these adhesions develop with the resolution of fibrinous deposits that result from previous surgical trauma. The pathobiology of peritoneal implantation suggests that multiple factors control the distribution of cancer seeding within the abdomen and pelvis and that this is not a random event.<sup>12</sup>

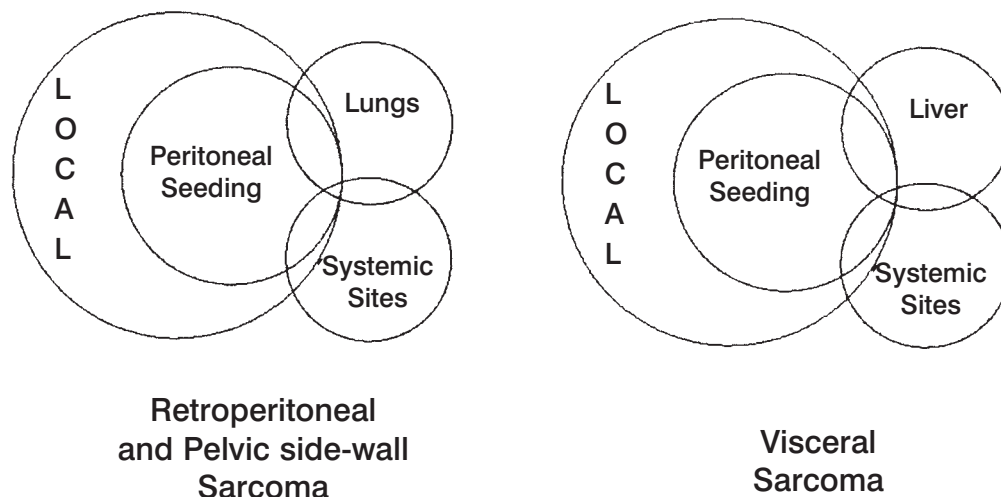
### Hematogenous Seeding to Lungs versus Liver

A difference in the intravascular dissemination of extremity sarcoma, retroperitoneal and pelvic sidewall sarcoma on the one hand and visceral sarcoma on the other needs to be noted. The first capillary bed draining the primary tumor is at highest risk for sarcoma metastasis.<sup>7</sup> For extremity sarcoma this is the lungs. For retroperitoneal and pelvic sidewall sarcoma the capillary bed at increased risk is also the lungs. For visceral sarcoma the venous blood draining the cancer is the portal system. With these malignancies the liver is by far the most common site for hematogenous metastases.

Figure 7.2 summarizes the patterns of treatment failure of sarcomas involving the abdomen and pelvis. The diagram emphasizes the high local recurrence rate and indicates that peritoneal seeding of sarcoma is a component of local recurrence. The first capillary bed draining retroperitoneal and pelvic sidewall sarcomas are the lungs; for visceral sarcomas this capillary bed is the liver. Neither group of sarcomas metastasizes to lymph nodes in a significant proportion of patients.

### TREATMENT

Enneking and colleagues have emphasized that there are two basic principles by which the treatments for sarcoma are directed.<sup>13</sup> First, one must determine as precisely as possible the anatomic location of the tumor. The second determinant for treatment of sarcoma concerns the biologic aggressiveness of the malignant process. With knowledge of these two determinants, cancer treatments can be selected that have the greatest likelihood of destroying the lesion with minimal compromise of normal function and quality of life. Low-grade lesions can be treated with a high expectation for cure even with minimal surgical margins. Also, one does not need to consider any therapies in addition to surgery for low-grade lesions excised with negative surgical margins. On the other hand, aggressive sarcomas must be expected to invade more deeply into the adjacent tissues, can produce satellite lesions in the surrounding soft tissue, and are capable of metastasizing via hematogenous routes to distant sites. Knowledge of the low biologic aggressiveness of a disease process in an advanced stage may encourage ultraradical regional treatments. At other times the futility of highly morbid therapies will become evident,



**Figure 7.2** Surgical treatment failures of abdominal and pelvic sarcomas.

and an aggressive lesion of large volume will be treated with conservatism because the clinician's judgement has determined that it is an incurable process.

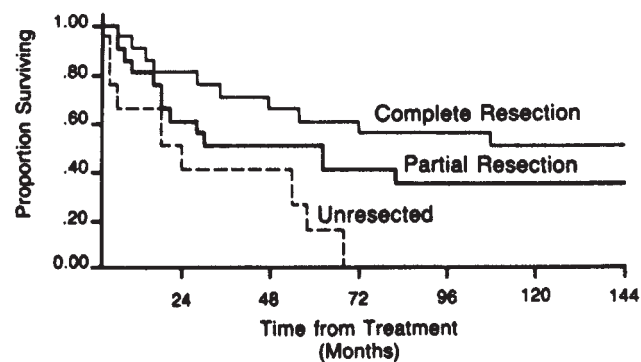
In dealing with abdominal and pelvic sarcomas one should realize that the routes for cancer dissemination are considerably different from those of adenocarcinomas. The adenocarcinomas require wide excision of the draining lymphatic tissues because lymph node metastases are common and the excision of involved nodes can result in cure. In contrast, lymph node involvement with abdominal and pelvic sarcoma is unusual, and if it does occur excision of the involved nodes will rarely result in long-term survival. Lymph node positivity in patients with sarcoma is almost always regarded as a signal of an unusually aggressive cancer, and it is highly probable that there has been systemic dissemination of disease. Consequently, in dealing with these sarcomas one attempts to remove the tumor with a generous margin of normal tissue, but wide lymph node dissections are unnecessary.<sup>14</sup>

Our comments will focus on the treatment option that have demonstrated efficacy in the management of abdominal and pelvic sarcomas. The first priority for treatment is surgery with negative margins of excision.<sup>15</sup> The results of surgical treatment alone are shown in [Figure 7.3](#). The more recent addition to abdominopelvic treatment options is intraperitoneal chemotherapy.<sup>16-18</sup> Radiotherapy has not shown survival benefits when used as an adjuvant with surgery<sup>19,20</sup>; also, aggressive systemic chemotherapy combined with surgery has no demonstrated survival benefits.<sup>21</sup>

Surgical removal with a clear margin is the treatment option indicated for all abdominal and pelvic sarcomas. This approach will test the surgeon's ability to exercise all those principles of surgery which allow large operations to be performed with minimal morbidity and mortality. Successful surgical treatments demand optimal exposure, skill in dealing with intestinal adhesions, meticulous hemostasis that is maintained throughout the procedure, a thorough knowledge of anatomy, a plan of attack on sarcomas at difficult anatomic sites and experience in reconstruction. The surgeon must be knowledgeable regarding those structures that can be sacrificed because their involvement by tumor, and those structures that must be preserved even if there is residual sarcoma.

## SURGICAL APPROACH

At this point in time the first priority for treatment for abdominal and pelvic sarcoma that is associated with long-term survival is complete surgical removal of the cancer with adequate margins. The cardinal principle of surgery is en-bloc excision of the primary tumor plus involved adjacent organs and tissues with dissection



**Figure 7.3** Actuarial survival for retroperitoneal sarcomas. Only complete resection achieves any hope for long-term survival. The expected survival for complete resection shows approximately 50% survival at 5 years. Unresected patients have a uniformly poor prognosis. Some patients with positive margins of resection who have grade I or less sarcomas will survive long term; often these patients live with gradually progressive cancer and require multiple resections over a long time period. From Jaques DP, Coit DG, Brennan MF. Soft tissue of the retroperitoneum. In: Shiu MH, Brennan MF, editors. *Surgical Management of Soft Tissue Sarcomas*. Philadelphia: Lea & Febiger; 1989:166.

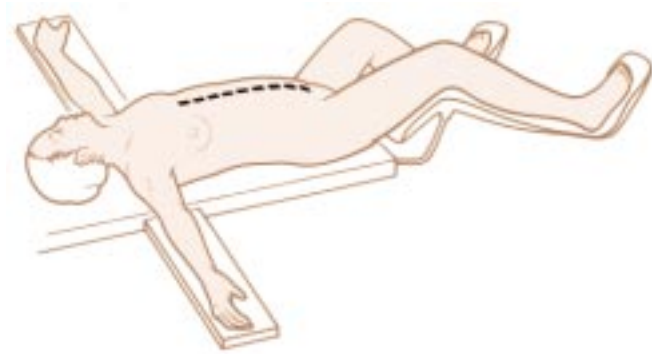
well clear of the sarcoma pseudocapsule. The major factor determining resectability is the extent of invasion to vital structures rather than the size of the tumor. Although preoperative radiological evaluation is essential, operability can be evaluated definitively only by laparotomy. Even with adherence of tumor to vital structures, with meticulous dissection most sarcomas are resectable. The surgeon must always remember that inadequate clearance resulting in local recurrence and inadequate containment resulting in sarcoma seeding are the major causes of treatment failure. Tumor debulking may occasionally be beneficial in a palliative way in cases where complete resection is impossible. However, palliative surgery for abdominal and pelvic sarcoma carries a high morbidity and limited progression-free survival and should be undertaken with great caution.

## Patient Position and Exposure

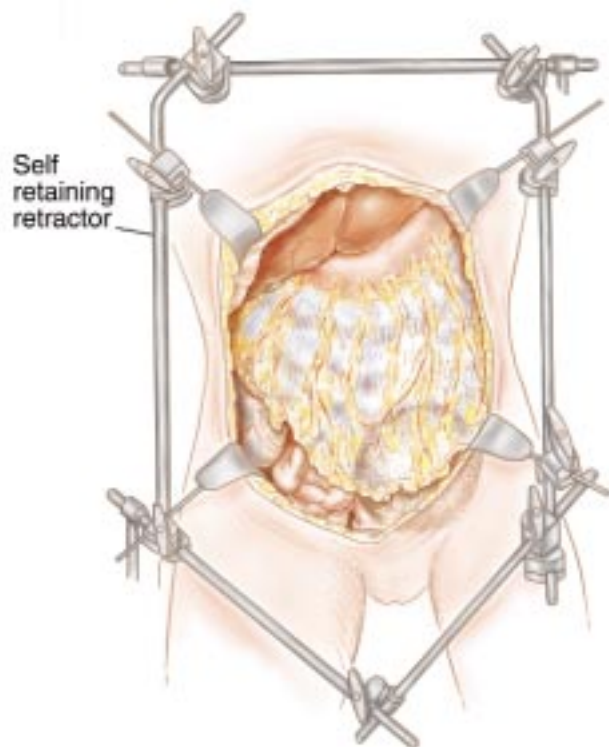
One must be prepared for a major surgical event with wide abdominal and pelvic exposure in order to achieve the greatest incidence of success. In many patients both abdominal and pelvic dissections must be performed. Positioning of the patients so that surgery through the perineum is possible is often indicated ([Figure 7.4](#)). Long abdominal incisions from xiphoid to pubis are usually not required. Self-retracting retractors that can expose the entire abdomen and pelvis are necessary

(Figure 7.5). Skin preparation so that a thoraco-abdominal or an abdomino-inguinal incision is frequently required (Figure 7.6).

One must always be cognizant of the surgeon's needs to think three-dimensionally in approaching these deep-seated malignancies. This helps to avoid inadvertent damage to vital structures. In order to build within the surgeon's mind a three-dimensional appreciation of the vital structures in the abdomen, one should always strive to open the abdomen and set up



**Figure 7.4** Patient position for surgical treatment of abdominal and pelvic sarcoma.

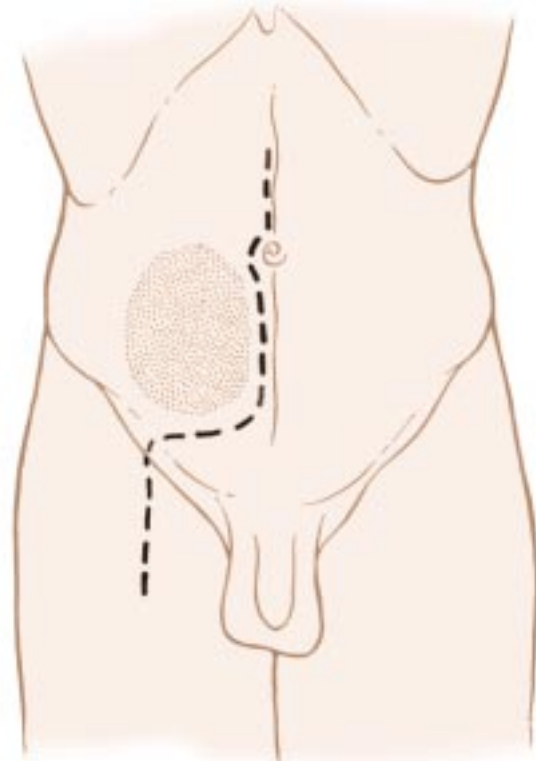


**Figure 7.5** Exposure for abdominal and pelvic surgery using a self-retaining retractor.

the self-retaining retractor system in the same way. This means that vital structures such as the left common iliac vein, the ureters, the left gastric artery, and the common bile duct have a particular spatial orientation within the surgeon's mind. A standard exposure of the abdominal cavity through a midline incision with uniform placement of the self-retaining retractor can assist the surgeon in his goal of avoiding hemorrhage and inadvertent damage to vital structures.

### Reoperative Surgery

Frequently, in a tertiary referral center, one sees patients with abdominal and pelvic sarcomas after one or more prior attempts at the surgical removal of the cancer. In these patients, removal of the recurrent sarcoma may be delayed many hours because exposure of the tumor mass may be difficult and time-consuming. Extensive abdominal adhesions, tumor that has regrown within scar tissue, fibrosis that accompanies the local recurrence of cancer, and alterations of normal anatomy by prior reconstructions may require patience and advanced technical skills to bring about the complete exposure of the malignant process.



**Figure 7.6** Abdomino-inguinal incision used for resection of sarcomas on the pelvic side wall.



### Always Open Old Incisions

Even though opening an old incision is difficult, and may result in seromuscular tears of small or large bowel, rarely should a new incision be made into the abdomen in performing reoperative surgery. New incisions will cause additional adhesions and may severely jeopardize primary wound healing of the abdominal wall. It is usually necessary to excise old incisions because they often contain recurrent sarcoma embedded within the scar tissue. The surgeon routinely plans to completely excise the old scar tissue in the skin, subcutaneous tissue and in fascia as the abdominal wall is opened.

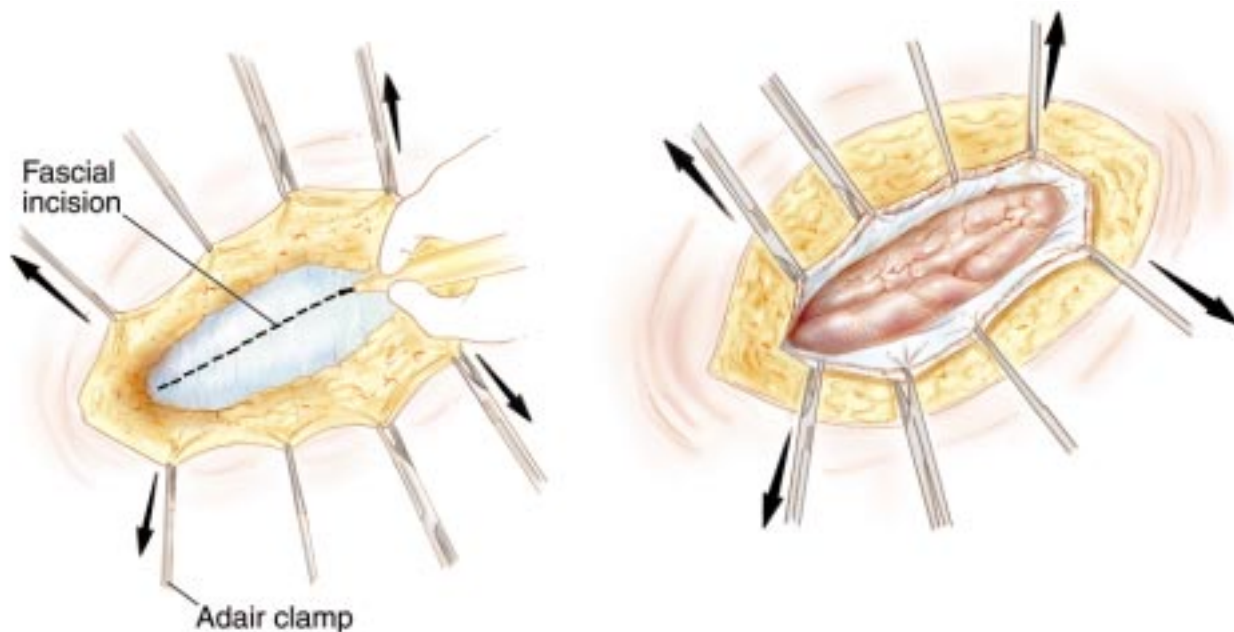
### Safe Entry into the Abdominal Cavity

Opening the abdomen without damage to bowels in a patient who has had several prior surgical procedures is difficult and time-consuming. One should realize that entering an abdomen with multiple adhesions requires an *elevation* of the abdominal wall in order to avoid inadvertent small bowel or large bowel enterotomy. Clamps should be used to apply strong upward traction on the skin or abdominal fascia as the abdomen is entered (Figure 7.7). Pushing down in order to spread the scar that makes up the old abdominal incision is to be avoided.

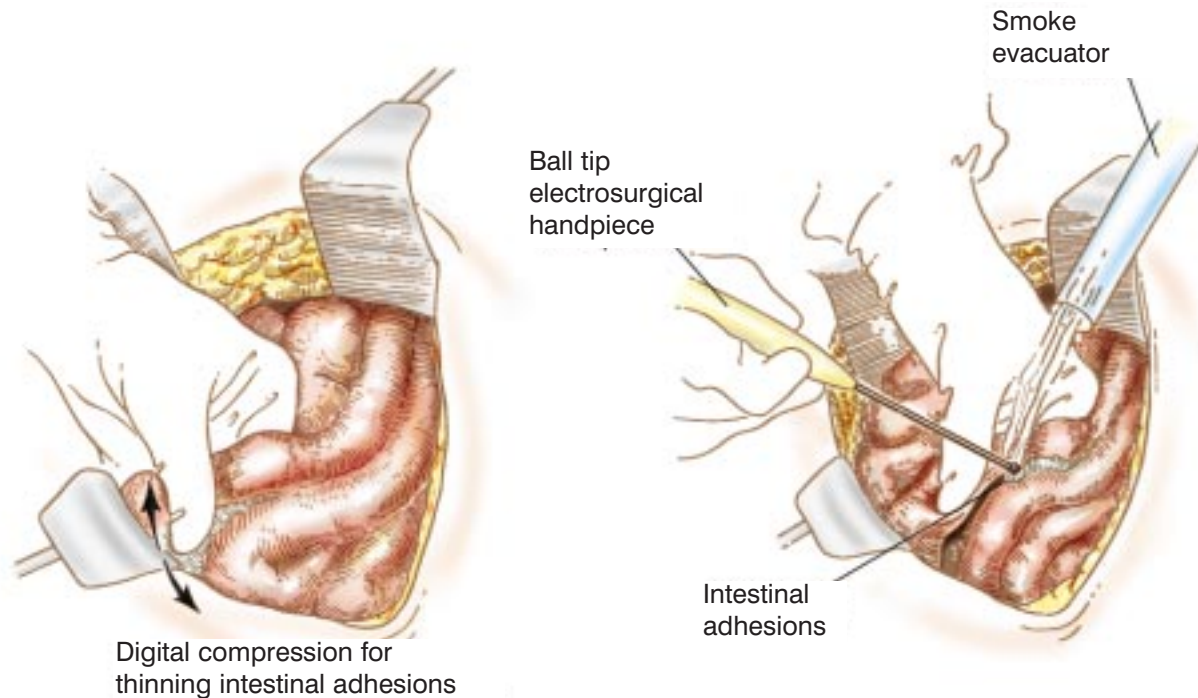
### Surgical Approach to Intra-abdominal Adhesions

Small bowel adhesions present a special problem in management. Small bowel enterotomy resulting in fistula formation after reoperative procedures is a major problem that will be encountered. The experienced surgeon will adhere to several principles in lysing small bowel adhesions:

1. Tactile sense should be added to visual perceptions in the dissection of the adhesions (Figure 7.8). This requires the use of ball-tipped electrosurgery. Fibrous adhesions and fat are morseled between the thumb and index finger of the nondominant hand. Considerable pressure may need to be applied. Ball-tip electrosurgery electroevaporates (carbonizes) residual tissue on the small bowel surface as this tissue is splayed out on the middle finger.
2. Absolute hemostasis must be maintained at all times in dissecting small bowel adhesions. One must realize that any bleeding that occurs while dissecting a small bowel adhesion means the surgeon is in an improper plane. Fat with blood vessels within should be divided in the abdomen and pelvis only when the surgeon is knowingly transecting omentum, transecting retroperitoneal structures, or transecting perirectal fat. Bleeding that is encountered while taking down intestinal adhesions indicates that the surgeon is dissecting within the wrong plane,



**Figure 7.7** Opening the old abdominal incision by pulling upward on skin (left) or fascial edges (right) using Adair clamps.



**Figure 7.8** Dividing abdominal adhesions. Pressure between thumb and index finger is used to thin out the adhesion between two loops of small bowel. Ball-tip electro-surgery is used to divide and evaporate the adhesion (right). Division of adherent tissue on small bowel surfaces on the middle finger of the nondominant hand adds tactile to visual perceptions (left).

usually the small or large bowel mesentery, and this should be avoided.

3. Large-volume saline irrigation should be used frequently. Even small amounts of blood can interfere with adequate visualization of subtle tissue planes for further dissection. If absolute hemostasis is combined with frequent irrigation the translucent nature of the tissues will be preserved throughout the dissection and inadvertent damage to vital structures or to blood vessels should not occur.
4. Fat or scar tissue should never be left behind on small bowel surfaces. This scar tissue may frequently contain entrapped tumor cells. Also, if miscellaneous tissues remain on bowel surfaces, confusion may arise in subsequent dissection. There is only one small bowel surface that contains fat on its anti-mesenteric border, and this is in the terminal ileum.
5. Strong traction should be maintained at the dissection point of the adhesion. The small bowel should be splayed out (broad traction) so that the plane of dissection for the ball-tipped electro-surgical handpiece is clearly visualized.
6. Complete removal is the rule when dealing with intra-abdominal adhesions. Generally, all adhesions must be lysed and then resected. The complete anatomy of the large and small bowel is visualized

prior to a decision regarding curative versus palliative sarcoma resection.

In summary, in the reoperative setting opening old abdominal incisions and the dissection of abdominal adhesions without damage to the bowel must be mastered by the sarcoma surgeon. Use of electro-surgery with the ball-tip is indicated because it allows tactile sensations to be added to visual perceptions in the dissection. This makes the process safer and certainly expedites the opening of the abdomen, lysis of intra-abdominal adhesions and clarification of the dissection required for definitive excision of the recurrent sarcoma.

### Exploring for Sarcomatosis

In performing surgery on patients with retroperitoneal or visceral sarcoma, the complete (both visceral and parietal) abdominal and pelvic surfaces must be visually inspected to look for tumor deposits. This means that all abdominal adhesions must be lysed as part of the complete exploration. The omentum, likewise, must be dissected free and inspected to determine whether it contains sarcoma nodules. The problem of sarcomatosis is of course more important in patients undergoing reoperative surgery for intra-abdominal sarcoma. If

there was tumor spillage at the time of earlier surgery, then sarcomatosis is expected to be discovered with the abdominal exploration.

If the patient can be made disease-free in the presence of sarcoma nodules, then the benefits of intraperitoneal chemotherapy should be considered. The adhesions are completely separated and resected as part of the oncologic procedure to allow uniform distribution of chemotherapy. From a purely surgical point of view, complete lysis and resection of all abdominal adhesions is not an absolute requirement for safe resection of abdominal and pelvic sarcoma. From an oncologic perspective, complete lysis and resection of all adhesions followed by peri-operative intraperitoneal chemotherapy may be an absolute requirement for the prevention of subsequent sarcomatosis.

### Centripetal Dissection

Centripetal dissection requires wide continued exposure of the abdomen and pelvis as provided by a long midline abdominal incision and self-retaining retractors. Repeated dissection in a circular fashion around the principal tumor mass at multiple sites is the goal. Dissection continues at a particular site only if there is clear visualization of the operative field. The surgeon should repeatedly circle the sarcoma as the laborer would repeatedly circle a tree stump that is being removed with shovel and axe. The "stump analogy" suggests that the surgeon never attempts a definitive dissection in one area. He always completes the superficial dissections before the more difficult deep ones are attempted. The axiom is always "Do what is easy first." He moves around and around the cancer, working only where he has good exposure. Criteria for continued dissection at a particular anatomic site include: (1) no loss of blood; (2) small chance for damage to vital structures; (3) dissection proceedings with a clear margin. If any of these criteria for safe progress are not met, the surgeon should move his dissection to a different area. The tumor mass is generally circled many times prior to delivering the intact specimen. In summary, centripetal dissection avoids at all times major hemorrhage or damage to vital structures by limiting dissection to areas that allow clear visualization of the operative field. A circular pattern of progressively deeper dissection results from this approach.

### Avoid Trauma to the Vasculature of the Sarcoma Capsule

In the removal of abdominal and pelvic sarcomas one must always be aware of possible major hemorrhage

from surface vasculature of the sarcoma. Blood vessels in the sarcoma pseudocapsule are large, thin-walled, easily traumatized and difficult to control once bleeding has occurred. Once one disrupts the tumor vasculature, bleeding is likely to be brisk and difficult. One should dissect away from the tumor in normal tissues as much as possible. If dissection of the tumor itself is required, this should be done only after all other dissection is completed.

### Maintain Hemostasis throughout the Procedure

One must always pay continuous attention to hemostasis, because inadequate hemostasis interferes with subsequent exposure. Moreover, blood in the operative field obscures the identification of additional bleeding points. Hemostasis must be achieved with electrocoagulation, ligatures, or clips as the dissection proceeds. The translucent nature of the tissues within the surgical field can be maintained by frequent irrigation and meticulous hemostasis.

### Use of Peritonectomy Procedures

Often in the reoperative setting or work with a retroperitoneal sarcoma the surgeon must be willing to dissect in a preperitoneal or retroperitoneal plane rather than moving through the peritoneal cavity itself. Peritonectomy procedures go beneath scar tissue to achieve a negative margin of resection.<sup>22</sup> Sarcoma recurrent at a resection site will almost always be beneath the peritoneal surface. An effective way to safely approach these recurrent tumor masses is by going beneath the peritoneal layer into a deeper plane away from the tumor mass (Figure 7.9). The concept of peritonectomy should be pursued in the reoperative setting, in dealing with sarcomatosis, with recurrence at the resection site, and for retroperitoneal sarcoma being resected for the first time.

### Utilize "Piecemeal" Excision

Often freeing-up of a tumor mass will progressively obscure the plane of dissection. This will compromise the safety of subsequent dissection because of inadequate visualization, inadequate hemostasis, or an unnecessarily narrow margin of excision. Large tumor masses, especially those in the pelvis, will become more and more difficult to extirpate as the dissection proceeds. As the anatomic site for further dissection is more deeply obscured by a large mass of tumor, the procedure becomes more dangerous. If the tumor mass remains intact, dangerous blunt dissection may be required to continue its removal.

In this situation, piecemeal excision of the sarcoma is an important part of the operative procedure. Superficial components of the tumor may be removed prior to continuing the dissection of a deeper aspect of the tumor. Piecemeal excision using an electro-surgical loop on pure cut is usually the best way to remove portions of the tumor prior to its complete resection (Figure 7.10).

Piecemeal excision of a large tumor mass is much safer for the patient than is dissection with inadequate visualization. However, one must do everything possible to guard against the intra-abdominal dissemination of sarcoma cells. The surrounding structures must be protected with laparotomy pads and towels. The electro-surgical loop at high voltage on pure cut removes fillets of tumor with minimal spillage of viable malignant cells. After each level of tumor is resected, thorough irrigation of the operative field is required. Before the procedure is completed intraperitoneal chemotherapy is indicated.

#### Guard against Frustration Toward the End of a Difficult Resection

The surgeon should realize that the greatest number of surgical misadventures occur just a few minutes prior to final removal of the tumor mass. Special care should be taken when the tumor mass is almost out. The final dissection is often performed over a large mass of sarcoma that results in reduced visualization. One must avoid damage to a vital structure such as a ureter or damage to a major blood vessel which results in

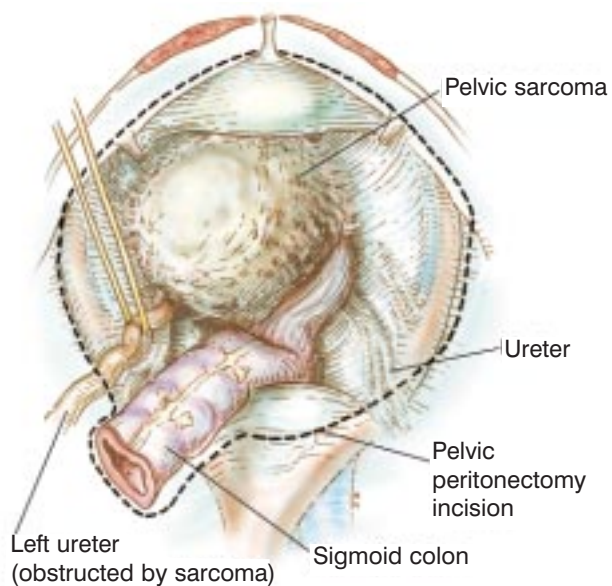
profuse hemorrhage. Many serious intraoperative errors in cancer resection occur just prior to the removal of a large specimen.

#### Transplants of Primary Vascularized Tissue

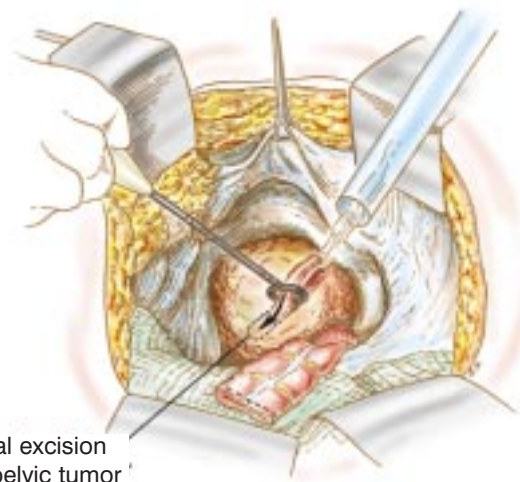
Within the abdomen there are two prominent sources of primarily vascularized tissue. These are the omentum and the rectus abdominus muscles. The rectus abdominus muscles based on the deep inferior epigastric vessels can be harvested either bilaterally or unilaterally (Figure 7.11). The omentum can be harvested so that its gastroepiploic pedicle is based on the left gastroepiploic vessels and the short gastric vessels on the left side of the stomach. More frequently the omental pedicle is based on the right side from the right gastroepiploic vessels (Figure 7.12). In both instances the numerous branches of the gastroepiploic vessels to the greater curvature are ligated and the gastroepiploic arcade is preserved. These large masses of freshly vascularized tissue can be used in four ways.

The primarily vascularized tissue is frequently used to fill empty space in the abdomen or pelvis. This tissue is often placed into an abdominal gutter from which a kidney was removed or into the pelvis. This greatly facilitates healing and serves to decrease the incidence of fluid accumulation and possible pelvic sepsis. These tissue transplants greatly improve the healing at a site of prior radiotherapy.

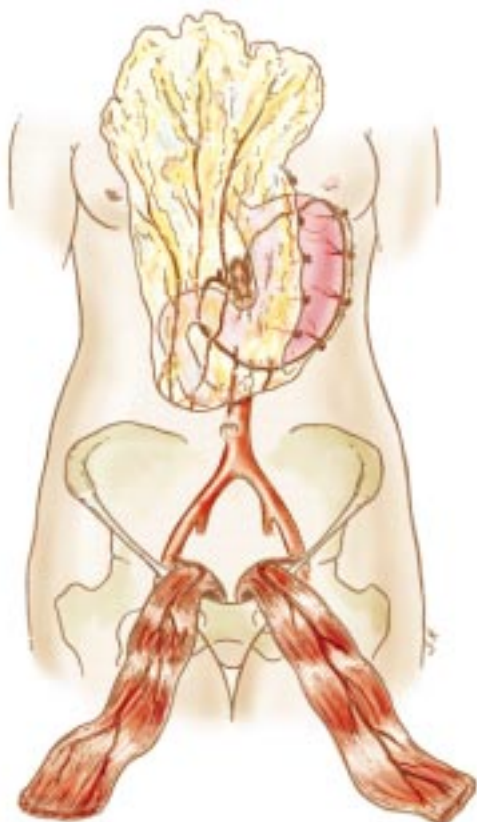
A second use of pedicle flaps is to create a new abdominopelvic partition. This tissue barrier does not



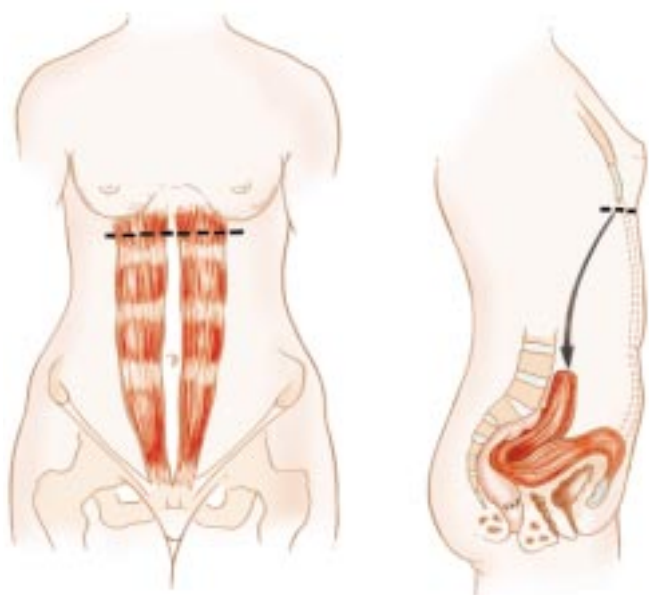
**Figure 7.9** Pelvic peritonectomy is useful to completely excise a pelvic sarcoma, especially if there is sarcomatosis or recurrent tumor at the resection site.



**Figure 7.10** Piecemeal excision of abdominal or pelvic sarcoma. (A) Electroevaporative surgery with a ball tip is used to define the margin of excision. (B) Loop electro-surgery is used to resect the sarcoma mass piecemeal. (C) Even in the depths of the pelvis with a large sarcoma the visualization can be excellent.



**Figure 7.11** Primarily vascularized tissue transplants may be harvested from three sources for abdominal and pelvic surgery. They are the greater omentum, right rectus muscle and left rectus muscle.

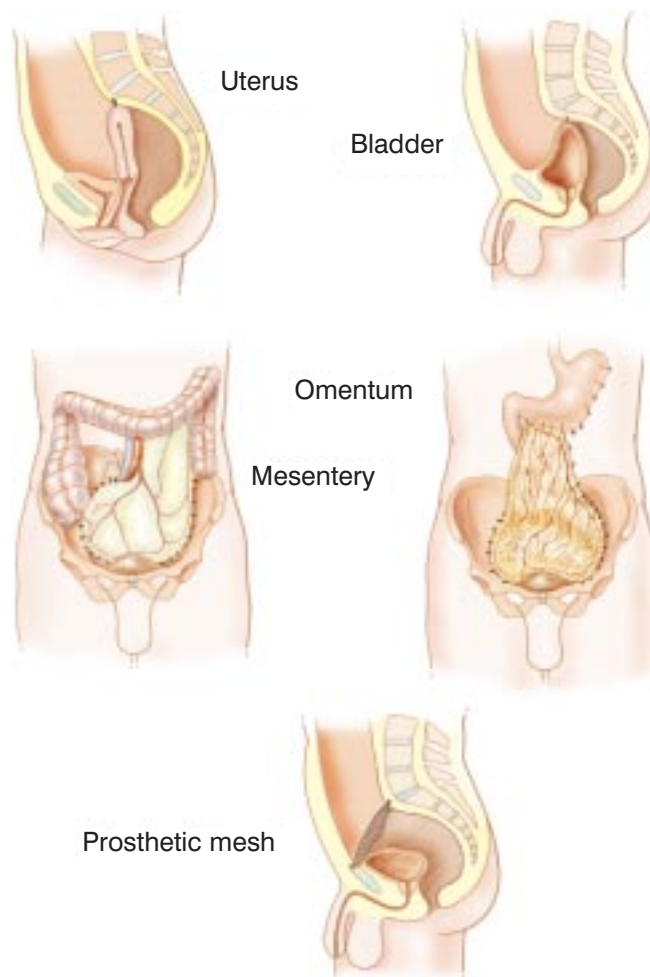


**Figure 7.12** Primarily vascularized tissue transplant of rectus abdominis muscles. These are especially needed if the patient has had prior radiation therapy to the pelvis.

allow small bowel to become entrapped in the pelvis, resulting in subsequent intestinal obstruction or fistulization. Other sources of tissue can also be used in construction of an abdominopelvic partition. Bladder, uterus, leaf of sigmoid mesentery and prosthetic materials have been used successfully (Figure 7.13).

A third common need for these primarily vascularized tissue transplants is coverage of cancerous tissues that have been incompletely excised. Positive margins of sarcoma resection are walled off from the remainder of the abdominal or pelvic cavity by the primarily vascularized tissue transplant. This will greatly improve long-term function by preventing cancerous invasion of the small bowel and the resultant intestinal obstruction.

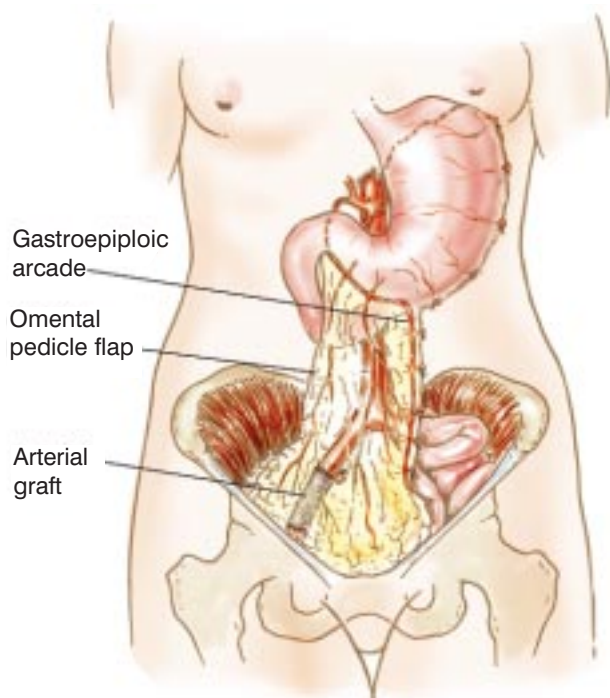
A fourth use of these primarily vascularized tissue transplants is to cover vascular grafts, reconstructed vessels, urinary tract reconstruction, or repair the bladder. Omentum or muscle draped over an exposed vascular graft, vascular anastomosis or repaired ureter and protect against false aneurysm, graft infection, and suture line disruption with late blow out (Figure 7.14).



**Figure 7.13** Methods to construct abdominopelvic partitions.

### Induction Chemotherapy

External beam radiation therapy and adjuvant chemotherapy have failed to show worthy survival benefits for intra-abdominal sarcoma when added onto surgery. However, induction chemotherapy treatments designed to shrink large retroperitoneal or visceral tumors prior to their surgical removal is a treatment option applicable to selected patients (Table 7.6). Whenever there is a major single artery supplying the sarcoma, induction chemotherapy is used intra-arterially to maximize responses in the primary tumor itself. The goal of these treatment strategies is to shrink the tumor and reduce its aggressive behavior for a defined time period. After completion of induction chemotherapy excision of the malignant process may be possible



**Figure 7.14** Omental pedicle flap used to cover common iliac artery reconstruction.

whereas surgery alone would have been unsuccessful. The current treatment plan utilizes three preoperative cycles of ifosfamide and systemic doxorubicin prior to surgical resection of the sarcoma.

### Peritonectomy and Intraperitoneal Chemotherapy

Another strategy of great value in selected patients concerns the treatment and prevention of resection site recurrence and peritoneal sarcomatosis. Heated intraperitoneal chemotherapy employed intraoperatively is effective in reducing the high incidence of resection site recurrence and sarcomatosis that often occurs after primary sarcoma resection. Elimination of sarcoma seeding by peritonectomy and the resulting improvement in local-regional control may have an effect on the survival of patients with sarcomatosis or with local recurrence. Standardized orders for heated intraoperative intraperitoneal chemotherapy are shown in Table 7.7. Figure 7.15 shows the tubes and drains required to deliver early postoperative intraperitoneal chemotherapy. Figure 7.16 shows the methodology for safe intraoperative delivery of heated cisplatin and doxorubicin via the intraperitoneal route.

The indications for perioperative intraperitoneal chemotherapy are shown in Table 7.8. Tumor spillage should in all instances be accompanied by heated intraoperative intraperitoneal chemotherapy. Sugarbaker and colleagues, and Eroglu and colleagues, have used intraperitoneal cisplatin and doxorubicin.<sup>16,17</sup> Other groups have explored the use of mitoxantrone.<sup>18</sup> It should be emphasized that the prevention of peritoneal sarcomatosis is a surgeon's responsibility. Treatment of this component of sarcoma cannot be delayed until later systemic chemotherapy treatment by the medical oncologist. Once sarcoma cells are embedded in scar tissue they are not treatable by any technique. Other indications for intraoperative intraperitoneal chemotherapy include small-volume peritoneal sarcomatosis; small-volume residual disease on peritoneal surfaces or at the margins of resection; and use in a randomized control trial in patients who have a complete excision of

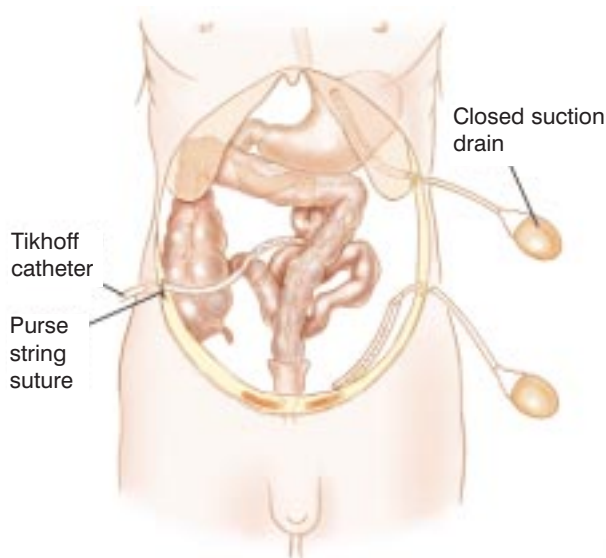
**Table 7.6** Standardized orders for induction chemotherapy of abdominal and pelvic sarcoma

#### Induction ifosfamide and doxorubicin

1. Ifosfamide \_\_ mg ( $2.25 \text{ gm/m}^2$ ) intravenous for 4 consecutive days in 250 cc 5% dextrose solution via intravenous catheter as 2-hour infusion. Repeat every 3 weeks.
2. Doxorubicin \_\_ mg ( $75 \text{ mg/m}^2$  per day) in 500 cc 5% dextrose in water to run by continuous intravenous catheter infusion through a central vein over 72 hours.
3. 25% dose reduction for both ifosfamide and doxorubicin for age greater than 65 or prior radiation therapy.
4. All cycles of chemotherapy are supplemented with G-CSF support at  $5 \mu\text{g/kg}$  subcutaneous, starting 24 hours after chemotherapy is finished.

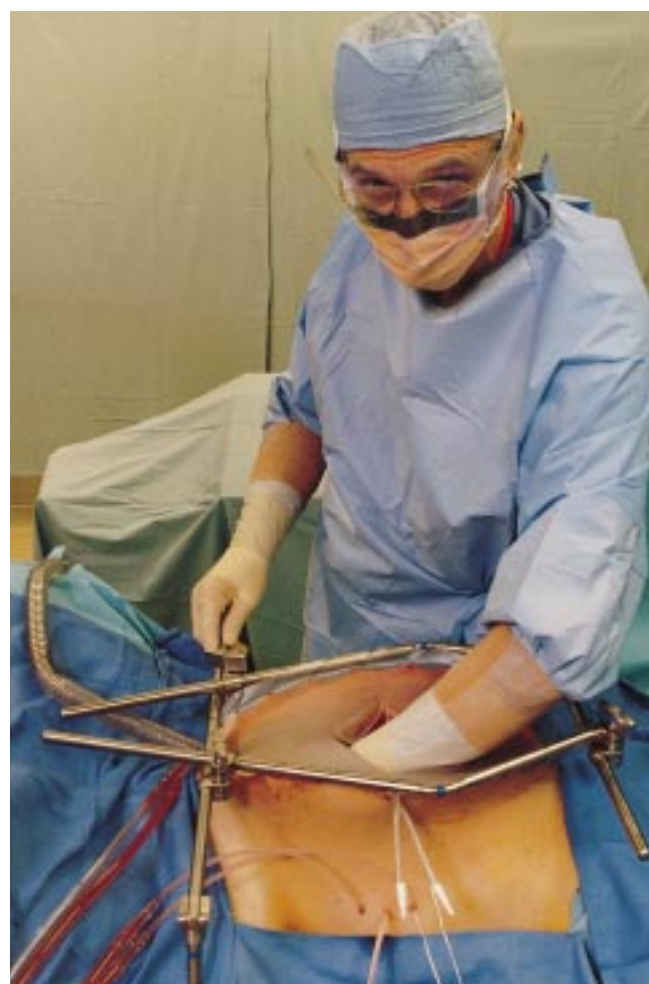**Table 7.7** Cisplatin and doxorubicin orders for heated intraoperative intraperitoneal chemotherapy

1. For gastric and ovarian cancer, mesothelioma and sarcoma; add cisplatin \_\_ mg to 2 liters of 1.5% dextrose peritoneal dialysis solution. Dose of cisplatin 50 mg/m<sup>2</sup>.
2. Add doxorubicin \_\_ mg to same 2 liters of 1.5% dextrose peritoneal dialysis solution. Dose of doxorubicin 15 mg/m<sup>2</sup>.
3. Use 33% dose reduction for heavy prior chemotherapy, marginal renal function, age greater than 60, extensive intraoperative trauma to small bowel surfaces, or prior radiotherapy.
4. Send 1 liter of 1.5% dextrose peritoneal dialysis solution to test the perfusion circuit.
5. Send the above to the operating room at \_\_ o'clock.

**Figure 7.15** Tubes and drains used for perioperative intraperitoneal chemotherapy.

sarcoma in order to identify a surgical adjuvant treatment.

The results of treatment of patients with recurrent sarcoma have been tested in phase II studies using reoperative surgery plus intraperitoneal chemotherapy (Table 7.9). In all four of these studies the surgery for recurrent sarcoma was designed to completely resect cancer. The treatments with intraperitoneal chemotherapy varied greatly. Berthet and colleagues, and Eroglu and colleagues, used heated intraoperative chemotherapy.<sup>16,17</sup> Karakousis and colleagues, and Eilber and colleagues, used intraperitoneal chemotherapy in a delayed manner after wound healing had occurred.<sup>18,23</sup> The results of the perioperative intraoperative chemotherapy suggested superior results when compared to the delayed intraperitoneal chemotherapy. Figure 7.17 shows the statistically significant difference

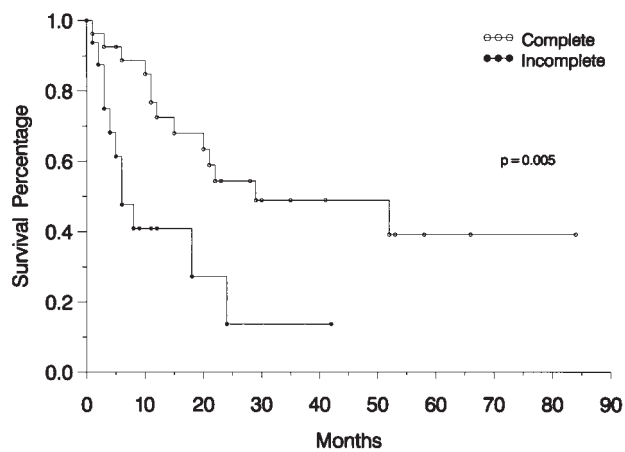
**Figure 7.16** Heated intraoperative intraperitoneal chemotherapy for sarcomatosis following cytoreduction and for patients with a high risk for microscopic residual disease.

**Table 7.8** Indications for heated intraoperative intraperitoneal chemotherapy

1. Rupture or perforated sarcoma.
2. Tumor spillage.
3. Small-volume peritoneal sarcomatosis after resection of primary sarcoma and peritonectomy of sarcomatosis.
4. Small-volume local residual disease.
5. After complete cytoreduction of sarcomatosis or sarcoma recurrence.
6. Clinical trials to test adjuvant treatments.

**Table 7.9** Adjuvant regional chemotherapy for abdominopelvic sarcoma: four nonrandomized series<sup>16,17,18,23</sup>

Series	Tumor type at presentation	Chemotherapy regimen	Mean follow-up time (range)	5 year overall survival (median)	Outcomes	Recurrence (%)
Karakousis <i>et al.</i> , 28 patients	Recurrent abdominal sarcoma	Postoperative cisplatin	17 months	7%	2 NED, 26 DOD, 1 DOC	93
Sugarbaker <i>et al.</i> , 43 patients	Recurrent abdomino-pelvic sarcoma	Perioperative hyperthermic cisplatin and/or doxorubicin	20 months (4–84)	39%	9 NED, 23 DOD, 10 AWD, 1DOC	74
Eilber <i>et al.</i> , 54 patients	Recurrent abdomino-pelvic sarcoma	Postoperative mitoxantrone	26 months (2–98)	31%	9 NED, 35 DOD, 10 AWD	83
Eroglu <i>et al.</i> , 33 patients	Primary or recurrent retroperitoneal sarcoma	Intraoperative hyperthermic abdominal perfusion, cisplatin and doxorubicin	57 months (28–95)	49% (58 months)	15 NED, 15 DOD, 3 AWD	73



**Figure 7.17** Complete versus incomplete resection of recurrent sarcoma in patients receiving perioperative intraperitoneal chemotherapy. From Berthet B, Sugarbaker TA, Chang D, Sugarbaker PH. Quantitative methodologioes for selection of patients with recurrent abdominopelvic sarcoma for treatment. *Eur J Cancer*. 1999;35:413–19.

which complete resection plus perioperative intraperitoneal chemotherapy shows when compared to incomplete resection.<sup>16</sup> Additional aggressive treatment modalities are indicated in recurrent abdominal and pelvic sarcoma along with phase III adjuvant studies in patients with primary sarcoma.

### Surgical Use of Radiotherapy

Intraoperative radiotherapy has been suggested for use in patients who have positive margins of excision on bone or on other vital structures such as aorta or vena cava. Interstitial radiation therapy (brachytherapy) may be considered in some instances. However, the use of brachytherapy and intraoperative radiation therapy remains controversial, and they have not been shown to be of benefit. Unfortunately, these radiotherapy technologies have been limited to only a few centers, and no phase III data are available by which to critically evaluate these treatment options.



## References

1. Sondak VK, Economou JS, Eilber FR. Soft tissue sarcomas of the extremity and retroperitoneum: advances in management. *Adv Surg.* 1991;24P:333–59.
2. Van Dam PA, Lowe PG, McKenzie-Gray B, Shepherd JH. Retroperitoneal soft tissue sarcomas. *Obstet Gynecol Surv.* 1990;45:670–82.
3. Lawrence W Jr, Neifeld JP. Soft tissue sarcomas. *Curr Probl Surg.* 1989;26:753–827.
4. Storm FK, Sondak VK, Economou JS. Sarcomas of the retroperitoneum. In: Eilber FC *et al.*, editors. *Soft Tissue Sarcomas.* New York: Grune & Stratton, 1987: 239–48.
5. Licht JD, Weissmann LB, Antman K. Gastrointestinal sarcomas. *Semin Oncol.* 1988;15:181–8.
6. Tsu Y, Lee M. Leiomyosarcoma of the gastrointestinal tract: general pattern of metastases and recurrence. *Cancer Treat Rev.* 1983;10:91–101.
7. Weiss L. *Principles of Metastasis.* New York: Academic Press, Harcourt Brace Jovanovich; 1985:187–9.
8. Glenn J, Sindelar WF, Kinsella T *et al.* Results of multimodality therapy of resectable soft-tissue sarcomas of the retroperitoneum. *Surgery.* 1985;97:316–25.
9. Potter DA, Glenn J, Kinsella T *et al.* Patterns of recurrence in patients with high-grade soft-tissue sarcomas. *J Clin Oncol.* 1985;3:353–66.
10. Sporn MD, Roberts AB. Peptide growth factors and inflammation, tissue repair and cancer. *J Clin Invest.* 1986; 78:329–32.
11. Sugarbaker TA, Chang D, Koslowe P, Sugarbaker PH. Patterns of spread of recurrent intra-abdominal sarcoma. In: Sugarbaker PH, editor. *Peritoneal Carcinomatosis: Principles of Management.* Boston: Kluwer; 1996:65–78.
12. Sugarbaker PH. Observations concerning cancer spread within the peritoneal cavity and concepts supporting an ordered pathophysiology. In: Sugarbaker PH, editor. *Peritoneal Carcinomatosis: Principles of Management.* Boston: Kluwer; 1996:79–100.
13. Enneking WF, Spanier SS, Malawer MM. The effects of the anatomic setting on the results of surgical procedures for soft part sarcoma of the thigh. *Cancer.* 1981;47:1005–22.
14. Mazeron JJ, Suit HD. Lymph nodes as sites of metastases from sarcomas of soft tissue. *Cancer.* 1987;60:1800–8.
15. McGrath PC, Neifeld JP, Lawrence W *et al.* Improved survival following complete excision of retroperitoneal sarcomas. *Ann Surg.* 1984;200:200–4.
16. Berthet B, Sugarbaker TA, Chang D, Sugarbaker PH. Quantitative methodologies for selection of patients with recurrent abdominopelvic sarcoma for treatment. *Eur J Cancer.* 1999;35:413–19.
17. Eroglu A, Kocaoglu H, Demirci S, Akgul H. Retroperitoneal soft tissue sarcoma: effect of hyperthermic total abdominal perfusion. *Tumori.* 1999;85:259–64.
18. Eilber FC, Rosen G, Forscher C, Nelson SD, Dorey FJ, Eilber FR. Surgical resection and intraperitoneal chemotherapy for recurrent abdominal sarcomas. *Ann Surg Oncol.* 1999;6:645–50.
19. Kinsella TJ, Sindelar WF, Lack E, Glatstein E, Rosenberg SA. Preliminary results of a randomized study of adjuvant radiation therapy in resectable adult retroperitoneal soft tissue sarcomas. *J Clin Oncol.* 1988;6:18–25.
20. Tepper JE, Suit HD, Wood WC, Proppe KH, Harmon D, McNulty P. Radiation therapy of retroperitoneal soft tissue sarcomas. *Int J Radiat Oncol Biol Phys.* 1984;10: 825–30.
21. Elias AD, Antman KH. Adjuvant chemotherapy for soft tissue sarcoma: a critical appraisal. *Semin Surg Oncol.* 1988;4:59–65.
22. Sugarbaker PH. Peritonectomy procedures. *Ann Surg.* 1995;221:29–42.
23. Karakousis CP, Kontzoglou K, Driscoll DL. Intraperitoneal chemotherapy in disseminated abdominal sarcoma. *Ann Surg Oncol.* 1997;4:496–8.

