

Palliative Forequarter Amputation for Metastatic Carcinoma to the Shoulder Girdle Region: Indications, Preoperative Evaluation, Surgical Technique, and Results

JAMES C. WITTIG, MD,^{1*} JACOB BICKELS, MD,² YEHUDA KOLLENDER, MD,² KRISTEN L. KELLAR-GRANEY, BS,¹ ISAAC MELLER, MD,² AND MARTIN M. MALAWER, MD¹

¹Department of Orthopedic Oncology, Washington Cancer Institute at the Washington Hospital Center, Washington, DC

²National Unit of Orthopedic Oncology, Tel-Aviv Sourasky Medical Center, Tel-Aviv, Israel

Background and Objectives: Uncontrolled metastatic carcinoma of the shoulder girdle is a difficult oncologic problem. This study reviews our experience with palliative forequarter amputation with emphasis on patient selection criteria, preoperative radiologic assessment, surgical technique, epineural postoperative analgesia, and clinical outcome.

Methods: Eight patients who underwent palliative forequarter amputation for metastatic carcinoma between 1980 and 1999 were analyzed retrospectively. Diagnoses included breast carcinoma (n = 3), squamous cell carcinoma (n = 2), hypernephroma (n = 2), and carcinoma of unknown origin (n = 1). All patients presented with severe, intractable pain and a useless extremity. Venography demonstrated obliteration of the axillary vein in each of the patients in whom this procedure was performed. Exploration of the brachial plexus confirmed tumor encasement and unresectability in all patients. Epineural catheters for bupivacaine infusion were placed for postoperative pain control.

Results: All patients experienced dramatic pain relief and improved mobility and overall function. Life-threatening hemorrhage and sepsis were alleviated. There were no instances of phantom limb pain or adverse psychological reactions, and no complications related to epineural analgesia.

Conclusions: Palliative forequarter amputation is relatively safe and reliable and provides effective pain relief for selected patients with unresectable metastatic carcinoma to the axilla and bony shoulder girdle in whom radiotherapy and/or chemotherapy has not been effective. The triad of pain, motor loss, and an obliterated axillary vein is indicative of brachial plexus infiltration and unresectability. *J. Surg. Oncol.* 2001;77:105–113.

© 2001 Wiley-Liss, Inc.

KEY WORDS: axillary tumor(s); brachial plexus; unresectable tumor; venography; regional analgesia; phantom limb pain

INTRODUCTION

Historically, forequarter amputation has been used for curative resection of locally advanced, high-grade bone and soft-tissue sarcomas involving the shoulder girdle region [1–6]. More recently, limb salvage, combined

*Correspondence to: James C. Wittig, MD, Department of Orthopedic Oncology, Washington Cancer Institute, 110 Irving Street N.W., Suite C-2173, Washington, DC 20010. Fax No.: 202-877-8959.

E-mail: wittigj@aol.com

Accepted 5 February 2001

TABLE I. Patients Treated With Palliative Forequarter Amputation: Patient Demographics, Indications, Complications, and Results*

No.	Age (yr)	Sex	Diagnosis	Indication	Complications	LR	Pain relief	Survival (mos)
1	52	M	Metastatic carcinoma of unknown origin	P,F,LD,L	N	N	Marked	D(3)
2	57	F	Metastatic hypernephroma	P,F,LD,L	Flap necrosis, I&D, STSG	N	Marked	D(8)
3	80	M	Metastatic squamous cell carcinoma	P,F,H	N	N	Good	D(10)
4	50	F	Metastatic hypernephroma	P,F,H	N	N	Marked	AWD (11)
5	44	F	Metastatic breast cancer	P,LD	N	N	Marked	D(6)
6	54	F	Metastatic breast cancer	P,LD,F,H	Skin flap necrosis, I&D, STSG; pleural effusion	Y	Marked	D(4)
7	79	F	Metastatic breast cancer	P,LD	N	N	Good	D(5)
8	49	F	Metastatic squamous cell carcinoma	P,I,F,H	N	N	Good	A-NED (12)

*A-NED, alive with no evidence of disease; AWD, alive with disease; D, dead; F, fungation; H, hemorrhage; I&D, irrigation/debridement; L, lymphedema; LR, local recurrence; LD, limb dysfunction; N, none; P, intractable pain; STSG, split thickness skin graft.

with neoadjuvant chemotherapy, has been performed safely for most sarcomas in this location. In rare instances, however, forequarter amputation may be indicated for palliation of patients with locally advanced, unresectable metastatic carcinoma of the shoulder girdle [1–3,6–11]. These tumors most commonly arise from metastatic spread to regional lymph nodes, the proximal humerus, or the scapula. A large soft-tissue mass may grow to encase the neurovascular bundle or invade the chest wall. At this point, the tumor becomes unresectable. Patients present with severe intractable pain, a useless extremity, varying degrees of paralysis and sensory impairment, and chronic lymphedema. Relentless growth may lead to tumor fungation, sepsis, and hemorrhage. Conservative measures such as chemotherapy and radiation are usually attempted for local control and pain relief. If they fail, the disease progresses. Postradiation brachial plexopathy may further compound signs and symptoms [12,13]. As a last resort, palliative forequarter amputation may provide effective pain relief and improve overall quality of life for these patients.

This study is a retrospective analysis of eight patients who underwent palliative forequarter amputation for metastatic carcinoma involving the shoulder girdle region. Its objectives are to describe our indications for palliative forequarter amputation and to review our surgical technique and patient outcomes. We also describe the clinical and radiographic criteria for patient selection.

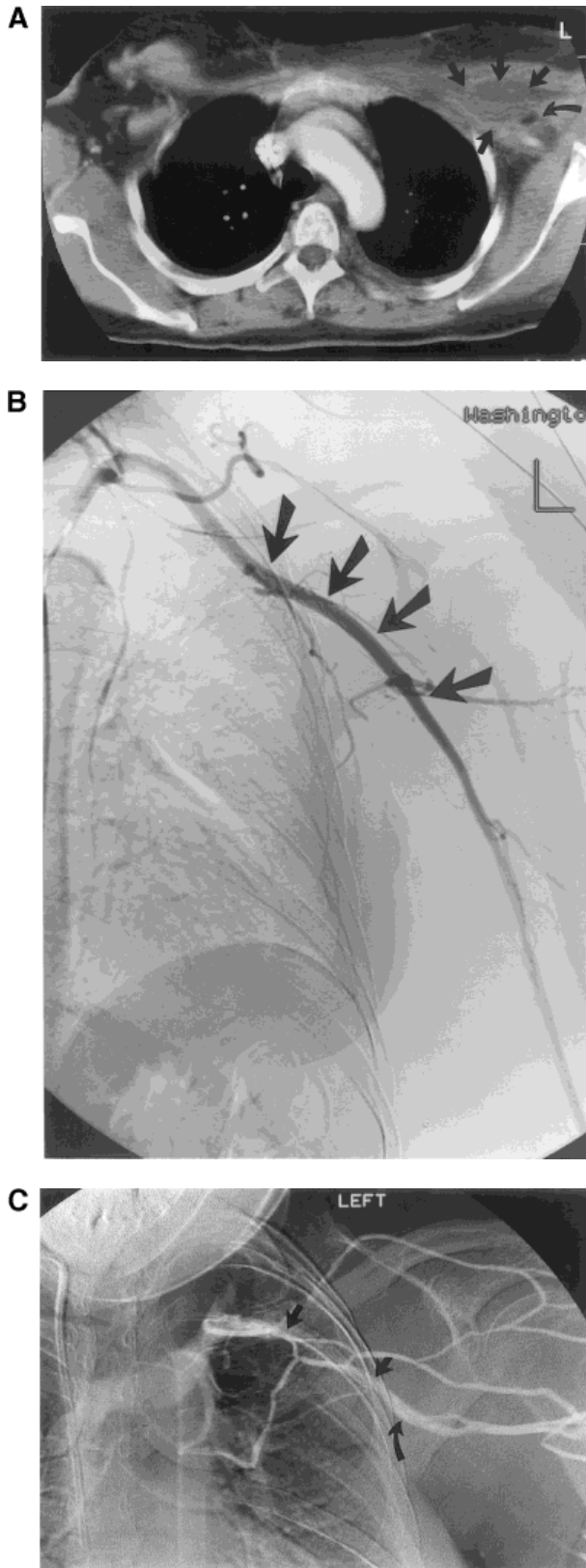
MATERIALS AND METHODS

The computer databases of both senior authors were searched for all patients who underwent forequarter amputation. Twenty-six forequarter amputations were

performed between 1980 and 1999. Of these procedures, eight were performed for palliative purposes on patients with metastatic carcinoma (Table I). There were two males and six females. Diagnoses included metastatic breast carcinoma (three patients), squamous cell carcinoma (two patients), hypernephroma (two patients), and carcinoma of unknown origin (one patient). Ages ranged from 44 years to 80 years (median, 52 years). Tumor diameter ranged from 7 to 20 cm. All eight patients were diagnosed with unresectable metastatic carcinoma and had severe intractable pain that limited function. All required high doses of morphine sulfate (80–120 mg every 3 to 4 hours) to help control the pain. Six patients had received radiotherapy (30Gy to 57Gy) in an effort to control the tumor and prevent progression. All patients presented with one or more of the following additional local complications: motor and sensory loss (eight patients), tumor fungation (six patients) that led to sepsis (two patients) or hemorrhage (three patients), or chronic lymphedema (three patients). Postoperatively, pain relief was graded according to the following criteria: (1) marked: greater than 90% pain relief and/or occasional codeine-based pain medication; (2) good: 60–90% pain relief and/or greater than 50% reduction in narcotic requirements; or (3) poor: less than 60% pain relief or less than 50% reduction of narcotic requirements. Function was evaluated in terms of mobility and ability to perform activities of daily living (ADLs).

Indications

Indications for palliative forequarter amputation included (1) an unresectable metastatic carcinoma (i.e., neurovascular invasion or chest wall extension); (2) failure of



conservative management (i.e., radiotherapy and chemotherapy); (3) severe intractable pain with loss of limb function; and (4) one or more of the following local tumor-related complications: paralysis, tumor fungation, hemorrhage, sepsis, severe lymphedema, venous gangrene, and radiation-induced complications, including brachial plexopathy.

Preoperative Radiologic Evaluation

Preoperative studies included plain films, angiography, computed tomography (CT), and/or magnetic resonance imaging (MRI). Venograms were performed on three recent patients to help determine tumor resectability (i.e., brachial plexus invasion vs. displacement; Fig. 1).

Surgical Technique

Forequarter amputation was performed by means of combined anterior and posterior approaches (Fig. 2). Skin flaps were modified to accommodate heavily irradiated skin damage, which was excised, and tumor fungation. The anterior exposure was performed first to facilitate exploration the infraclavicular portion of the brachial plexus and axillary vessels. The pectoralis major was released from its humeral insertion. The coracobrachialis, short head of the biceps, and pectoralis minor were subsequently released from the coracoid, which completed exposure of the axillary vessels and brachial plexus (Fig. 3). Once neurovascular encasement was confirmed, forequarter amputation continued. The subclavian artery and vein and brachial plexus were individually doubly ligated and transected. The serratus anterior muscle was resected when involved by tumor. It was not necessary, in any patient in this study, to resect a portion of the chest wall, or the ipsilateral breast. After anterior exploration, the incision was extended posterolaterally over the shoulder, curving medially at the scapular tip. This resulted in construction of a large medially based posterior skin flap. All muscles anchoring the scapula to the chest wall were released (Fig. 4). The clavicle was osteotomized close to the sternoclavicular joint. The two skin incisions were connected in the axilla. Hemostasis was achieved. The pectoralis major was either transected

Fig. 1. (A–D) Estimating tumor resectability. (A) Locoregional failure from a previously resected breast carcinoma resulting in metastatic disease to the left axillary lymph nodes. There is a large mass arising in the left axillary space (straight arrows). The tumor is juxtaposed to the axillary vessels and brachial plexus (curved arrow). (B) Angiogram of the same patient demonstrating anterolateral displacement of the axillary artery (arrows). The arterial system remained patent because of the artery's thick walls and high intraluminal pressure. (C) Formal venogram demonstrating obliteration (between straight arrows) of the axillary vein (curved arrow). This finding is consistent with tumor infiltration and encasement of the left axillary sheath. (D) Schematic demonstrating an unresectable tumor.

BRACHIAL PLEXUS (TUMOR UNRESECTABLE)

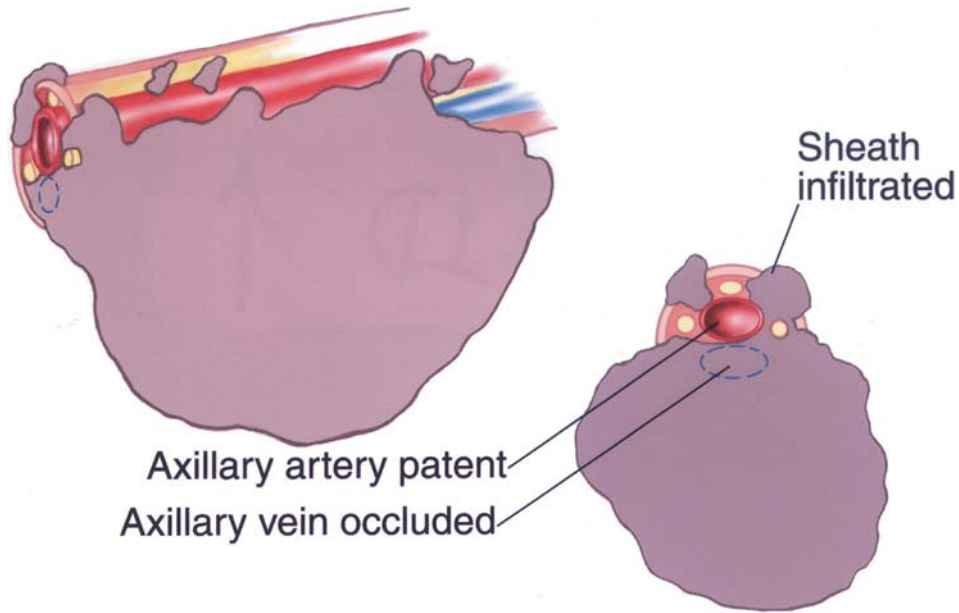


Fig. 1. (Continued)

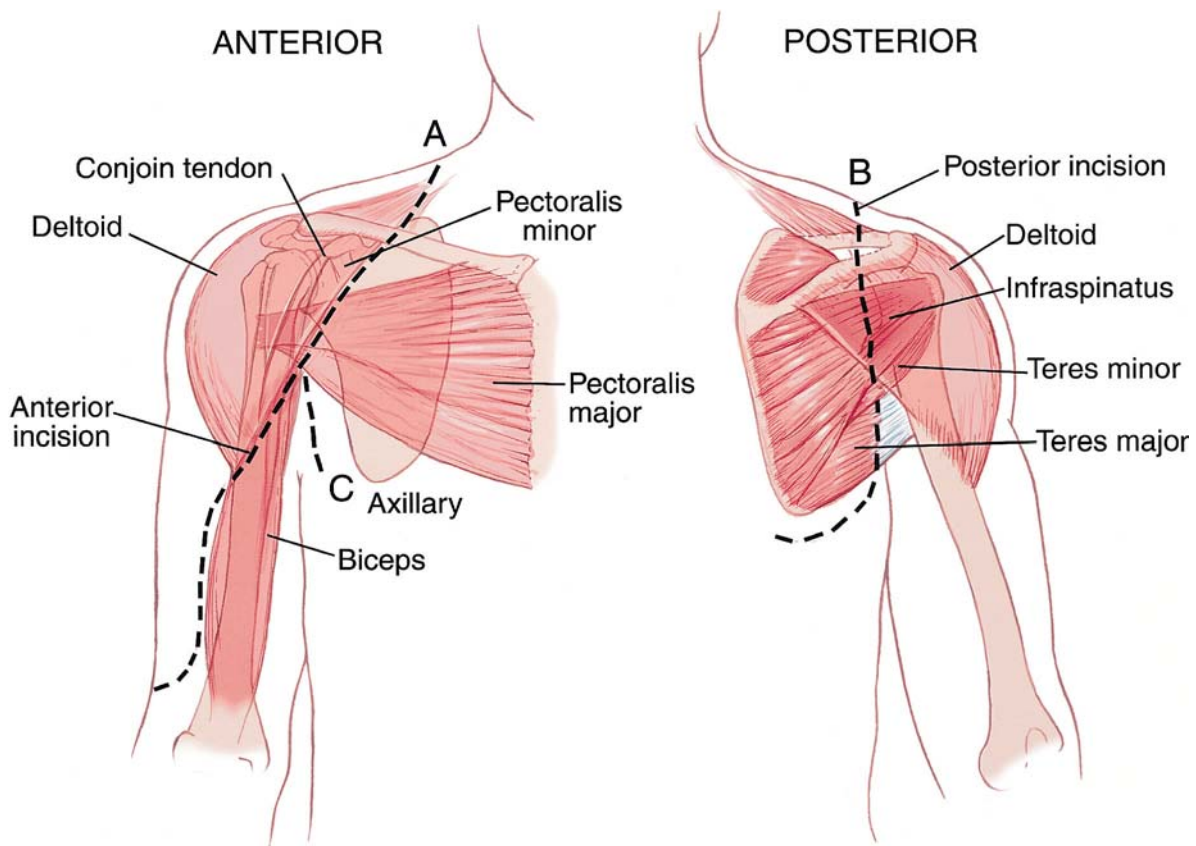


Fig. 2. Forequarter amputation: surgical approach (utilitarian shoulder girdle incision). The utilitarian shoulder girdle incision is used. The anterior approach, which is performed first, allows exposure and exploration of the brachial plexus and final determination of tumor resectability. The anterior incision follows the neurovascular bundle and extends from the mid-clavicle, medial to the coracoid, along the

deltopectoral groove, to the axilla (A, C). After exploration of the brachial plexus and determination that the tumor is unresectable, the patient is rotated and the incision is extended (B) posterolaterally over the shoulder for the entire length of the scapula, curving medially just inferior to the scapular tip. Posteriorly, a large medially based fasciocutaneous skin flap is developed and used for closure.

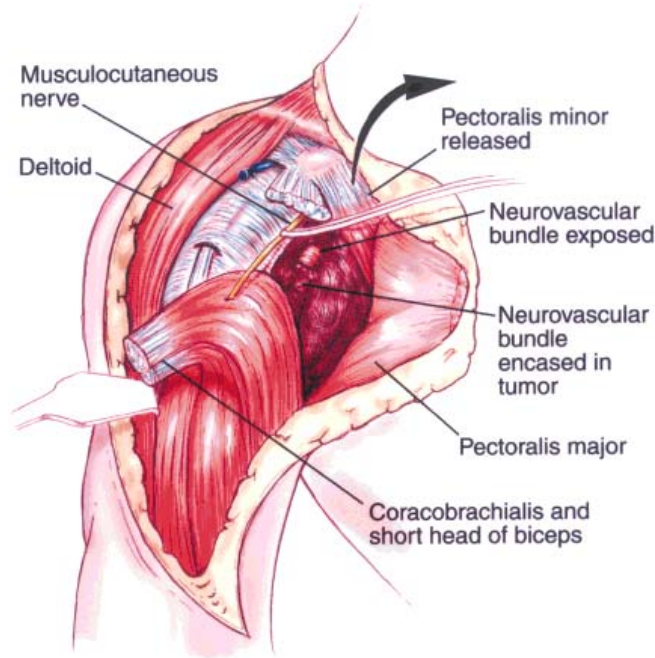


Fig. 3. Exposure of the brachial plexus and axillary vessels. After the anterior skin incision is made, the neurovascular bundle is exposed and the tumor is explored. The key to exposing the neurovascular bundle is release of the pectoralis major from its humeral insertion, followed by

the conjoined tendon (coracobrachialis, short head of the biceps and pectoralis minor) from the coracoid. The entire brachial plexus, axillary vessels, and tumor are exposed. The brachial plexus is explored, and tumor resectability is definitively determined.

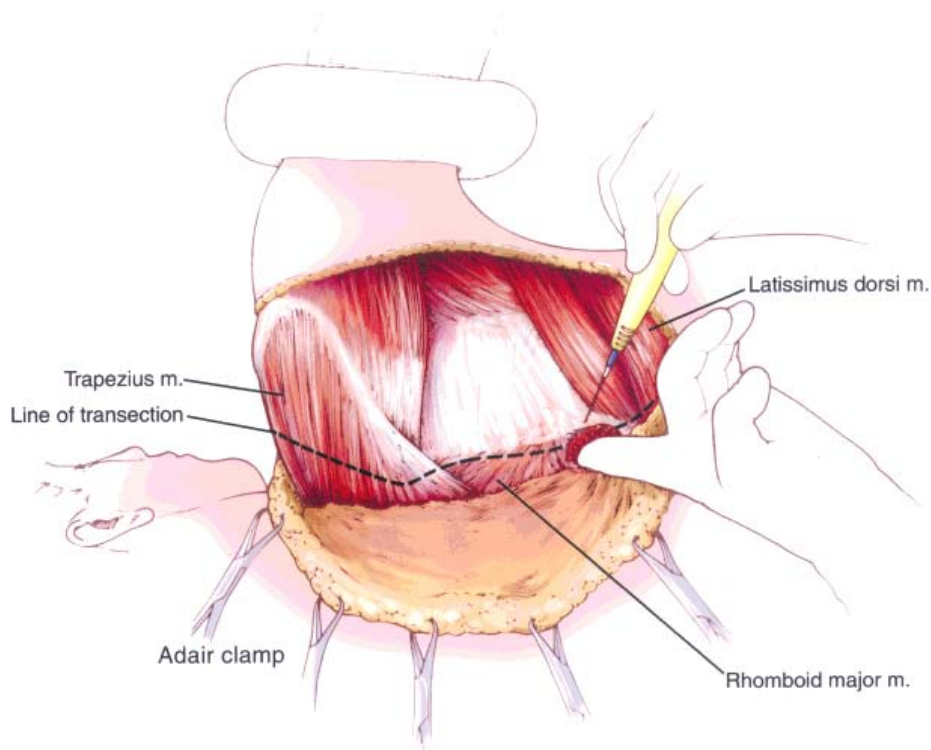


Fig. 4. Release of periscapular muscles. If the tumor is determined to be unresectable, the incision is extended posteriorly and all periscapular muscles are released from the scapula.

TABLE II. Literature Review Reporting Results of Palliative Forequarter and Lower-Extremity Amputations*

Authors	No. of patients	Procedure	% palliation	Complications
Holleb and Lucas 1959 [7]	6	Forequarter	83	LR (1)
El-Domieri and Miller 1969 [2]	11	Forequarter	91	Not stated
Pressman 1974 [9]	2	Forequarter	100	0
Malawer et al. 1991 [27]	11	LE	100	Minor wound (3)
Ham et al. 1993 [3]	2	Forequarter	100	0
Bhagia et al. 1997 [1]	2	Forequarter	100	Not stated
Meriminsky et al. 1997 [15]	21	LE	91	Not stated
			(2 not assessable)	

*LE, lower extremity.

close to its origin or sutured to the chest wall. The skin flap was closed over the defect.

Epineural Catheter Bupivacaine Infusion

Before wound closure, an epineural pain catheter was inserted into the brachial plexus sheath in six patients. Immediate analgesia was obtained with an initial bolus of 10–20 cc of 0.25% bupivacaine that was infused before the patient awakened from anesthesia. Continuous infusion was instituted promptly in the recovery room. The infusion rate was titrated for maximal pain relief and generally ranged from 4 to 8 cc/hr of 0.25% bupivacaine. The catheters remained in place until the pain could be readily controlled with an oral narcotic. In one patient, infusion continued after being discharged from the hospital (i.e., for 3 weeks). Patients also received patient-controlled analgesia (PCA) or oral opioids as inpatients and were discharged home on oral narcotics.

RESULTS

Survival ranged from 3 to 12 months (median, 5.5 months; Table I). Six patients died from tumor-related causes. Two patients are currently alive and pain-free at 11 and 12 months after amputation; the latter patient (case 8) has no evidence of disease. All patients experienced significant pain relief and a reduction in narcotic requirements after forequarter amputation. Five patients were rated as having marked pain relief, and three patients as having good pain relief. Preoperatively, all patients had difficulty with ADLs because of severe pain and inability to use the limb. They were sedentary, bedridden, and depressed. Each patient with a fungating tumor underwent dressing changes several times per day. Two patients with hemorrhaging tumors were hospitalized and received blood transfusions. Postoperatively, all patients were able to perform ADLs. They were no longer burdened with the need for dressing changes and blood transfusions. They became more mobile, and their mood improved. There were no instances of phantom limb pain,

and no patient developed an adverse psychological reaction to the amputation. Quality of life improved for all patients in this group.

Complications included two instances of skin flap necrosis (cases 2 and 6). Both were successfully treated with incision, debridement, and skin grafting. Case 6 developed a pleural effusion after being discharged. It resolved and did not require treatment. This patient also developed local recurrence consisting of several painless subcutaneous nodules. These were adequately controlled with radiotherapy until the patient's demise. There were no complications related to epineural analgesia.

DISCUSSION

The results of this study support the use of palliative forequarter amputation for select patients with advanced, unresectable metastatic carcinoma involving the shoulder girdle. We have not performed palliative forequarter amputations for indications of pain alone because of the disfiguring nature of the procedure, the possibility that the patient might develop intractable phantom limb pain after amputation, and a desire to prevent functional limb loss from amputation of an otherwise useful extremity. Despite the potential morbidity associated with the procedure, we have found it useful and reliable when performed according to specific criteria. All eight patients in this series had significant pain relief and improvement in quality of life after amputation. They became more active and ambulatory. Narcotic requirements were reduced, and mood was improved in all patients. Complications were minor and did not compromise results. Additionally, there were no instances of post-operative phantom limb pain.

There are few reports in the literature focusing on palliative forequarter amputation for metastatic carcinoma (Table II). Most are based on a small group of patients or case reports. Indications and results, however, have been similar to ours. Holleb and Lucas [7], in 1959, reported on six patients who underwent palliative forequarter amputation for a painful, lymphedematous,

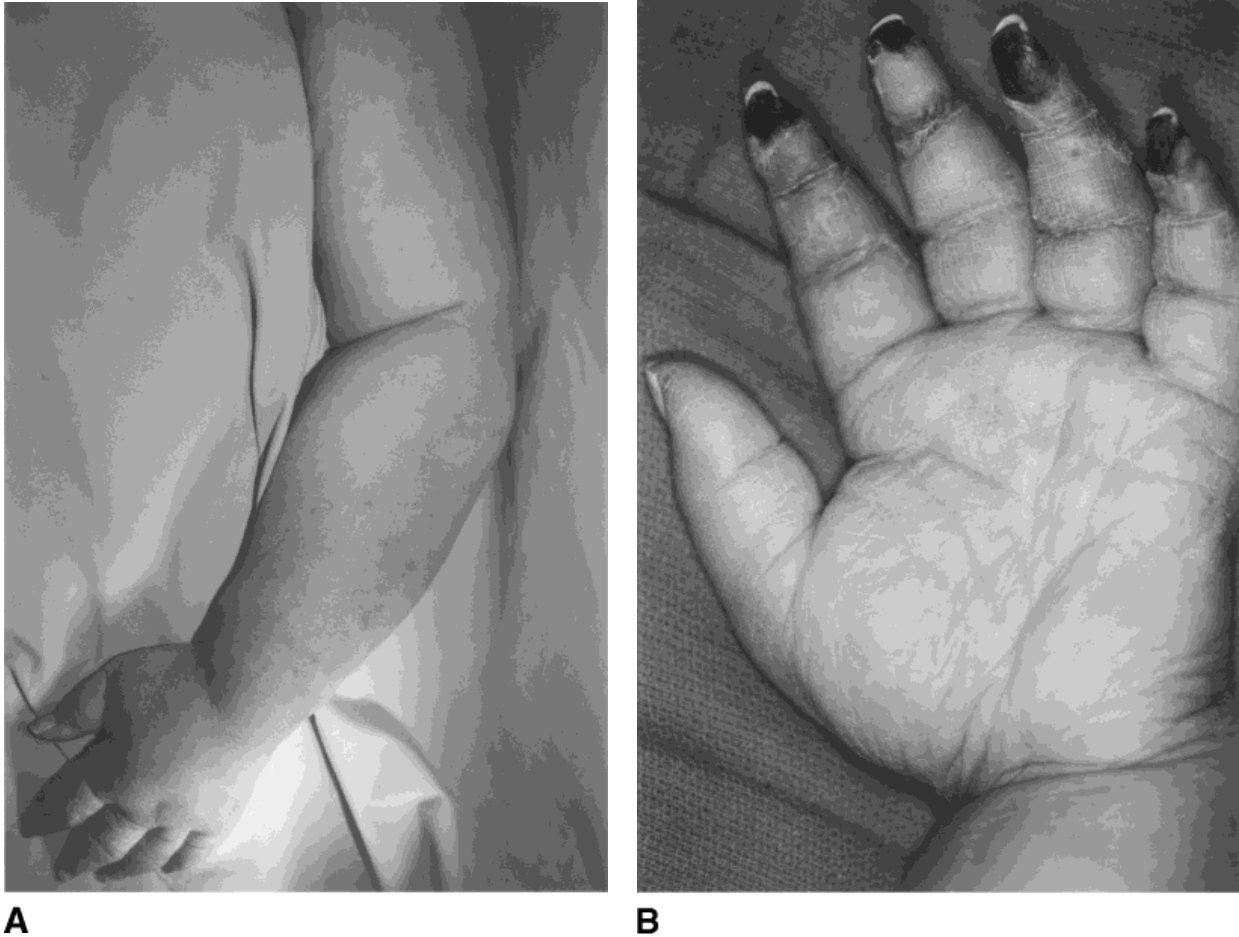


Fig. 5. (A,B) Clinical findings consistent with venous gangrene. Clinical photograph showing diffusely stiff upper extremity with severe lymphedema. (B) Close-up of the hand demonstrating necrosis of the fingertips, severe lymphedema, and stiffness (no active or passive motion). These changes reflect chronic venous stasis resulting in venous gangrene.

useless upper extremity secondary to recurrent breast carcinoma or radiation-induced complications from primary treatment. Five of six patients were relieved of pain and had no tumor recurrence. Pressman [9] reported palliation of two patients with painful, swollen, useless arms secondary to radiation-induced complications from treatment of breast carcinoma. Ham et al. [3] reported palliation of one patient with an expansive, uncontrollable, bleeding tumor and another patient with an undifferentiated epithelial carcinoma. El-Domieri and Miller [2] reported 11 patients who underwent palliative forequarter amputation for swollen painful extremities secondary to metastatic breast, kidney, lung, colon, or adrenal carcinoma. Ten of 11 patients were relieved of pain. Bhagia et al. [1] reported on two patients who were relieved of pain and gained independence after forequarter amputation. These results are consistent with those of other studies examining mixed cohorts of

patients for whom palliative amputations were performed for unresectable carcinomas or sarcomas primarily involving the lower extremities [14,15] (Table II).

Our study, viewed in the context of these previous reports, confirms a role for palliative amputation for a highly select group of patients. We recommend forequarter amputation as a last resort for patients with unresectable metastatic carcinoma infiltrating the brachial plexus when more conservative measures such as radiotherapy fail to prevent tumor progression or control pain. We believe it is crucial that perioperative pain control be maximized to reduce the risk of postoperative phantom limb pain.

The population of patients presented in this study reflects the pattern of metastatic spread to the shoulder girdle region. Metastatic carcinoma to this region typically arises from distant spread to a regional lymph node or lymph node group or through bony metastases to

the proximal humerus or scapula [15,16]. The proximal humerus and scapula are common sites of metastases for hypernephromas. The axillary lymph nodes serve as a reservoir for lymphatic drainage from the breast, upper extremity, and chest wall. Hence, breast cancer is the most common carcinoma to metastasize to the axillary nodes. Any carcinoma arising in the upper extremity, such as squamous cell carcinoma or melanoma, may also spread to this nodal site.

Radiotherapy may effectively eradicate small lesions; however, bulky tumors and hypernephromas are often radioresistant. Studies examining local control using radiotherapy for locoregional recurrences of breast cancer document a 30–70% long-term success rate [17–21]. Lesions that can be successfully controlled with radiotherapy alone are usually less than 3 cm. Tumors that fail to respond to radiotherapy continue to grow and cause local complications and, frequently, a painfully agonizing death [22]. Therefore, we recommend primary surgical resection for resectable locoregional recurrences. Radiotherapy should be reserved for microscopic residual disease or as conservative treatment for late-presenting unresectable tumors.

It is difficult to determine brachial plexus or neurovascular involvement before surgery. No single imaging study allows one to accurately determine plexus involvement and, thus, resectability. Nerve pain, or paresthesias, alone, are not a reliable means of distinguishing displacement from encasement. In our experience, nerve pain becomes intractable and motor neuropraxia develops with infiltration of the brachial plexus. All patients in this study presented with motor and sensory loss. Changes consistent with early venous gangrene, including lymphedema and skin/nail changes, may also develop secondary to chronic venous obstruction (Fig. 5). We have found that venography demonstrating obliteration of the axillary/brachial vein indirectly correlates with brachial plexus invasion (Fig. 1). When tumor has infiltrated the axillary sheath, the angiogram usually demonstrates patency of the axillary artery, because the high-pressure system and thick-walled vessels prevent occlusion. The venous system, however, is a low-pressure system. Its walls are thin and easily compressed by infiltrating tumor. Obliteration of venous flow, therefore, provides an indirect reflection of plexus invasion because of the close apposition of the vein to the brachial plexus within the axillary sheath.

We propose the following triad for accurate preoperative determination of plexus invasion: single or multiple motor nerve loss; intractable pain; and venous obliteration, as demonstrated by axillary venography, and signs of venous gangrene.

The final decision regarding resectability, however, should be made intraoperatively after exploring the tumor

and brachial plexus, considering the mutilating nature and functional loss associated with a forequarter amputation.

The key to successful exposure and exploration of the tumor and brachial plexus lies in releasing the pectoralis major from its humeral insertion followed by releasing the pectoralis minor, short head of the biceps and coracobrachialis from the coracoid process. The pectoralis major was not involved by tumor in any of the patients in this study. Although preoperative imaging studies may have demonstrated close proximity of the tumor to this muscle, a fascial plane existed in all patients that facilitated medial retraction of the pectoralis major after release from its insertion. It was not necessary in any patient to release the pectoralis major from its sternal and costal origins to improve exposure. In several cases, preoperative imaging studies also demonstrated close apposition of the mass to the chest wall; however, during intraoperative exploration, a surgical plane existed between the tumor and ribs, that was created by the serratus anterior muscle. The serratus anterior muscle was resected when involved by tumor however, no patient in this study required concomitant chest wall resection.

Provision of adequate perioperative analgesia may have been crucial for the positive outcomes documented in our analysis. Phantom limb pain has been reported in 60–90% of amputees [23]. It may be more prevalent in cancer patients who have undergone amputations, particularly those exposed to chemotherapeutic agents, than in other amputees. The incidence of phantom limb pain may also be greater in patients who experience prolonged preoperative pain and pain in the immediate perioperative period than in those who do not [23,24]. Perioperative analgesia may decrease the incidence and severity of postoperative phantom limb pain. However, frequently it is difficult to control postamputation pain in a patient who has had extreme preamputation pain. Additionally, we have found that immediate postamputation pain may be more severe than preoperative pain. A few studies have emphasized the efficacy of regional techniques for optimizing postoperative analgesia [24–28]. Some of these studies have suggested that phantom limb pain may be prevented with these techniques; however, there have been no prospective randomized studies that examined the effect of postoperative regional analgesia on the incidence of phantom limb pain in cancer patients [26,27].

Our goal has been to optimize preoperative and postoperative analgesia in patients undergoing palliative forequarter amputation. High-dose narcotics and select low-dose anticonvulsive and antidepressant medications are used liberally in the preoperative period. Regional epineural analgesia, administered as described earlier in this study, has been especially efficacious in controlling

early postoperative pain. It has been previously shown to reduce postoperative narcotic requirements by as much as 80% [27].

Our current study demonstrates an absence of phantom limb pain after forequarter amputation in a group of patients who appear predisposed to this complication because of the long duration and intensity of their preoperative pain. We attribute most of this success to excellent postoperative analgesia obtained with epineural bupivacaine infusion in the majority of patients. Pain relief was reliable and management simplified. We do recognize that although no patient reported signs or symptoms of phantom limb pain, the preoperative pain may have been so severe that any residual postoperative pain was a drastic improvement and patients may not have complained about it, even when questioned.

CONCLUSIONS

Palliative forequarter amputation seems to be a relatively safe and reliable procedure for alleviating pain and improving quality of life for selected patients with unresectable metastatic carcinoma to the axilla and bony shoulder girdle in whom radiotherapy and/or chemotherapy have been ineffective. We recommend the procedure for patients with severe intractable pain, a useless extremity, and one or more local tumor-related complications. Pain relief is substantial, and any residual pain can usually be controlled with low doses of codeine or other narcotics. Patients' mobility, mood, and quality of life can be positively affected. We underscore the importance of adequate perioperative analgesia in this population. Epineural analgesia can help optimize postoperative pain control and, possibly, prevent phantom limb pain.

REFERENCES

- Bhagia SM, Elek EM, Grimer RJ, et al.: Forequarter amputation for high-grade malignant tumors of the shoulder girdle. *J Bone Joint Surg Br* 1997;79:924-926.
- El-Domieri A, Miller TR: The role of interscapulothoracic amputation in the treatment of malignant tumors. *Surgery* 1969;1203-1206.
- Ham SJ, Koops HS, Eisma WH, Oldhoff J: The interscapulothoracic amputation in the treatment of malignant diseases of the upper extremity with a review of the literature. *Eur J Surg Oncol* 1993;19:543-548.
- Jacques DP, Coit DG, Brennan MF: Major amputation for advanced malignant melanoma. *Surgery* 1989;169:1-6.
- Masterson EL, Davis AM, Wunder JS, Bell RS: Hindquarter amputation for pelvic tumors. *Clin Orthop* 1998;350:187-194.
- Nadler SH, Phelan JT: A technique of interscapulothoracic amputation. *Surgery* 1966;359-364.
- Holleb AI, Lucas JC: Palliative interscapulothoracic amputation in the management of the breast cancer patient. *Cancer* 1959;12:643-647.
- Pack GT, McGraw TA: Interscapulomammothoracic amputation for malignant melanoma. *Arch Surg* 1961;83:694-699.
- Pressman PI: Interscapulothoracic amputation for the complications of breast cancer: A new approach. *Surgery* 1974;75:796-801.
- Willard WC, Collin C, Casper ES, et al.: The changing role of amputation for soft-tissue sarcoma of the extremity in adults. *Surgery* 1992;175:389-396.
- Zachary LS, Gottlieb LJ, Simon M, et al.: Forequarter amputation wound coverage with an ipsilateral, lymphedematous, circumferential forearm fasciocutaneous free flap in patients undergoing palliative shoulder-girdle tumor resection. *J Reconstr Microsurg* 1993;9:103-107.
- Kori SH: Diagnosis and management of brachial plexus lesions in cancer patients. *Oncology* 1995;9:756-765.
- Thomas JE, Colby MY: Radiation-induced or metastatic brachial plexopathy. A diagnostic dilemma. *JAMA* 1972;222:1392-1395.
- Malawer MM, Buch RG, Thompson WE, Sugarbaker PH: Major amputations done with palliative intent in the treatment of local bony complications associated with advanced cancer. *Surg Oncol* 1991;47:121-130.
- Merimsky O, Kollender Y, Inbar M, et al.: Palliative major amputation and quality of life in cancer patients. *Acta Oncol* 1997;36:151-157.
- Carty NJ, Foggitt A, Hamilton CR, et al.: Patterns of clinical metastasis in breast cancer: an analysis of 100 patients. *Eur J Surg Oncol* 1995;21:607-608.
- Aberzick WJ, Silver B, Henderson C, et al.: The use of radiotherapy for treatment of isolated locoregional recurrence of breast carcinoma after mastectomy. *Cancer* 1986;58:1214-1218.
- Amichetti M, Valdagni R, Graiff C, Valentini A: Local-regional recurrences of breast cancer: treatment with radiation therapy and local microwave hyperthermia. *Am J Clin Oncol* 1991;14:60-65.
- Chen KKY, Montague ED, Oswald MJ: Results of irradiation in the treatment of locoregional breast cancer recurrence. *Cancer* 1985;56:1269-1273.
- Chu FCH, Lin FJ, Kim JH, et al.: Locally recurrent carcinoma of the breast. Results of radiation therapy. *Cancer* 1976;37:2677-2681.
- Patanphan V, Salazar OM, Poussin-Rosillo H: Prognosticators in recurrent breast cancer. *Cancer* 1984;54:228-234.
- Recht A, Pierce SM, Abner A, et al.: Regional nodal failure after conservative surgery and radiotherapy for early-stage breast carcinoma. *J Clin Oncol* 1991;9:998-996.
- Katz J, Melzack R: Pain memories in Phantom limbs: Review and clinical observations. *Pain* 1990;43:319-336.
- Enneking FK, Scarborough MT, Radson EA: Local anesthetic infusion through nerve sheath catheters for analgesia following upper extremity amputation. *Regul Anesth* 1997;22:351-356.
- Bach S, Noreng MF, Tjelliden U: Phantom limb pain in amputees during the first twelve months following amputation after preoperative lumbar epidural blockade. *Pain* 1988;33:297-301.
- Fisher A, Meller Y: Continuous postoperative regional analgesia by nerve sheath block for amputation surgery: A pilot study. *Anesth Analg* 1991;72:300-303.
- Malawer MM, Buch R, Khurana JS, et al.: Postoperative infusional continuous regional analgesia, a technique for relief of postoperative pain following major extremity surgery. *Clin Orthop* 1991;266:227-237.
- Pinzur MS, Garia PGN, Pluth T, Vrbos L: Continuous postoperative infusion of a regional anesthetic after an amputation of the lower extremity. *J Bone Joint Surg Am* 1996;78:1501-1505.