

26

Pelvic Resections (Internal Hemipelvectomies)

Jacob Bickels and Martin Malawer

OVERVIEW

Internal hemipelvectomies involve resection of part or all of the innominate bone with preservation of the extremity. This chapter will describe the surgical technique of resection of the ilium (Type I pelvic resection) and the pubic region (Type III pelvic resection). These resections do not violate the hip joint and minimally compromise the stability of the pelvic girdle, and therefore do not require reconstruction. Detailed preoperative evaluation and meticulous surgical dissection are crucial because of the close proximity of the pelvic girdle to major blood vessels, nerves, and internal organs in these regions. The surgical technique of Type II (periacetabular) resection is described in Chapter 28.

INTRODUCTION AND ANATOMIC CONSIDERATIONS

The pelvic girdle is a common location for primary bone sarcomas and metastatic lesions with the periacetabular region being the most common location, followed by the ilium and the pubis. Hemipelvectomy, the classic treatment for these lesions, has been associated with dismal functional and psychological outcomes. Improved survival of patients with musculoskeletal malignancies, and refinements in surgical technique, have allowed the execution of limb-sparing procedures in these situations. Local tumor control is good, as is the probability of a functional extremity. Internal hemipelvectomies, which involve resection of part or all of the innominate bone with preservation of the extremity, are now a reliable surgical option in the treatment of primary bone sarcomas, benign-aggressive lesions, and metastatic tumors of the pelvic girdle.

Detailed preoperative evaluation is necessary in order to evaluate the bony and soft-tissue extents of the tumor and their relation to the major blood vessels, nerves, and pelvic viscera. The complex anatomy of the pelvic girdle, and the close proximity of the major neurovascular bundle and pelvic cavity, necessitate wide exposure of the surgical field. No attempt is made to resect a tumor through a limited incision; this might result in injury to a major structure and compromise the oncologic quality of the surgery.

The classification of internal hemipelvectomies is based on the resected region of the innominate bone, from posterior to anterior: Type 1 – ilium; Type 2 – periacetabular region, and Type 3 – pubis. En-bloc resection of the ilium and sacral ala is classified as an extended Type 1 or Type 4 resection.

Resection of the ilium can be partial or complete; only a segment of the iliac wing or the entire ilium can be resected. Stability of the pelvic girdle is not impaired after partial iliac resection because a rim of bone still bridges the periacetabular region and the sacrum. Complete iliac resection, on the other hand, impairs pelvic girdle stability because the space created between the acetabulum and the sacrum allows upward migration of the lower extremity upon weight-bearing. However, the extent of that migration is not significant because a contralateral, stiff sacroiliac joint and the extensive scar formation in the surgical site prevent excessive tilting. As a result, limb-length discrepancy of not more than 2 cm is observed in most cases and can be effectively treated with ipsilateral shoe lift. It is therefore a matter of controversy whether to reconstruct the retroacetabular defect or not.

The inner aspect of the ilium is covered by the iliacus muscle, which originates from the iliac crest. The iliacus is “pushed” by a growing bone sarcoma and serves as a

barrier to direct extension of a tumor to the pelvic viscera. The same is true for the gluteus medius muscle, which lies against the outer table of the ilium. When resection of the ilium is performed for a benign-aggressive lesion, both muscles can be spared. However, when the resection is performed for a primary bone sarcoma or a metastatic lesion, both of which commonly break through the inner and outer table, the portion of the iliacus and gluteus medius muscles which lies against the ilium must be resected en-bloc with the tumor. It is important to try to spare as much substance of the gluteus medius muscle as possible because it will serve for reconstruction of the abductor mechanism and soft-tissue coverage of the pelvic cavity.

Isolated resections of the pubis are rare; in most cases these are performed in conjunction with resection of a large periacetabular tumor. Because of the relatively superficial location of the pubis, surgeons tend to assume that pubic resections are simple, and often try to approach a pubic lesion through an inadequate exposure. Wide exposure is essential in order to achieve wide margins of resection as well as for mobilizing the femoral vessels and nerve, bladder, and urethra, which are in close proximity to the pubis.

As opposed to tumors of the ilium, there is no muscular layer between tumors of the pubis and the pelvic organs; the urinary bladder and urethra, which lie directly behind and under the symphysis pubis, are usually only a few millimeters from the growing edge of a bone sarcoma or directly invaded by metastatic carcinomas of the pubic region.

The pubis does not bear weight, which is transmitted directly to the lower extremities via the hip joints. The lack of one or two pubic bones has minimal impact on stability of the pelvic girdle because of the presence of intact sacroiliac joints. Reconstruction is therefore not indicated following resection of the pubis.

SURGICAL TECHNIQUE

Type I Resection

The patient is positioned in a semilateral position (45°). The utilitarian pelvic incision, that was described in detail in Chapter 10, is used; its ilioinguinal component is advanced medially to the symphysis pubis and its posterior arm is brought to the level of the sacroiliac joint (Figure 26.1).

All muscle attachments, with the exception of iliacus and gluteus medius which are resected en-bloc with the tumor, are removed from the iliac crest. The abdominal wall musculature, sartorius, and tensor fasciae lata are transected from the iliac crest and reflected away from the ilium. The rectus femoris muscle remains intact (Figure 26.2). The iliotibial band is transected from its

origin from the iliac crest and reflected posteriorly along with the gluteus maximus. Large fasciocutaneous flaps are raised and reflected medially and posteriorly.

The plane between the iliacus and the psoas muscle is developed with caution because the femoral nerve lies in that space. The psoas muscle and the femoral nerve are reflected medially and the iliacus muscle is transected through its substance (Figure 26.3). The

external iliac artery, which lies against the lower margin of the ilium, gives no major branches along the inner table of the ilium and ligation of large blood vessels is therefore not required in Type I pelvic resection. Most tumors of the ilium break through the outer table and push the gluteus medius muscle laterally. The gluteus medius muscle is transected through its substance, 2–3 cm distally to the inferior border of the tumor

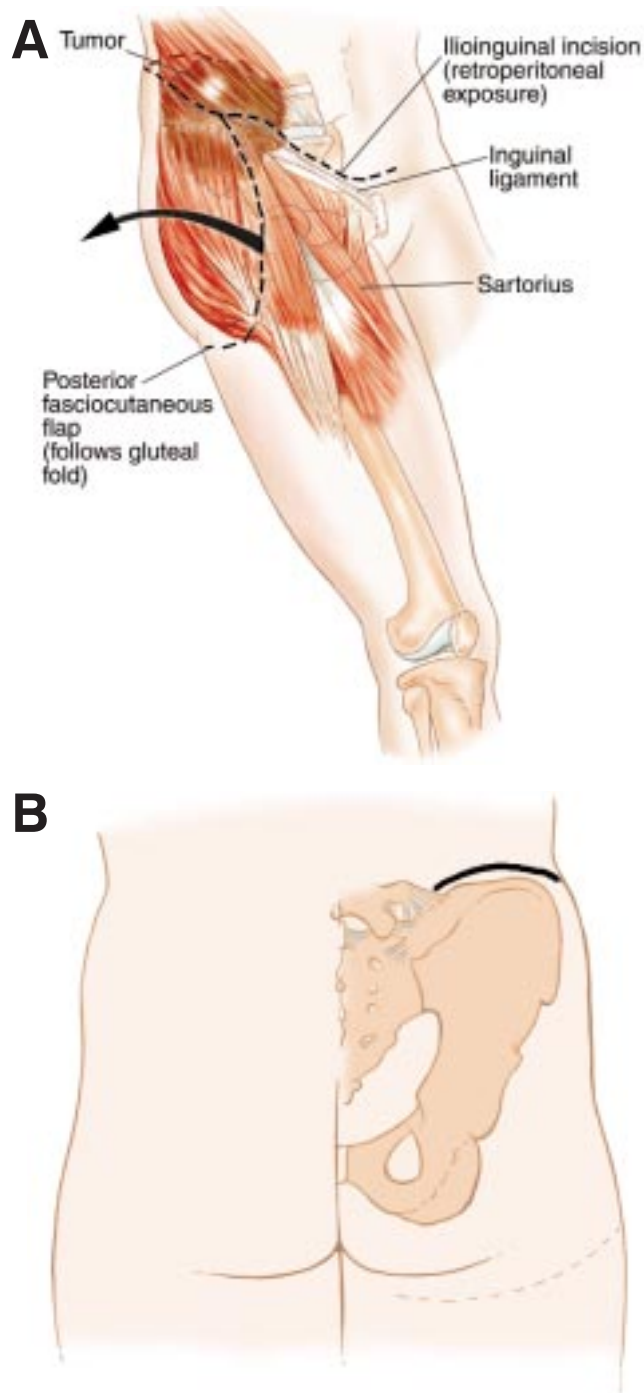


Figure 26.1 (see also following page) (A) Incision and surgical approach. The entire utilitarian incision is used for Type I (iliac) resection. The posterior fasciocutaneous flap exposes the entire retrogluteal area; the sciatic notch, the sciatic nerve, the abductor muscles and the hip joint. This approach provides a good exposure of the retroperitoneal space as well as the posterior retrogluteal area and permits a safe resection of the ilium. The ilioinguinal component is advanced medially to the symphysis pubis and, (B) posteriorly to the sacrum. (C) Plain radiograph showing an extremely high-grade MFH arising from the superior and inferior pubic ramus involving the entire obturator foramen, pelvic floor, and medial and supra-acetabular aspect of the acetabulum (solid arrows). This was the first patient treated at our institution with a combined Type II/Type III resection in lieu of a hemipelvectomy. He received intra-arterial chemotherapy preoperatively (1988) and had median tumor necrosis of 95%. He underwent resection and reconstruction and remains free of local and disseminated disease at 12 years. (D) Gross specimen following Type II/Type III pelvic resection performed in 1988 (IL = portion of the ilium; A = acetabulum; and P = the entire pelvic floor including superior and inferior pubic ramus). (E) Gross specimen following a complete internal hemipelvectomy (Type I/Type II/Type III pelvic resection). IL shows portion of the ilium; A = acetabulum; SP = the superior pubic ramus, IP = the inferior pubic ramus and pubis. The femoral head is seen still attached by the ligamentum teres. It is our practice (for large periacetabular tumors) not to remove the femoral head separately. There is a small incidence of tumor spreading from the periacetabular region, especially the medial wall, through the ligamentum teres, into the synovium and femoral head. Therefore, we attempt to perform an extra-articular resection. (F) Radiograph of the resected specimen showing complete involvement of the hemipelvis. The defect superiorly was created by an open biopsy.

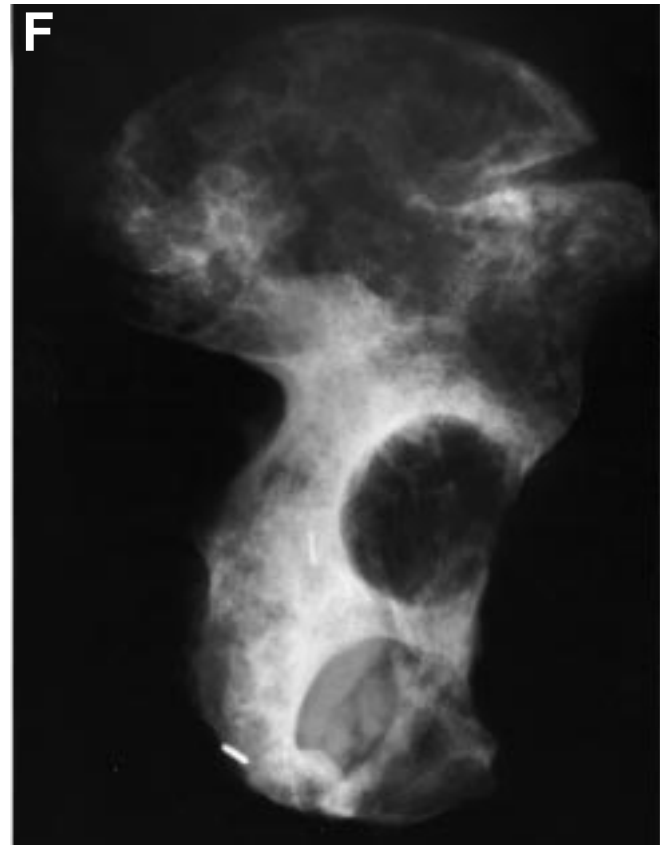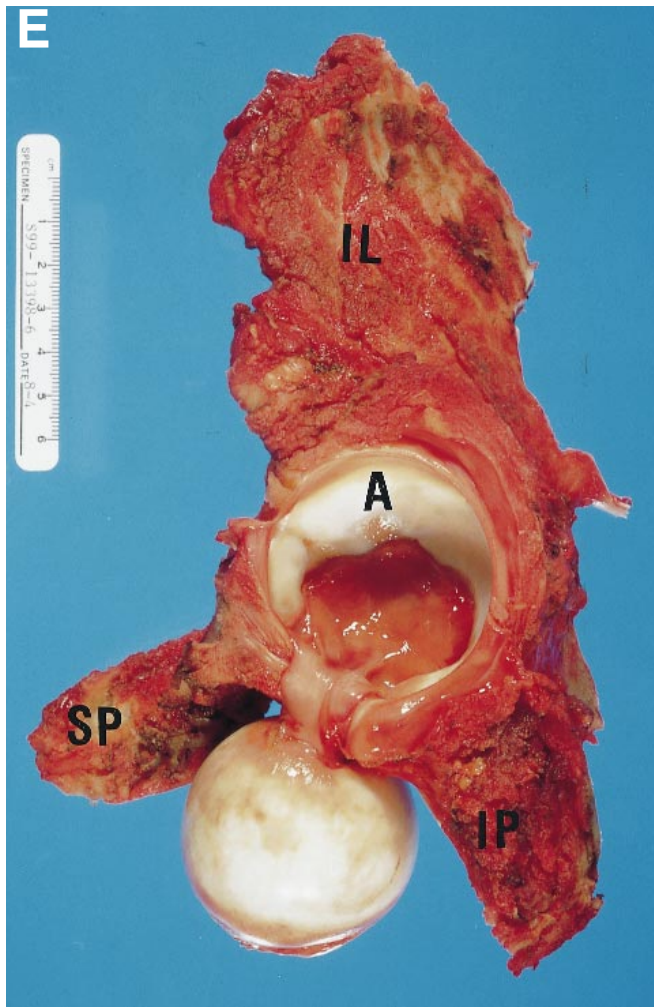
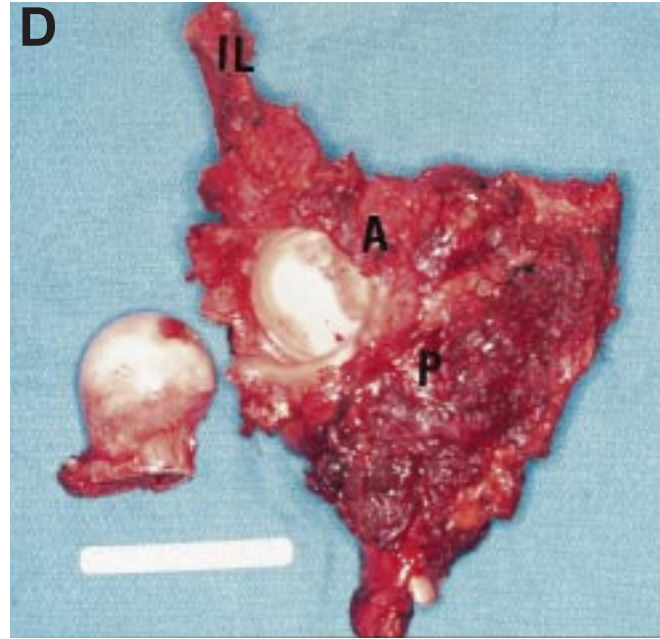

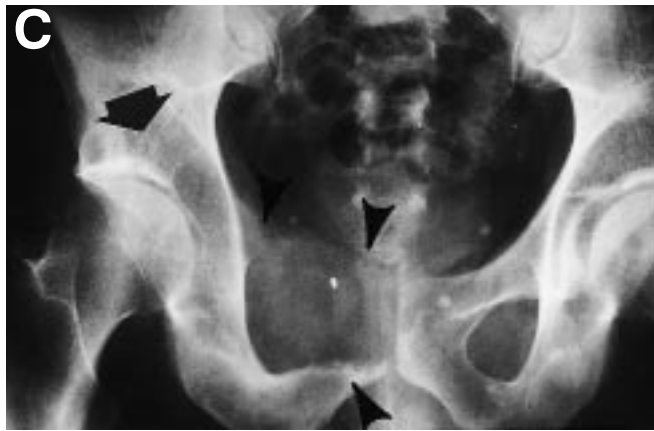
Figure 26.1 C-F

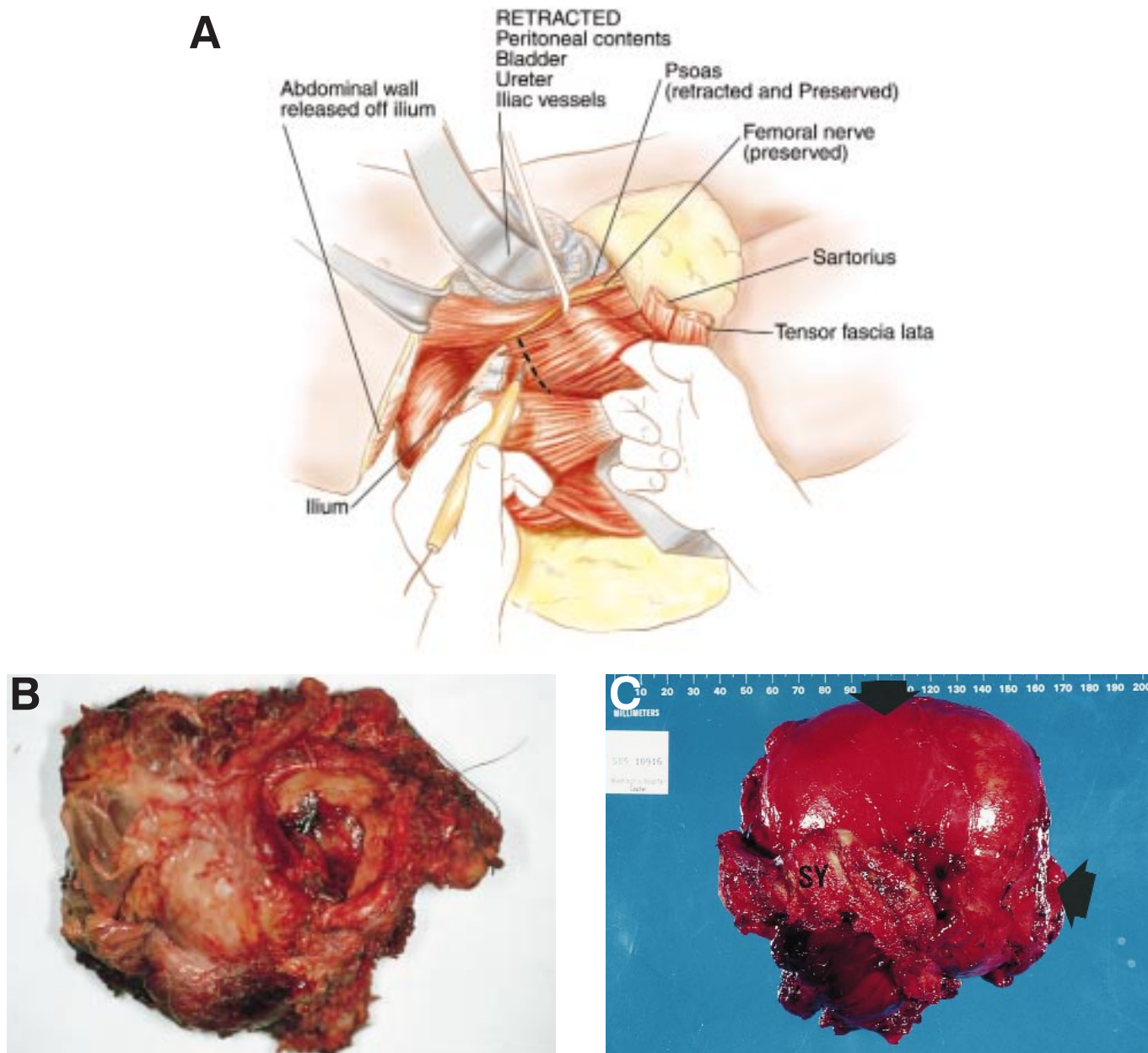


Figure 26.2 (A) Posterior exposure and muscle releases. The abdominal wall musculature is transected off of the iliac crest. The sartorius and tensor fasciae lata muscles are transected from their tendinous and reflected distally. The rectus femoris muscle remains intact. Large fasciocutaneous flaps are raised and reflected medially and posteriorly. The iliotibial band is transected from its origin from the iliac crest and reflected posteriorly along with the gluteus maximus. (B) Gross specimen of a combination Type II/Type III pelvic resection. The acetabulum can be visualized and a large tumor mass involving the entire floor and the superior and inferior pubic rami was removed en-bloc. Type II/Type III pelvic resections are extremely difficult and can often be performed only following induction chemotherapy if there is a good response to the chemotherapy. (C) Gross specimen following a Type III pelvic resection. There is a large tumor mass arising from the obturator internus muscle (solid arrows). The symphysis pubis (SY) is seen. The medial wall of the acetabulum was not involved, but was the closest margin. In general, following a Type II or Type III pelvic resection for low- or high-grade sarcomas, radiation therapy is used postoperatively to avoid a local recurrence.

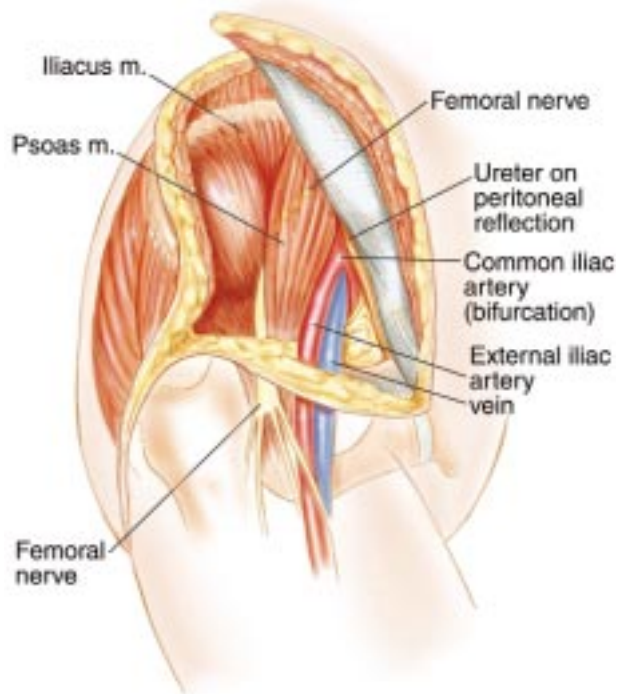


Figure 26.3 Anterior (retroperitoneal) exposure. The retroperitoneal space is easily exposed and explored through the ilioinguinal component of the incision. The plane between the iliacus and the psoas muscle is developed with caution because the femoral nerve lies in that space. The psoas muscle and the femoral nerve are reflected medially and the iliacus muscle is transected through its substance. The femoral nerve is preserved.

(Figure 26.4). It is important to try to save as much muscle belly as possible because it will be the major component in soft-tissue coverage of the pelvic content and will be necessary for reconstruction of the abductor mechanism.

Osteotomy of the ilium is performed, using a malleable retractor which is inserted through the greater sciatic notch, along the inferior border of the inner table, and out just underneath the anterior superior iliac spine, to protect the pelvic viscera (Figure 26.5). The ilium is transected along the dotted line, leaving the origin of the rectus femoris muscle and the roof of the acetabulum intact. Osteotomy of the posterior aspect of the ilium is then performed; a malleable retractor is positioned through the greater sciatic notch, along the posterior border of the ilium and in parallel to the ipsilateral sacral ala. The osteotomy is moving to the inside (Figure 26.5 – insert).

The most important component of soft-tissue reconstruction is the attachment of the proximal rim of

the gluteus medius muscle to the abdominal wall musculature. Even if the entire gluteus medius muscle was spared, the attachment of these two muscle groups, which are not anatomically connected, creates a significant tension, which can be reduced by placing the lower extremity in abduction. The suture line is reinforced with the tensor fasciae lata and sartorius muscles (Figure 26.6). Closure of the muscle layer must be meticulously executed because poor healing and wound dehiscence will expose the abdominal and pelvic contents and will be difficult to manage.

The extremity is kept in balanced suspension for at least 5 days. An abduction brace is customized for the patient. Continuous suction is required for 3–5 days. Perioperative intravenous antibiotics are continued until the drainage tubes are removed. Postoperative mobilization with an abduction brace and weight-bearing as tolerated are continued for 3 weeks, by the end of which the abduction brace is removed.

Type II Resection

Resection of the acetabulum alone is termed a periacetabular resection. This is classified as a Type II pelvic resection. Tumors of the acetabulum are difficult to treat. Various techniques of reconstruction have been described, including: allografts, prosthetic replacement, ischiofemoral arthrodesis, and the saddle prosthesis.

The surgical technique of resection requires three osteotomies be performed: superior pubic ramus, ischium, and supra-acetabular. The surgical approach utilizes the ilioinguinal incision as well as the retrogluteal approach.

Chapter 28 describes in detail the surgical technique and reconstruction of periacetabular (Type II) defects.

Type III Resection

The patient is positioned in a slight elevation of the ipsilateral hip. The ilioinguinal component of the utilitarian pelvic incision with a caudal extension is used (Figure 26.7). This incision allows exposure and mobilization of the femoral vessels, nerve, and bladder. The caudal extension of incision is used to expose the ischium, which is resected through the ischiorectal fossa when the resection is performed for a large pubic lesion.

Large myocutaneous flaps are raised. The spermatic cord is reflected medially. The inguinal ligament is transected from its pubic insertion and reflected laterally. The neurovascular bundle (femoral artery, vein, and nerve) is reflected laterally, exposing the origin of the adductor magnus and pectineus muscles, which is transected off the pubis and reflected distally. Using the caudal component of the incision, the origin of the hamstrings, adductors, and gracilis is transected off the

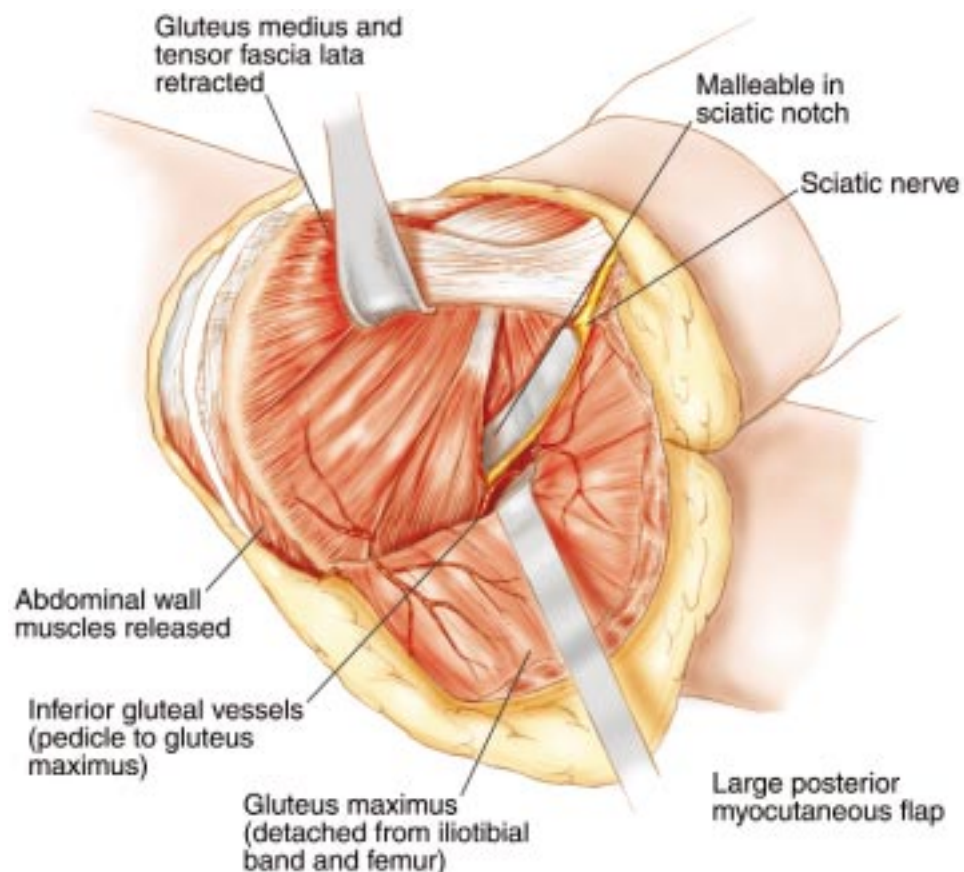


Figure 26.4 Posterior exposure and release of gluteal muscles. The retrogluteal area is exposed. The gluteus maximus muscle is released from the iliotibial band and from the femur and reflected posteriorly. The sciatic nerve is identified and preserved. All of the remaining abdominal muscles are released from the wing of the ilium. The gluteus medius muscle is transected through its substance, 2–3 cm distally to the inferior border of the tumor; it is important to try to save as much muscle belly as possible.

ischium and reflected distally (Figure 26.8). A first malleable retractor is placed behind the symphysis pubis, in front of the bladder. The second malleable retractor is placed behind the superior pubic ramus and in front of the inferior pubic ramus, medial or lateral to the ischium, depending on the required oncological margins. Osteotomy through the symphysis pubis and pubic rami is performed. It is important to smooth the sharp bony edges, especially these which lie against the bladder.

Surgical wounds around the groin are notoriously known to be associated with a high incidence of dehiscence and infection. Meticulous wound closure with adequate drainage is therefore mandatory. Continuous suction is required for 3–5 days. Perioperative intravenous antibiotics are continued until the drainage tubes are removed. Postoperative mobilization with weight-bearing as tolerated is allowed.

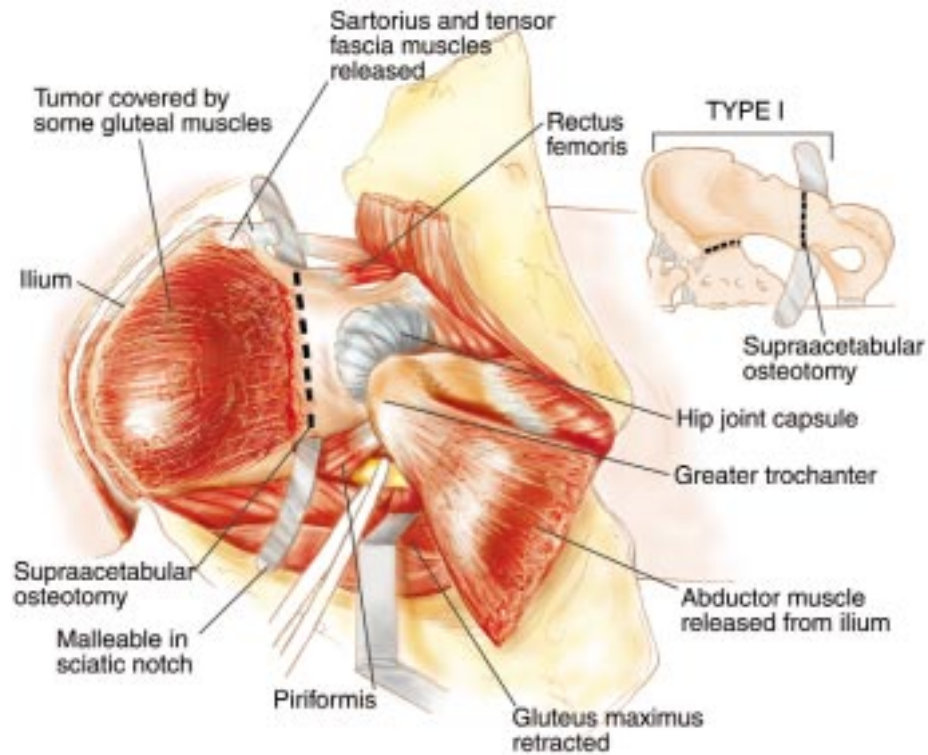


Figure 26.5 Supra-acetabular osteotomy and sacroiliac disarticulation. A malleable retractor is inserted through the greater sciatic notch, along the inferior border of the inner table, and out just underneath the anterior superior iliac spine, to protect the pelvic viscera. The ilium is transected above the hip capsule, leaving the origin of the rectus femoris muscle and the roof of the acetabulum intact. Care is taken not to enter the hip joint. (*Insert*) The sacroiliac joint is opened from within the pelvis. The iliac vessels must be mobilized and retracted before attempting to open the sacroiliac joint. The malleable retractor is positioned through the greater sciatic notch, along the posterior border of the ilium and in parallel to the ipsilateral sacral ala; the osteotomy is performed from the inside out.

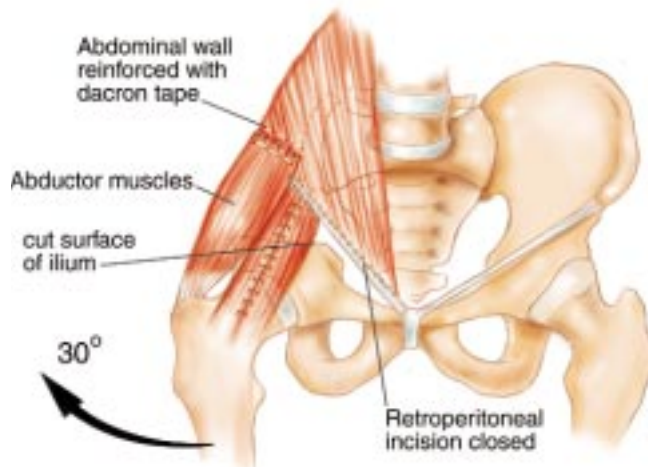


Figure 26.6 Soft-tissue reconstruction. The gluteus medius muscle is sutured to the abdominal wall musculature with the ipsilateral lower extremity in abduction. Dacron tape must be used to reinforce this reconstruction. The suture line is also reinforced by oversewing the tensor fasciae lata and sartorius muscles.

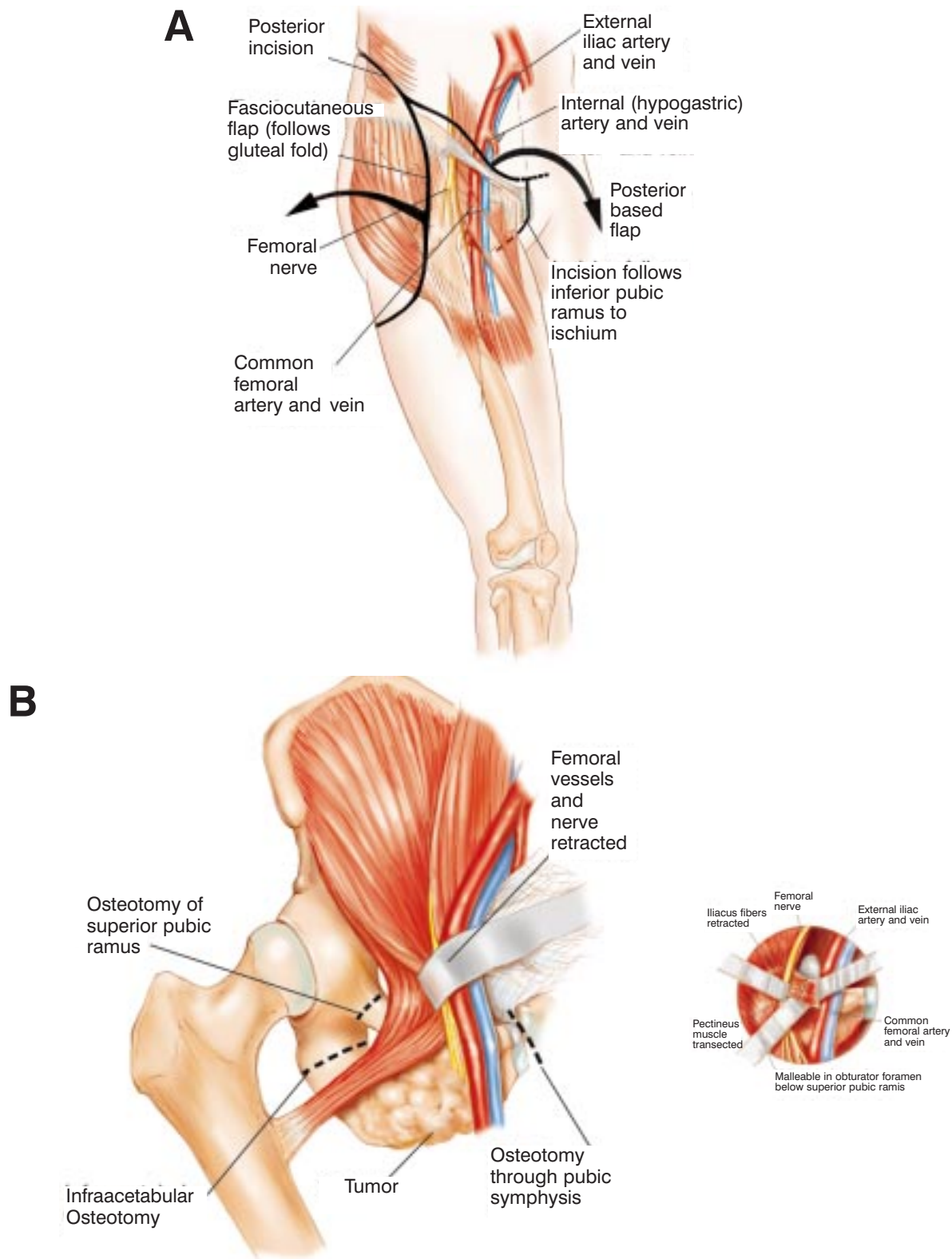


Figure 26.7 Incision. (A) The ilioinguinal component of the utilitarian pelvic incision with a modified perineal extension are used. The ilioinguinal component is advanced medially to the symphysis pubis. (B) Schematic of the three osteotomies required to remove the pelvic floor. A wide exposure of all three sites is required. Schematic of surgical exposures. The superior pubic ramus is approached through the anterior ilioinguinal incision. The spermatic cord is reflected medially. The inguinal ligament is transected from its pubic insertion and reflected laterally. The neurovascular bundle (femoral artery, vein, and nerve) is reflected medially, exposing the origin of the pectineus muscles, which is transected to expose the underlying bone, the superior pubic ramus (*insert*). The superior pubic ramus is transected with a high-speed burr. Care must be taken to retract and protect the femoral vessels and the femoral nerve. Through the perineal component of the incision the origin of the hamstrings, adductors, and gracilis is transected off of the ischium and reflected distally.

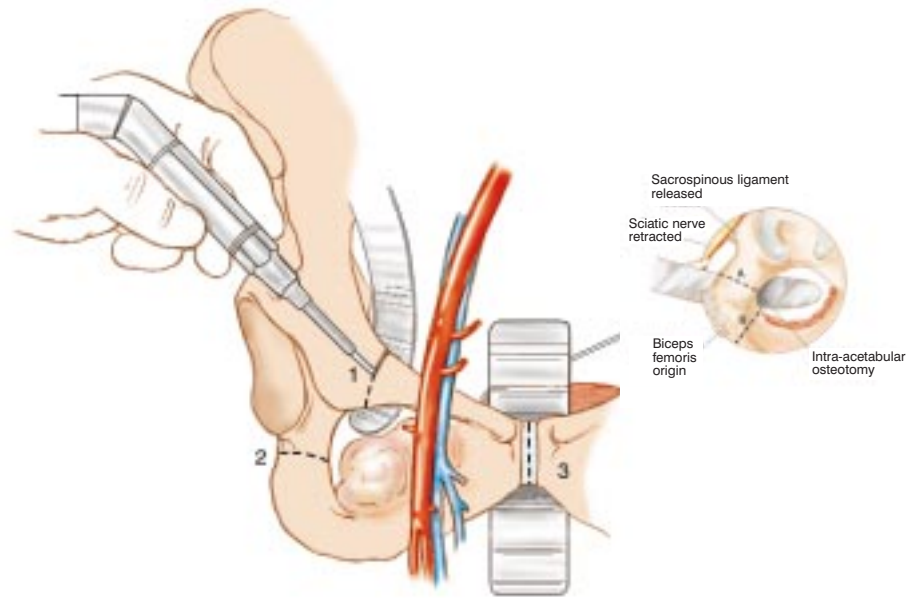


Figure 26.8 Transection of the symphysis pubis and ischial osteotomy. A malleable retractor is placed behind the symphysis pubis, in front of the bladder. This retractor protects the bladder and the urethra. The second osteotomy is performed either through the ischium or the inferior pubic ramus, depending upon the oncological need. A malleable retractor is placed behind the ischium, i.e. medial and lateral to the inferior pubic ramus (**insert**). The ischium (or inferior pubic ramus) are identified by palpation and the attaching or overlying muscles are transected with a cautery. The quadratus femoris muscle must be transected as it crosses the ischium to provide exposure and correct placement of the retractors.