

Unknown Musculoskeletal Tumor Cases Part B

Cases 11-20

James C. Wittig, MD
Orthopedic Oncologist
Sarcoma Surgeon
www.TumorSurgery.org

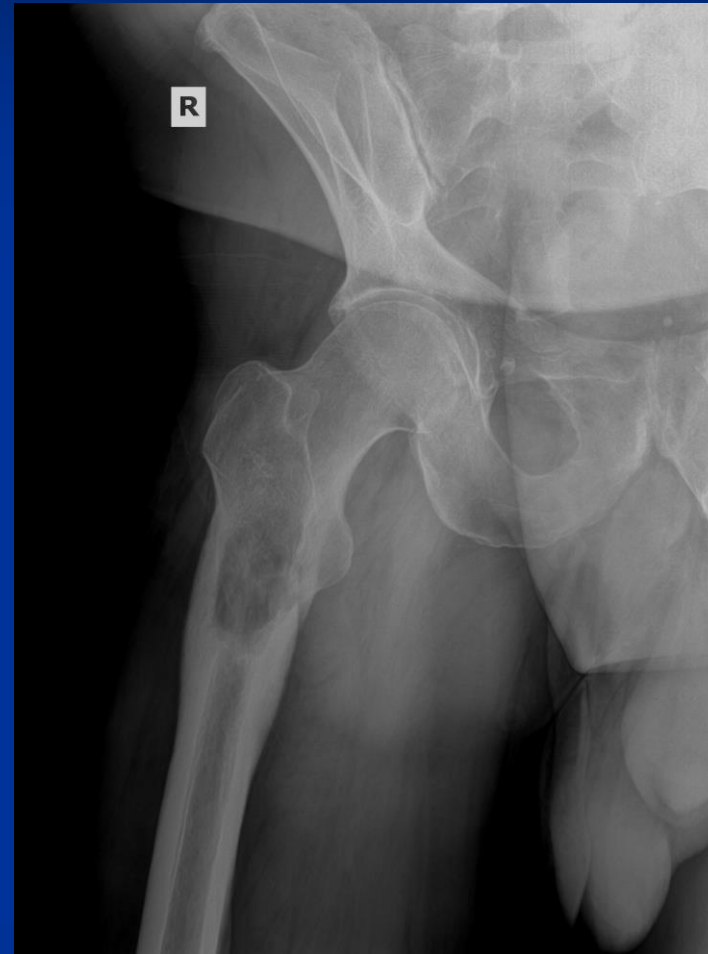
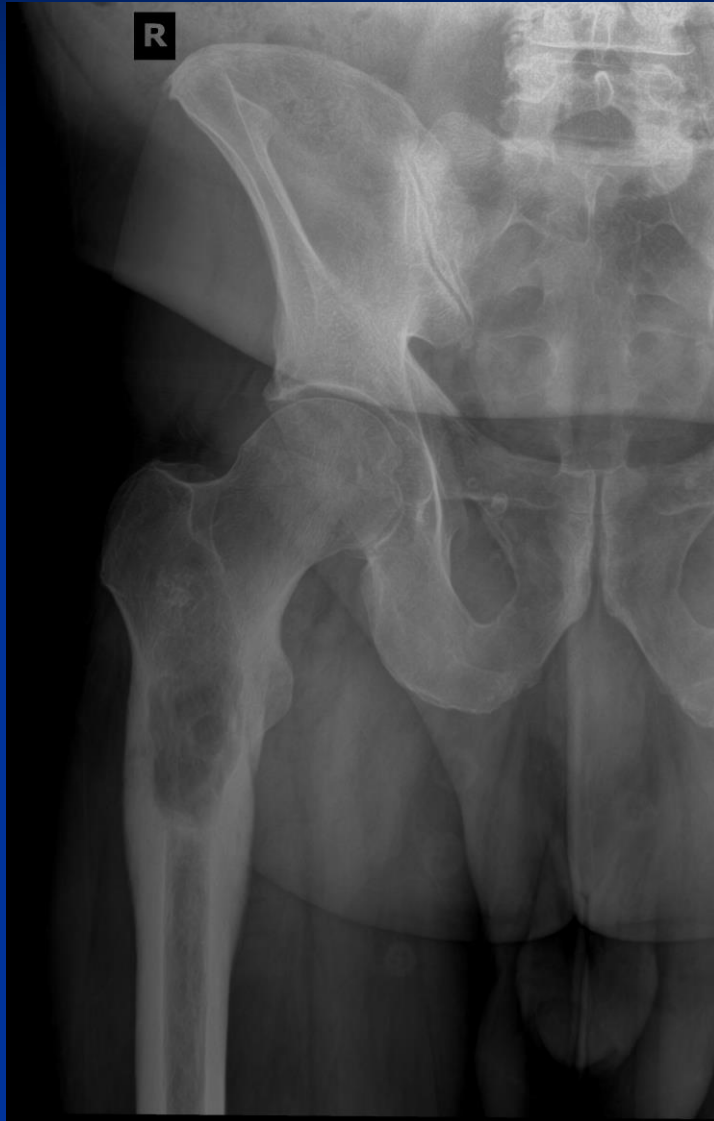
CASE #11

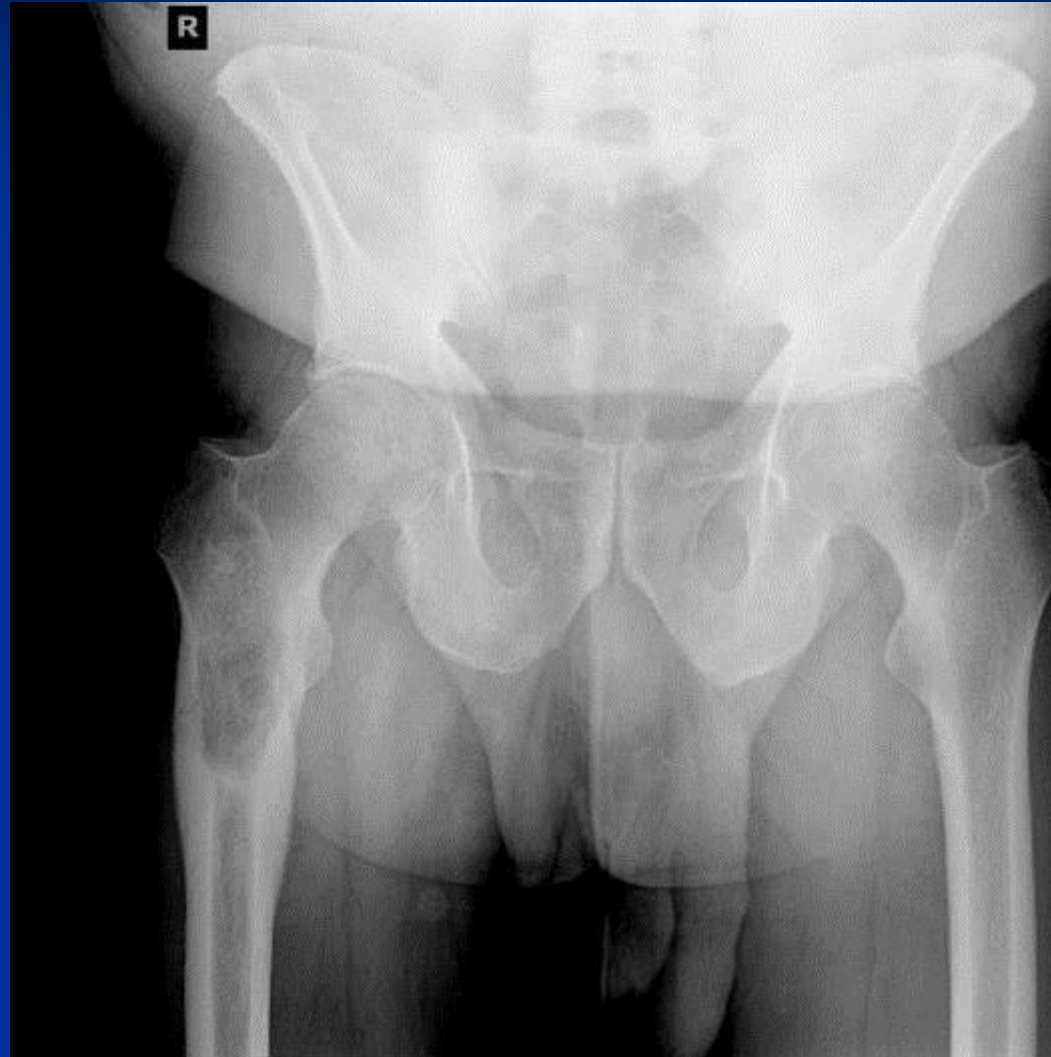
- A fairly active 62 year old male complained of right hip pain. After imaging, a lytic lesion was discovered in his right proximal femur. Physically, the mass was palpable. He had no recall of an accident or trauma, but he noticed pain after walking on the treadmill. Pain has increased over a span of two months. MR showed two lesions, one in the subtrochanteric area and one in his intertrochanteric area.



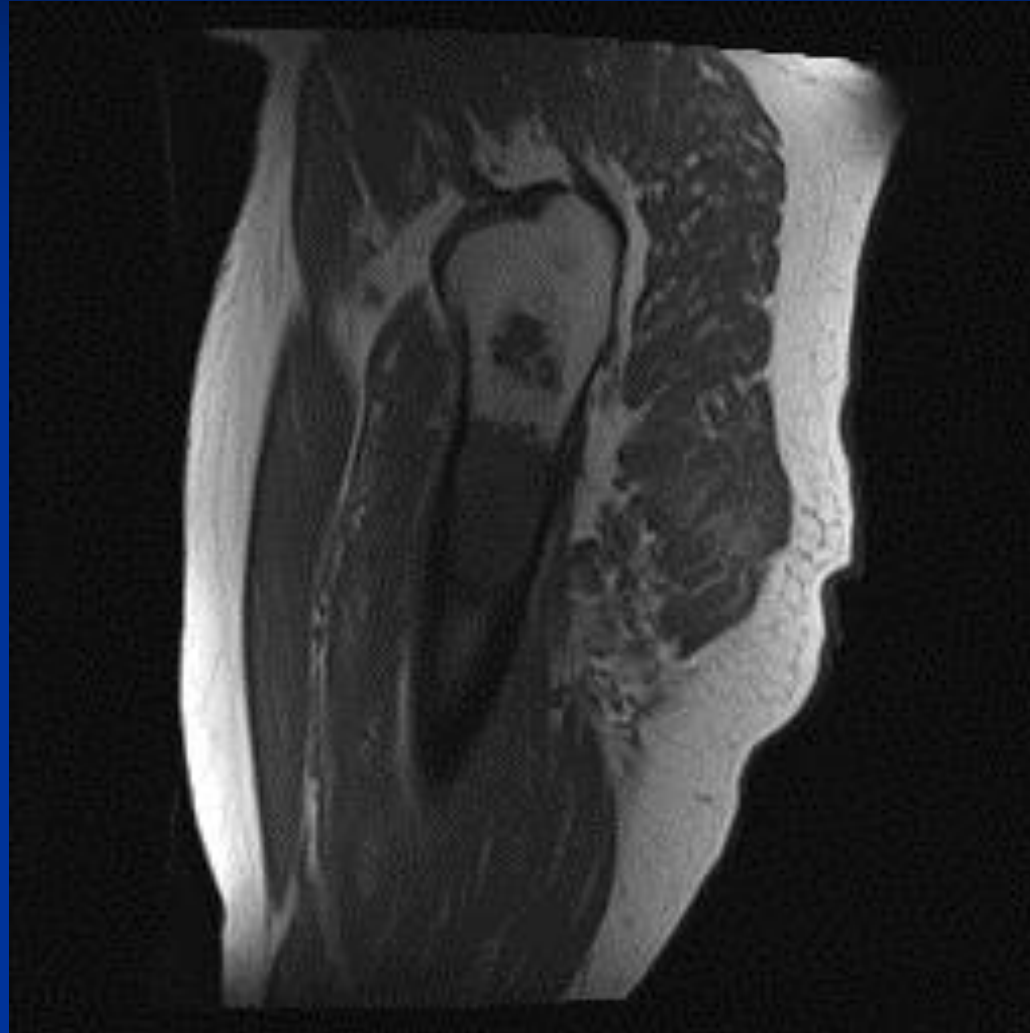
XR Unilateral



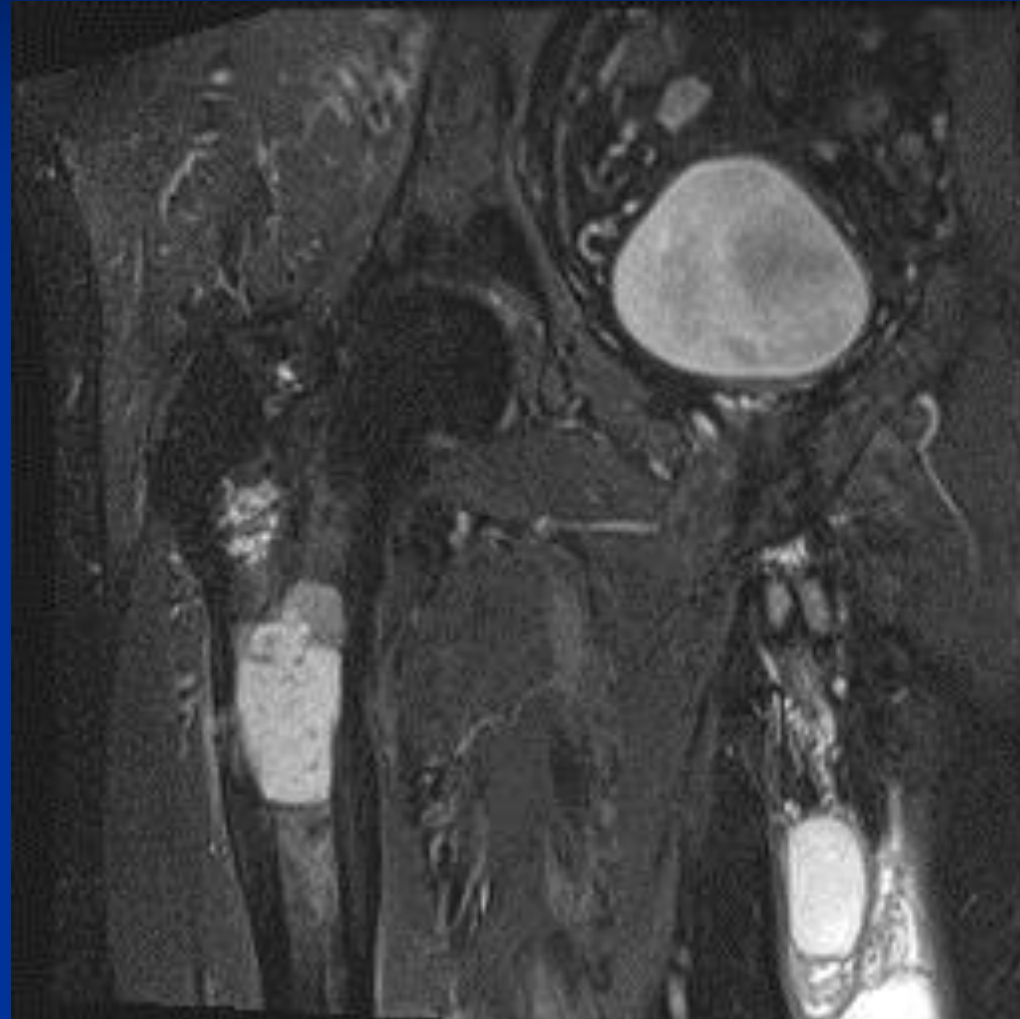
XR Lumbosacral



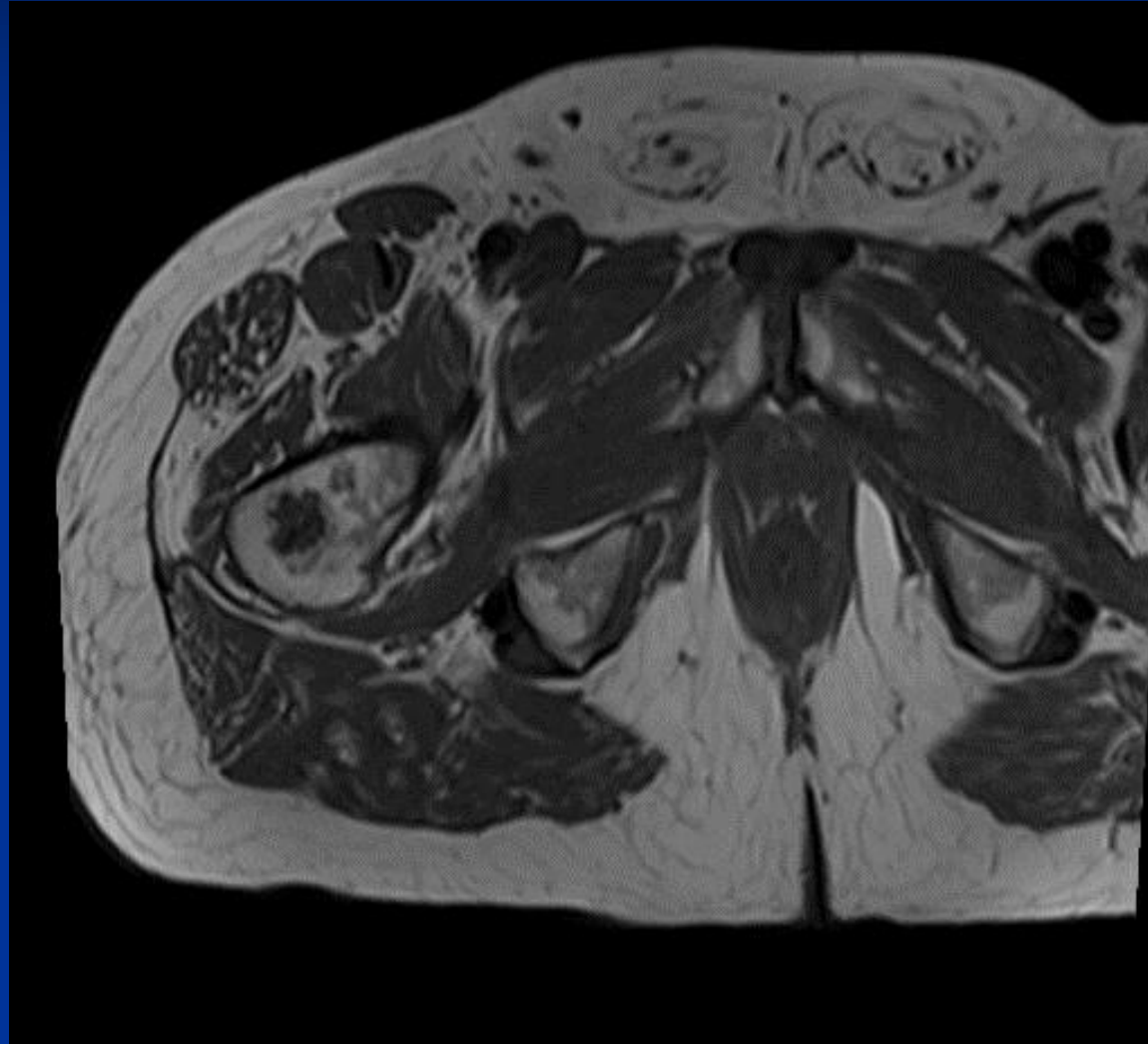
T-1 Sagittal



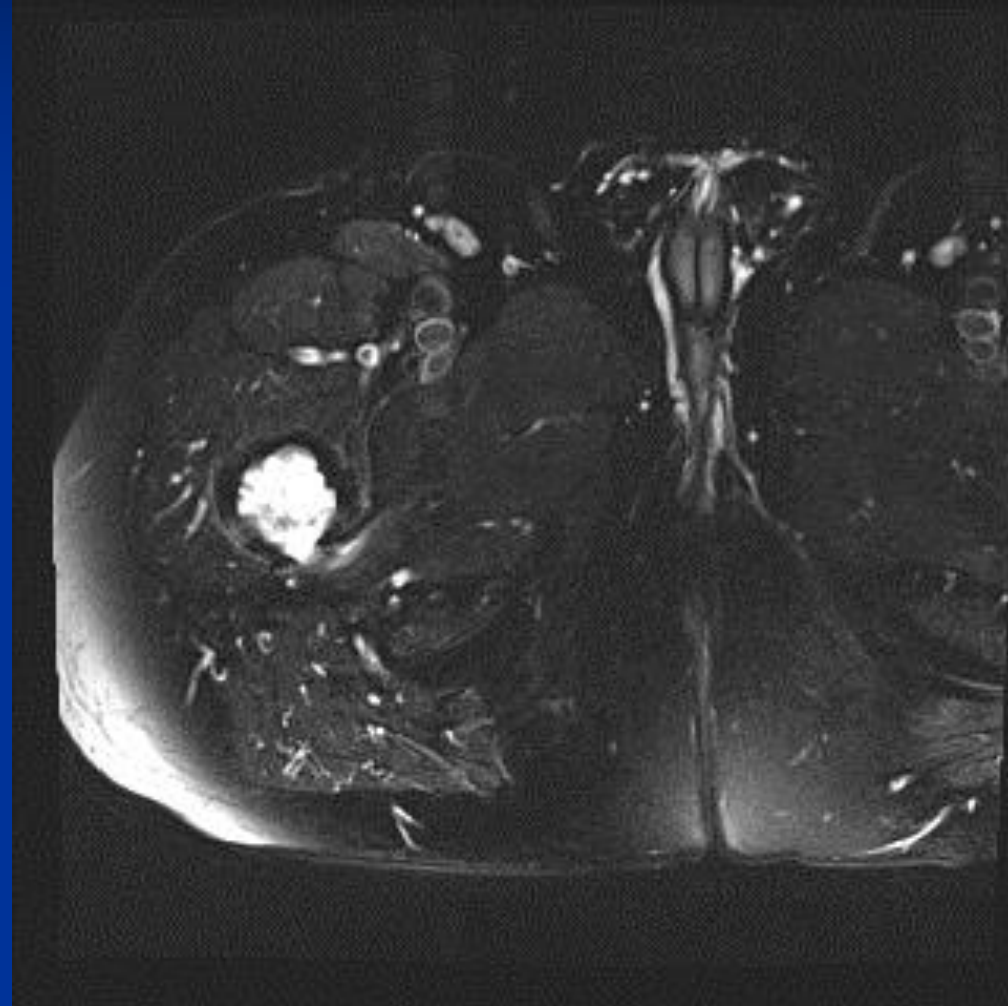
COR STIR

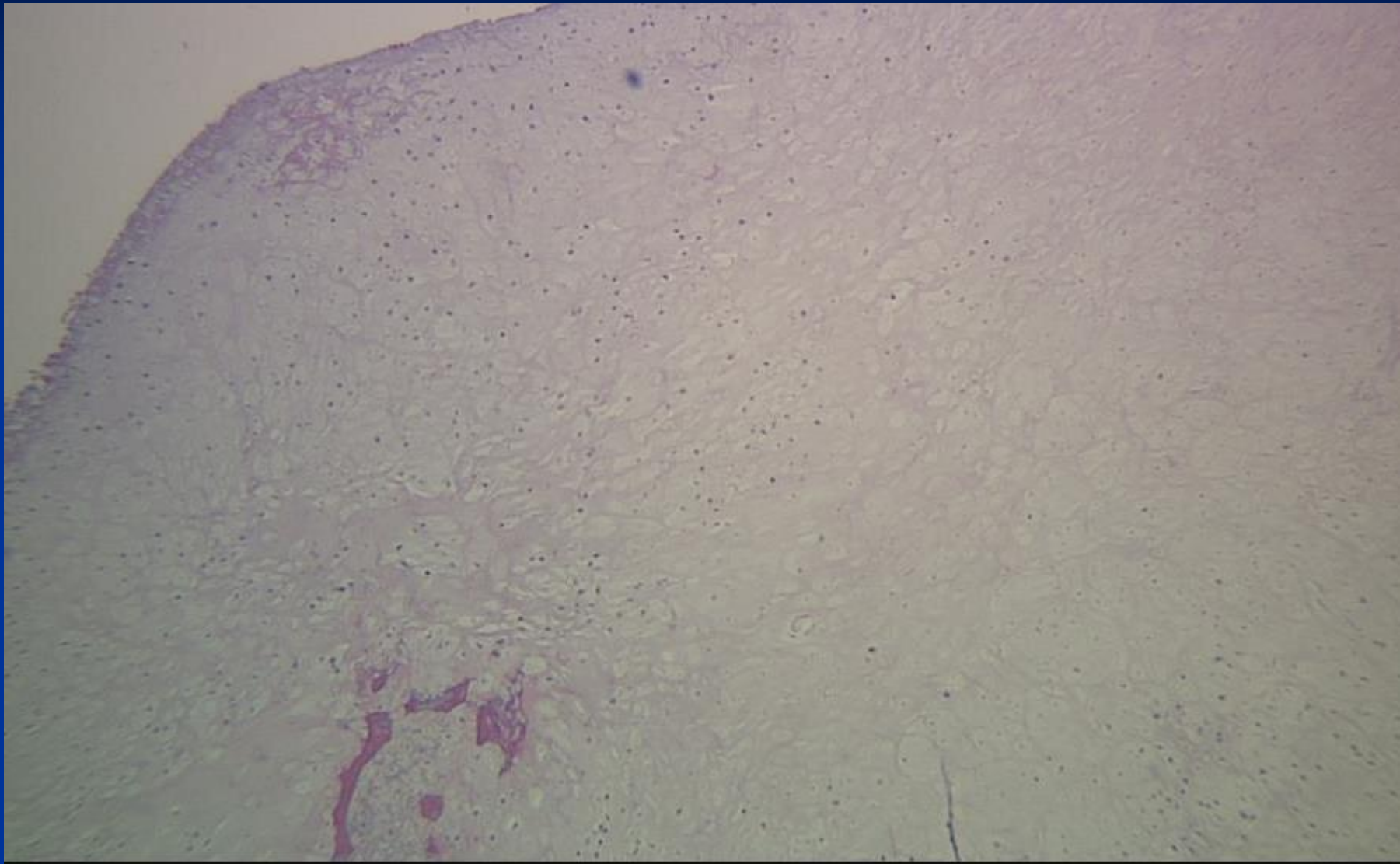


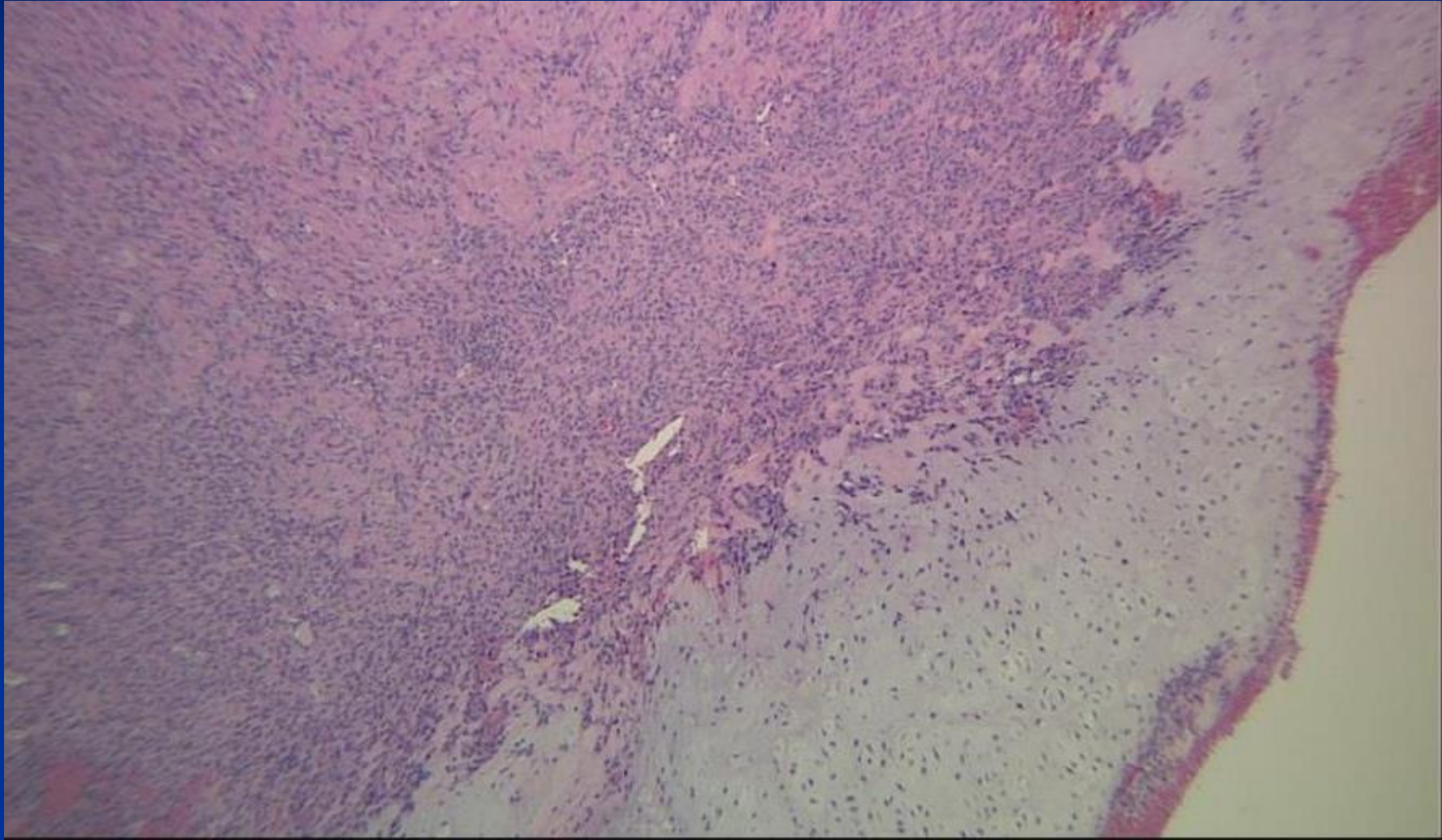
Axial T-1

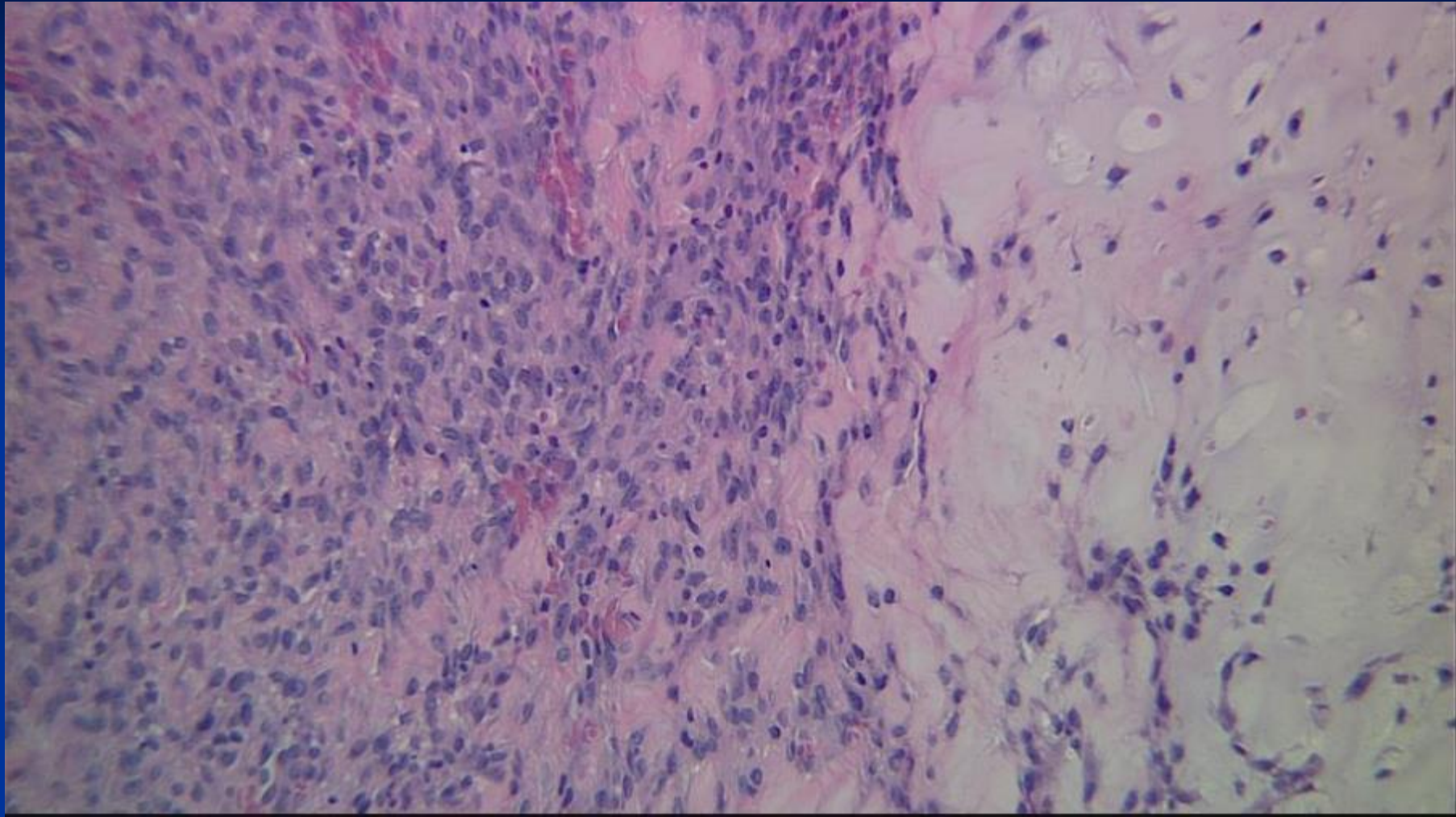


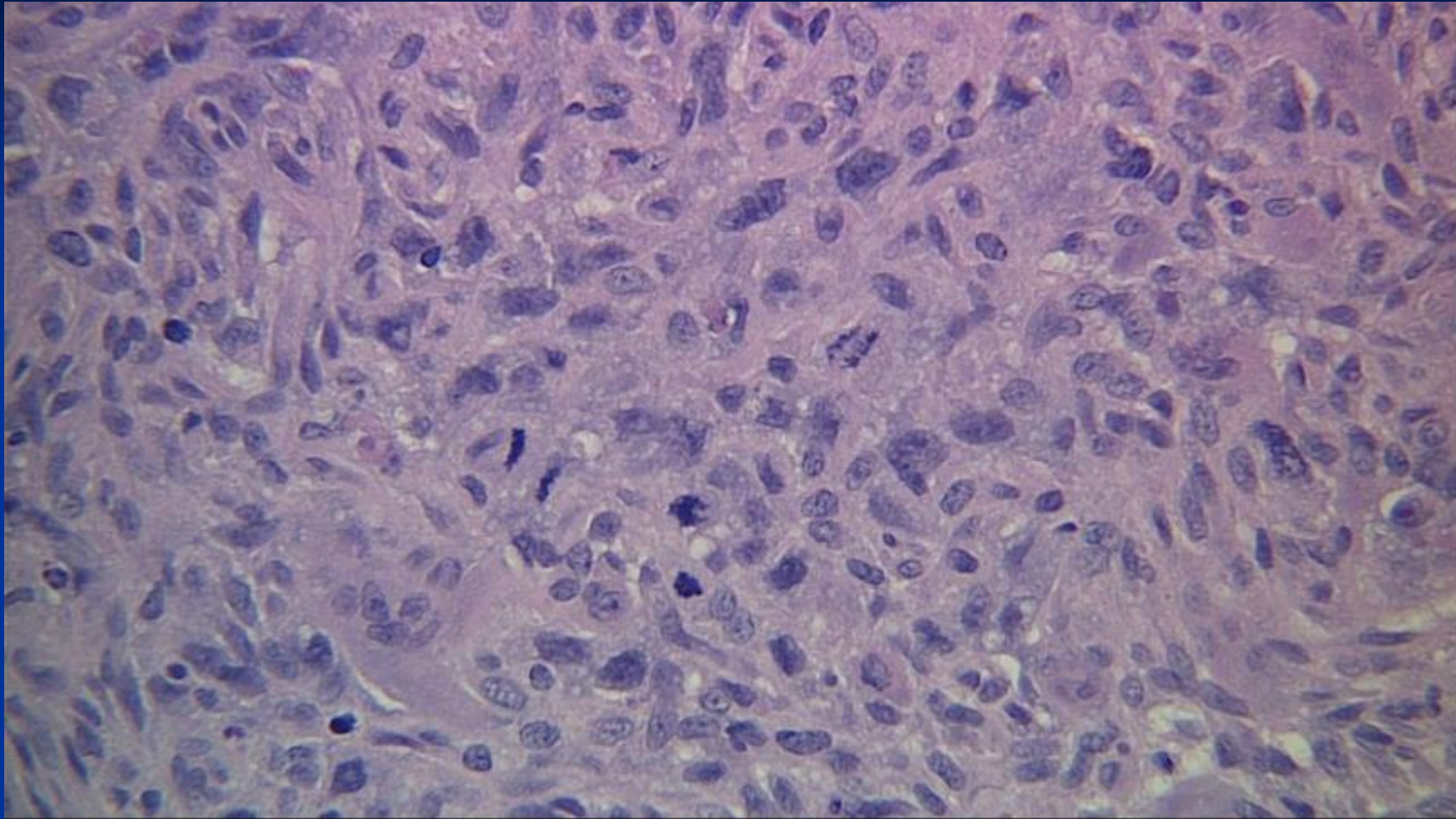
Axial T-2 FS











*Diagnosis Next



Dedifferentiated Chondrosarcoma

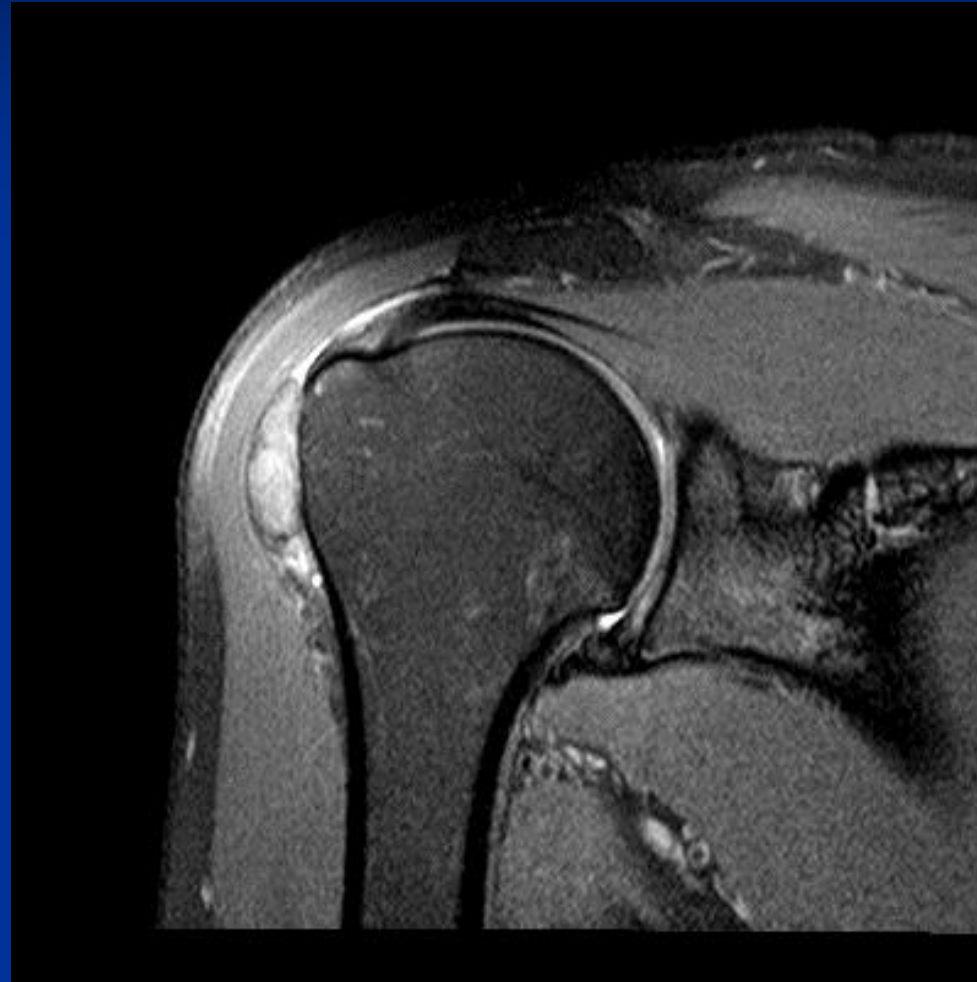

CASE #12

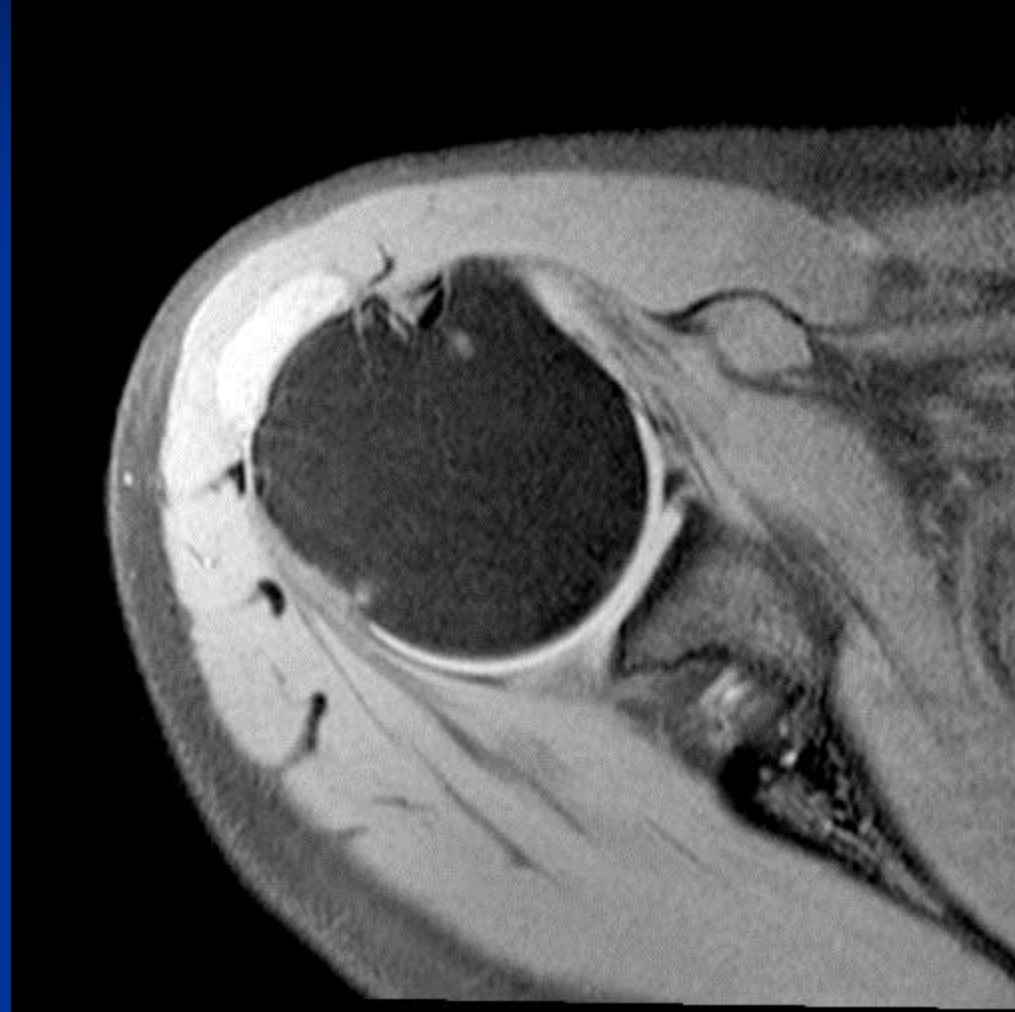
- A 38 year old woman presented with a small painless, mobile, non-tender mass in her right anterior shoulder that was first noticed 3 months ago. The mass has not enlarged. She denies pain, fever, chills, numbness, tingling, and weakness. MRI showed a mass in the subdeltoid bursa. The mass was removed.

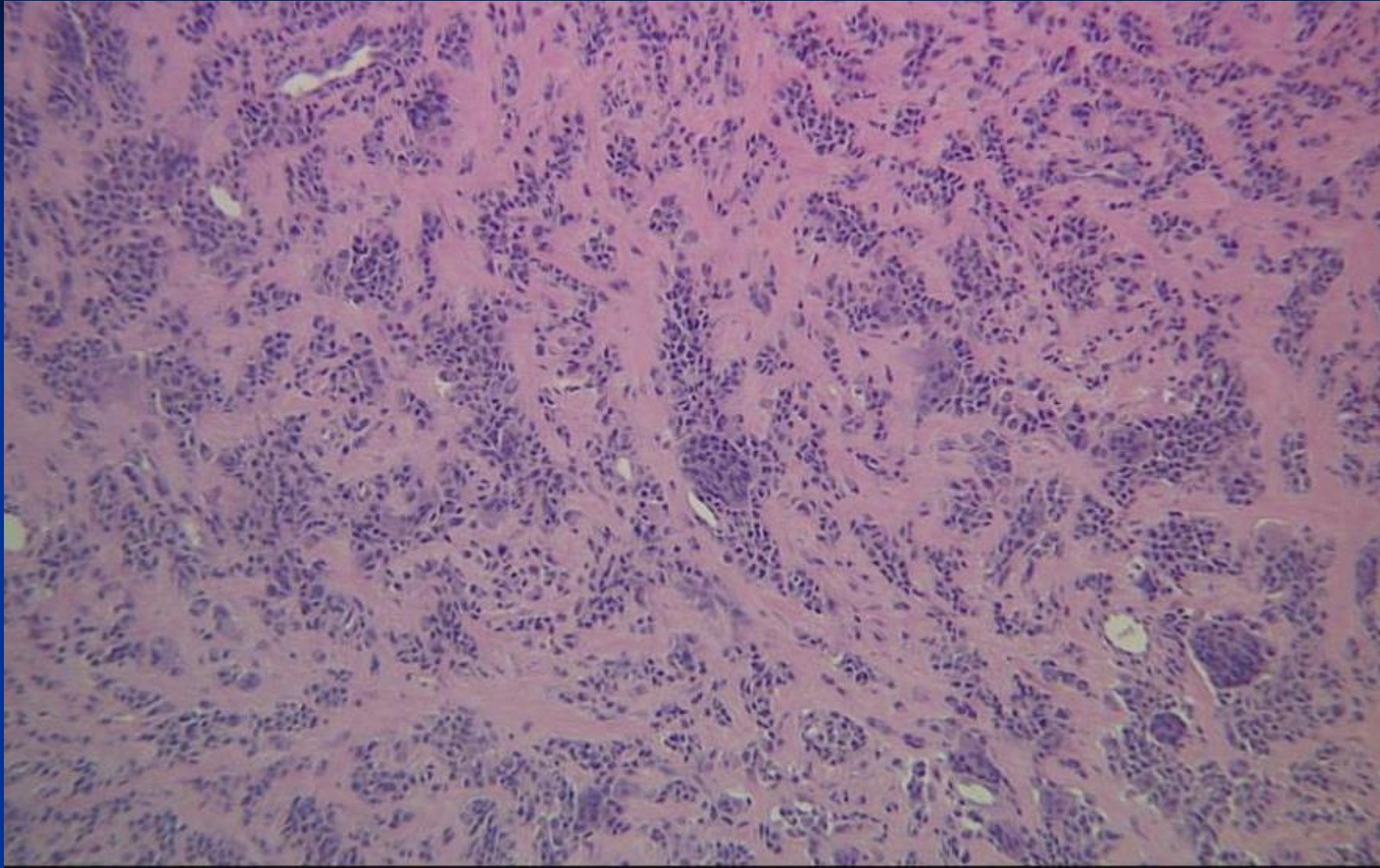


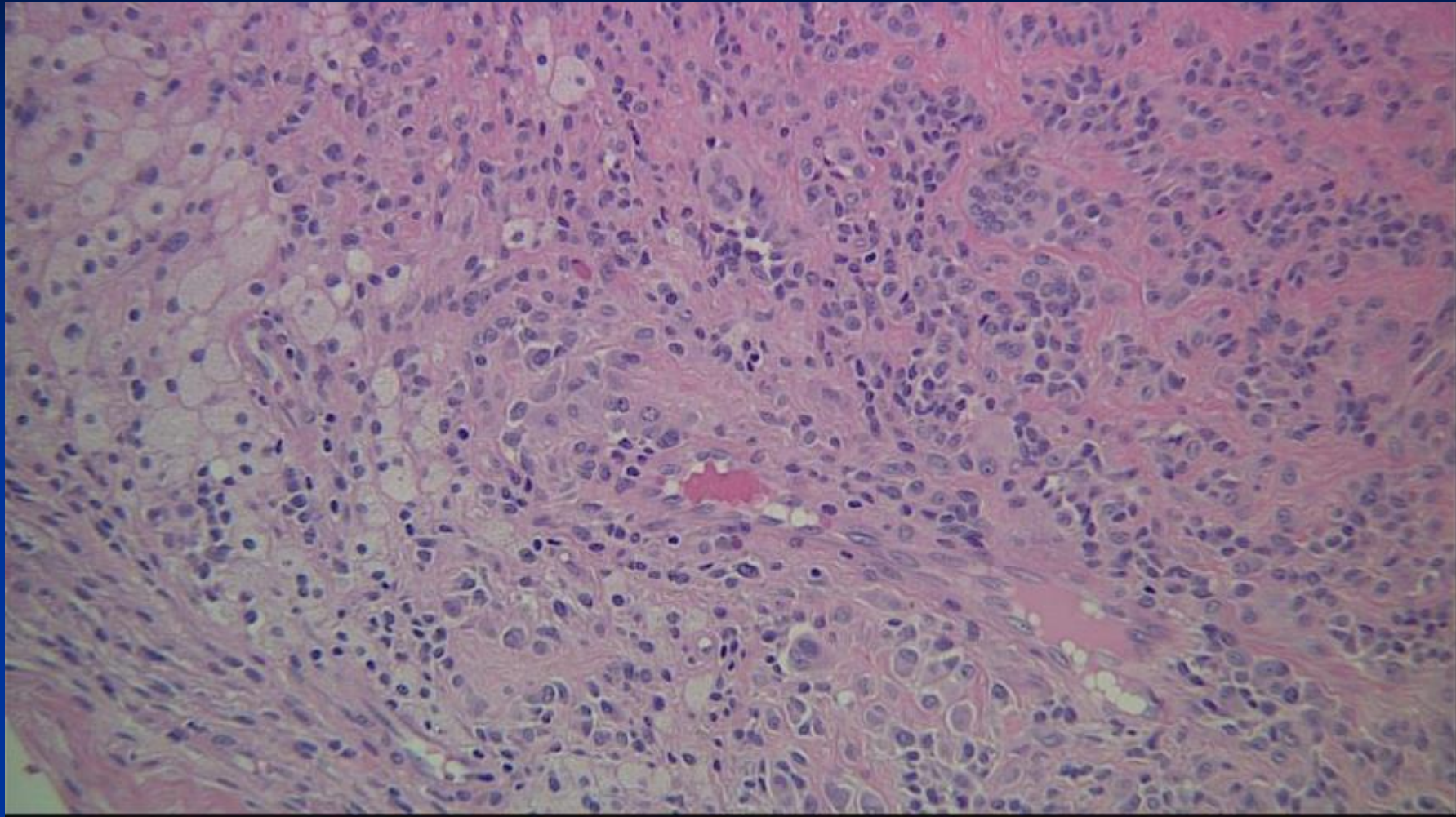
COR T-2 FS Clear

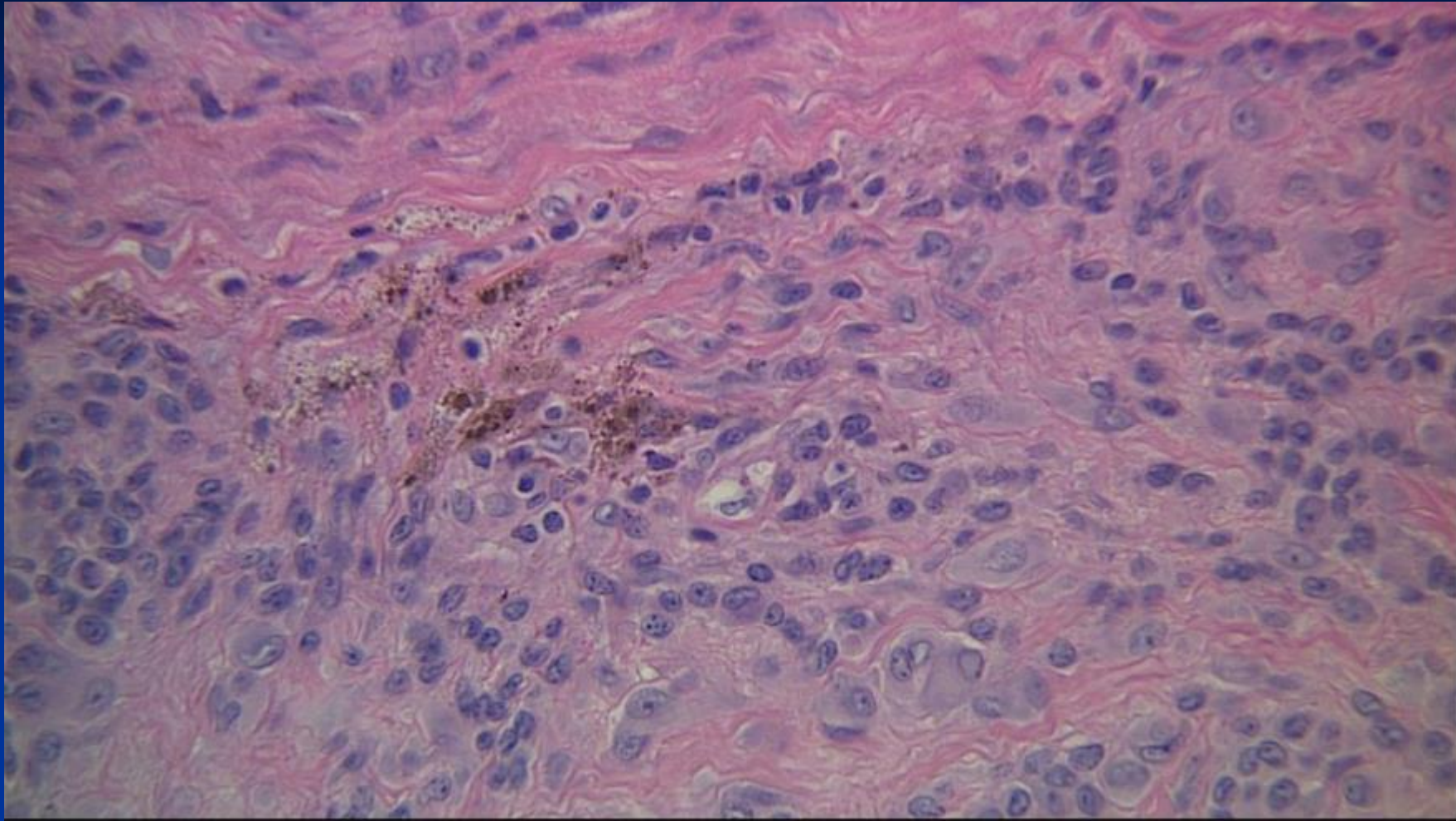


TRS TSE T-1 FS Clear









*Diagnosis Next

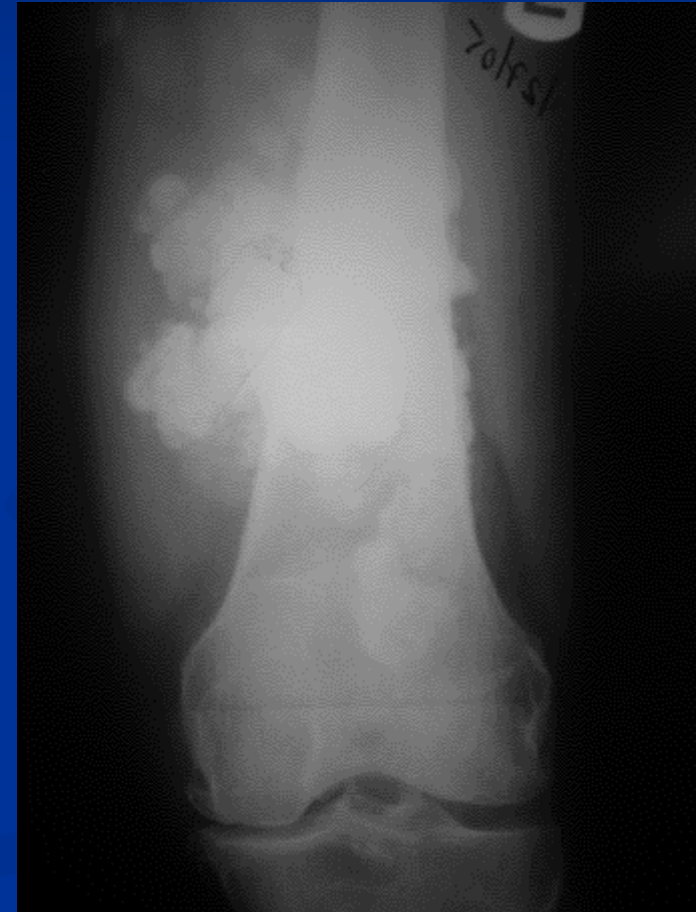

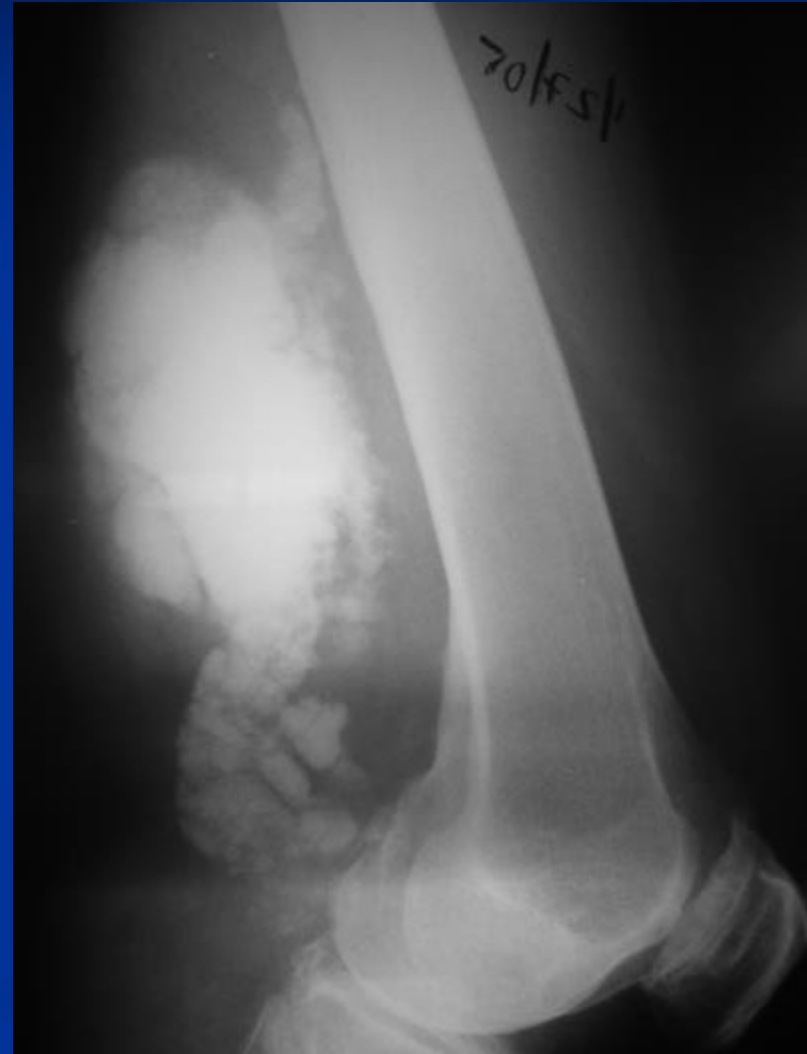
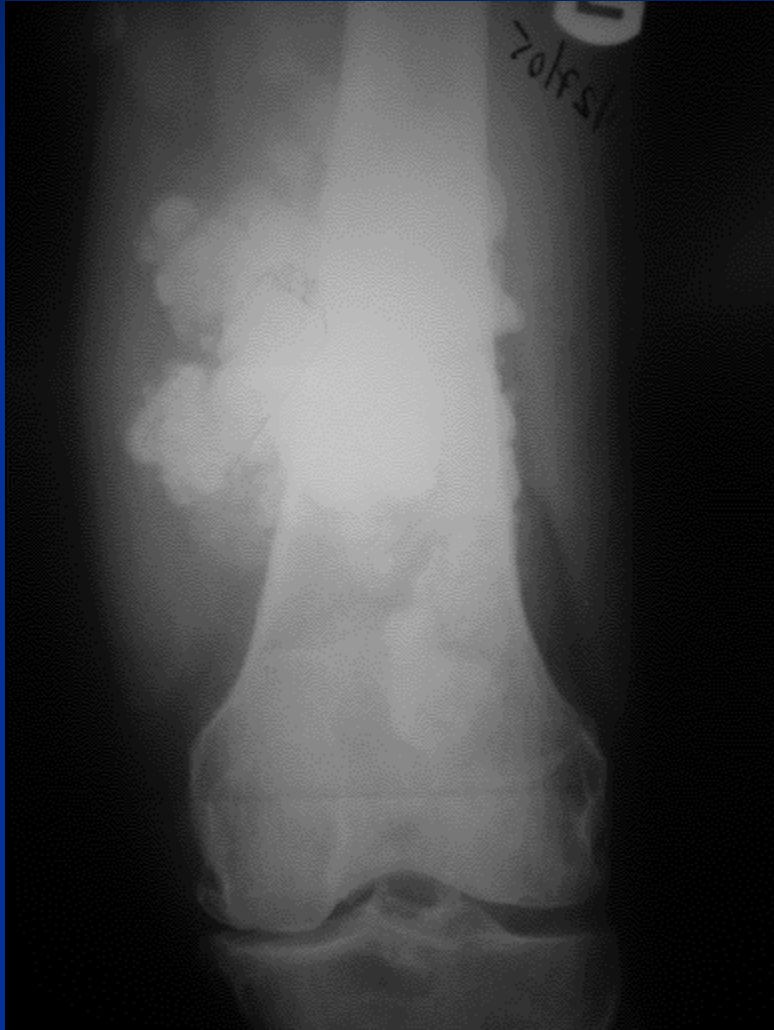Nodular PVNS

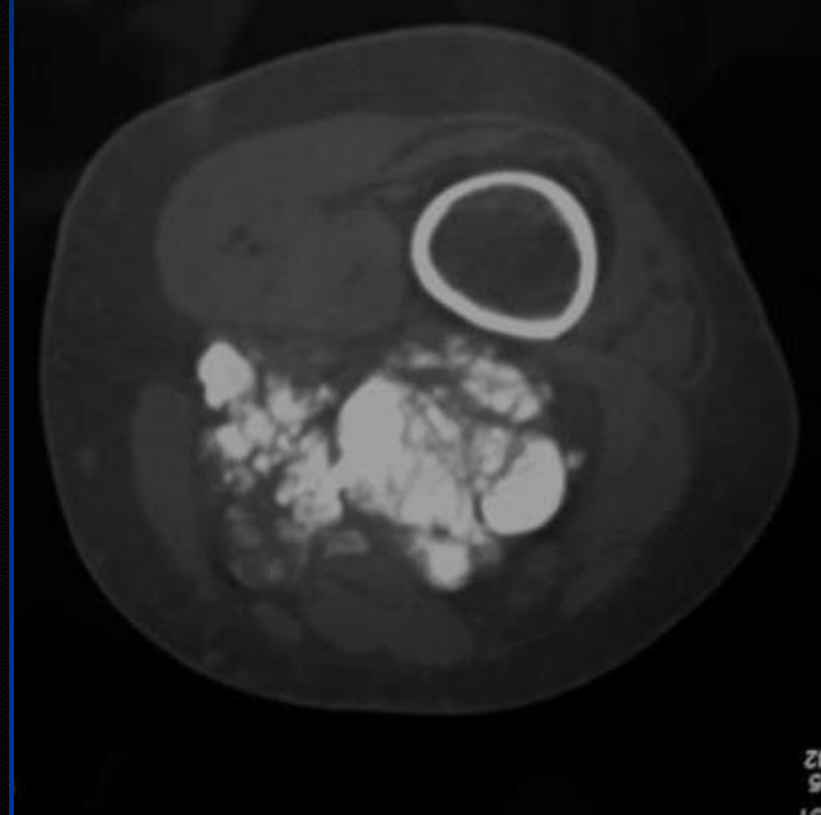
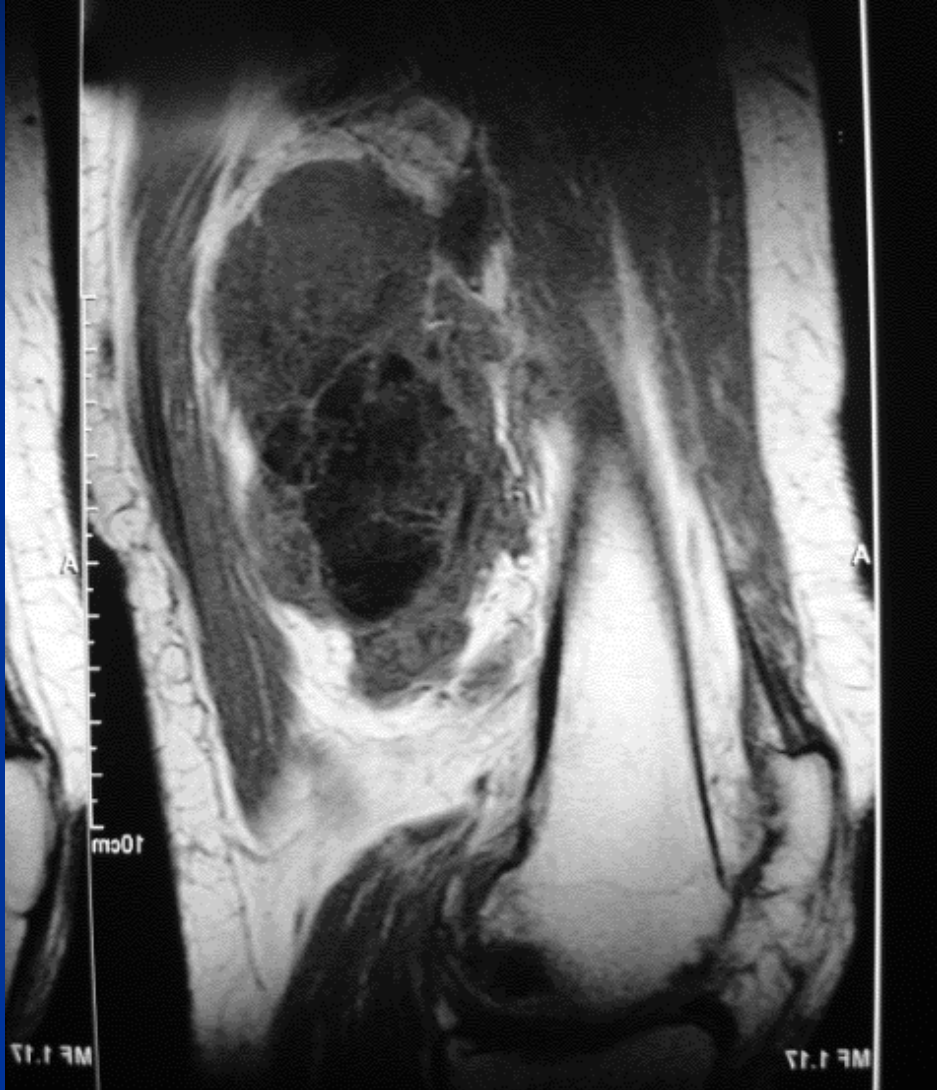


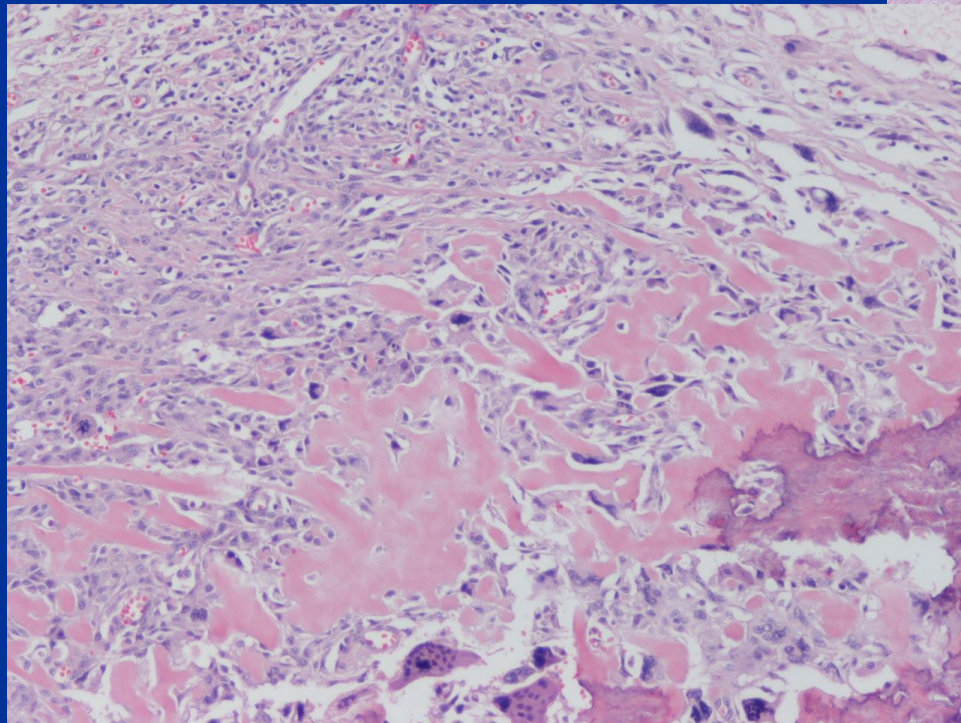
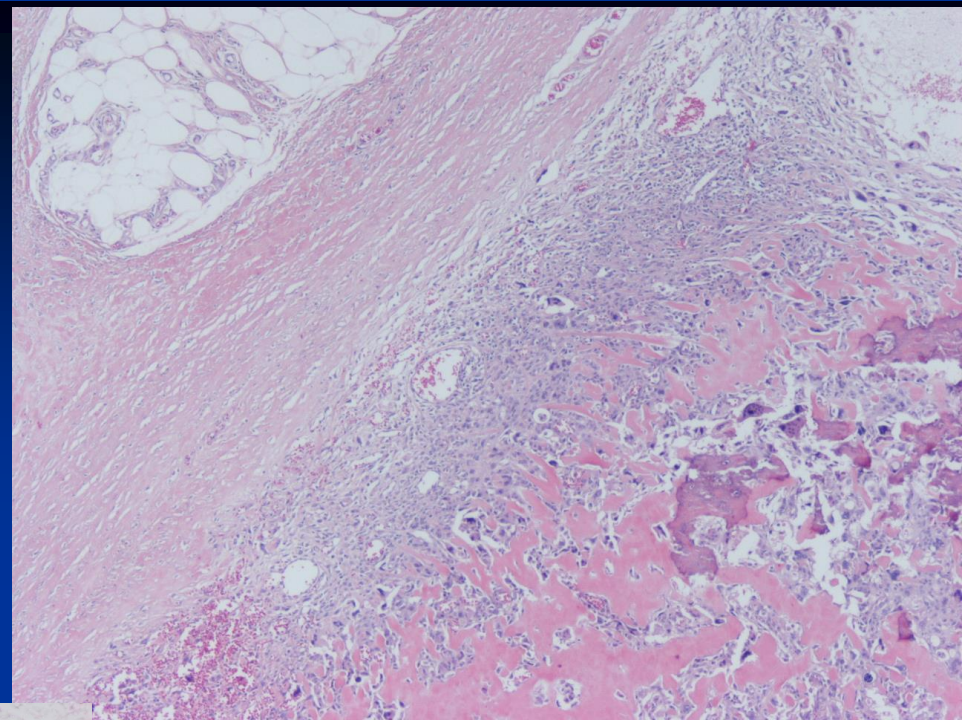
CASE #13

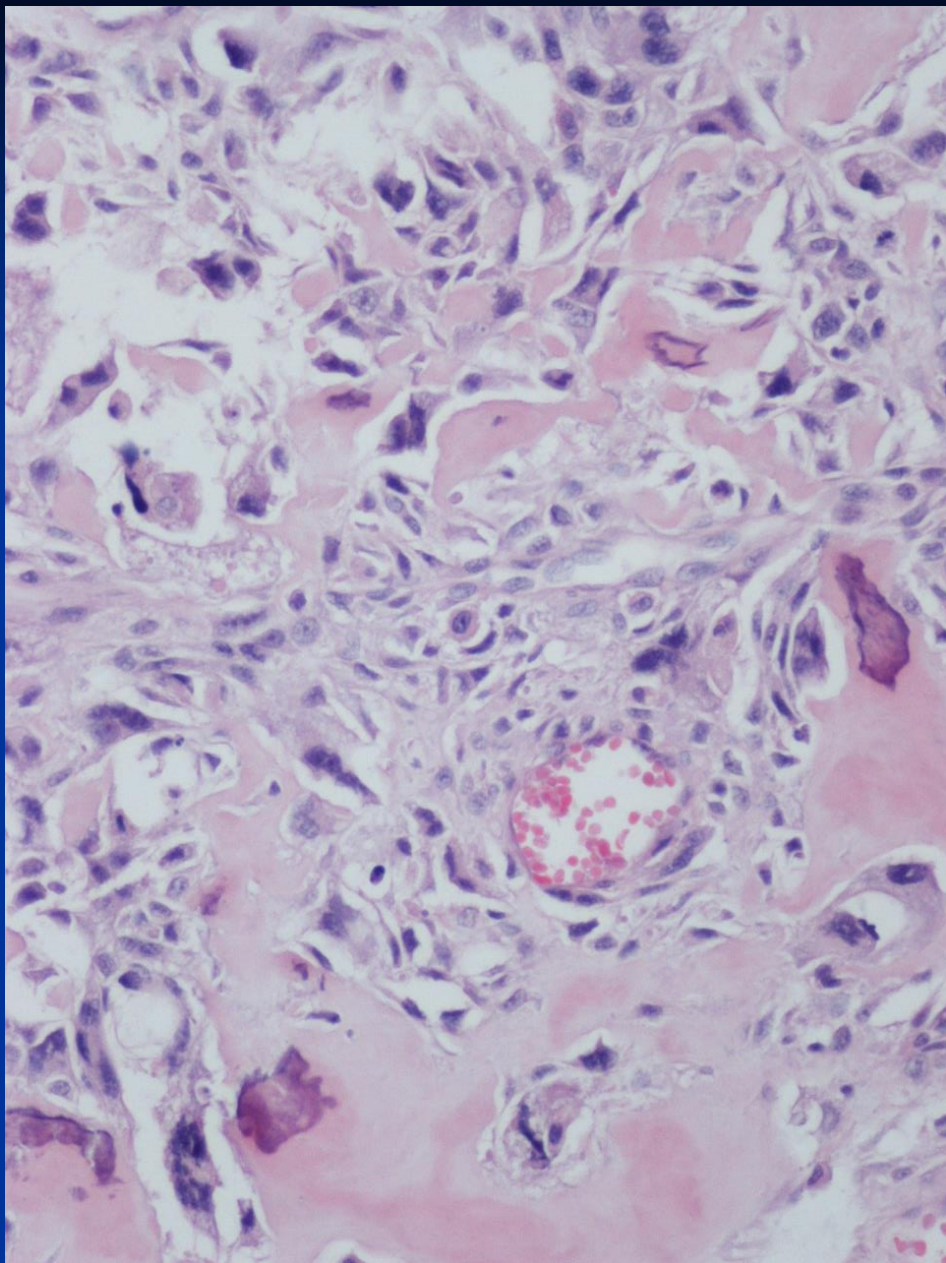
- 40 yo female
- Painful big mass in the left posterior thigh











*Diagnosis Next

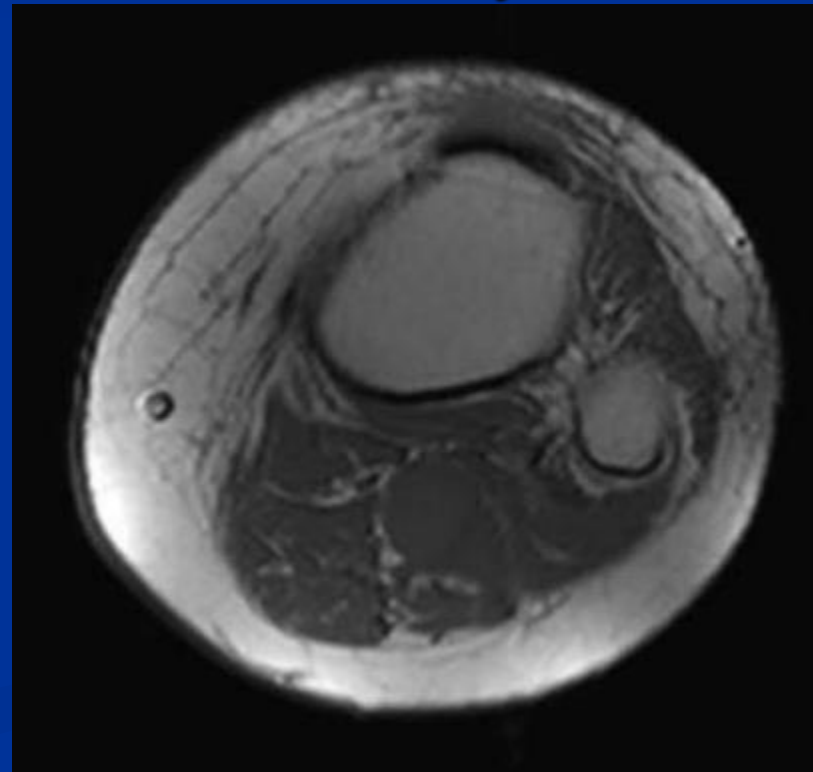


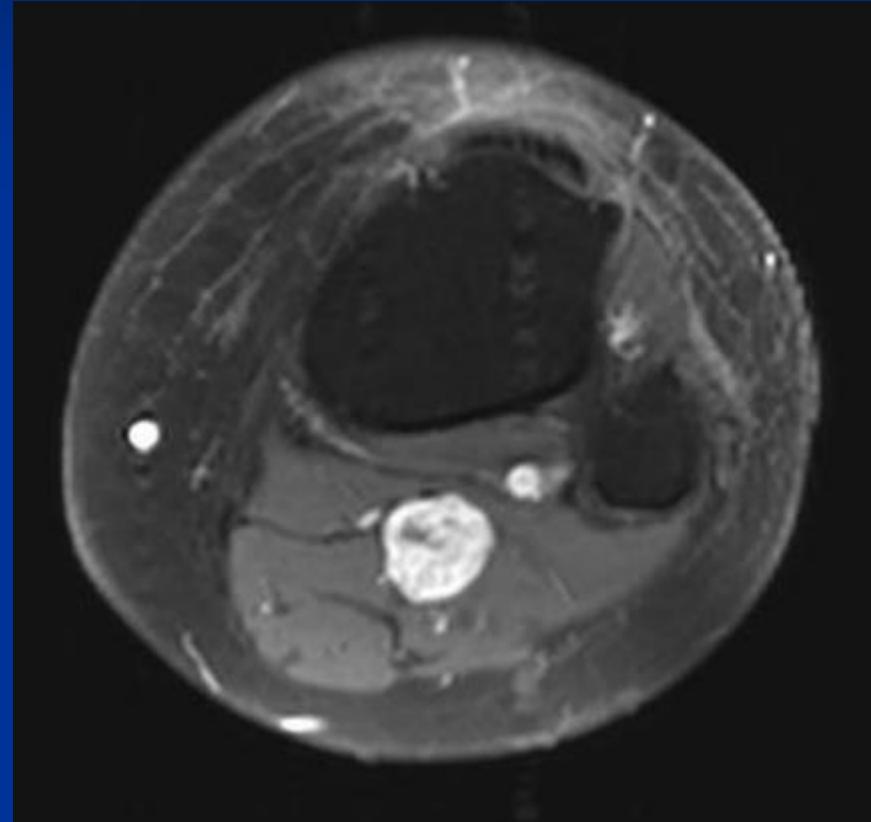
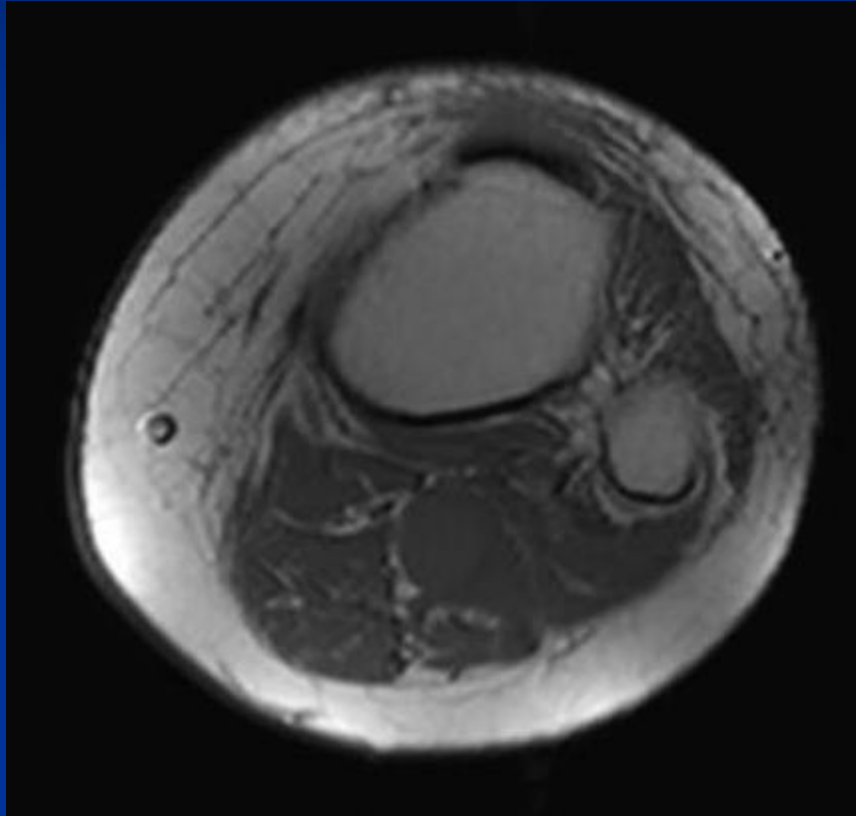
Soft-Tissue Osteosarcoma

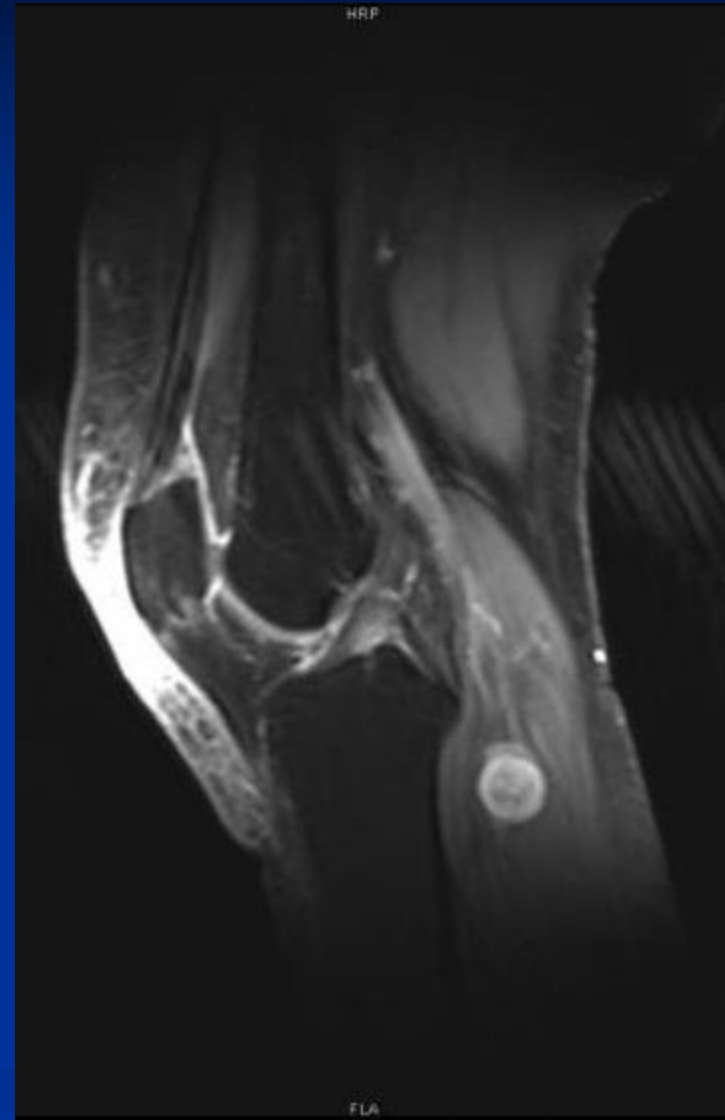
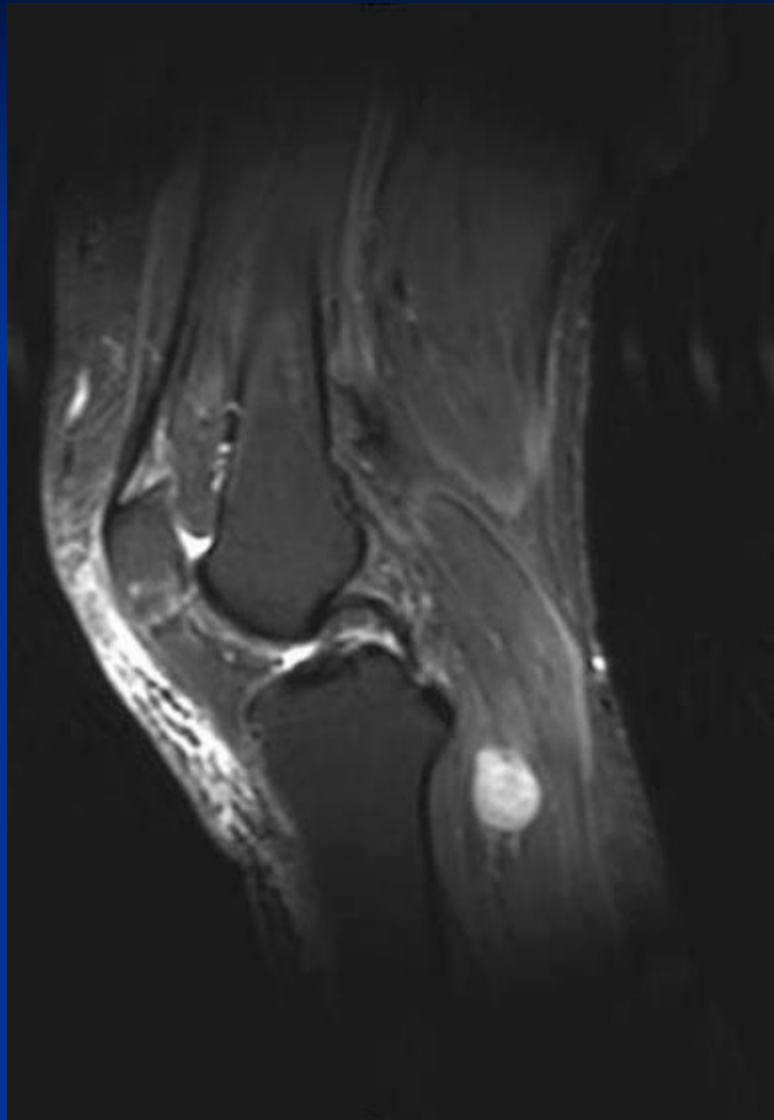


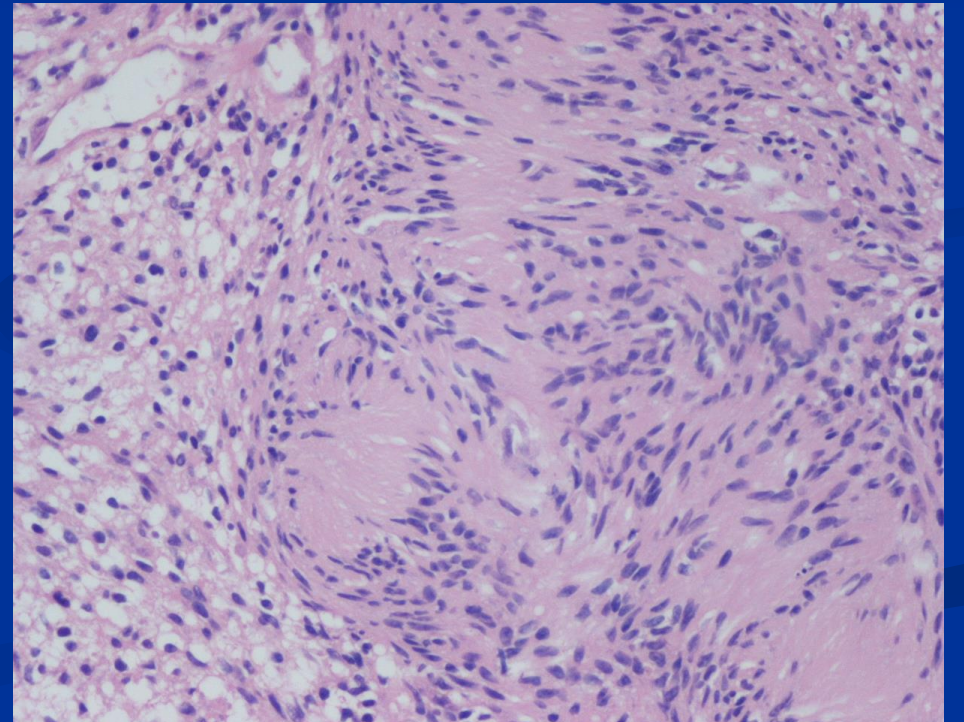
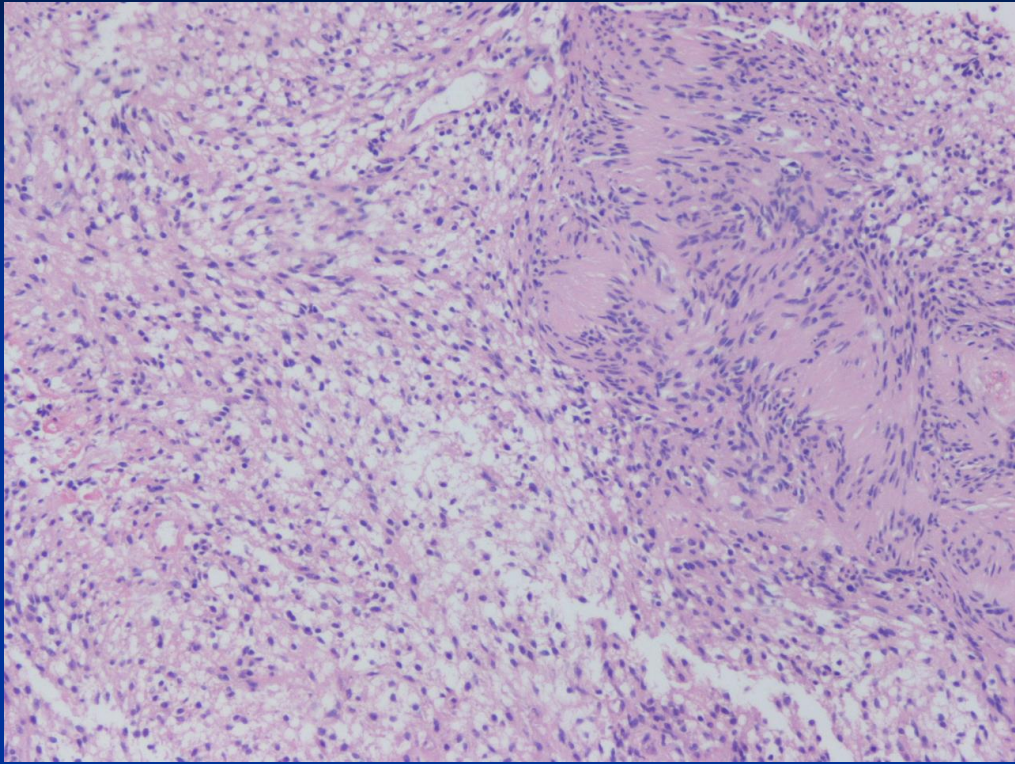
CASE #14

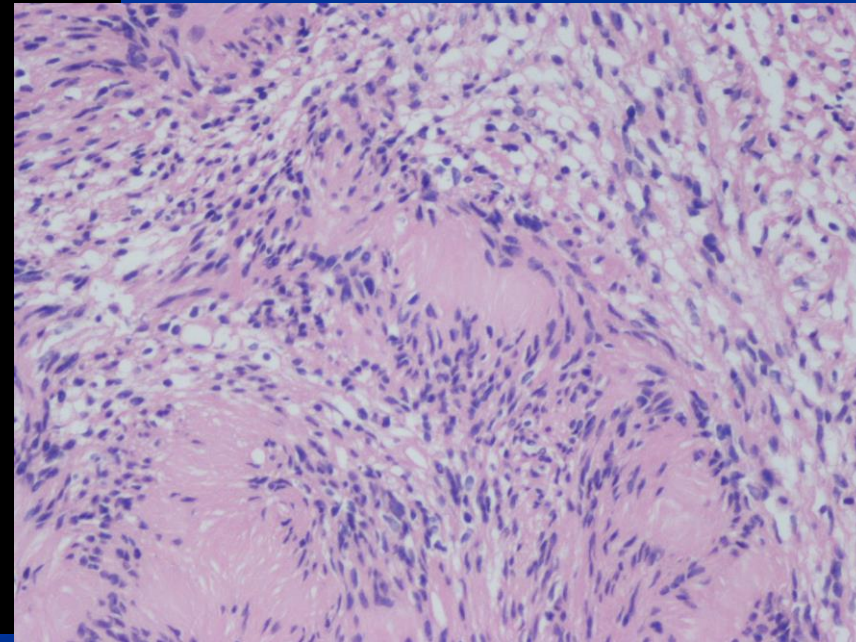
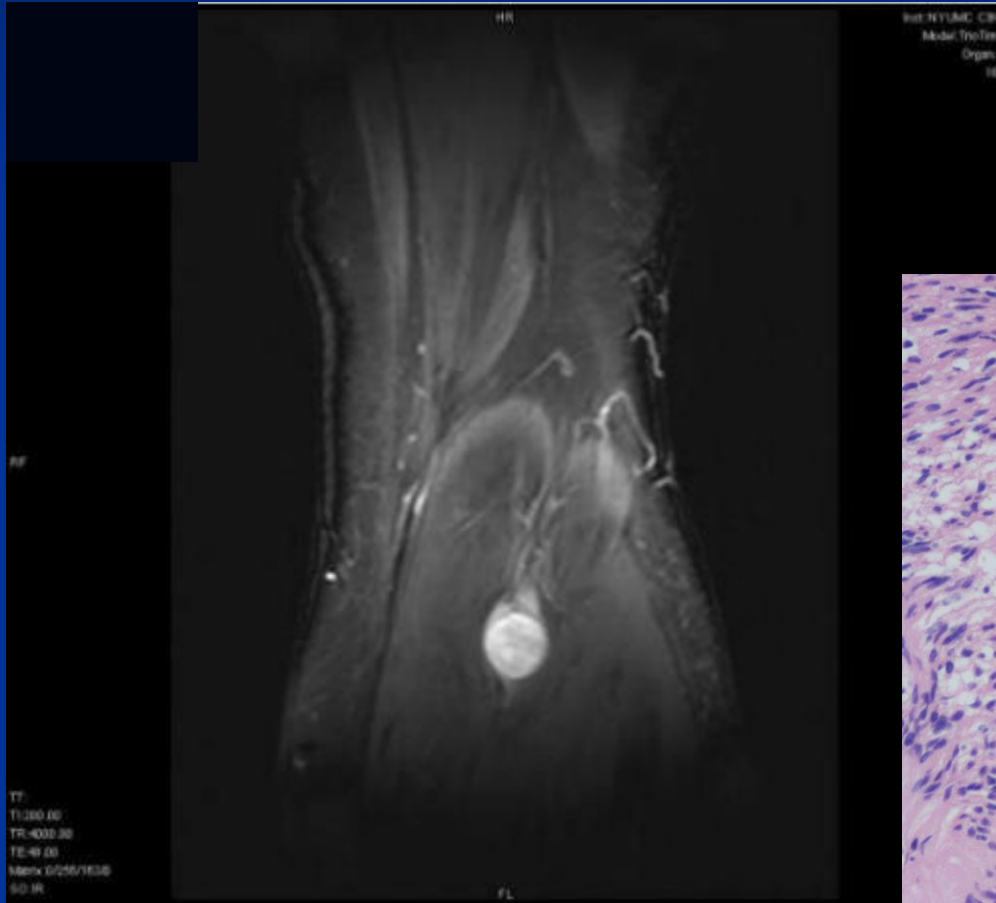
- 36 yo female
- c/o throbbing pain in the L calf, radiates distally.











***Diagnosis Next**

Wittig Orthopedic Oncology

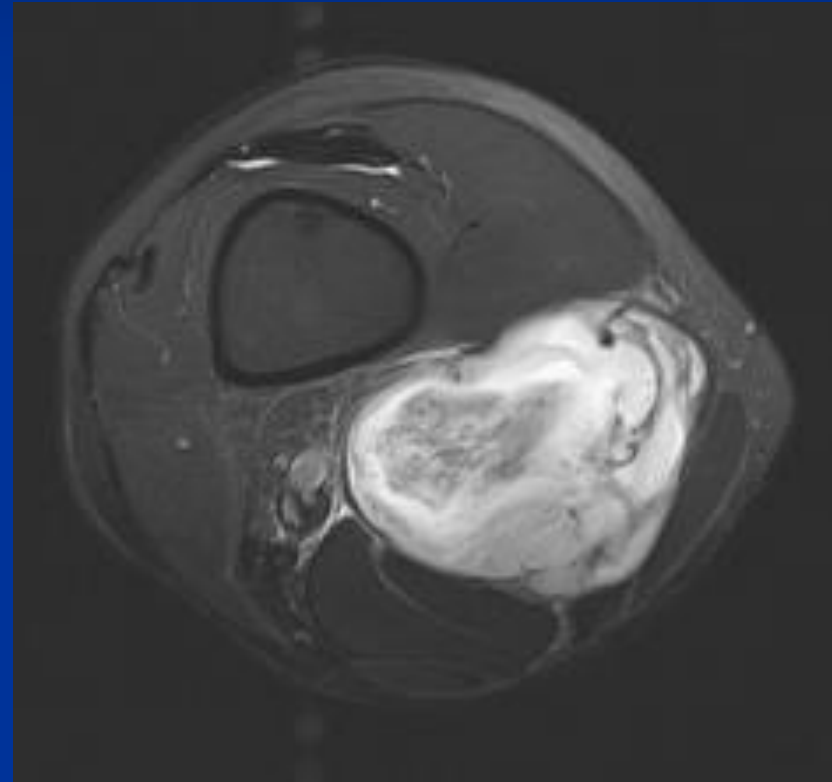


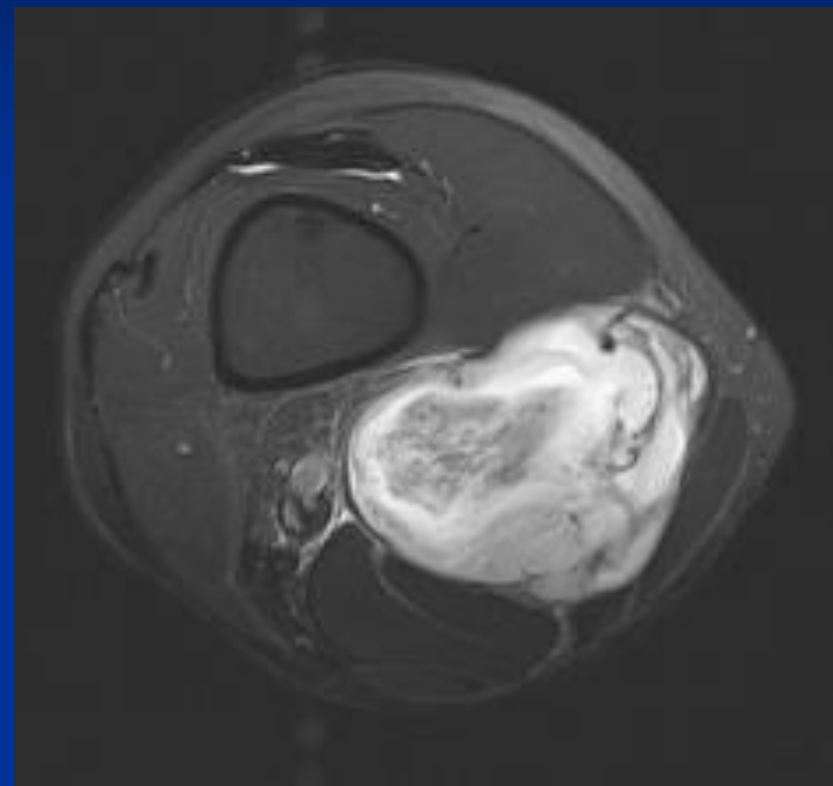
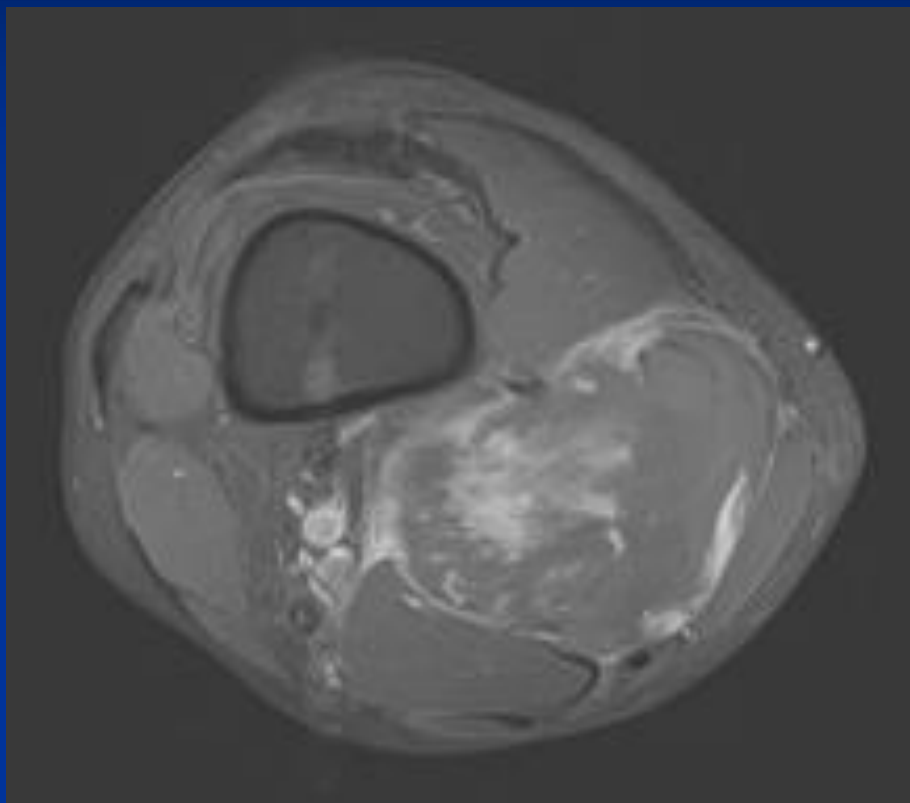
Schwannoma

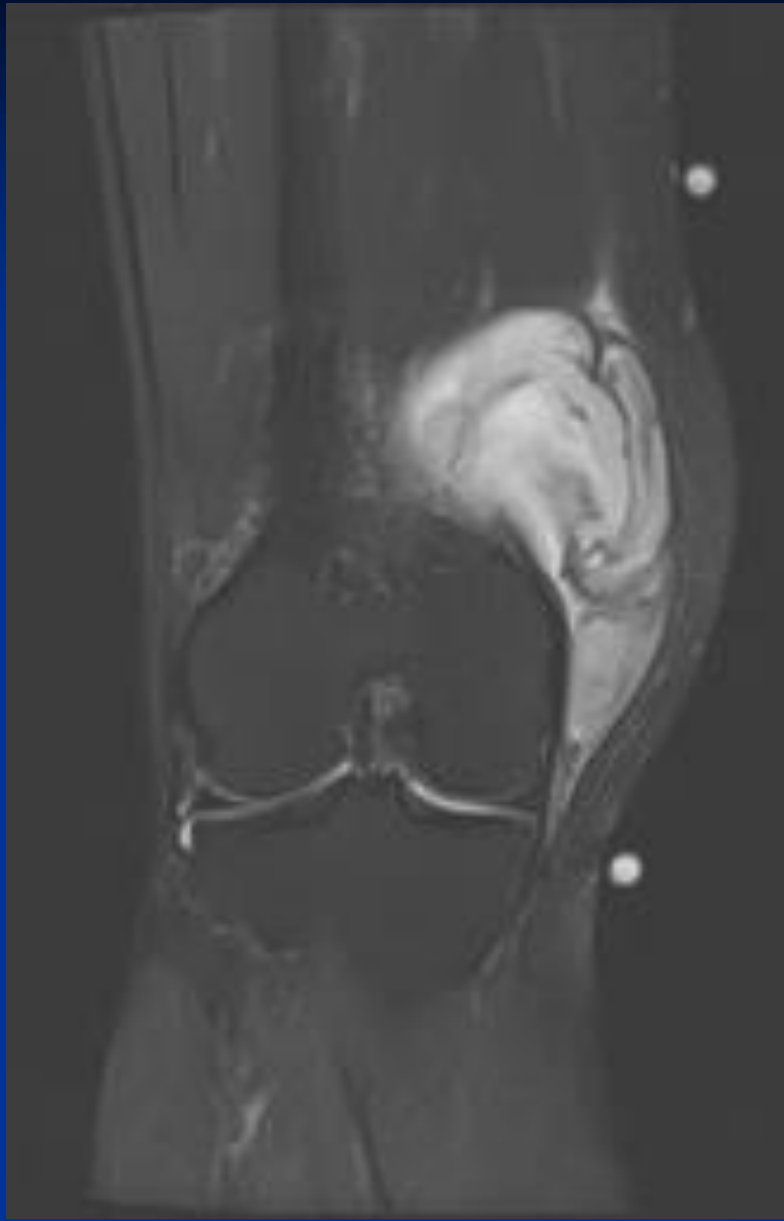


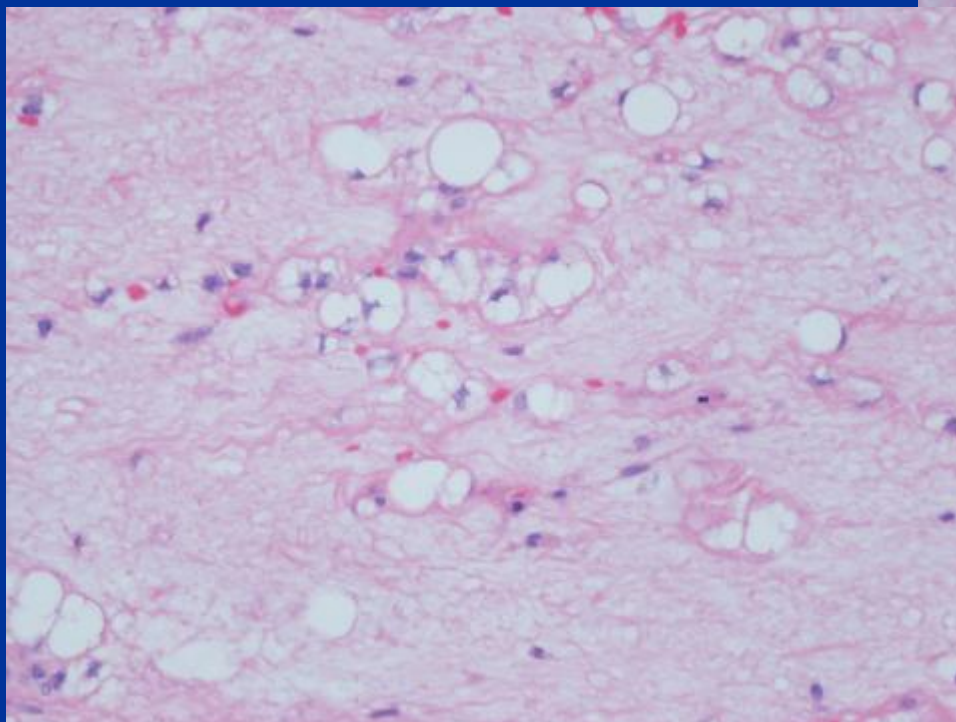
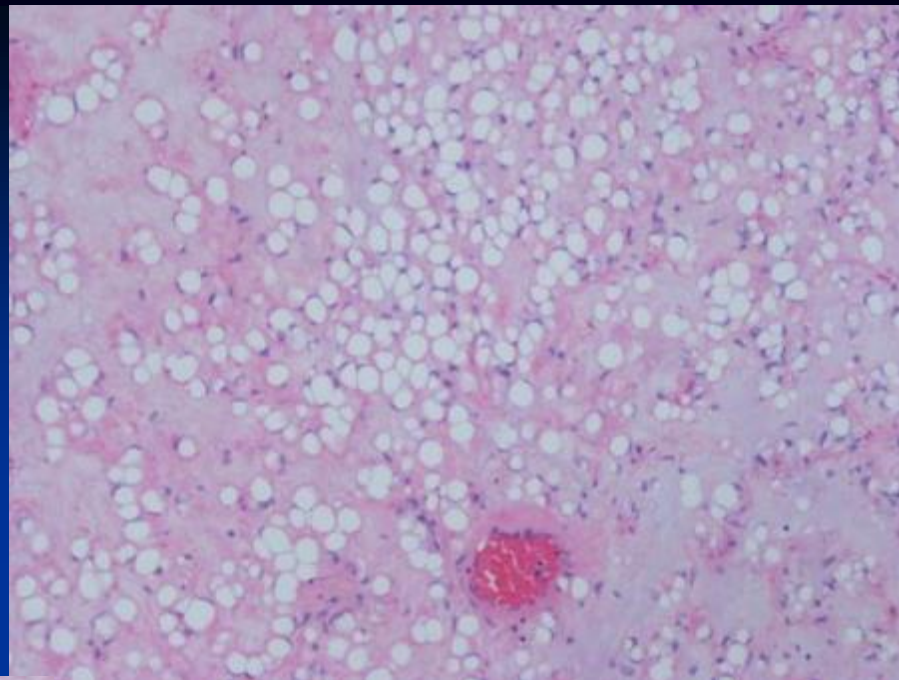
CASE #15

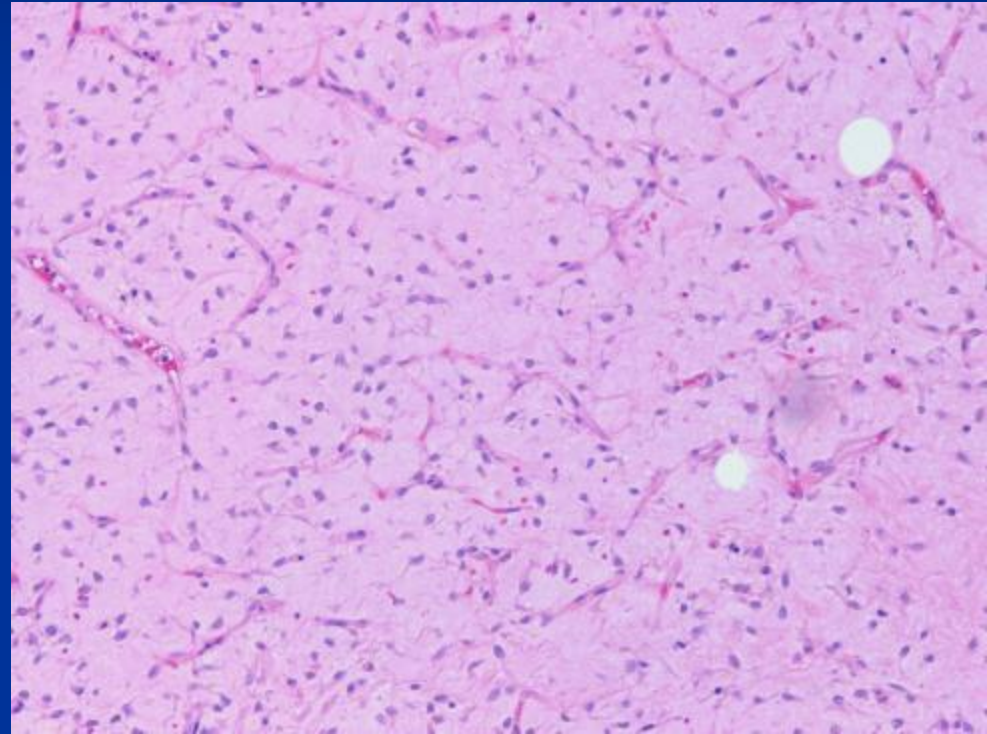
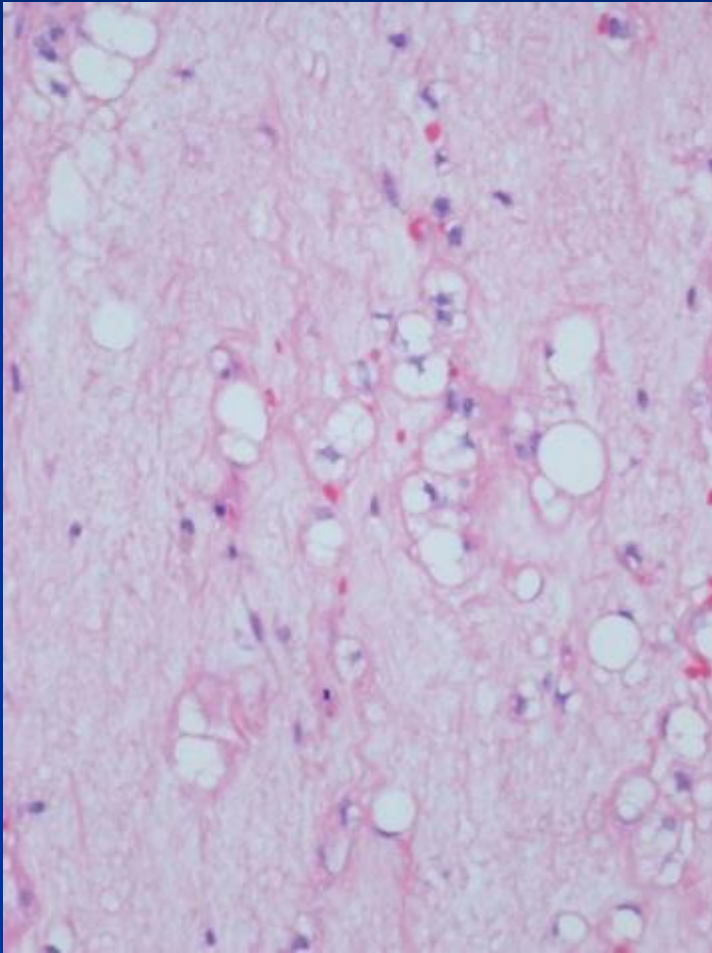
- 47 yo male
- Painless growing mass in the right knee for the last year











*Diagnosis Next

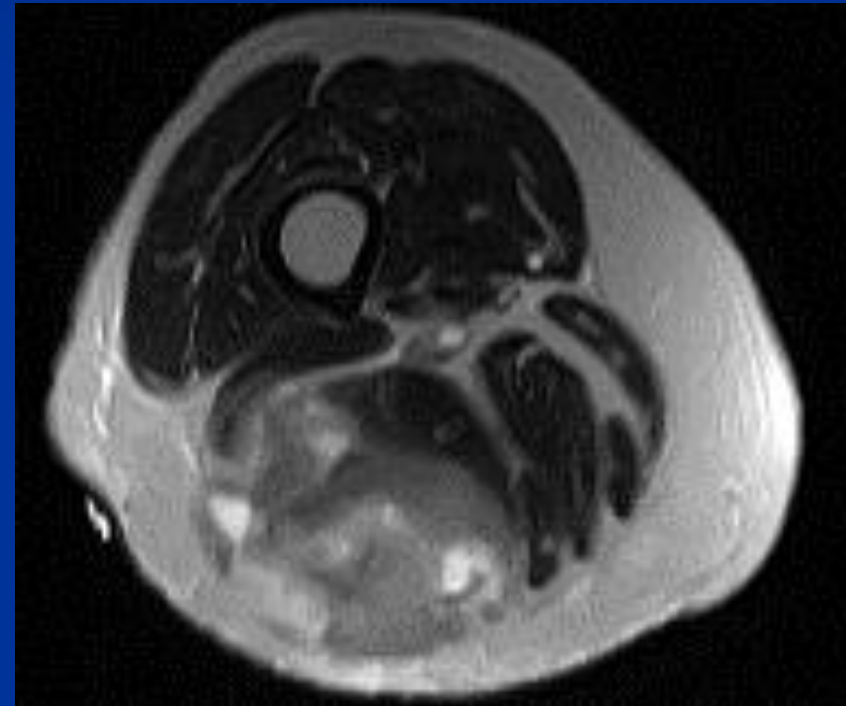


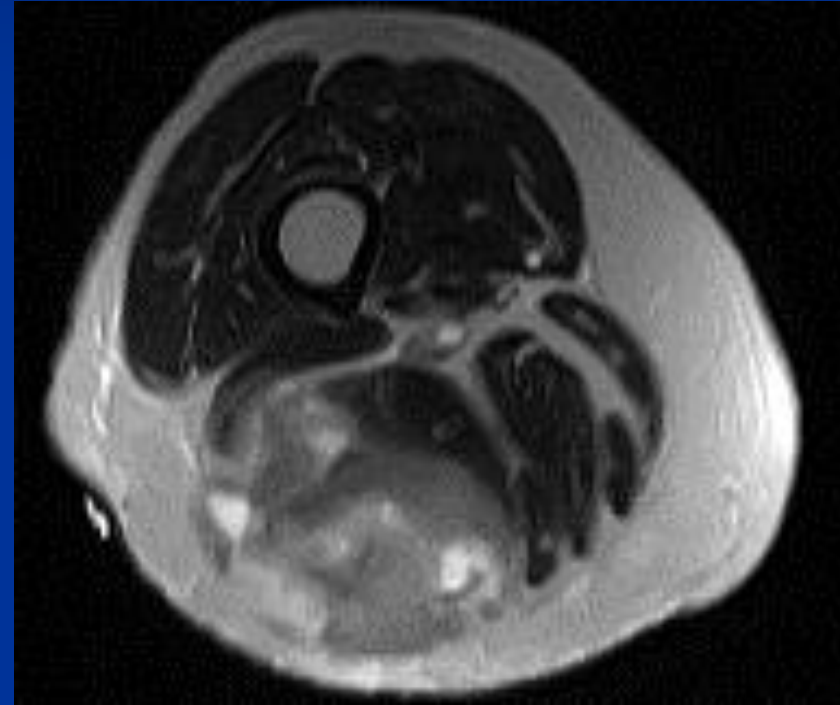
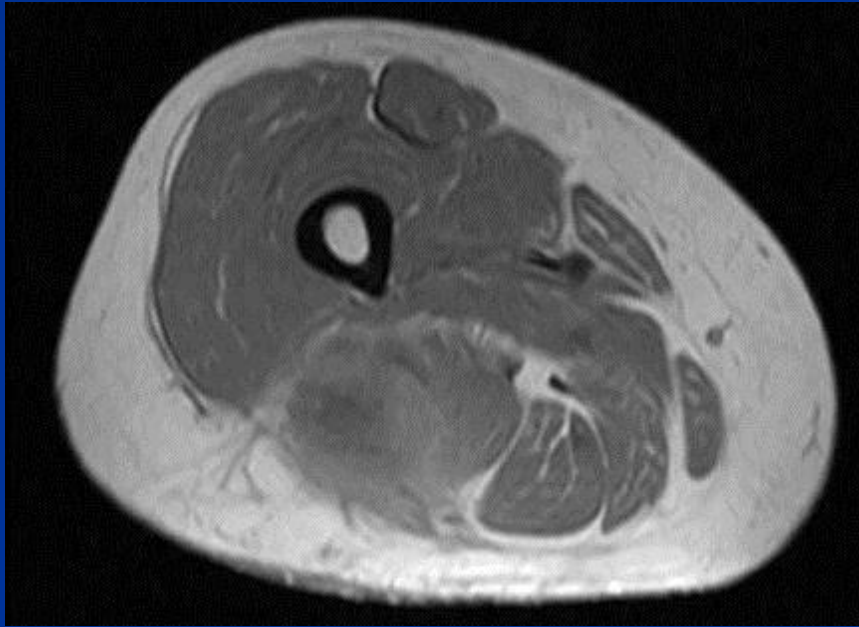Myxoid Liposarcoma

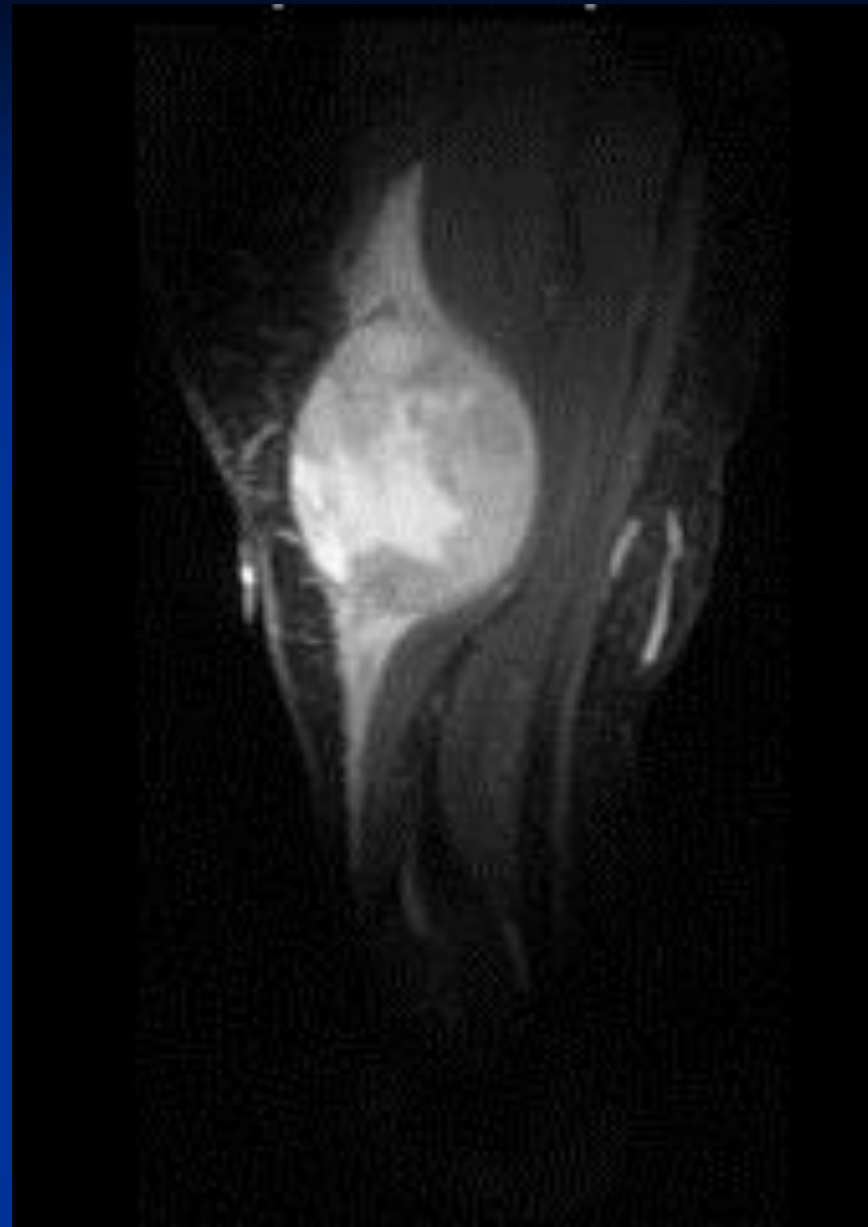
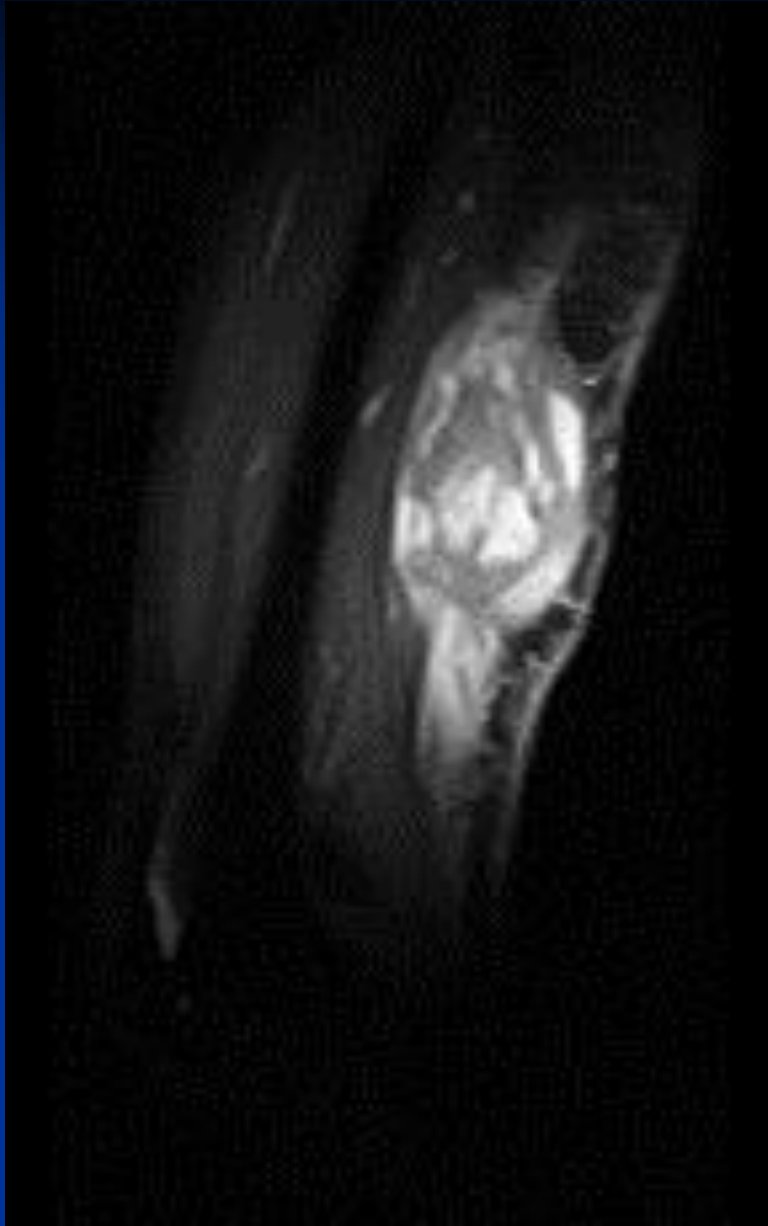


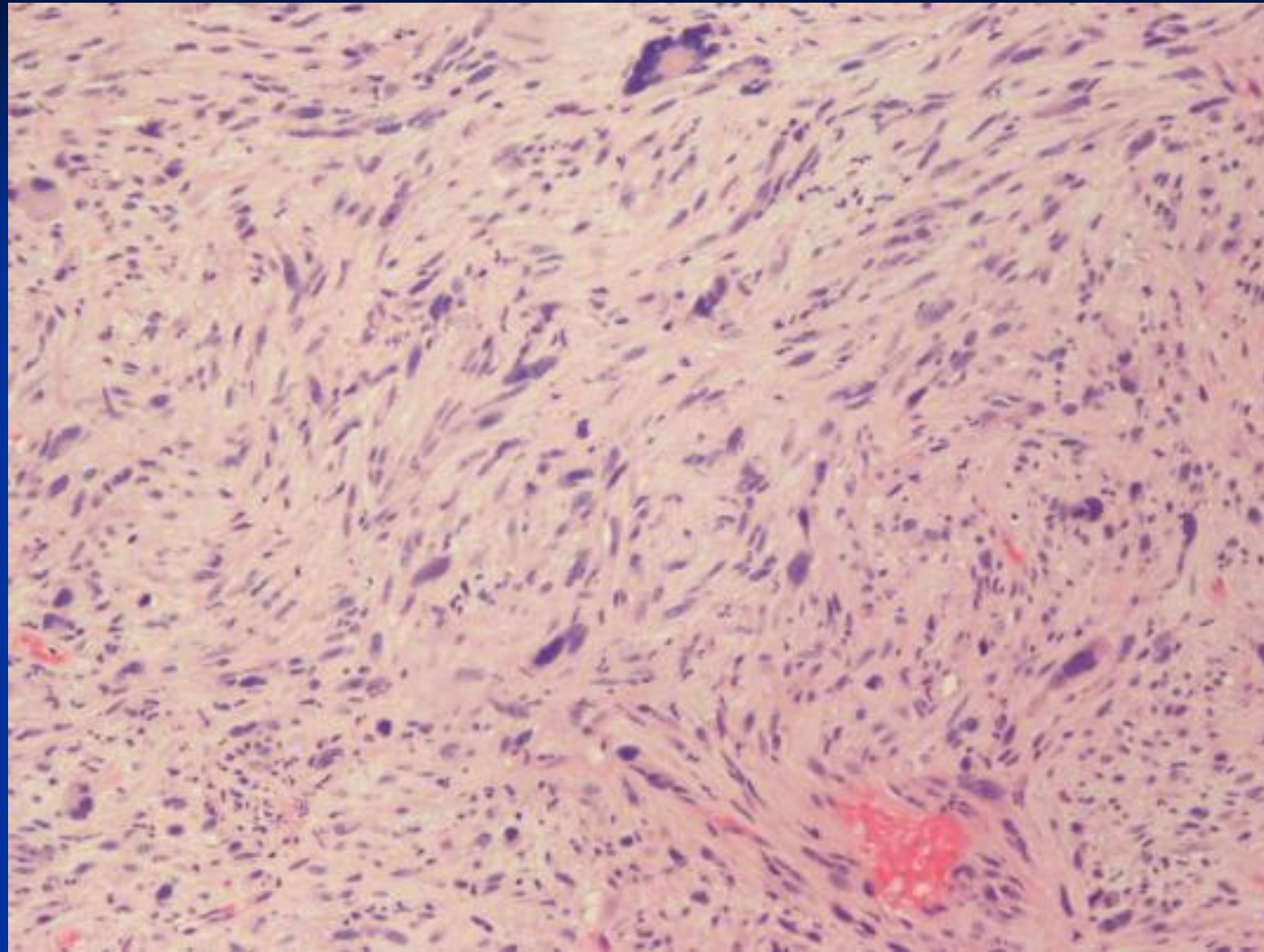
CASE #16

- 35 yo Female
- Pain in the right thigh with exercise for the last 3 months
- A biopsy was performed. The sample stained positively for vimentin and actin.



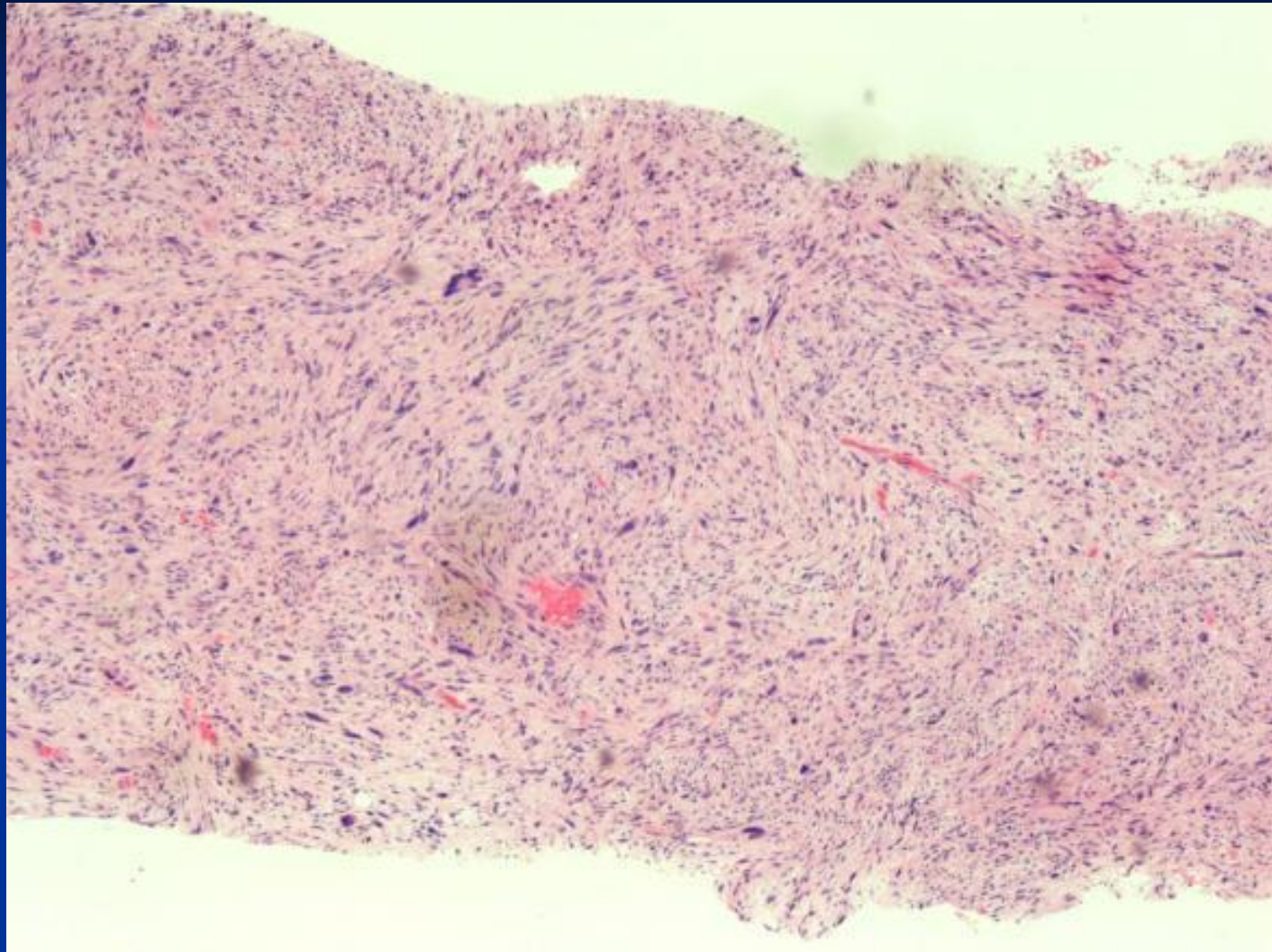


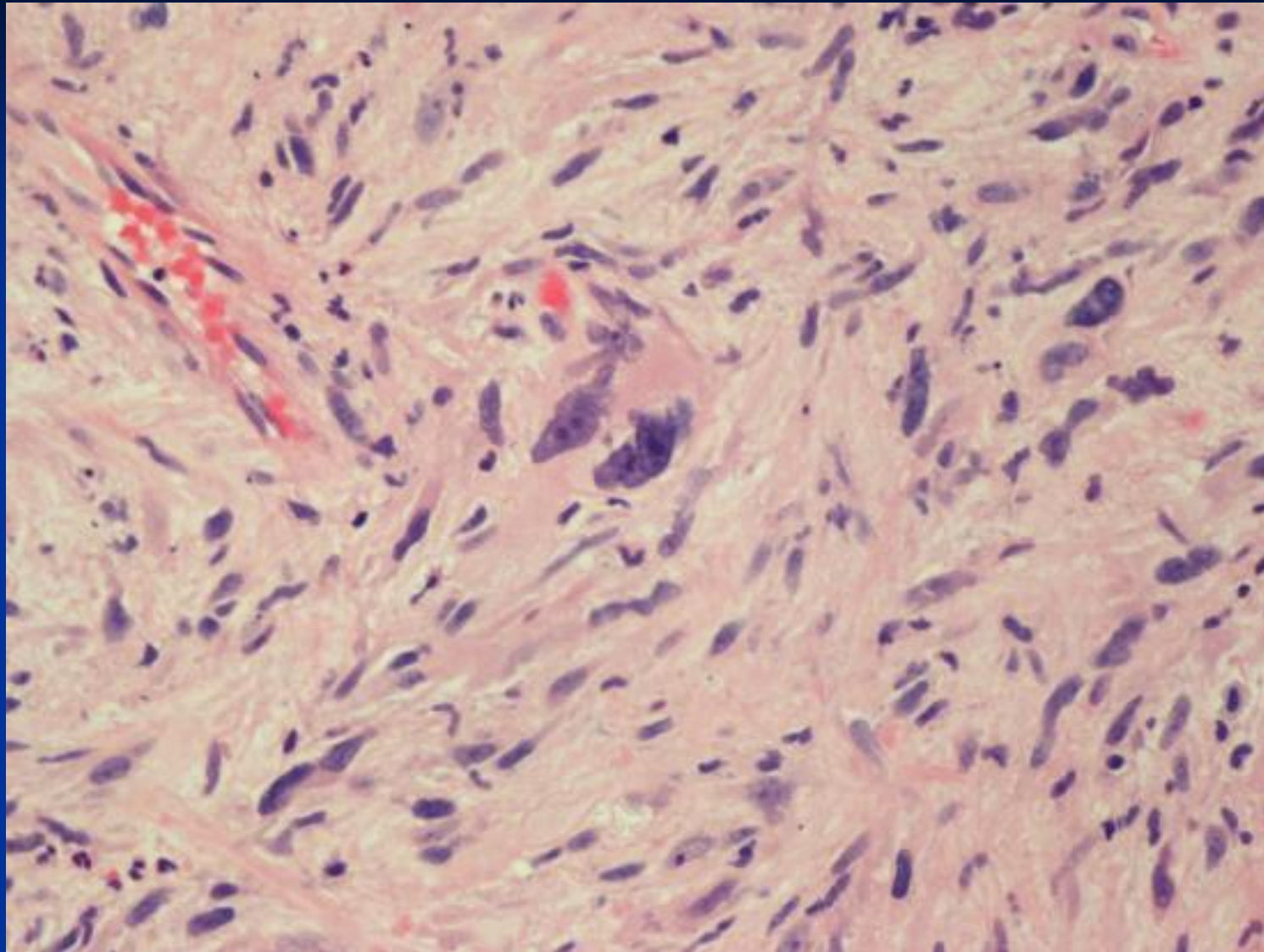




Actin (+)
Desmin (+)







*Diagnosis Next

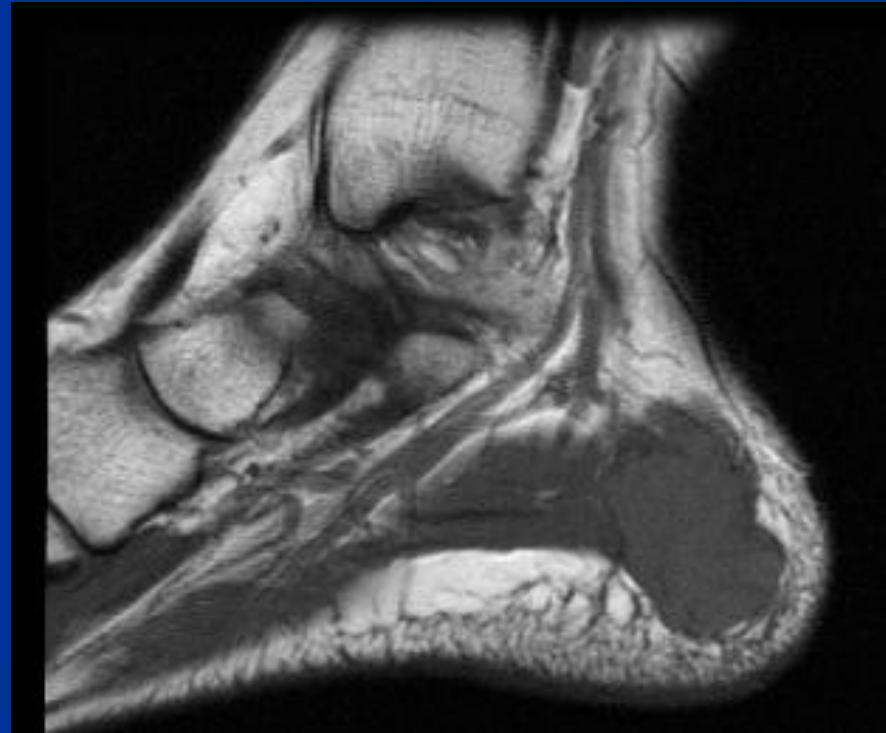


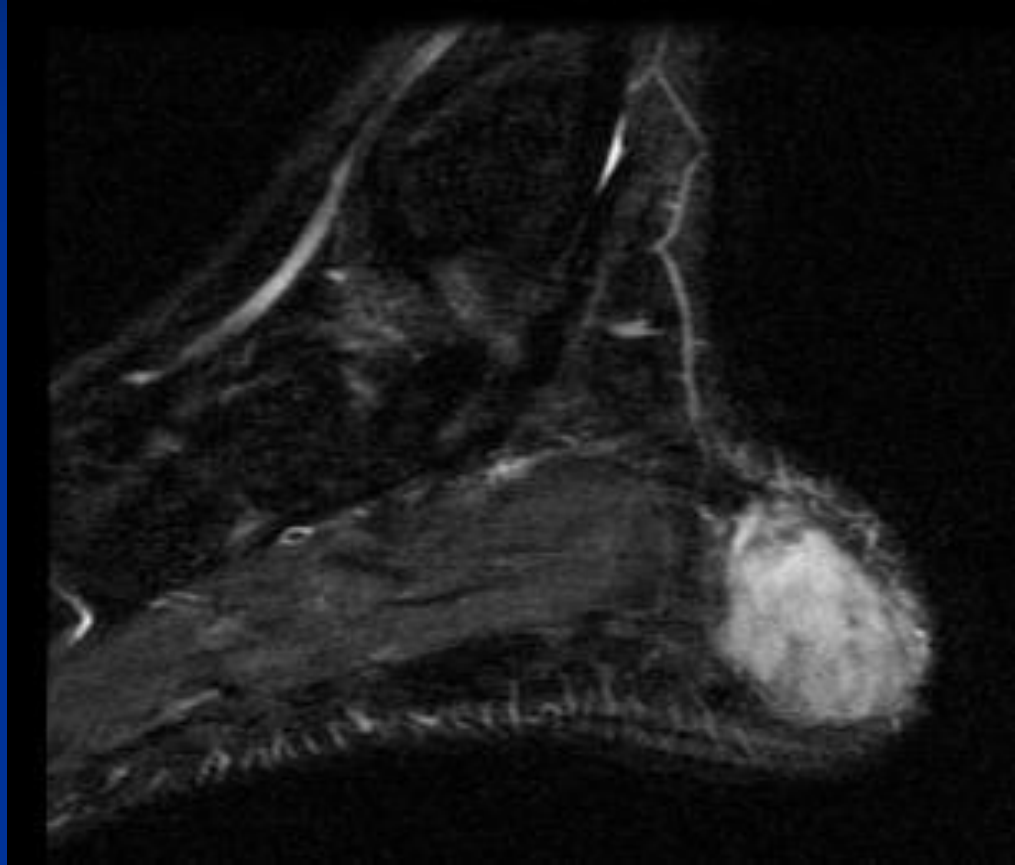
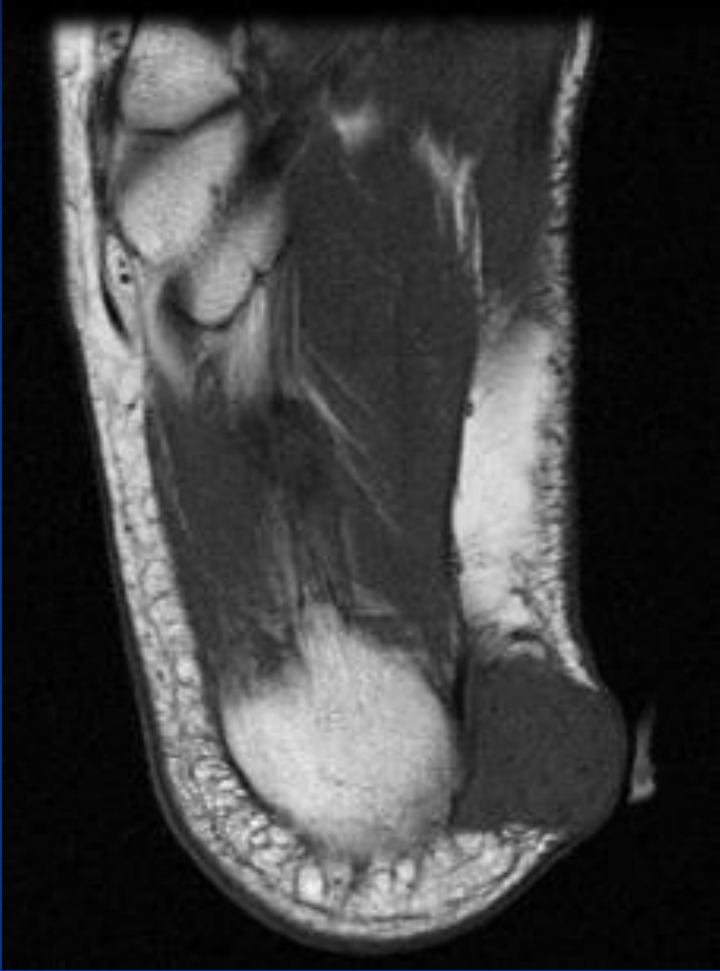
Leiomyosarcoma

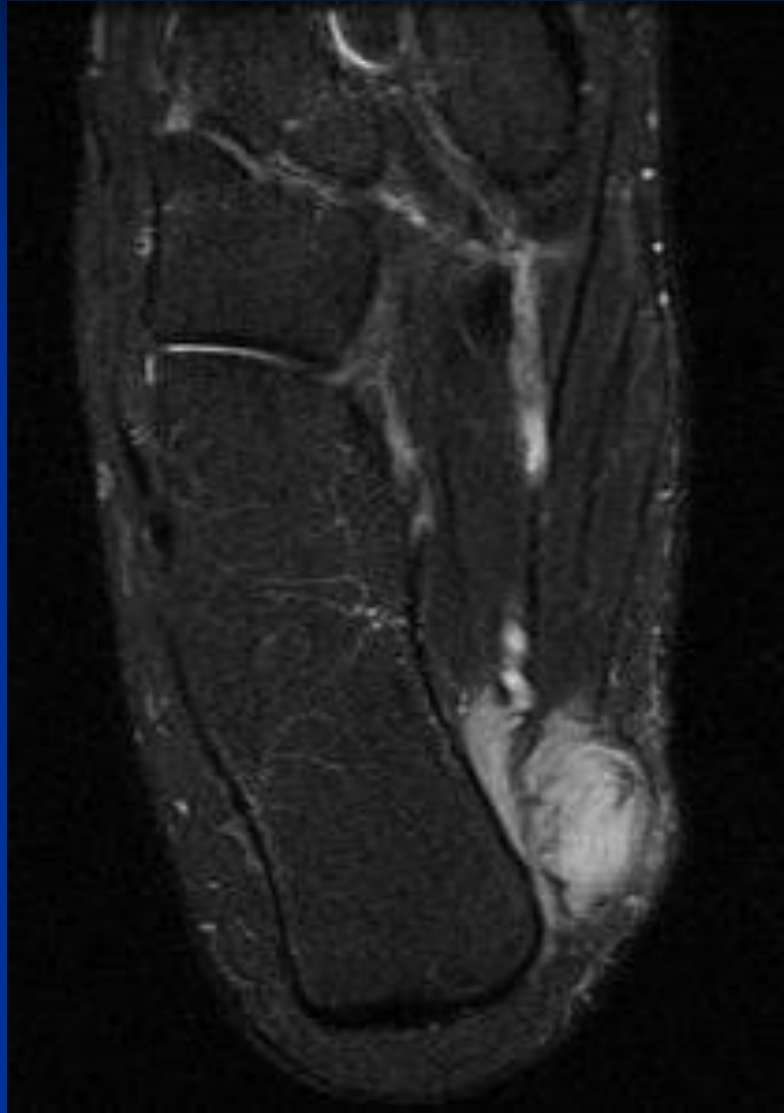


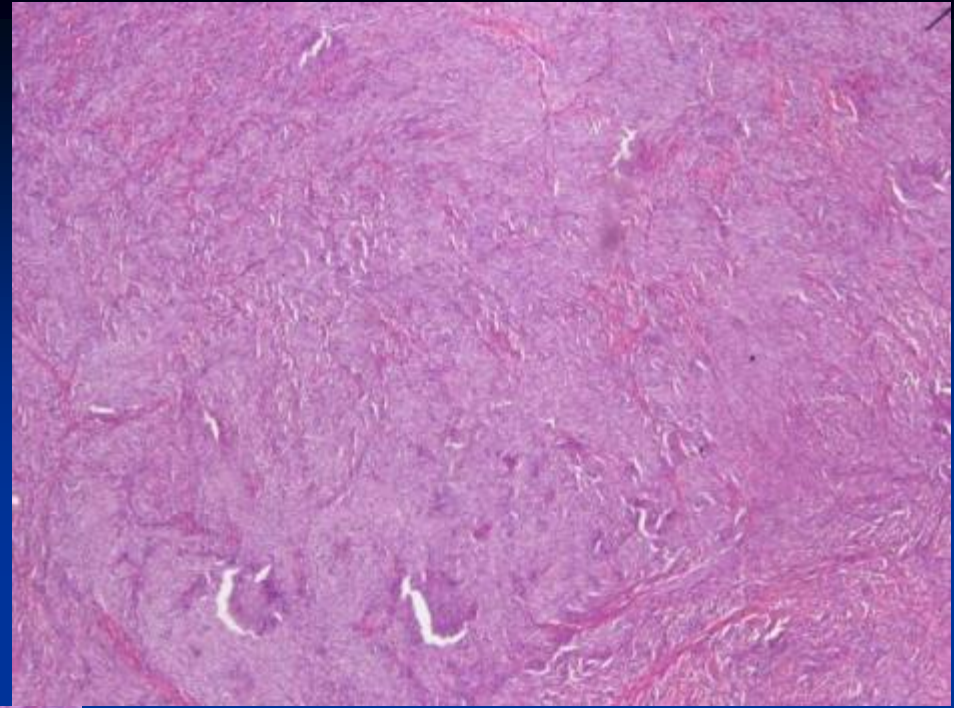
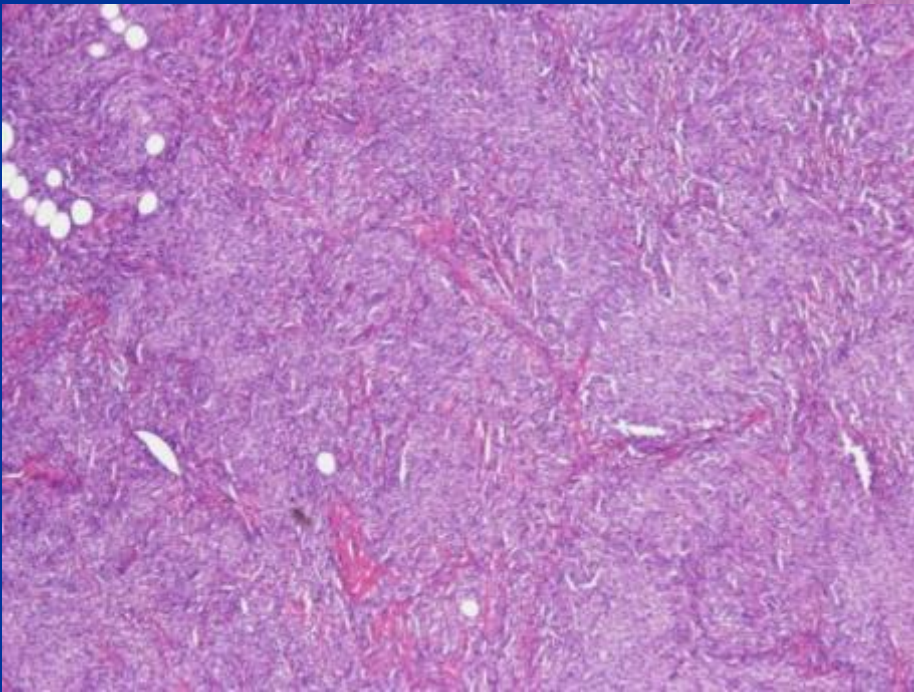
CASE #17

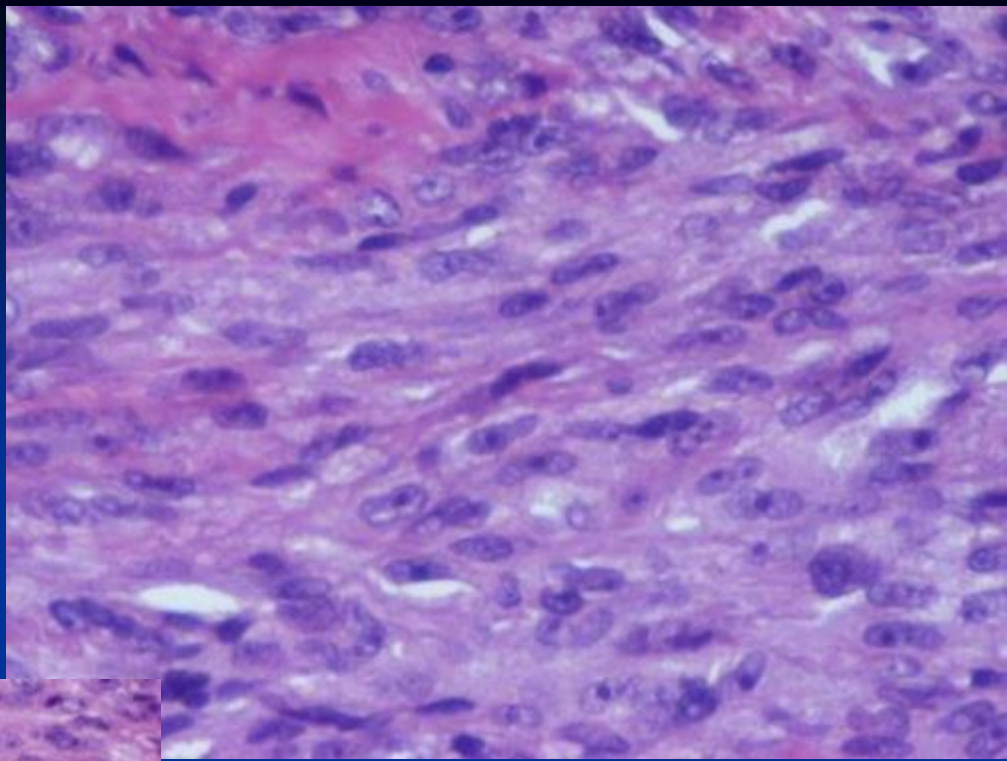
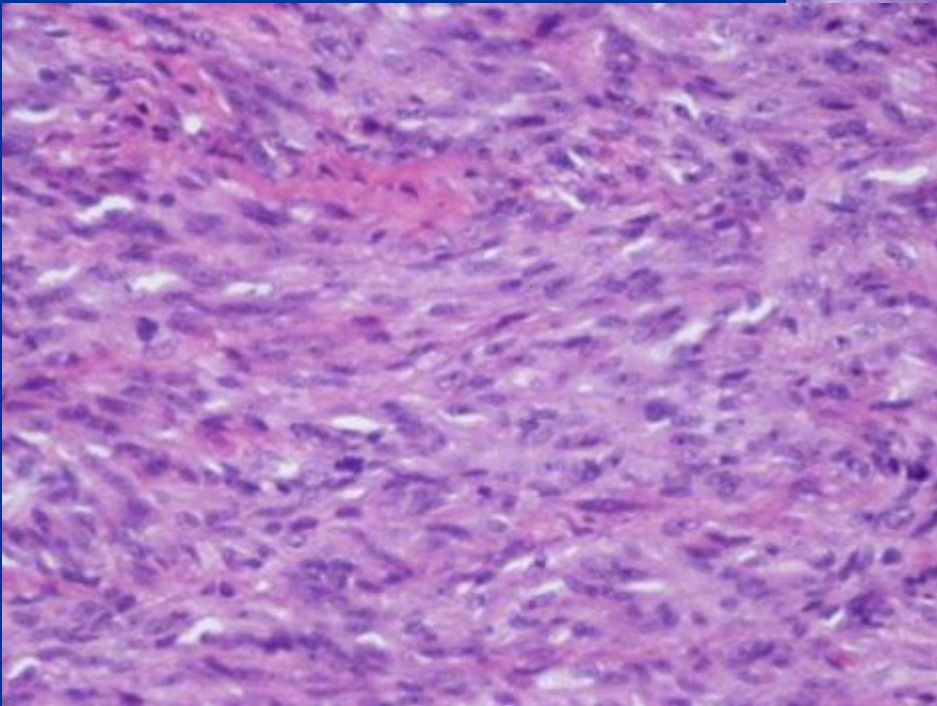
- 60 yo male
- Enlarging mass and pain in the R foot.

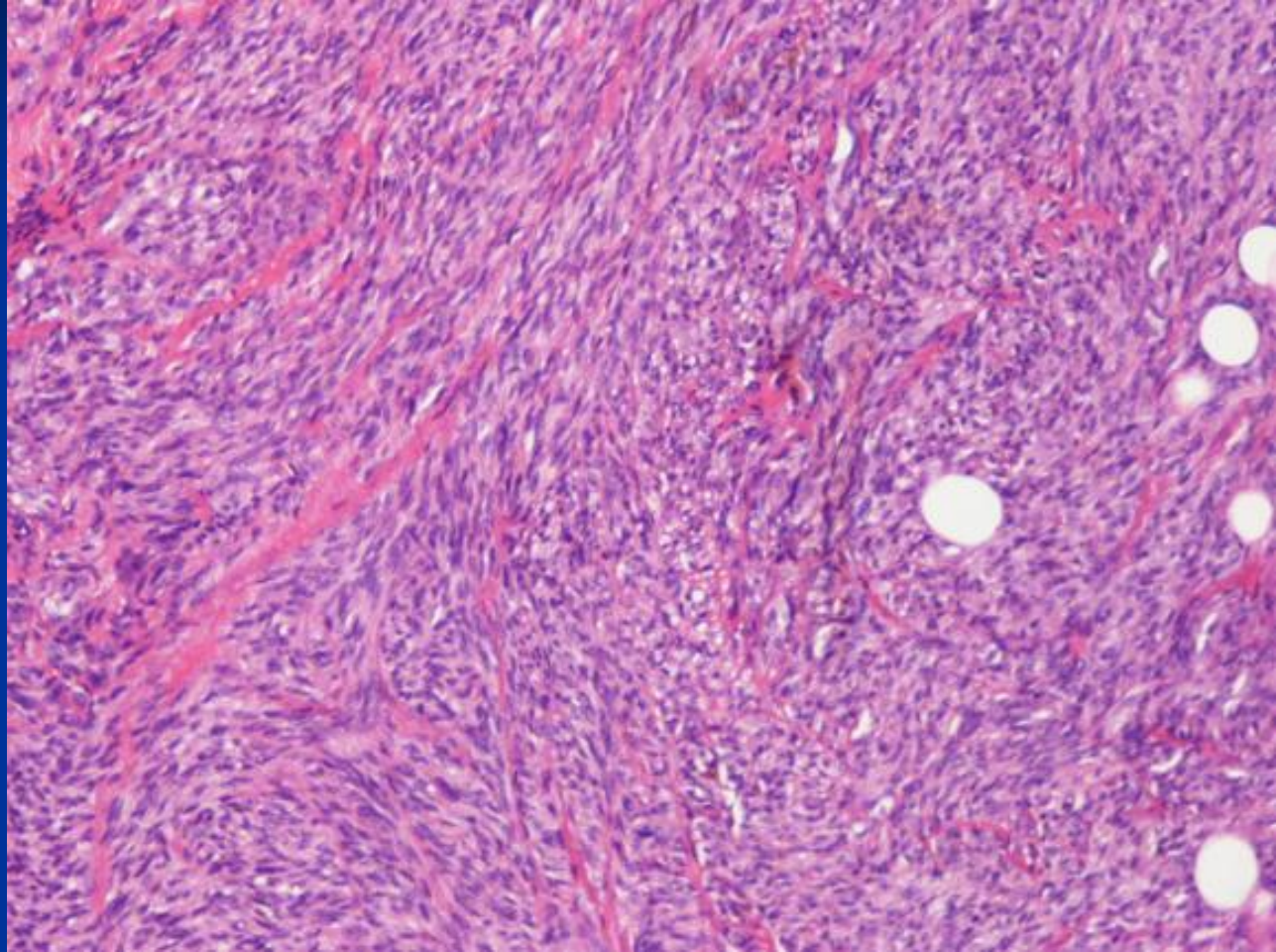












***Diagnosis Next**

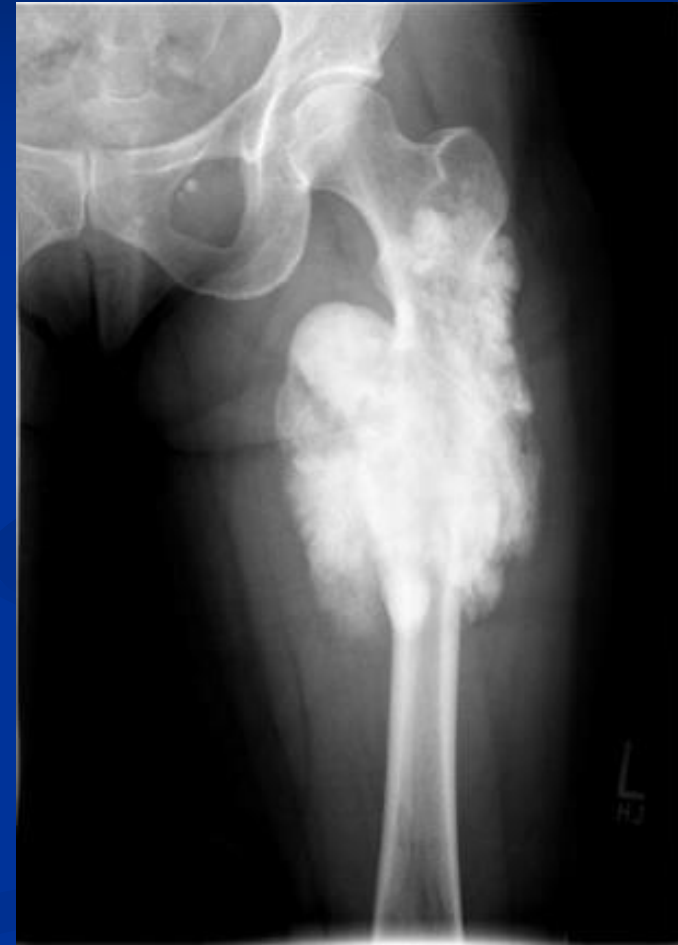

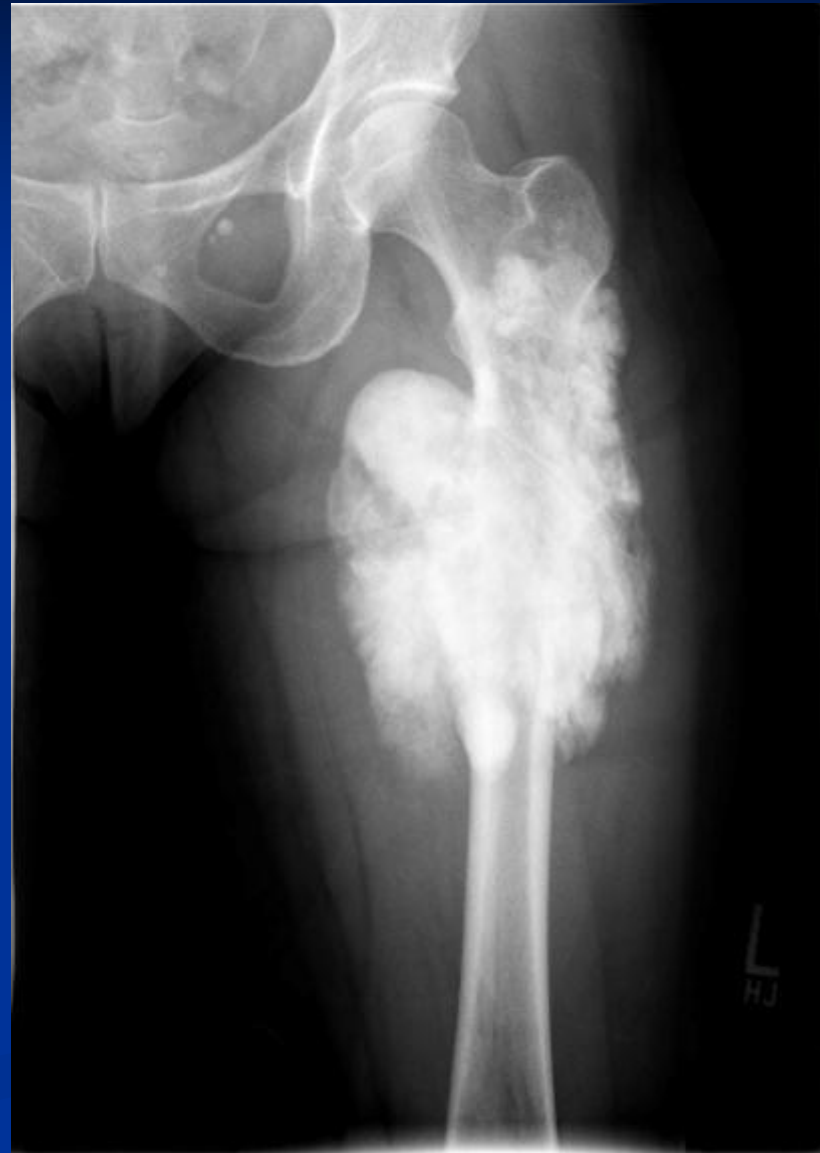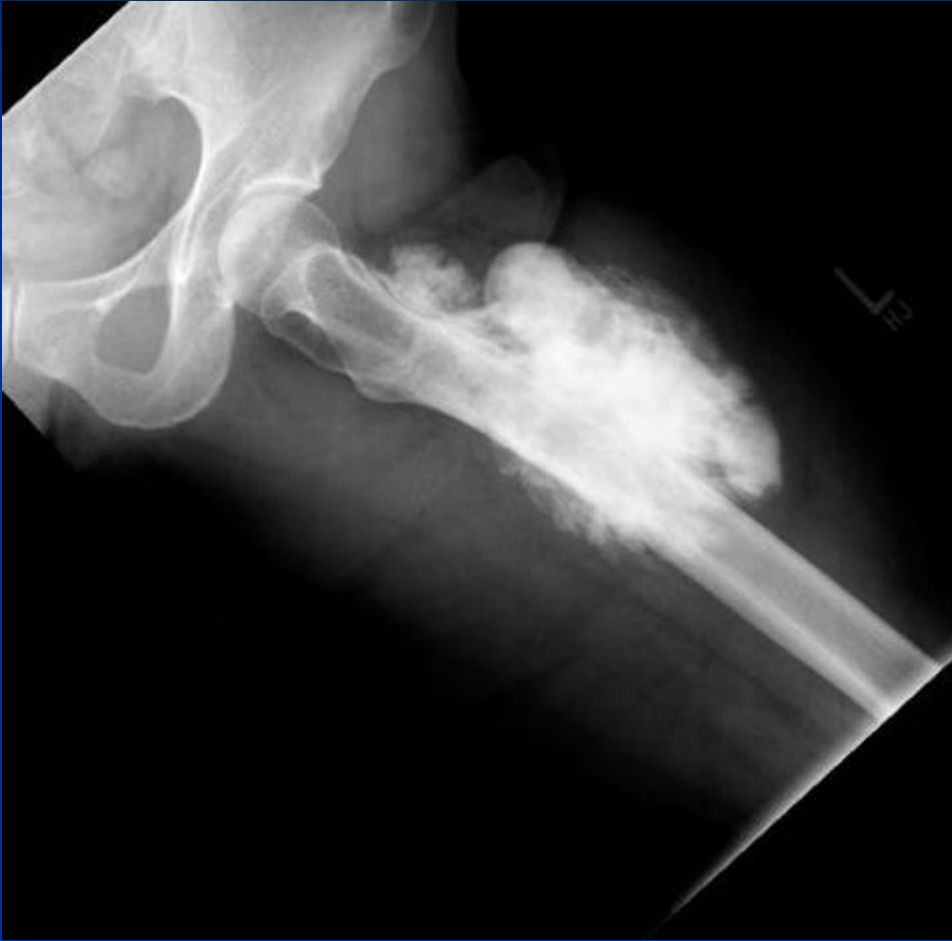Clear Cell Sarcoma

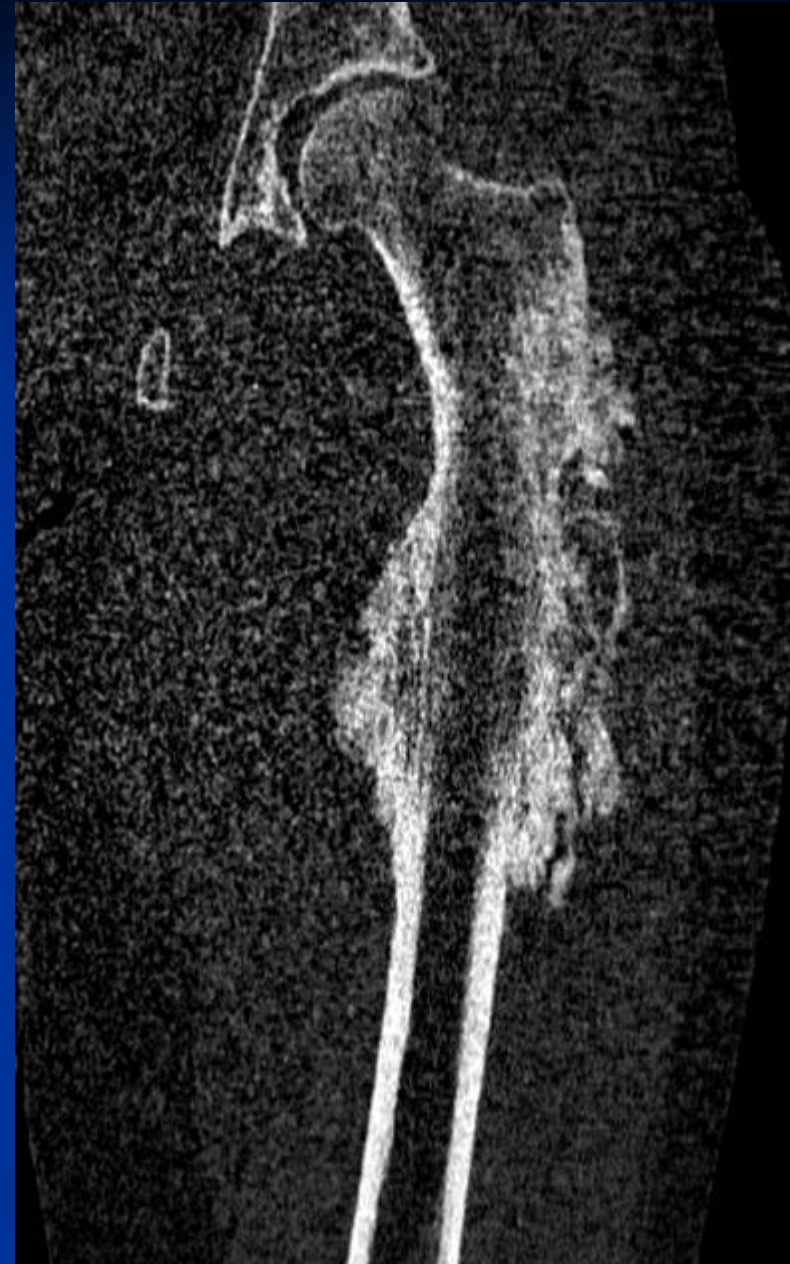
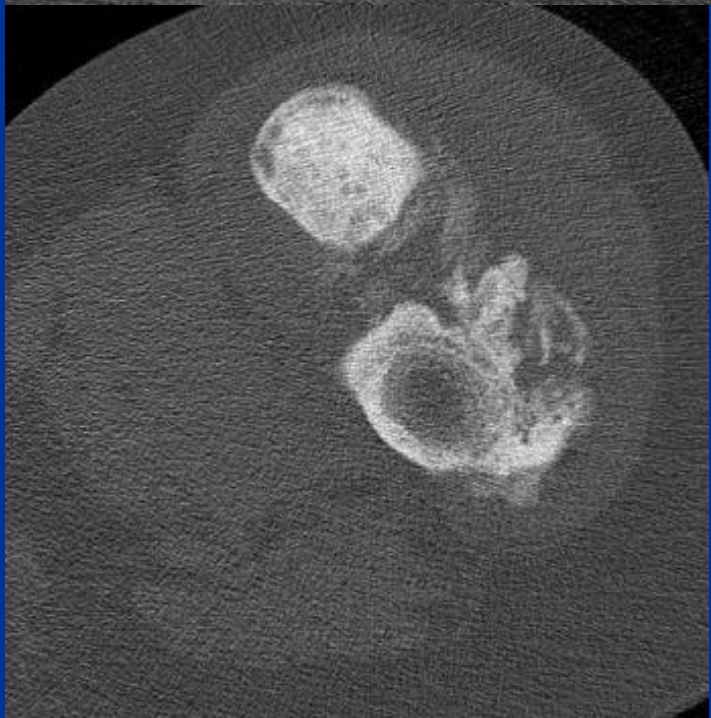
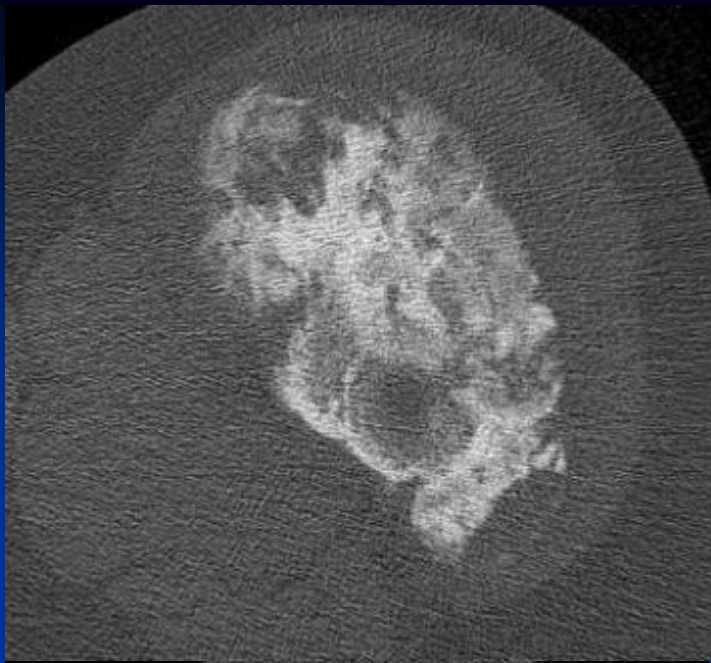


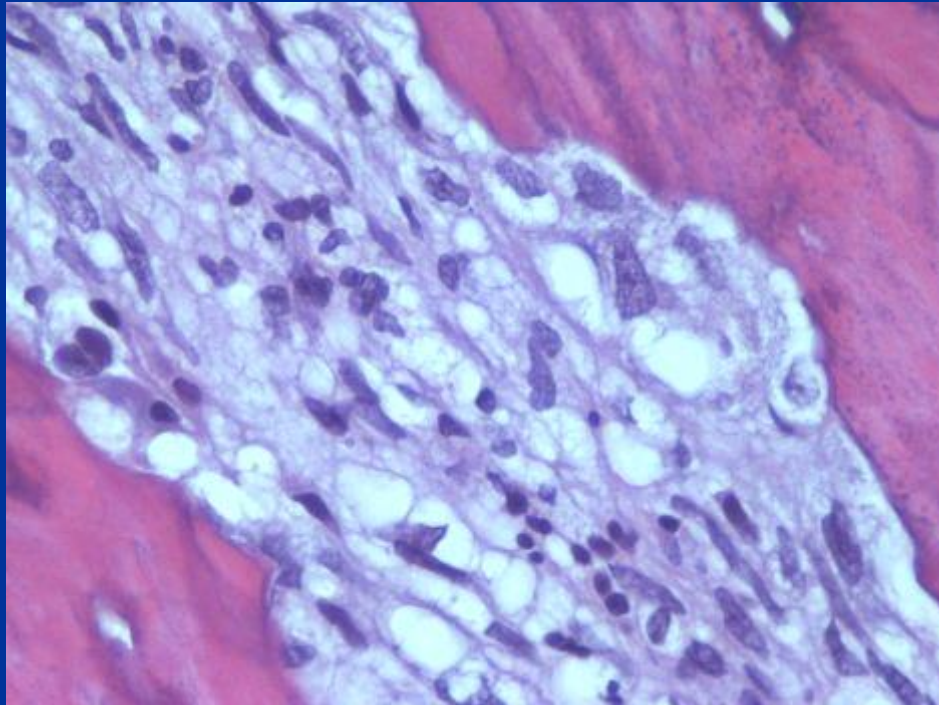
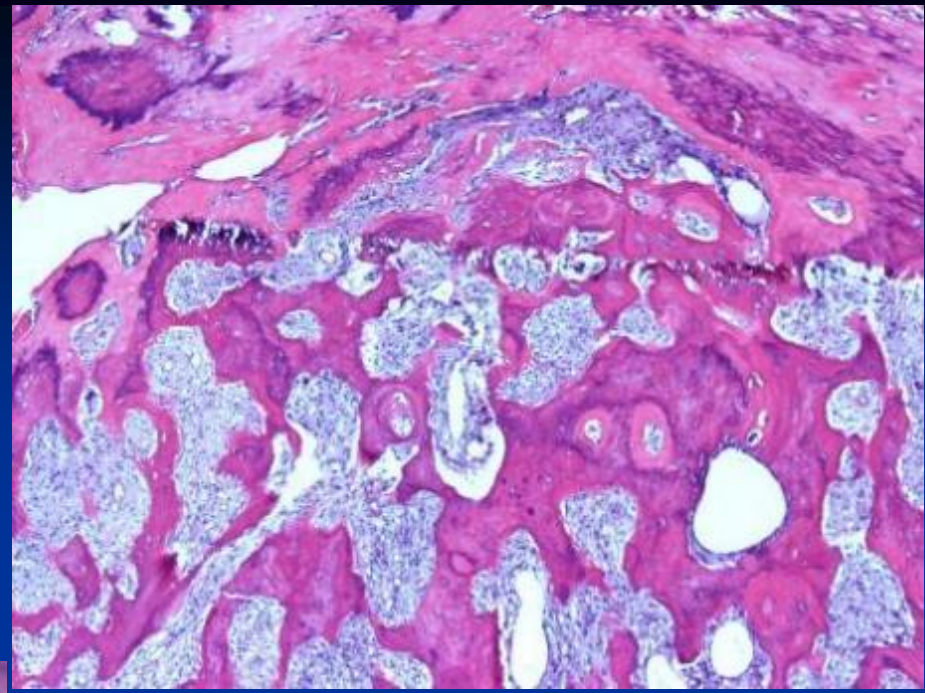
CASE #18

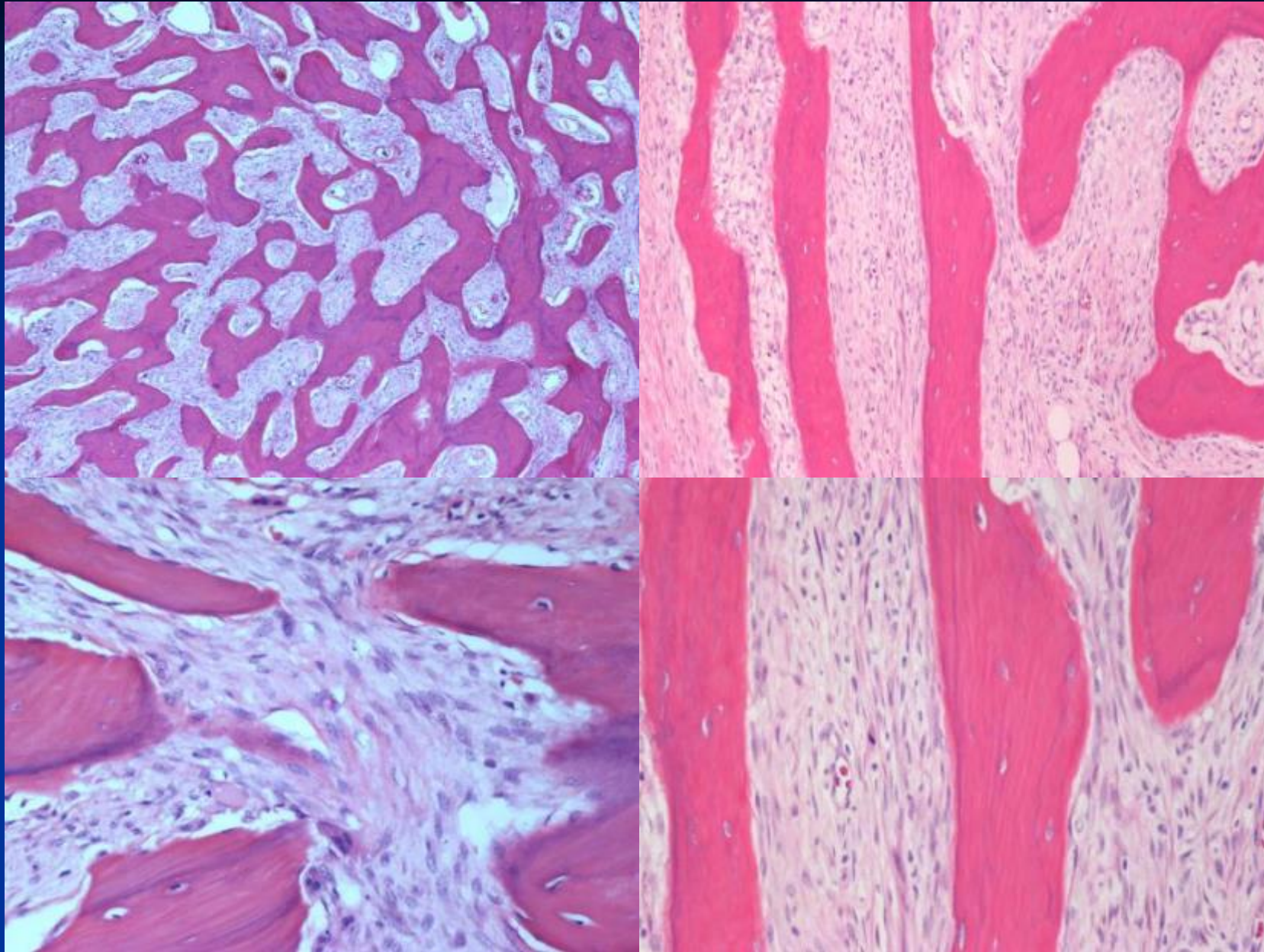
- 52 yo female with mild pain and an enlarging mass in the left thigh.
- Fever and weight loss in the last month

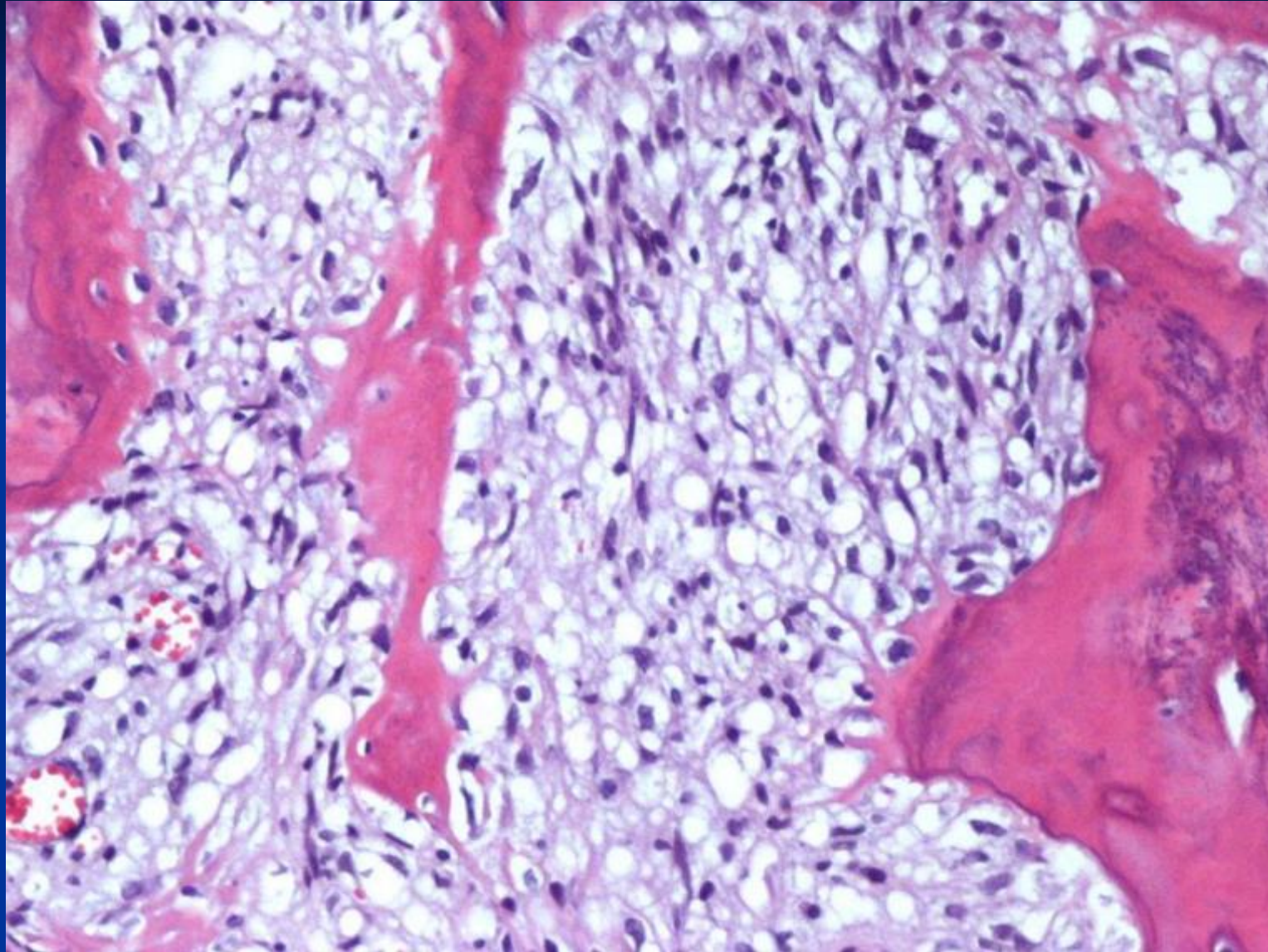












*Diagnosis Next

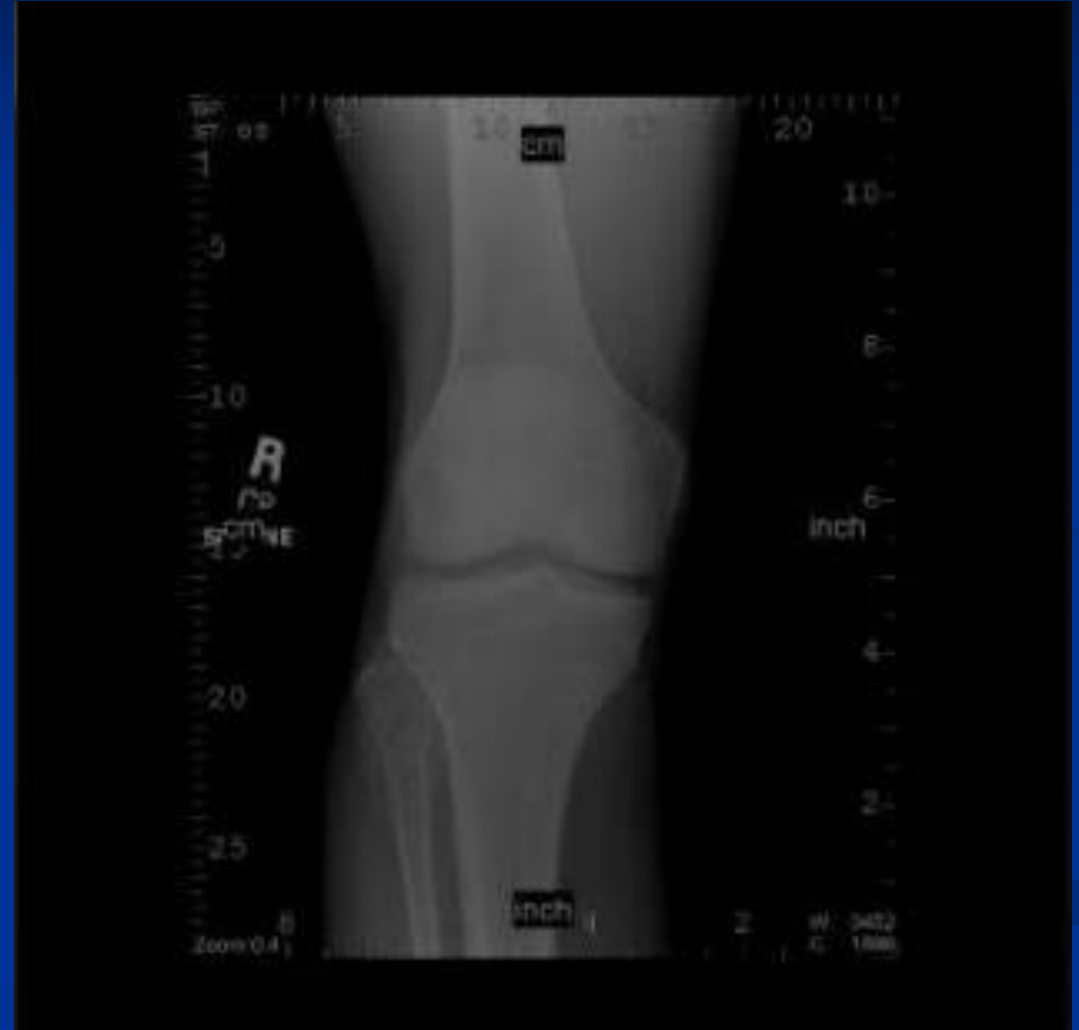

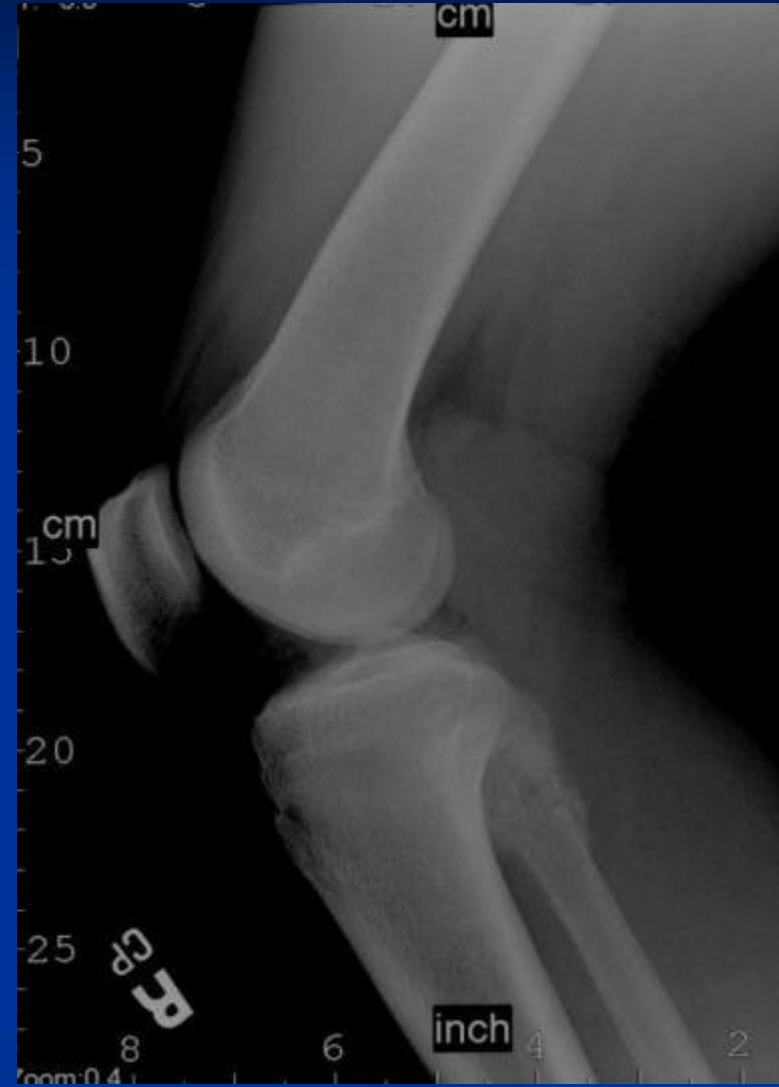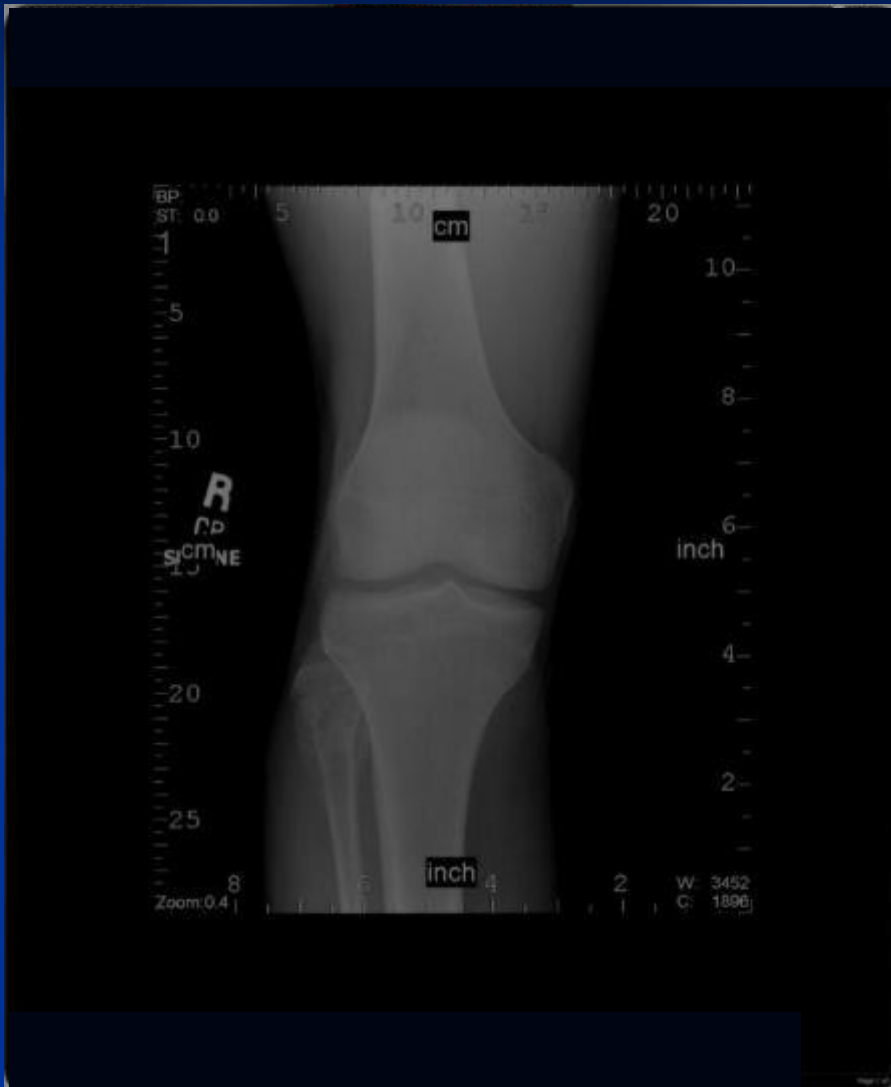Parosteal Osteosarcoma

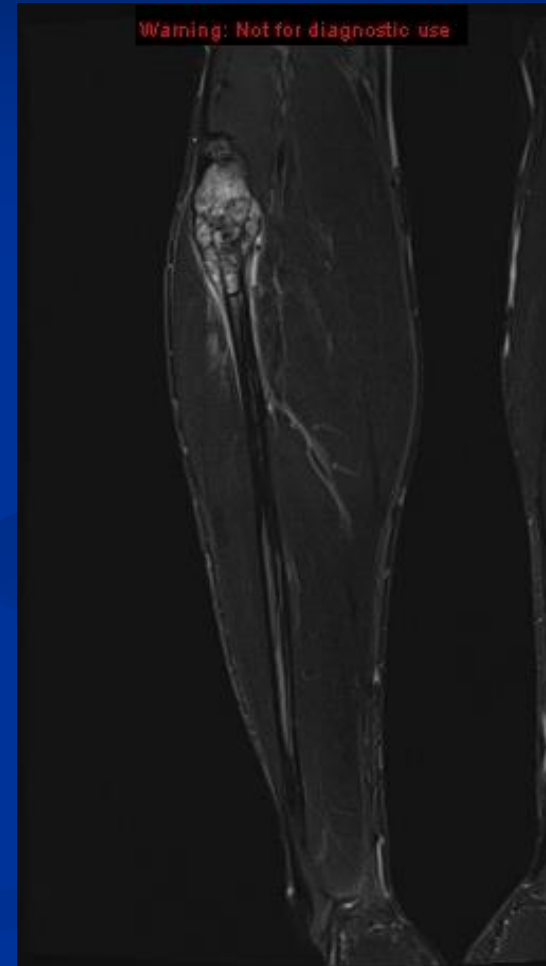
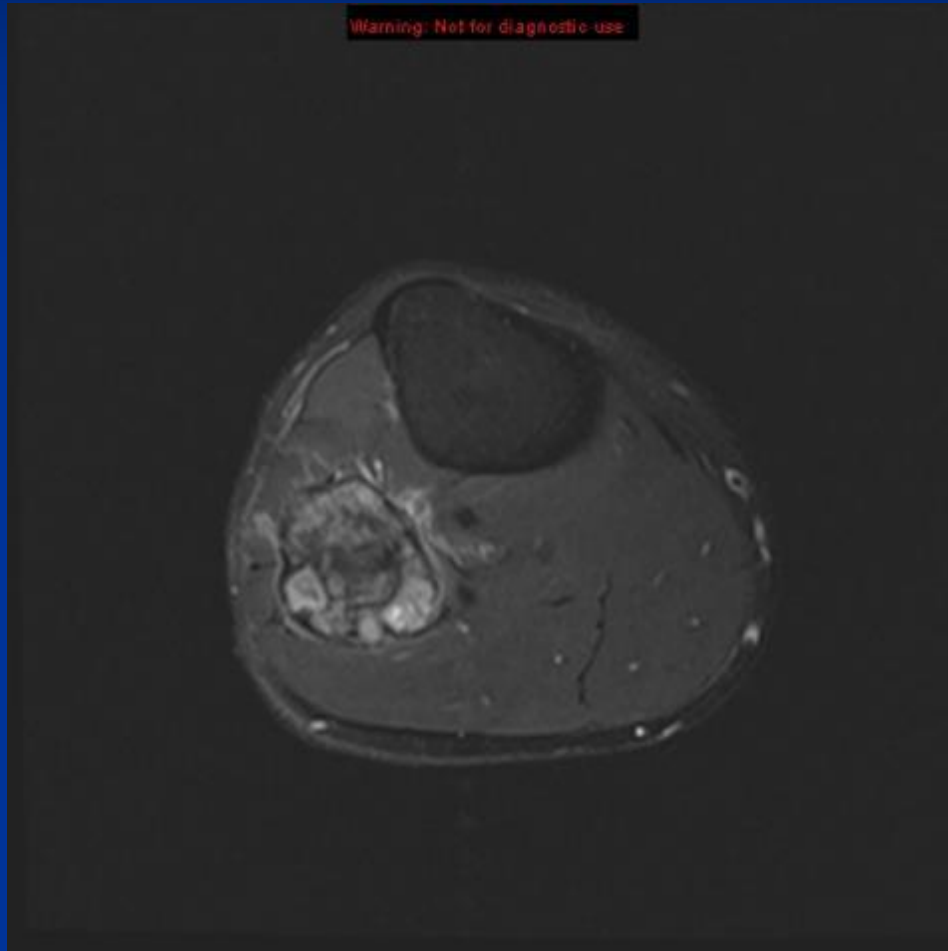


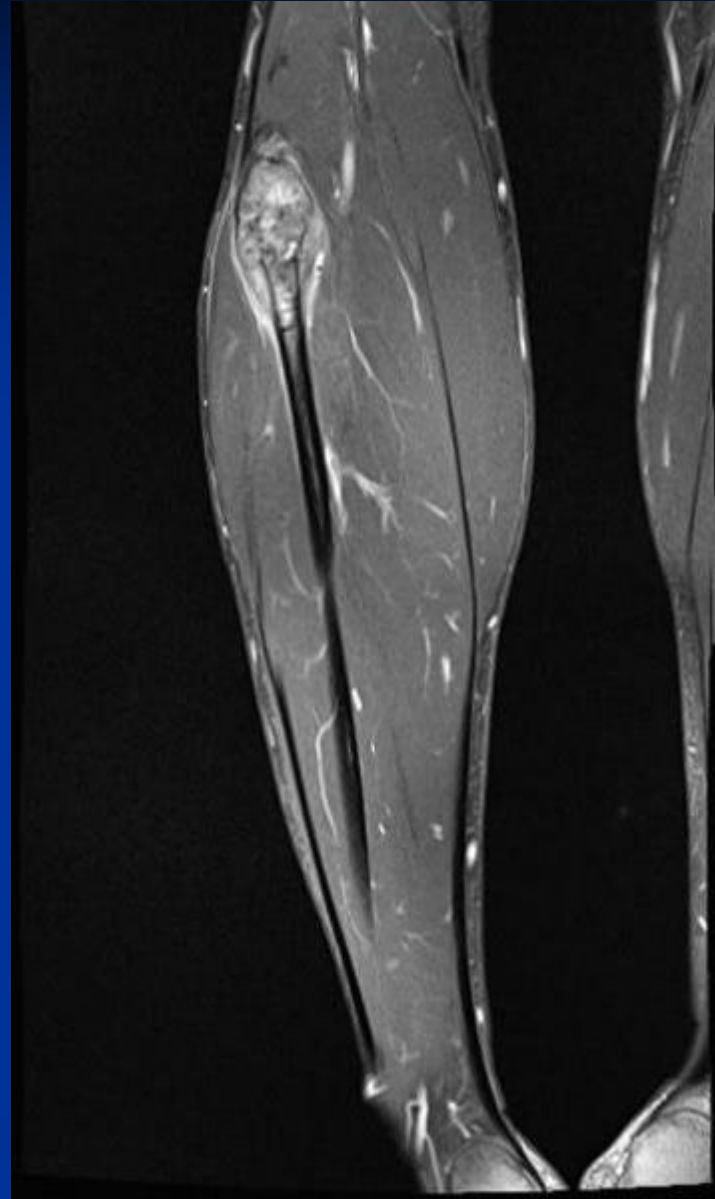
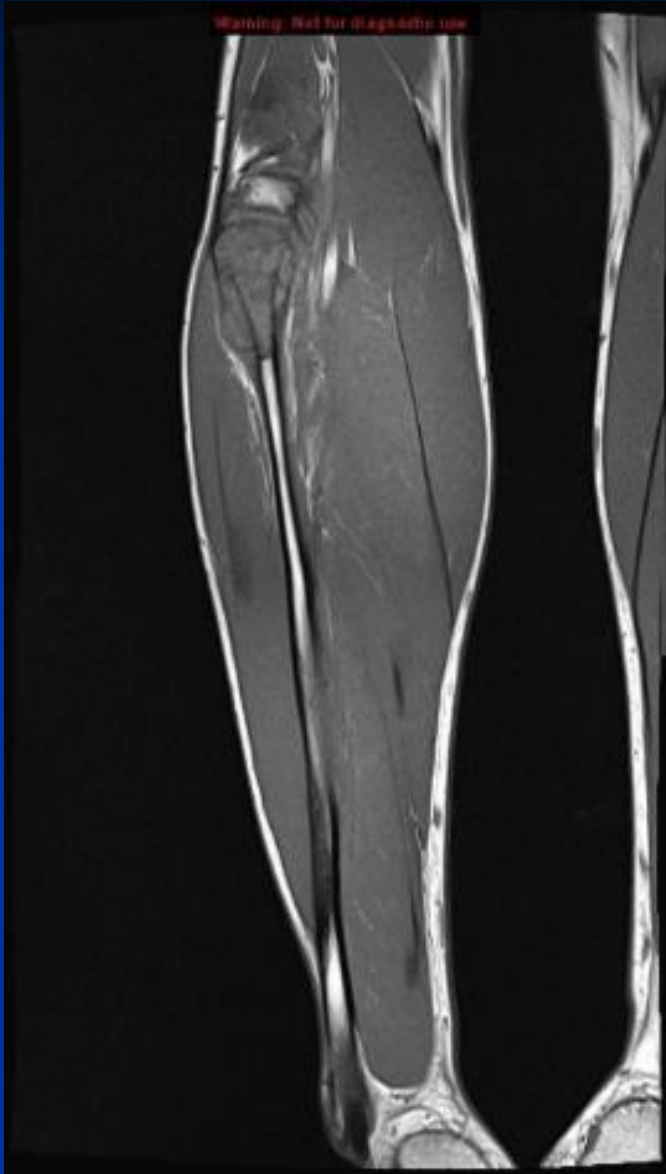CASE #19

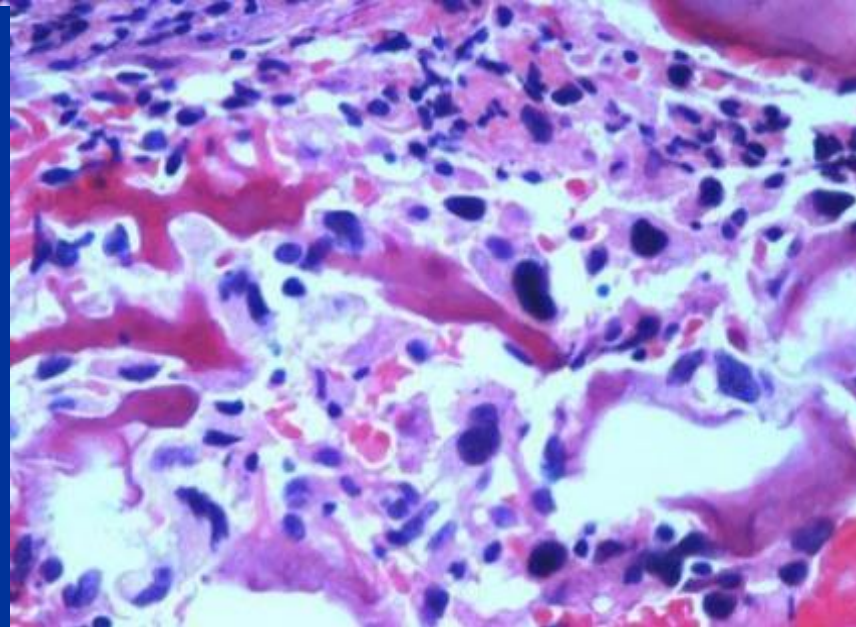
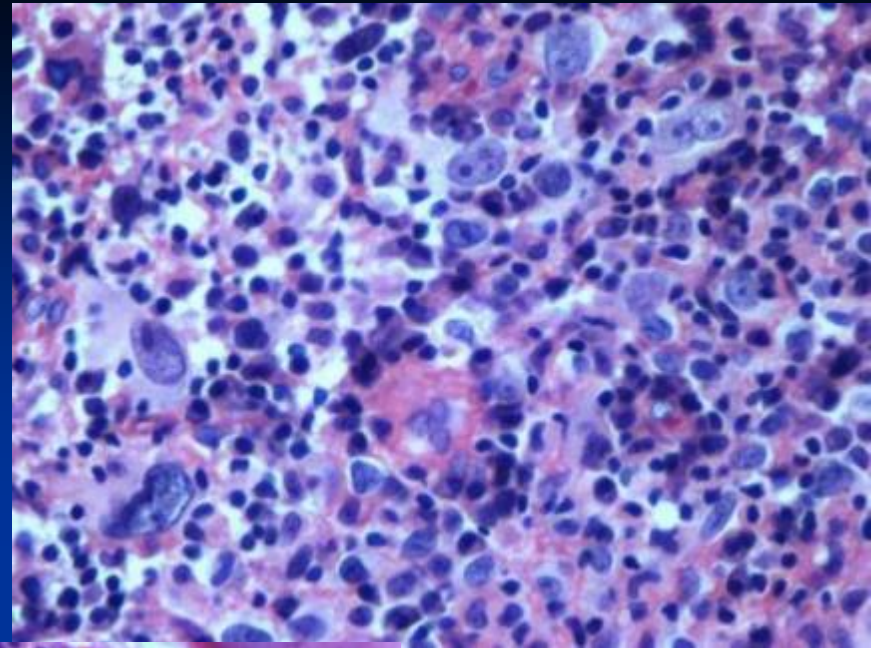
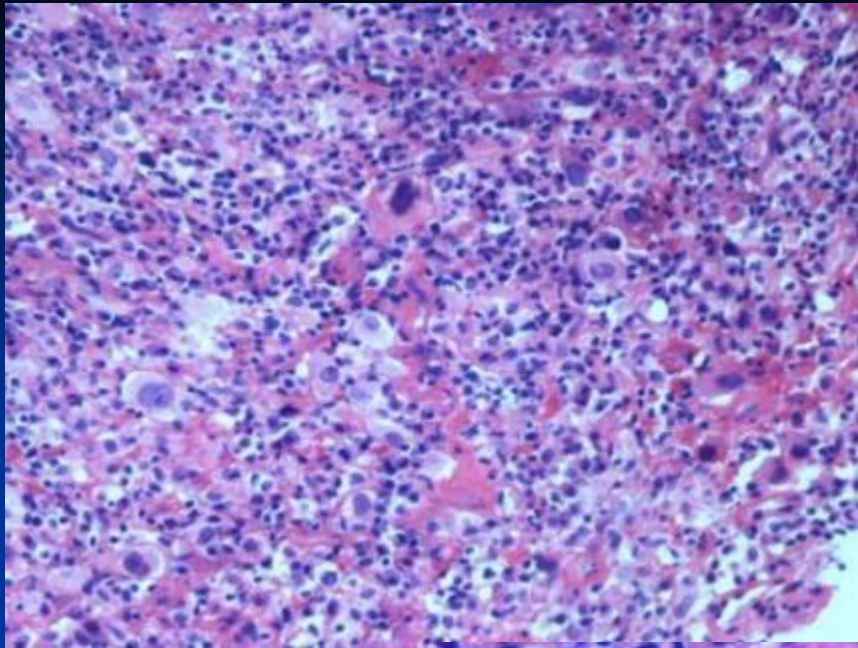
- 22 yo male
- 6 months of pain in the right knee.
- Hypoesthesia in the right foot.











*Diagnosis Next

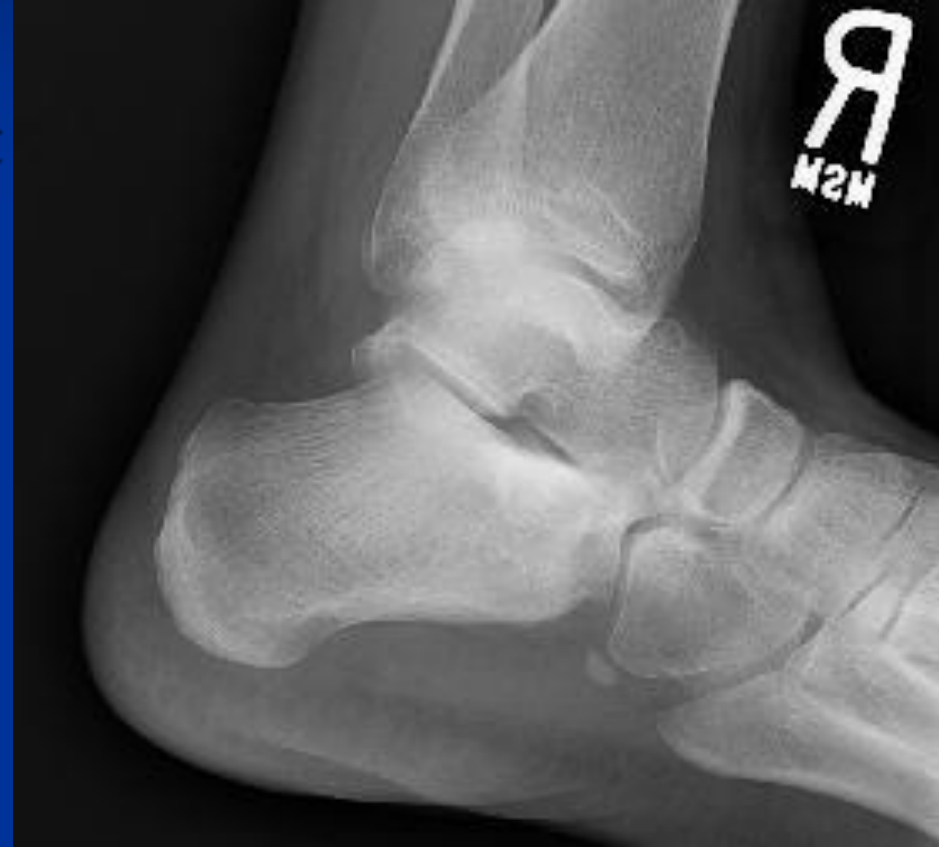

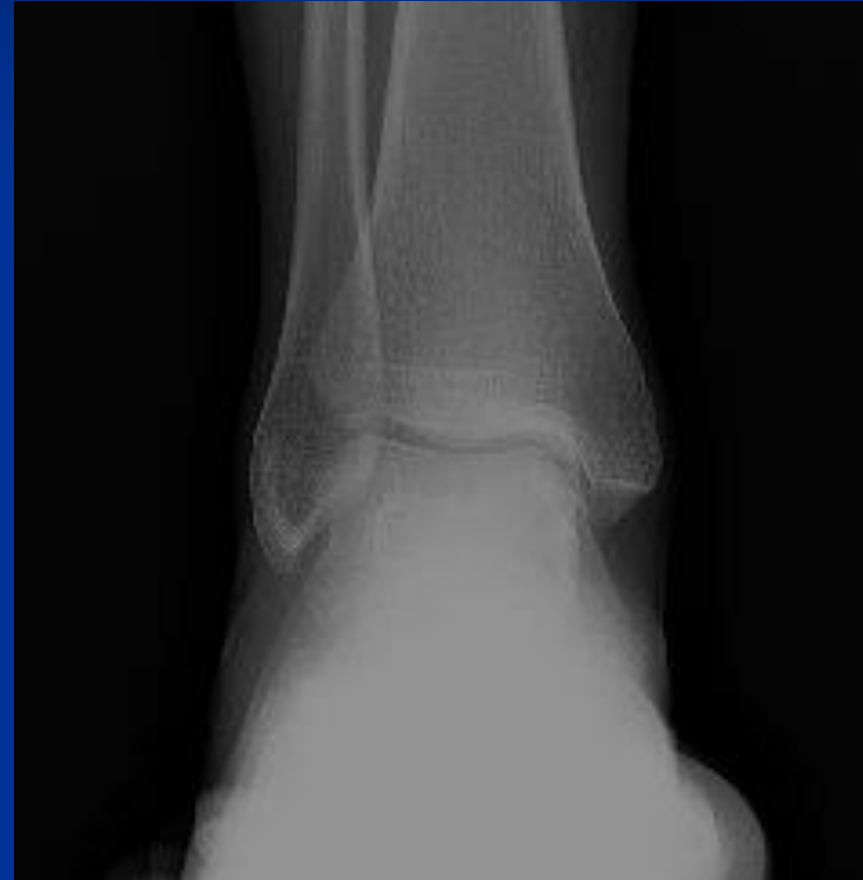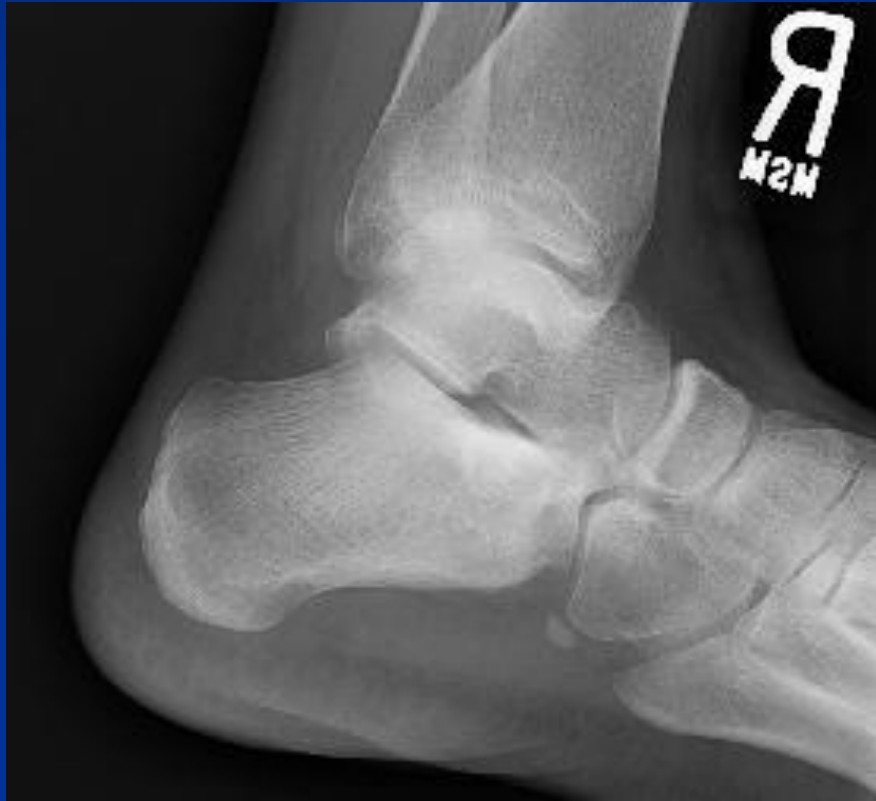Conventional High-grade Osteosarcoma

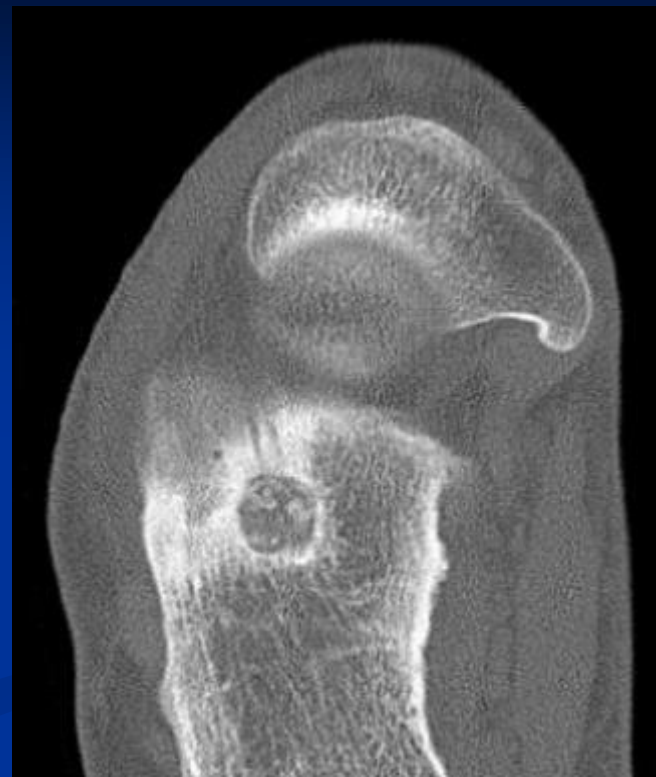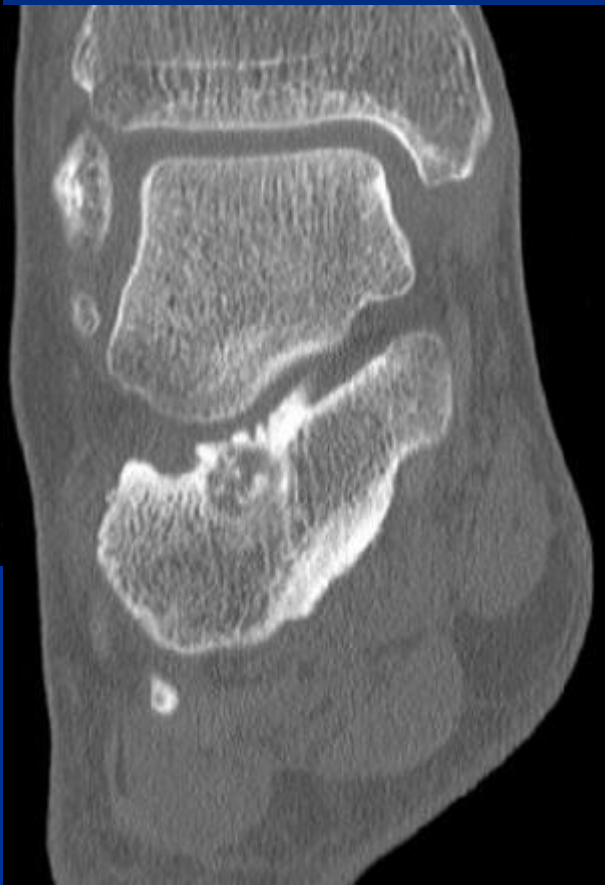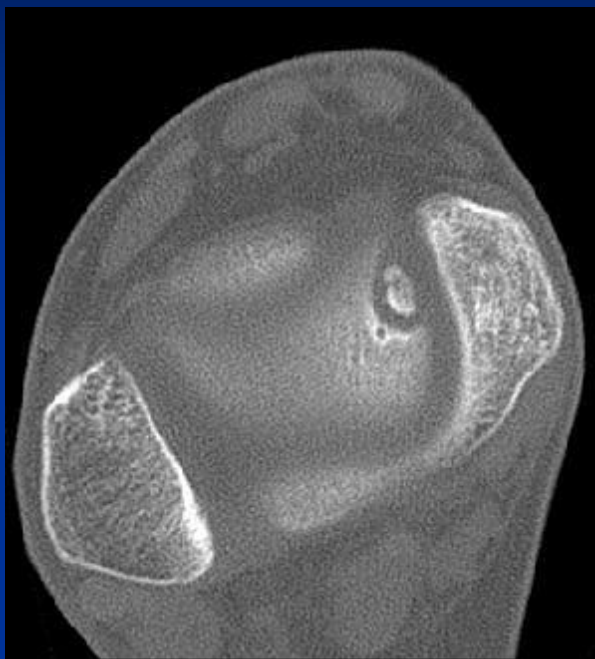


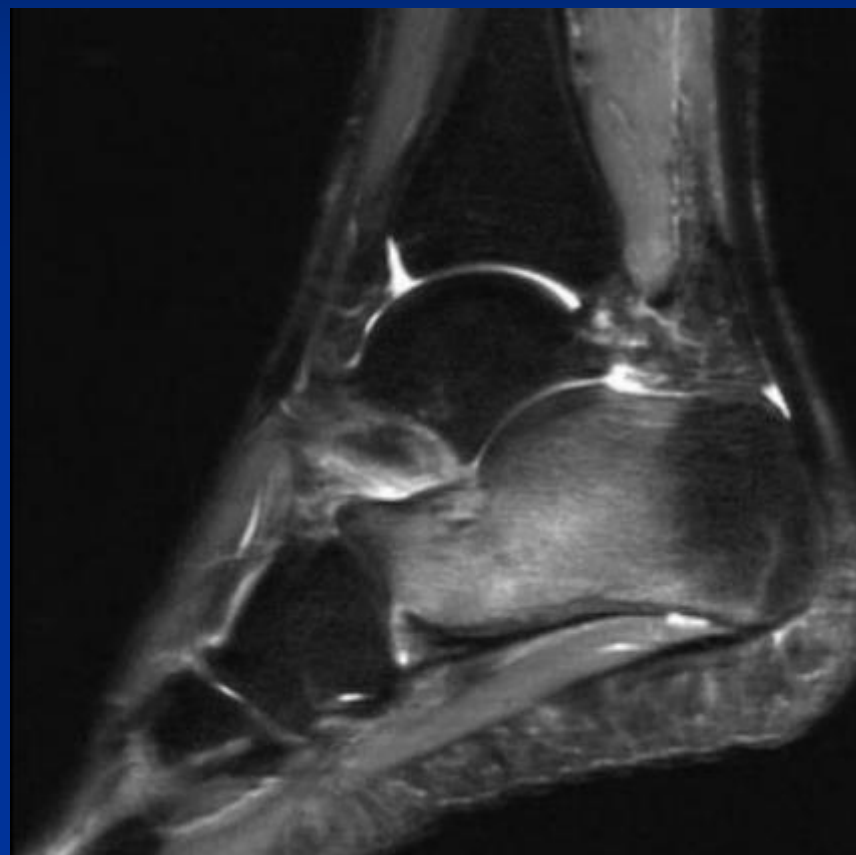
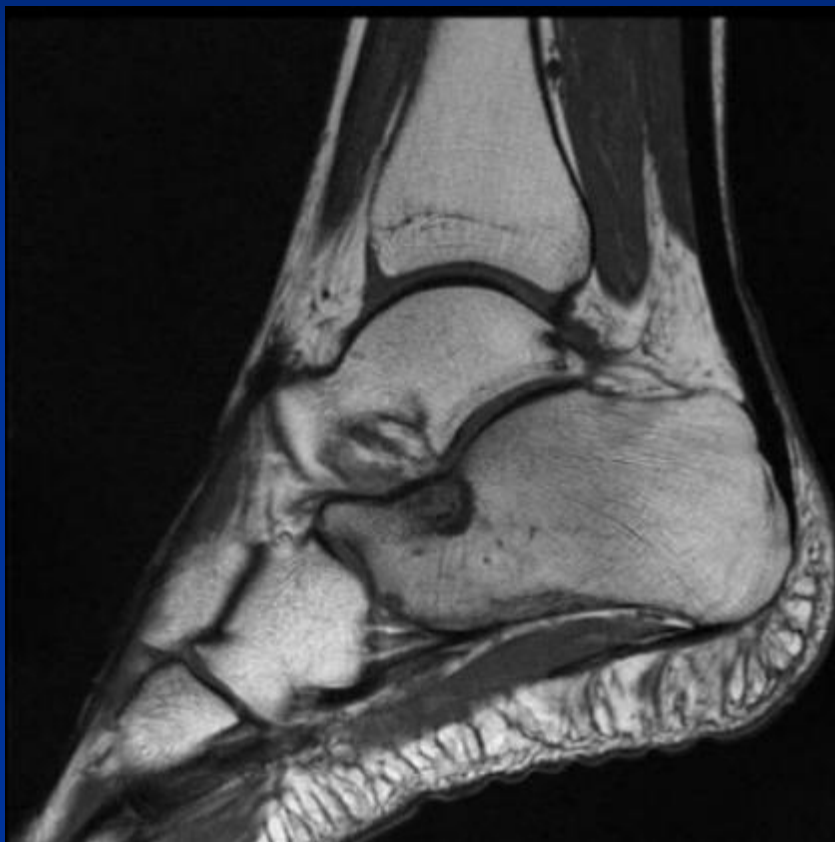CASE #20

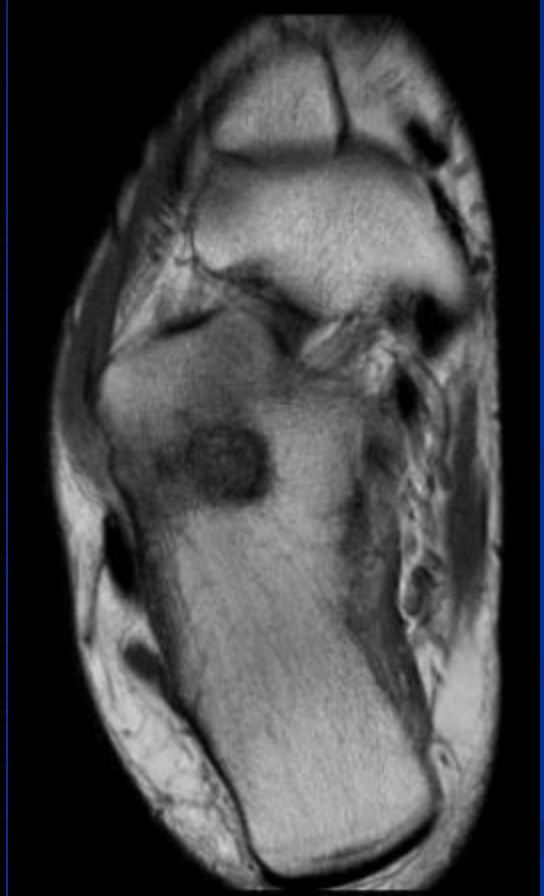
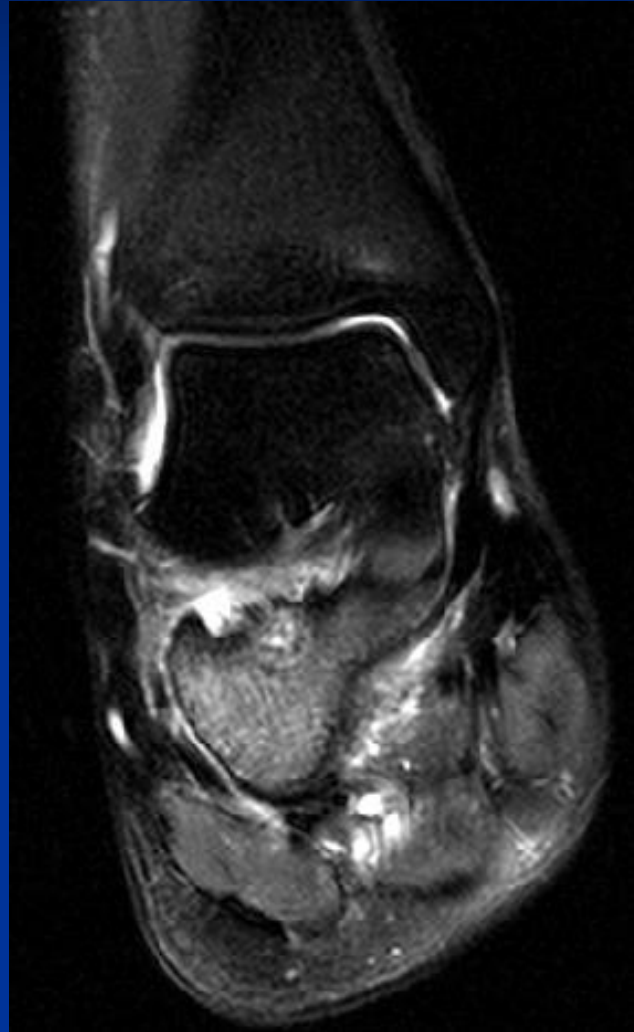
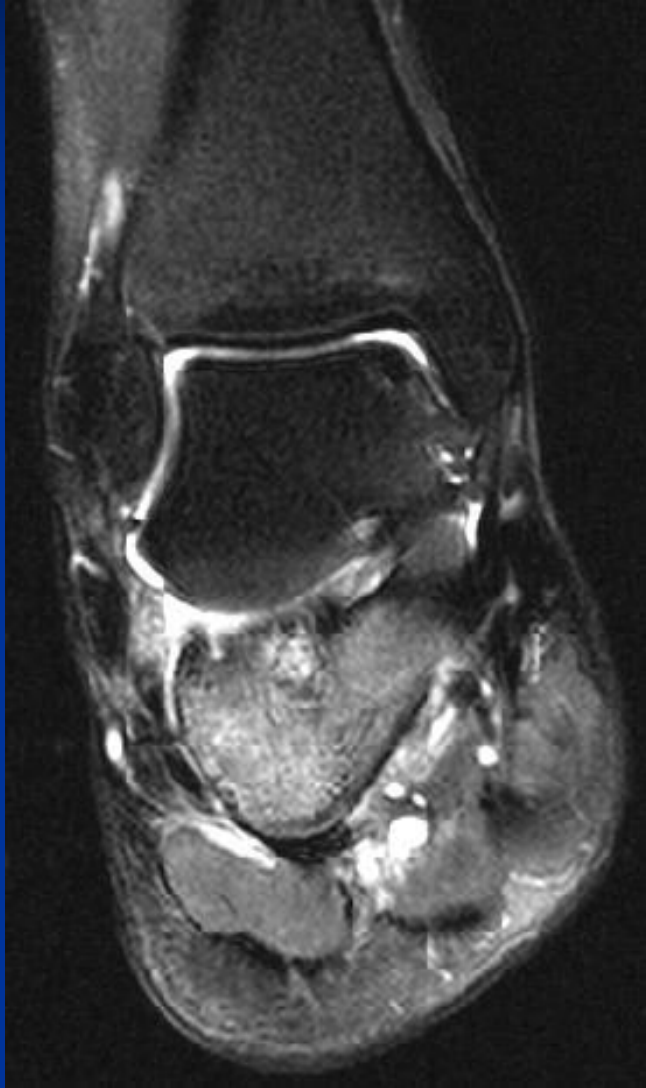
- 32 yo male
- Severe pain in his right foot especially in the night for the last 7 months.

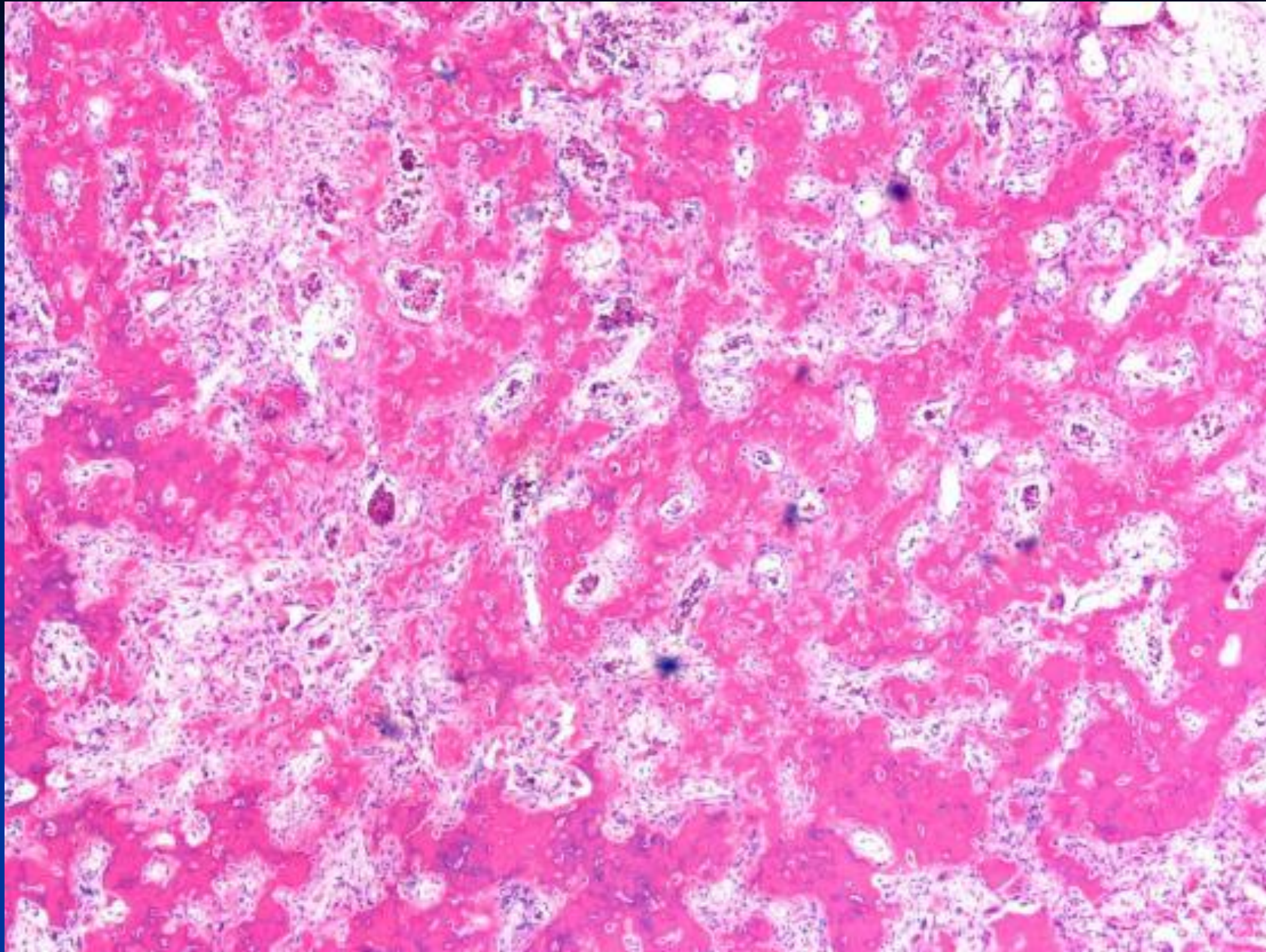


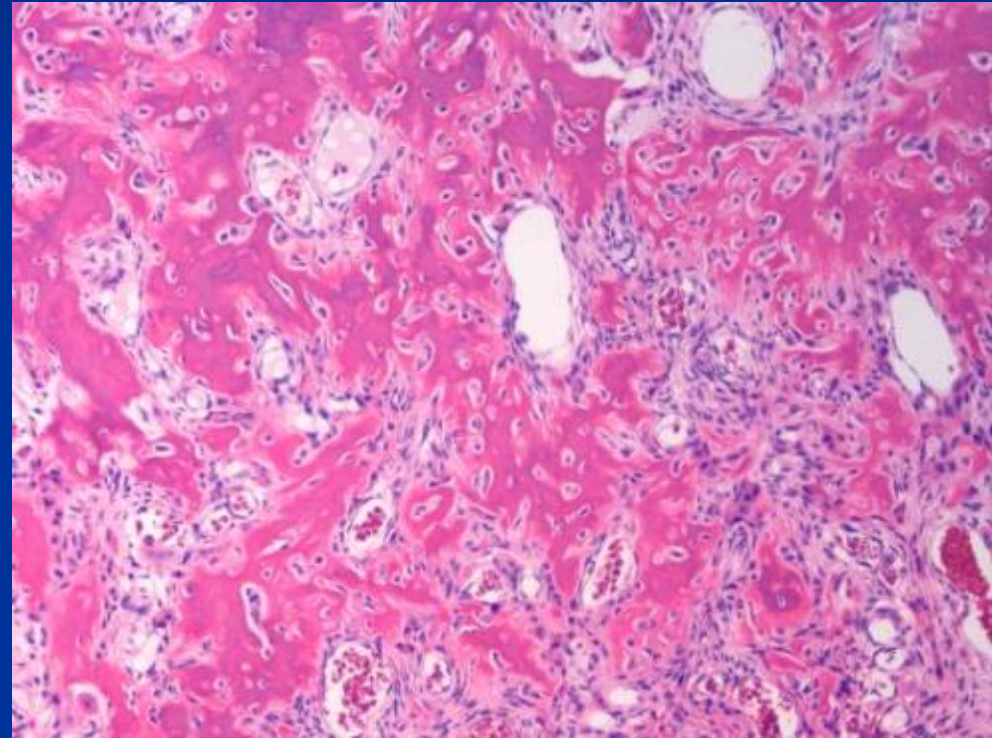
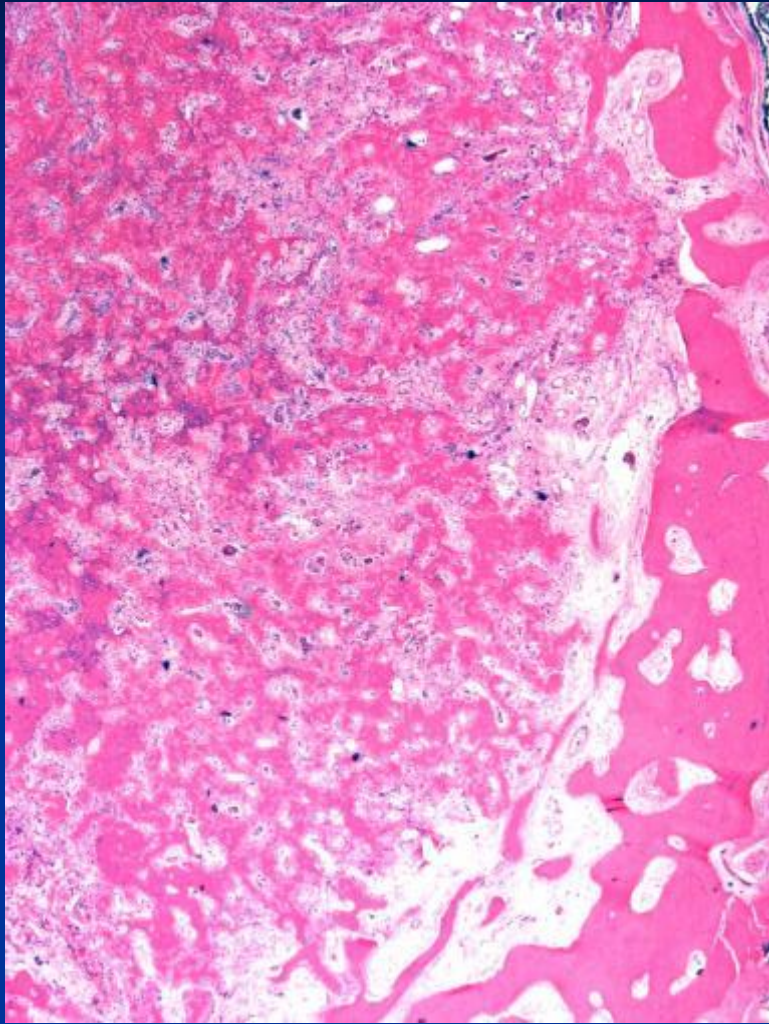












***Diagnosis Next**



Osteoid Osteoma



Thank You!
www.TumorSurgery.org

