

Unknown Musculoskeletal Tumor Cases Part A

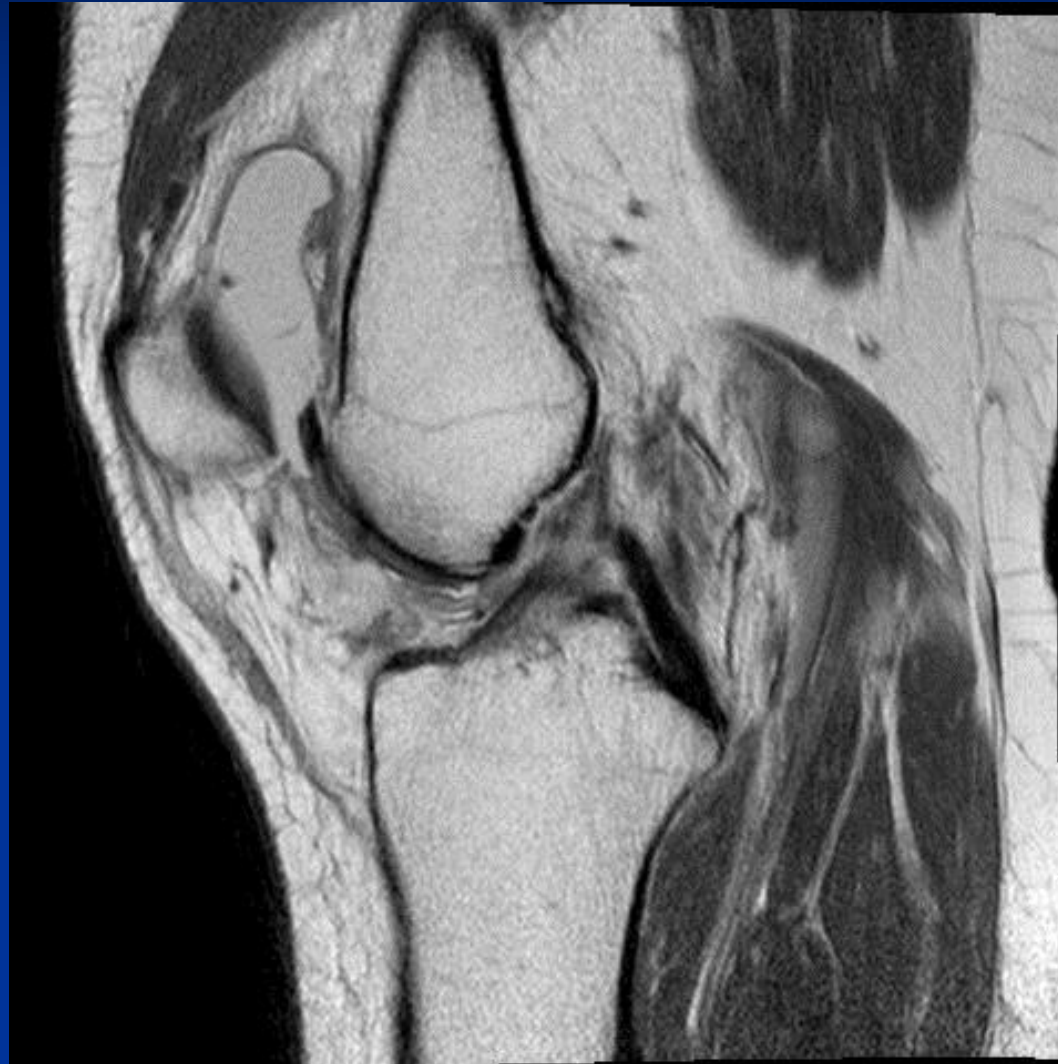Cases 1-10

James C. Wittig, MD
Orthopedic Oncologist
Sarcoma Surgeon
www.TumorSurgery.org

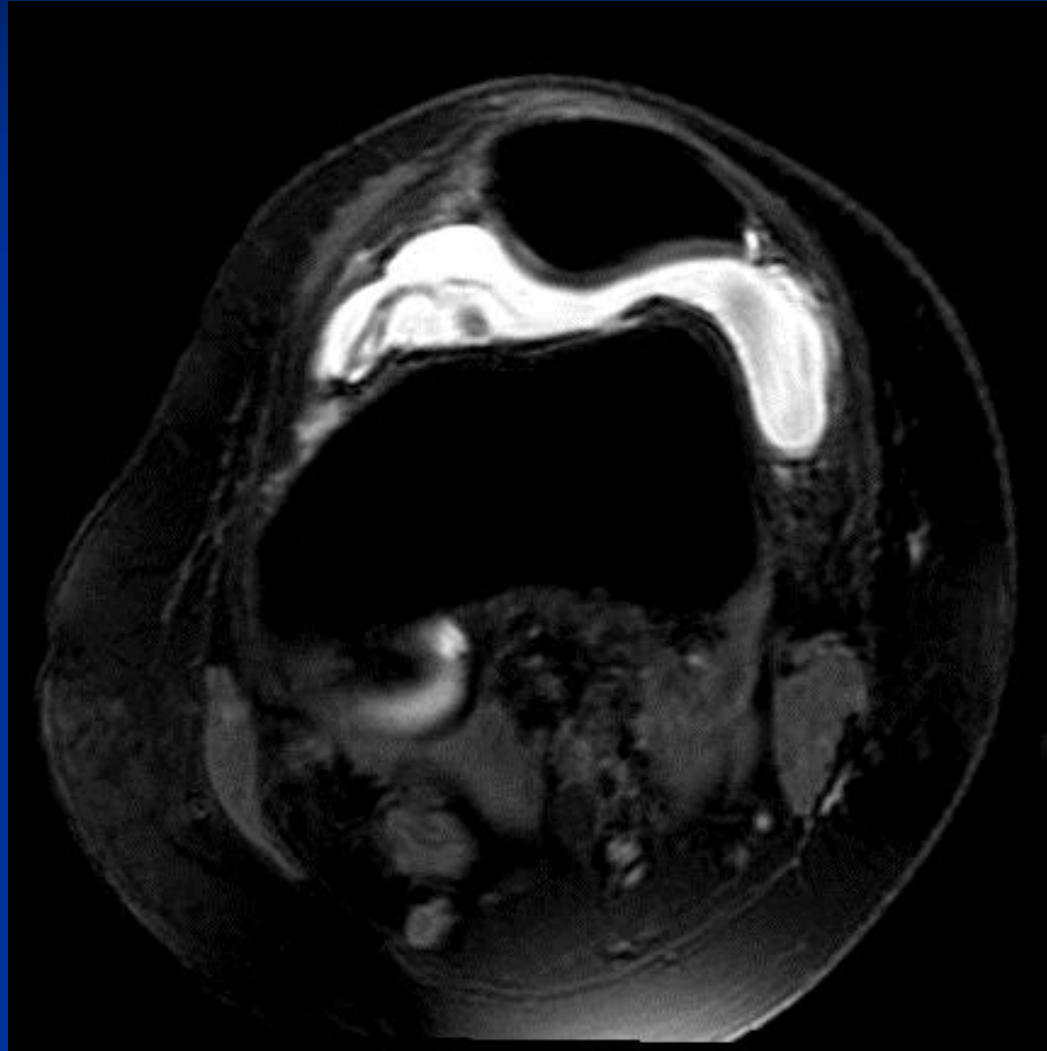
CASE #1

- 44-year-old woman presented with anterior left knee pain and swelling/burning sensations. Her pain arose 8 months ago when she birthed triplets. She received a cortisone injection and her symptoms improved. CBC showed a low RBC, HGB, HCT, and monocyte count, but a high neutrophil count. All other blood work appeared unremarkable. MRI's are included. The mass was removed. Low and high power histology slides are included.

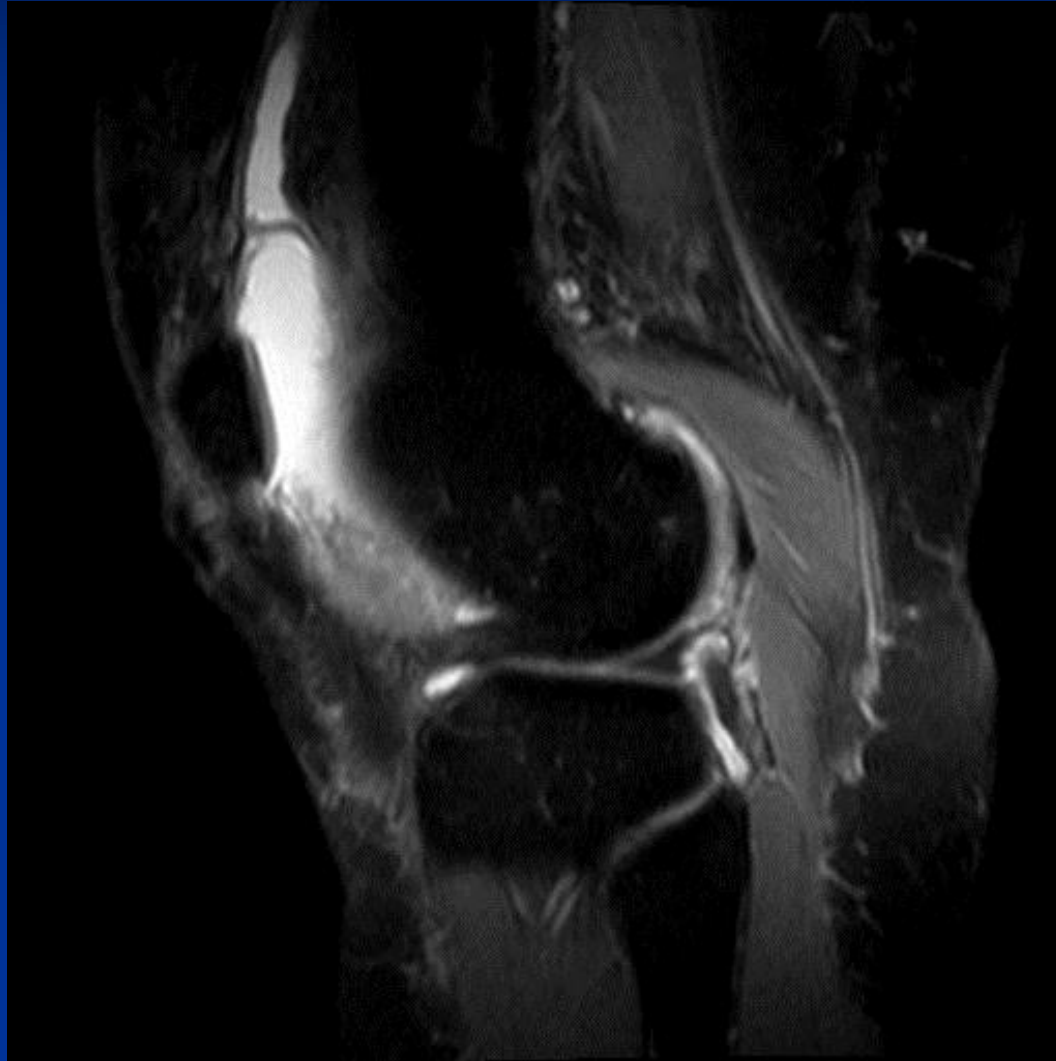
Protein Density Weighted - TSE



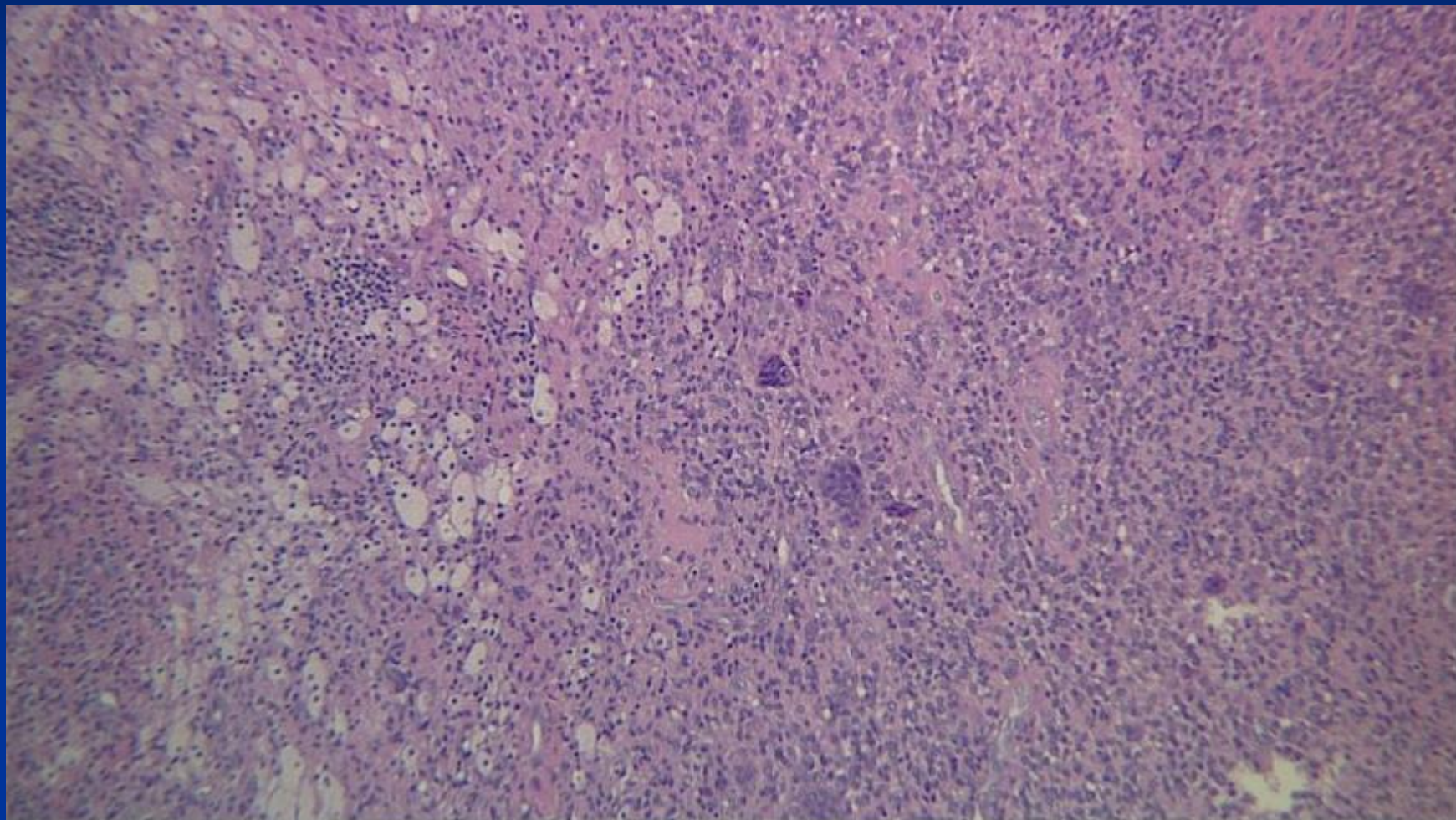
3D-Watsf Try



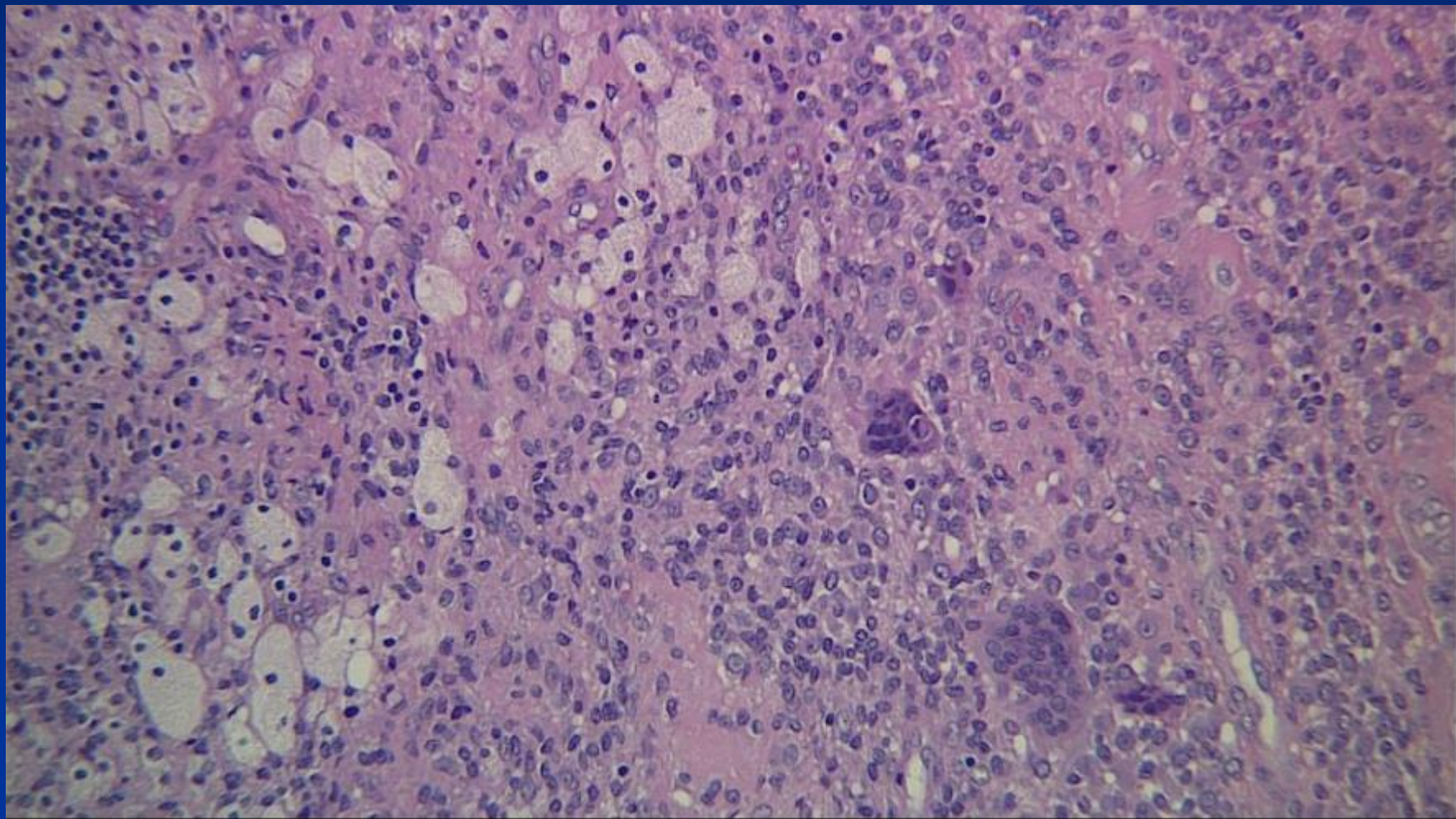
PDW-SPIR PH FAST

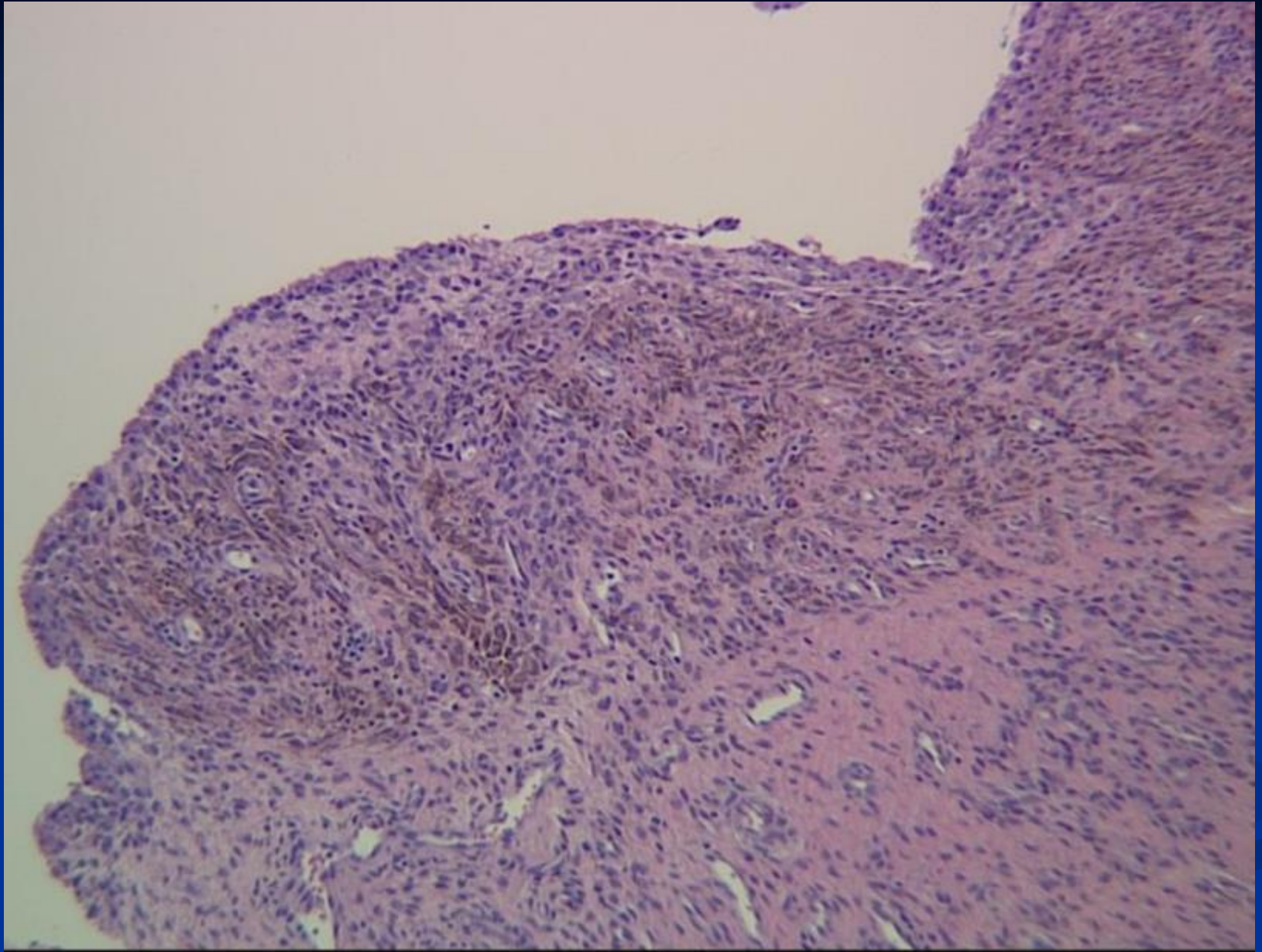


Low Power



High Power





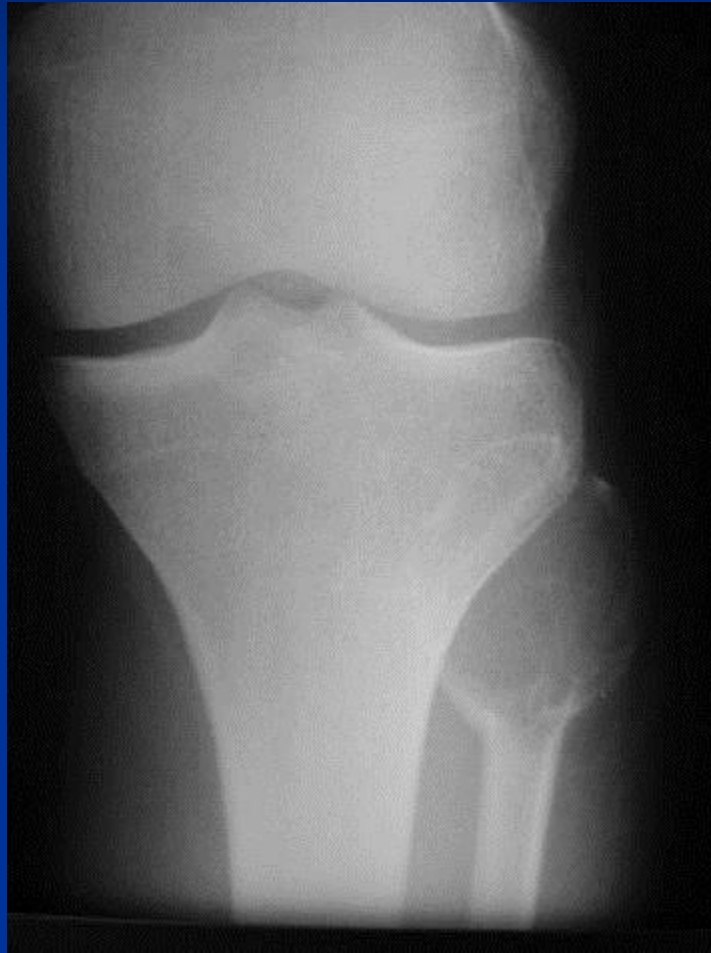*Diagnosis Next



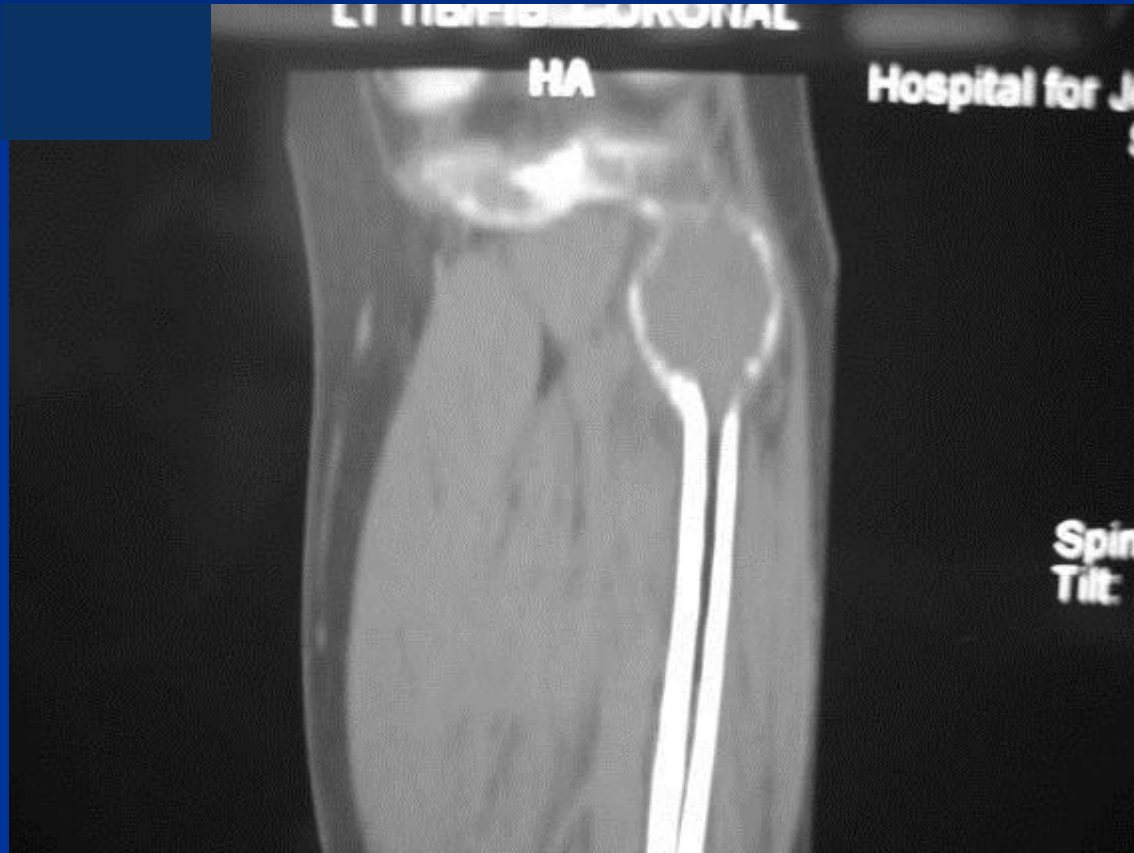PVNS

CASE #2

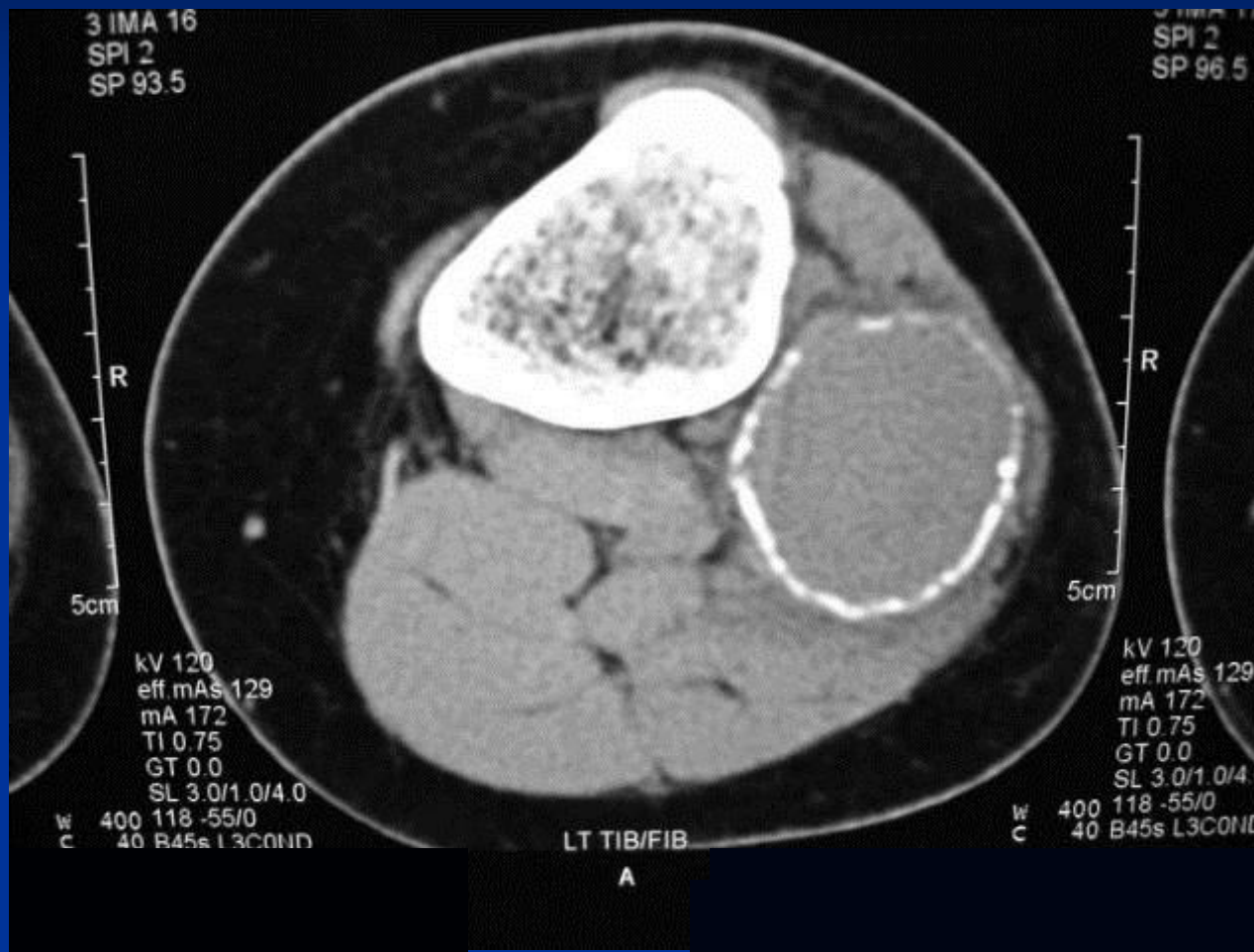19 year old female with a mildly painful swelling on the outside of her left knee for several months. The patient gave a history of a twisting injury to the knee several months prior to the onset of pain. The patient was otherwise healthy. She was born in the U.S. and gave no history of travel. There were no fevers, night sweats or weight loss. Blood tests were normal. The lesion was low to intermediate signal on T1 and intermediate to high signal on T2 weighted images. The tumor diffusely enhanced with contrast. Bone scan was performed. A biopsy was obtained.



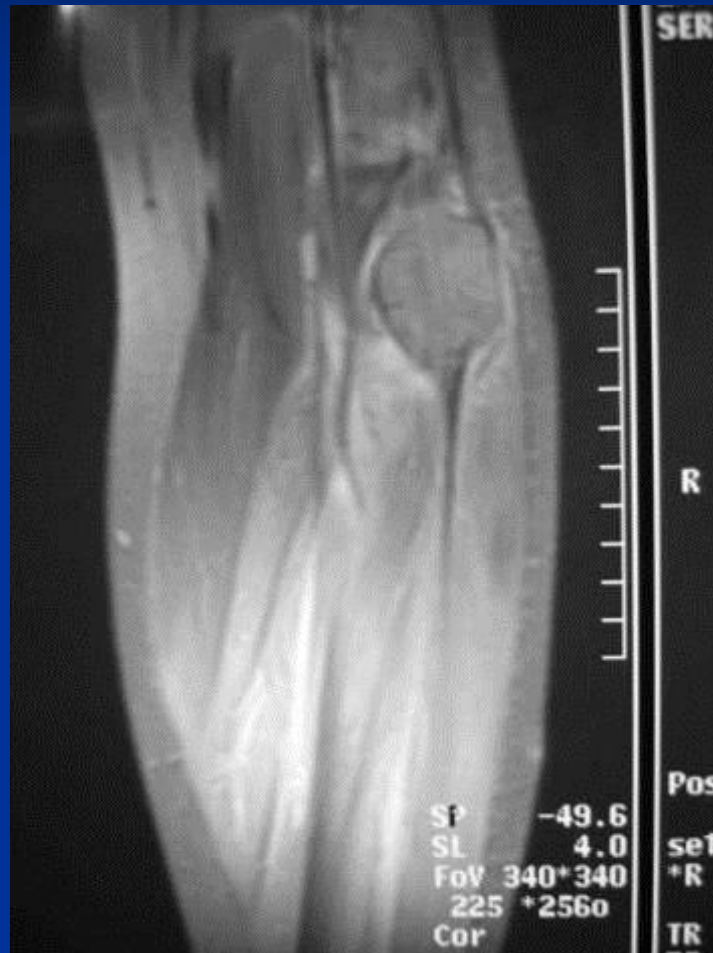CT Scan

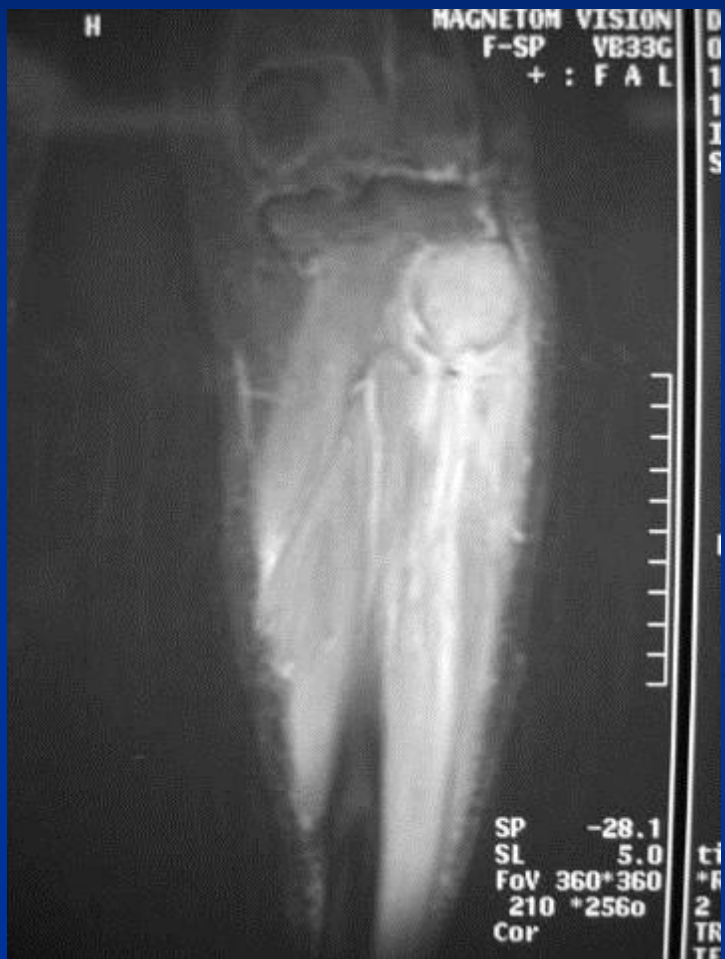

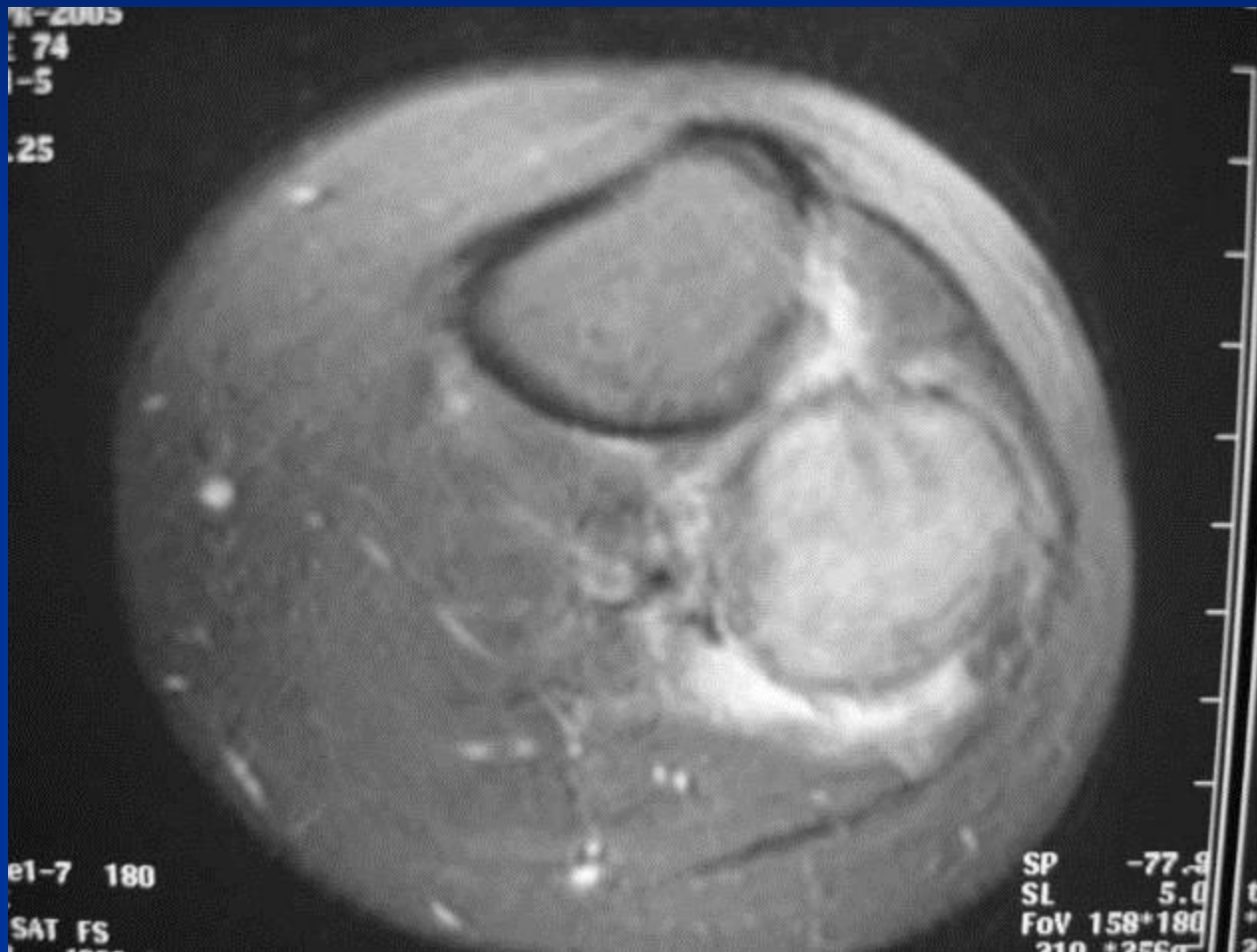CT Scan Axial Section



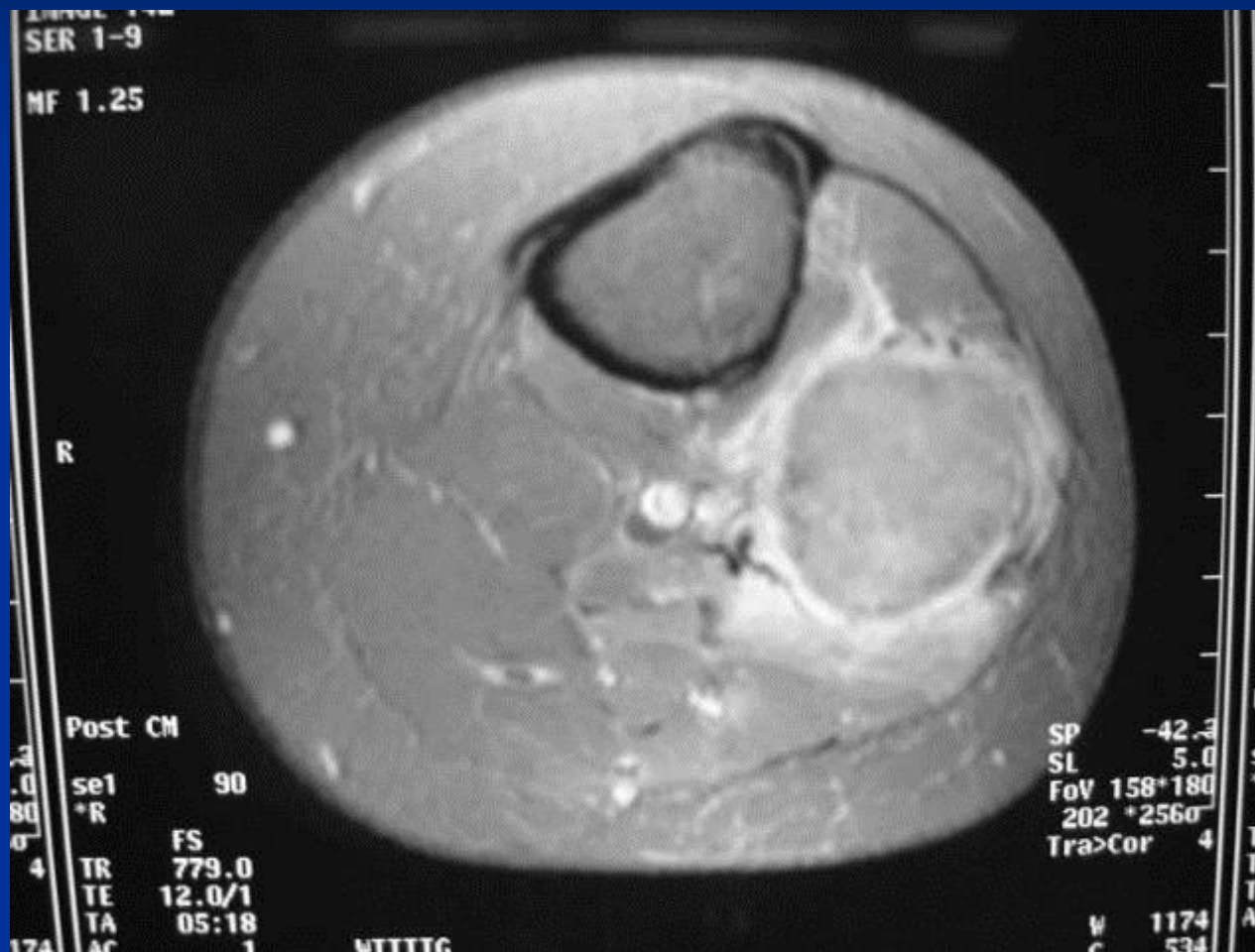MRI



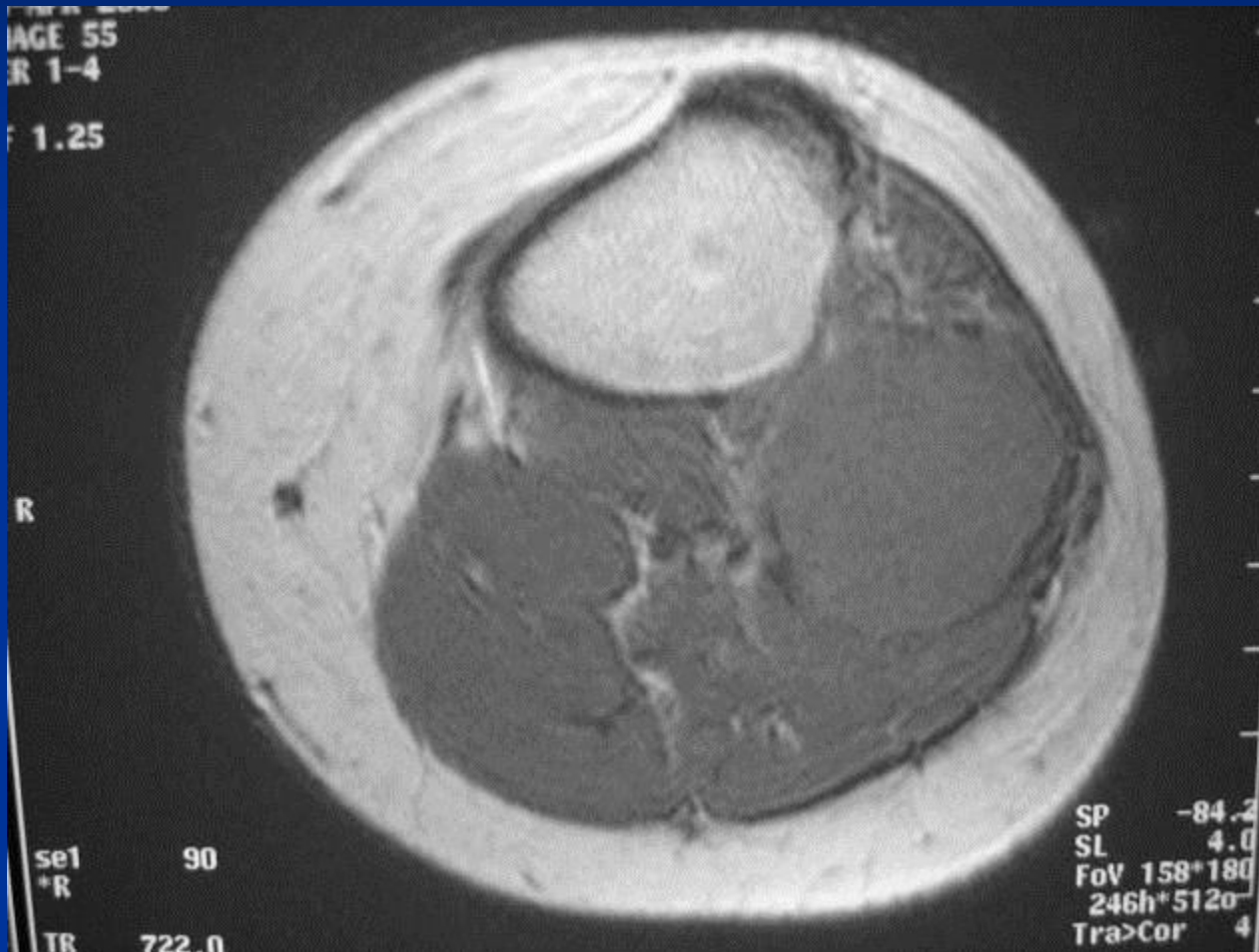



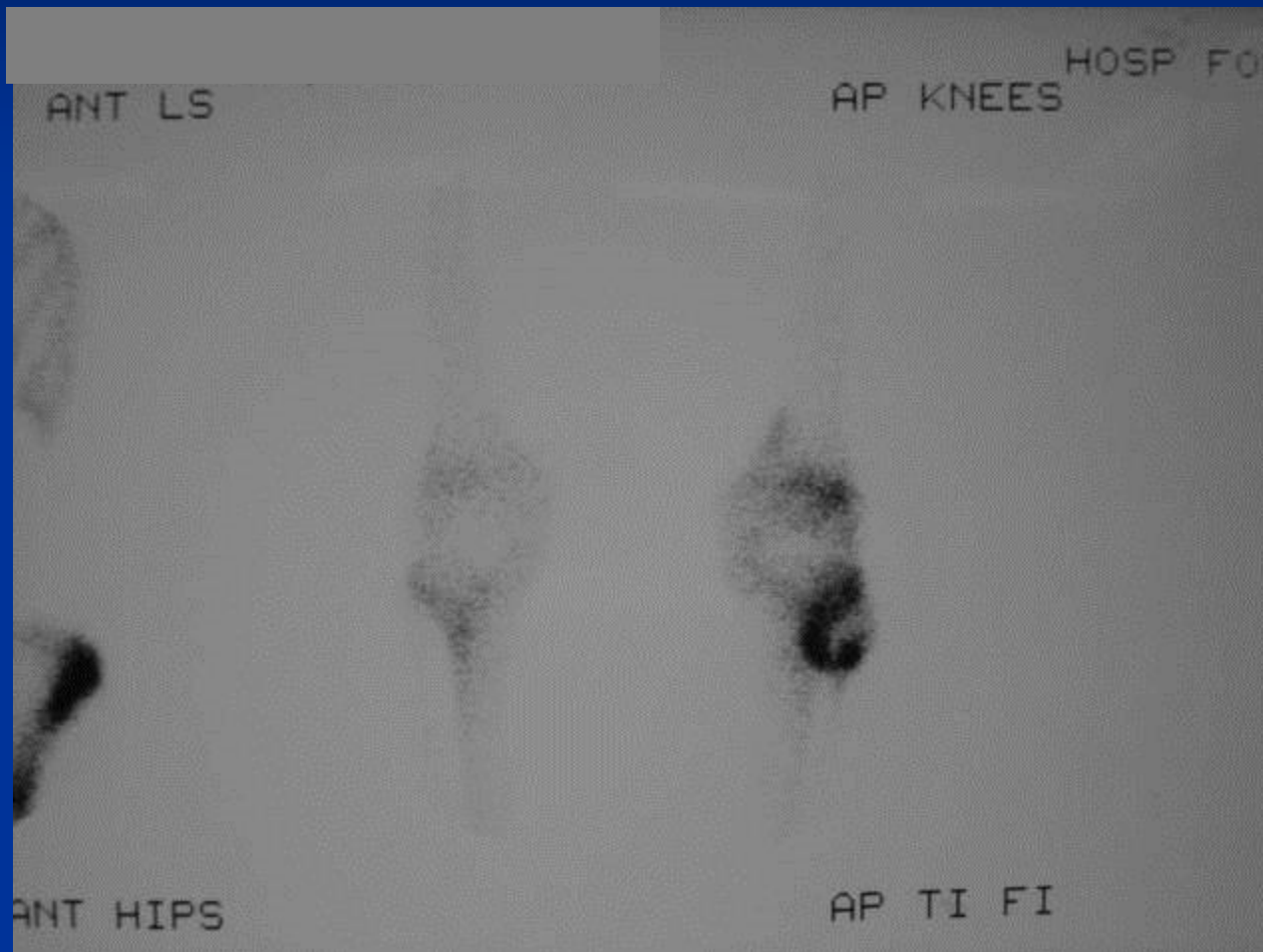
MRI with Gadolinium Contrast

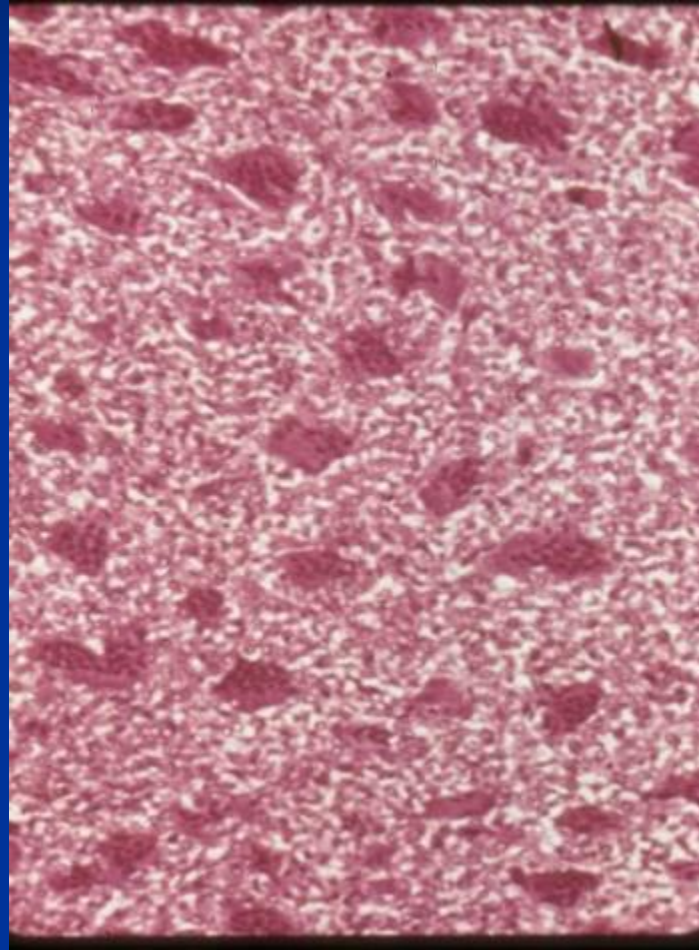


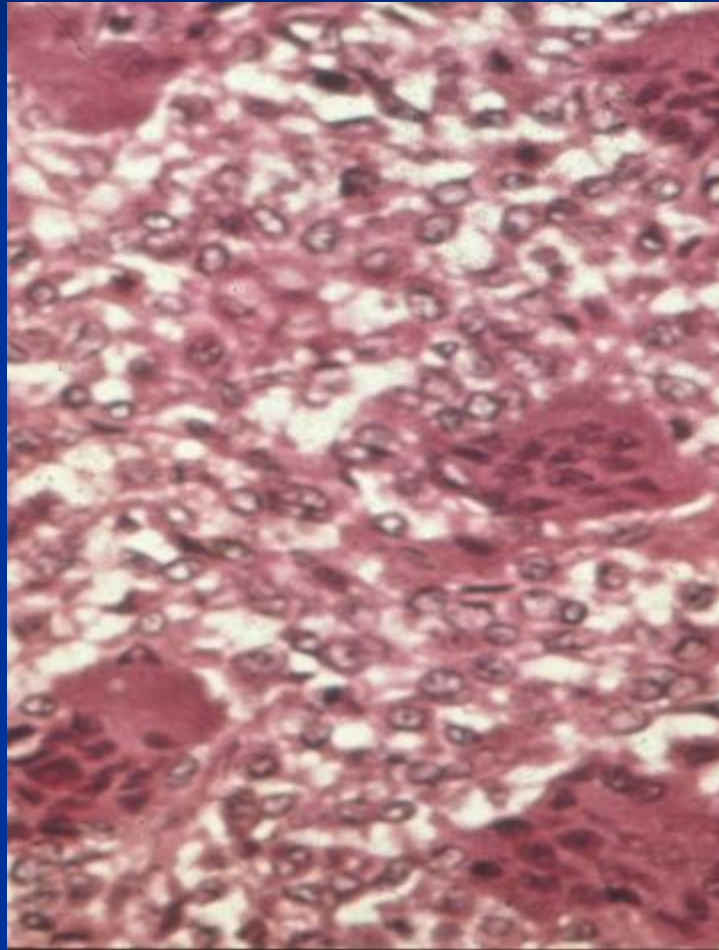
T1 Weighted Axial MRI

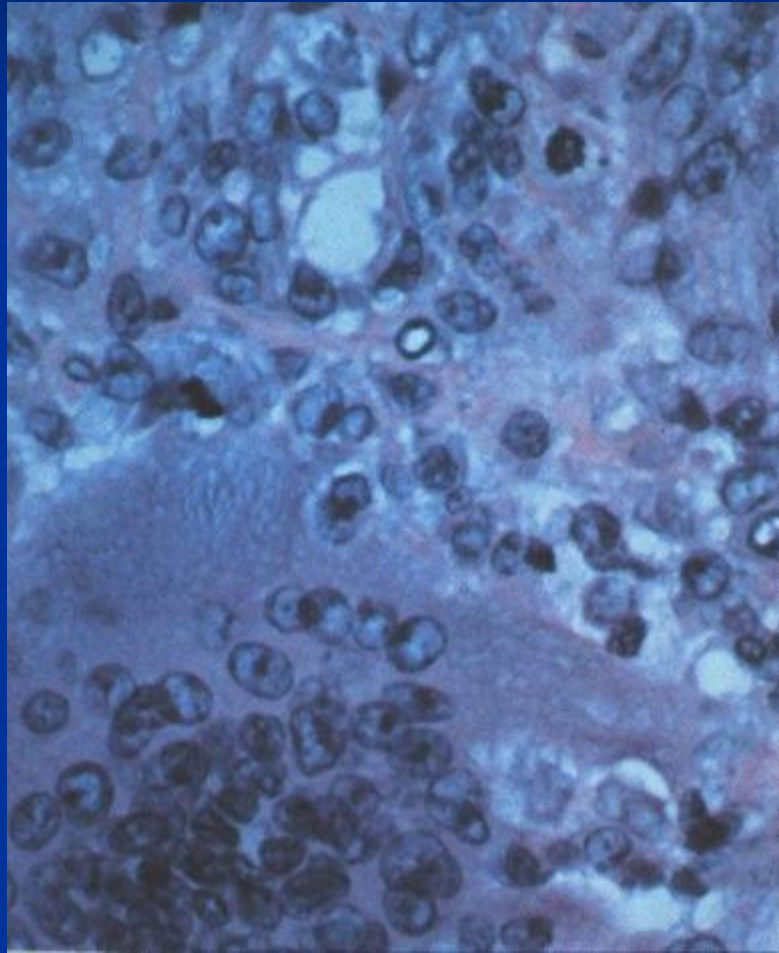


Bone Scan Demonstrates Increased Activity in Neoplasm







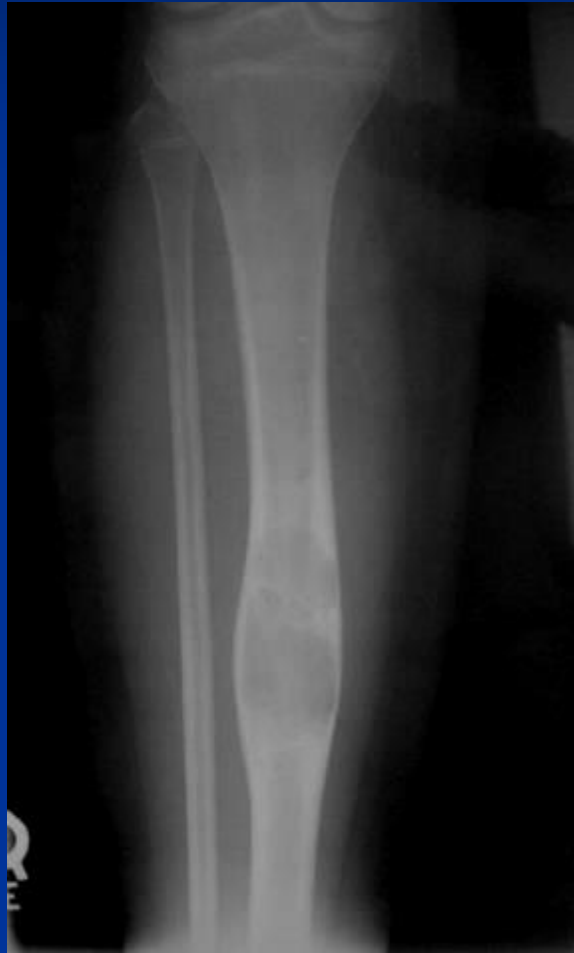

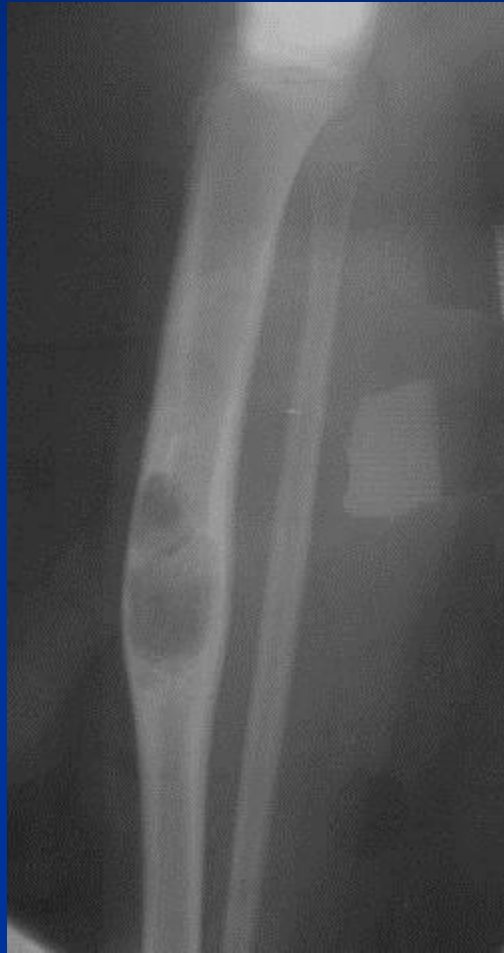*Diagnosis Next

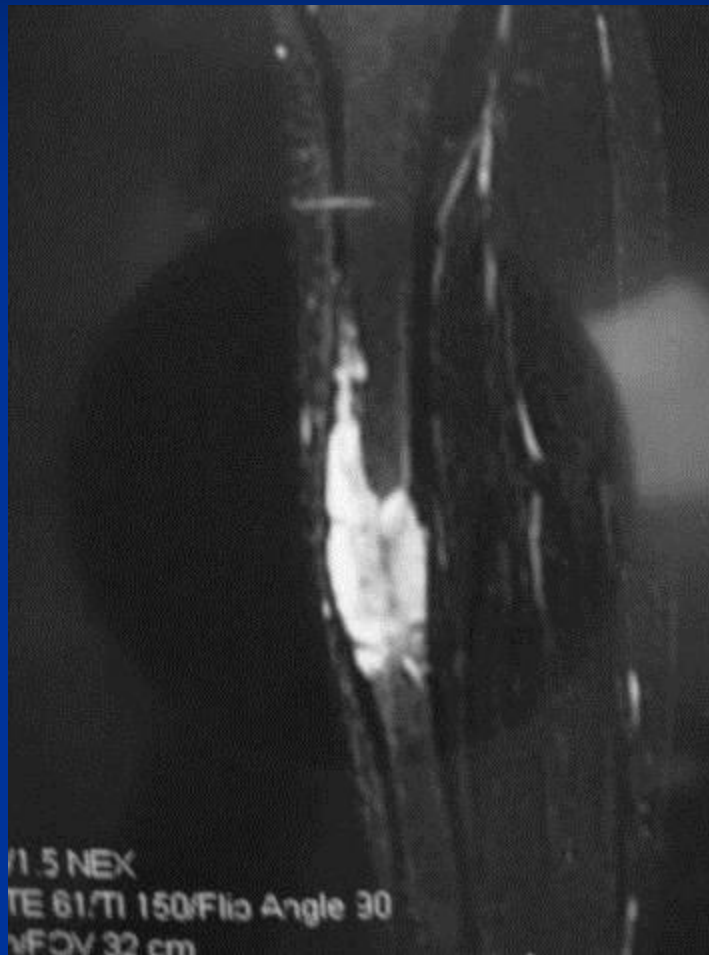GCT of proximal fibula

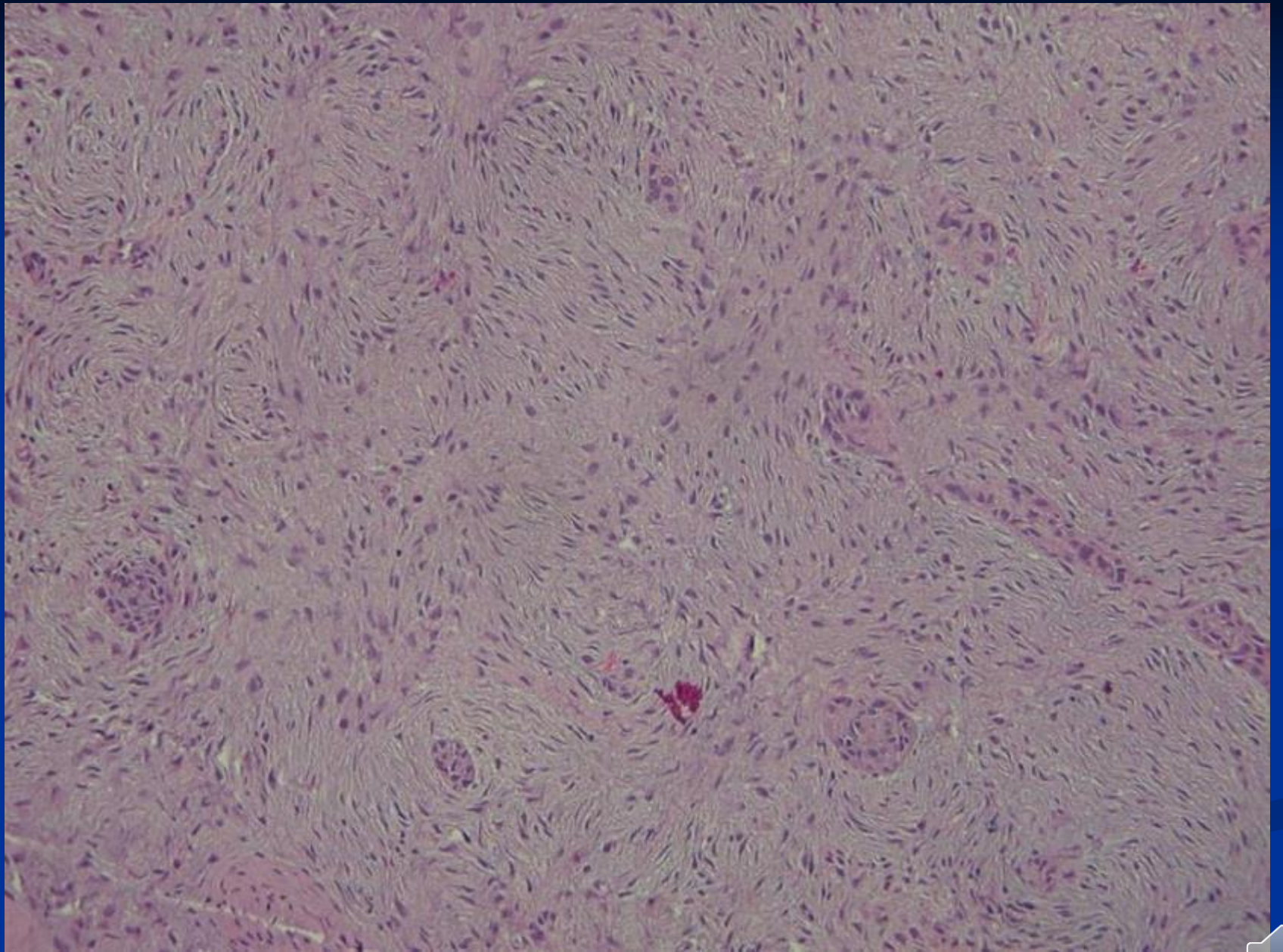
CASE #3

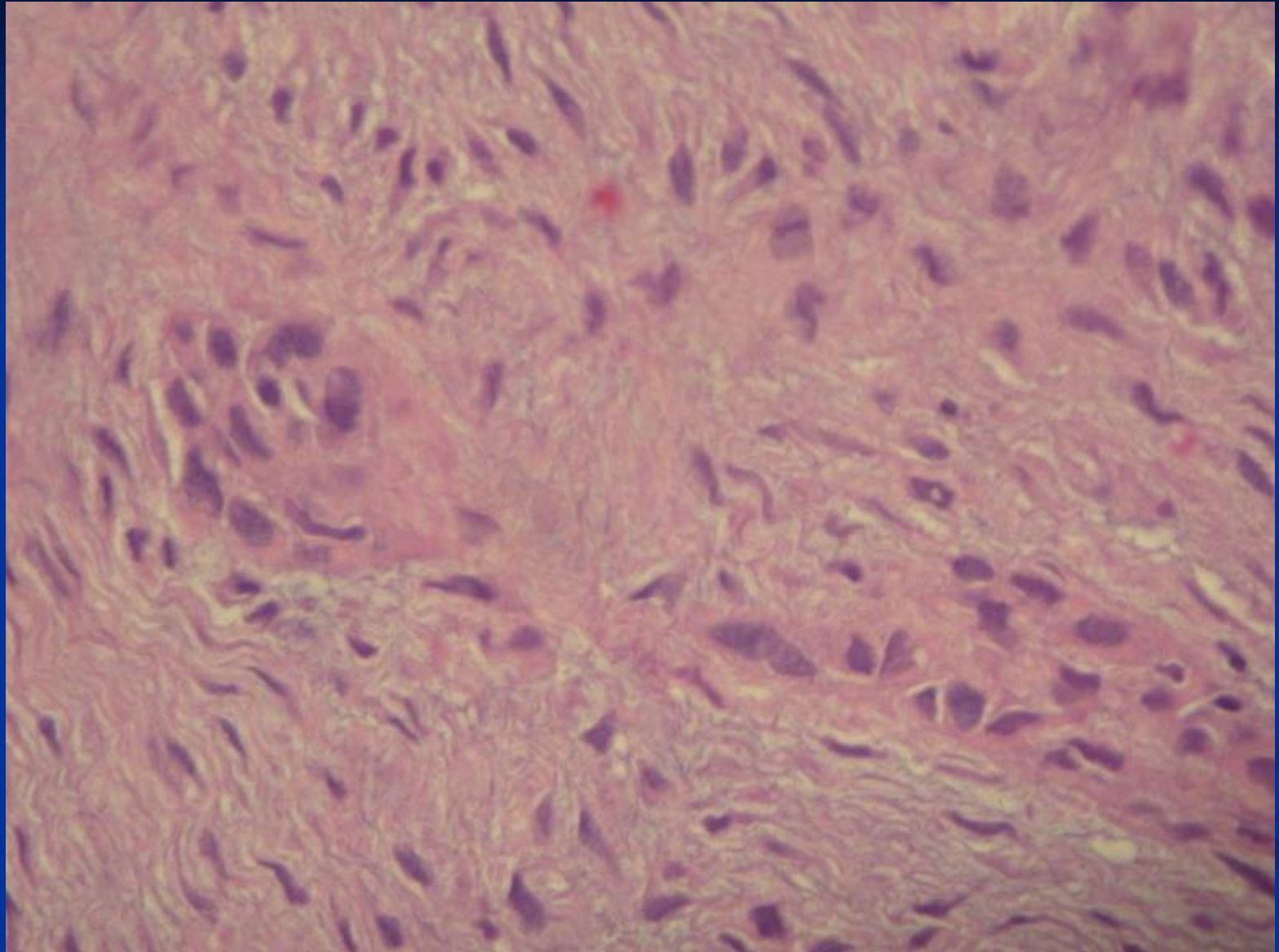
- 15 year old male with pain in right tibia for 6 months. The mother noticed that the child had a bowing deformity of the tibia for many years. X-ray and T-2 weighted MRI are shown. Biopsy sample is shown. The Biopsy sample demonstrated positive staining for keratin.

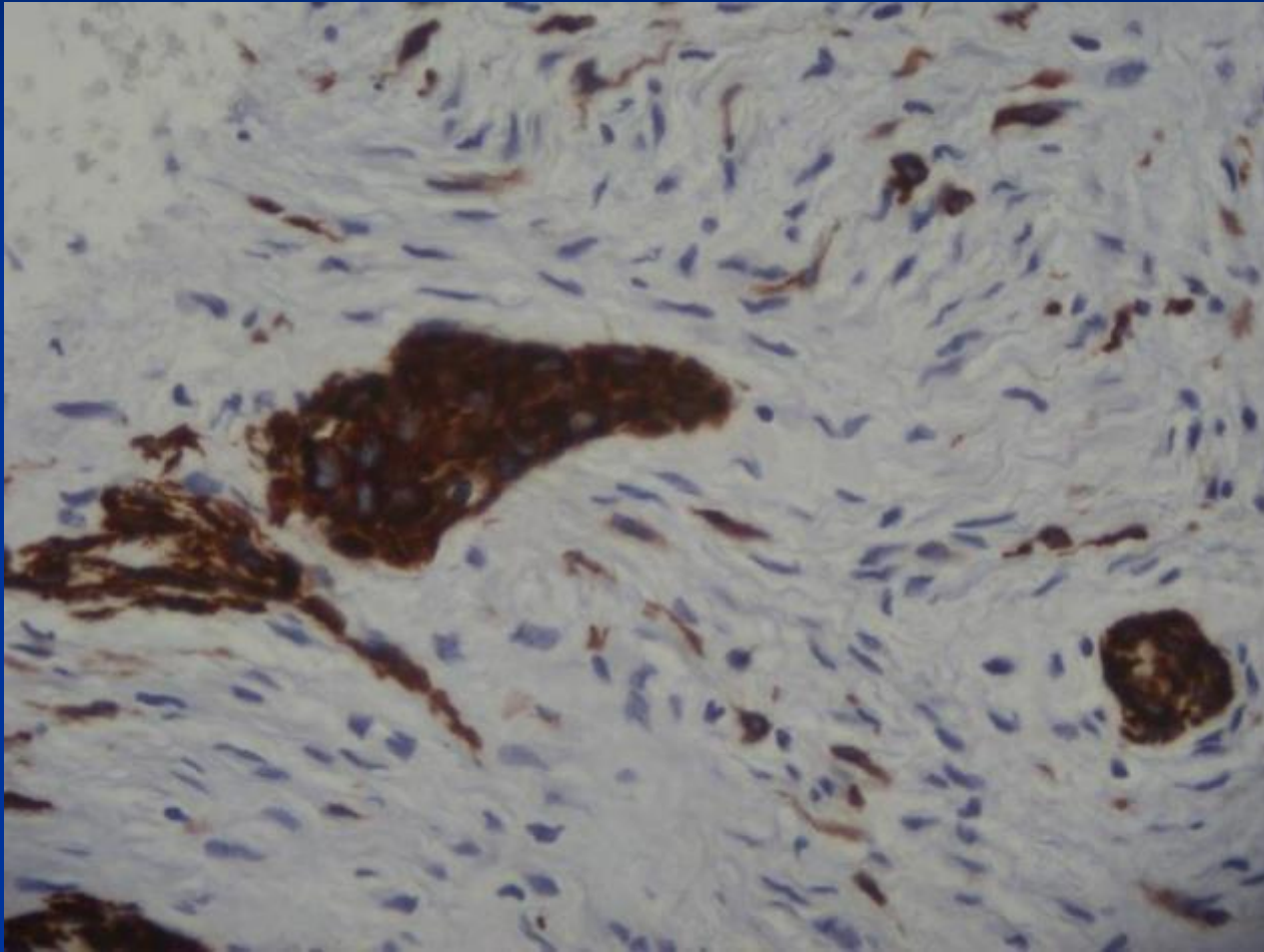










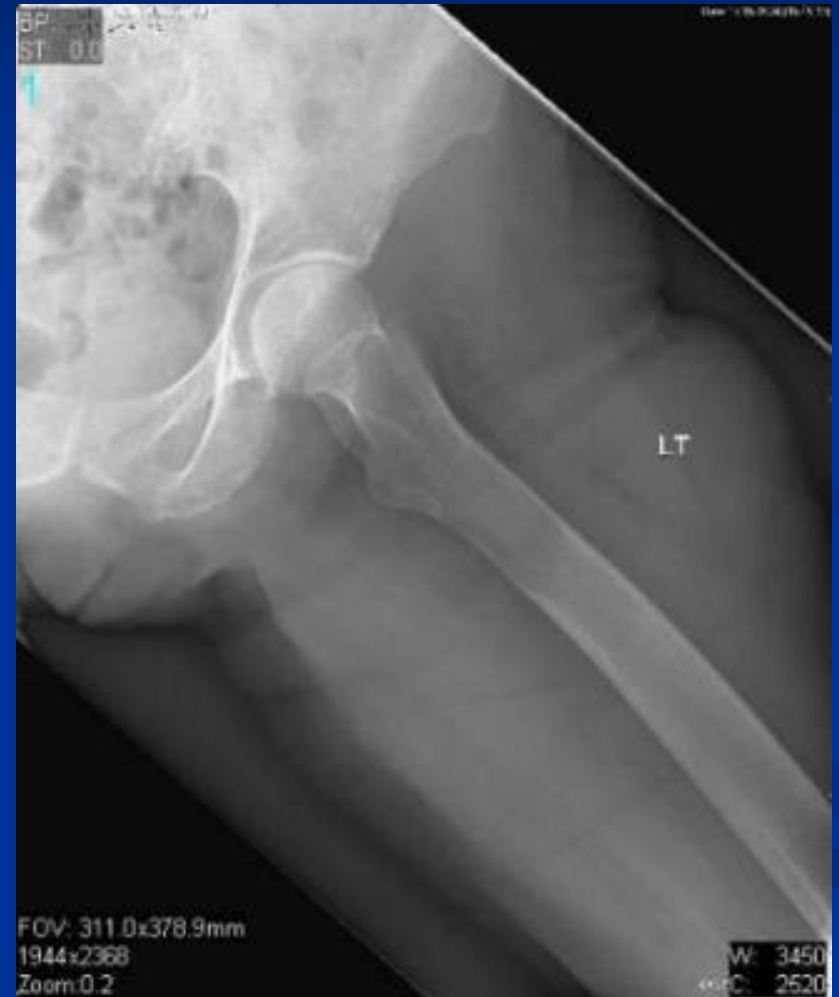

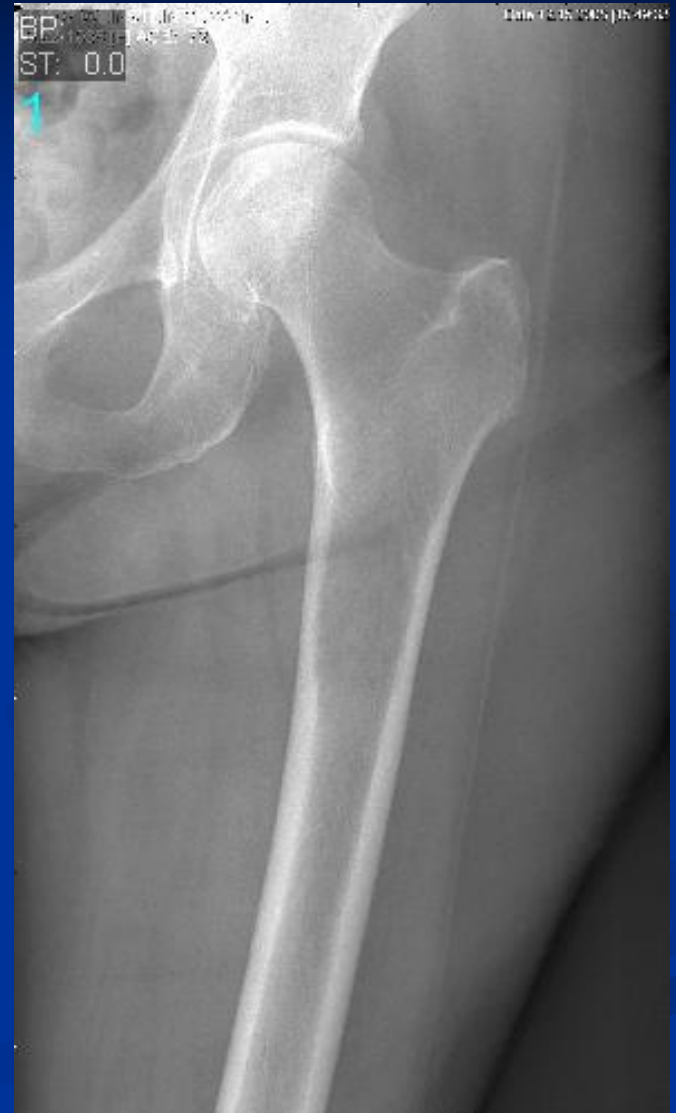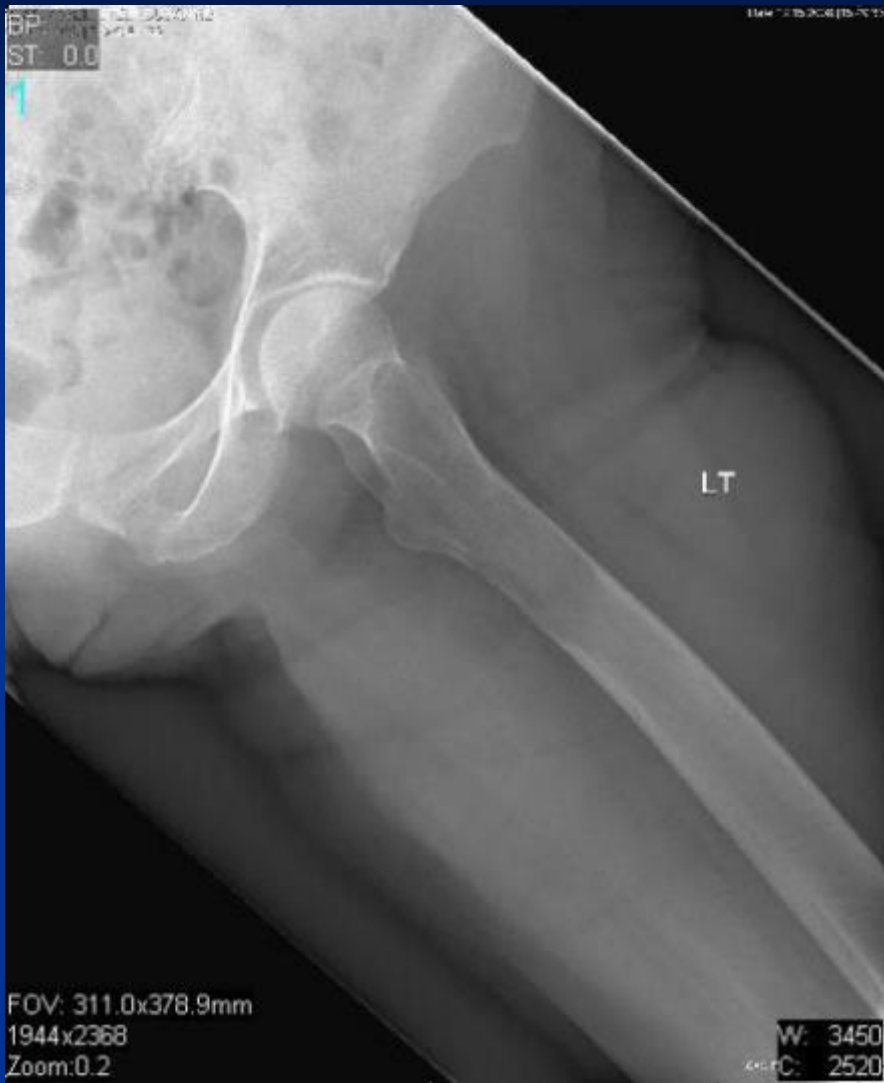*Diagnosis Next

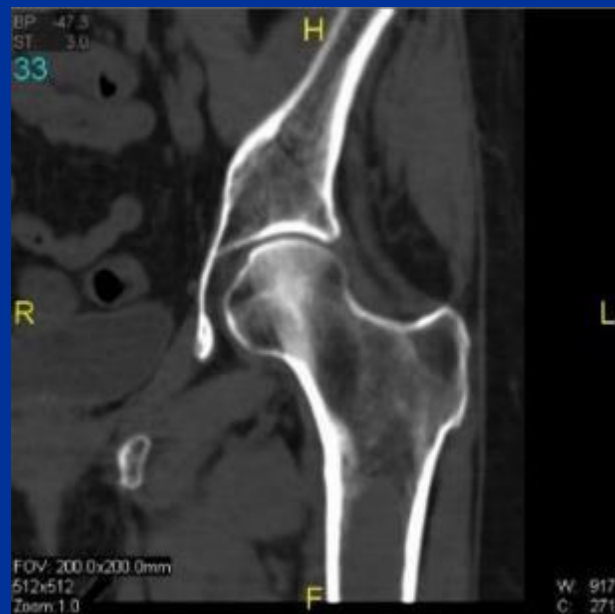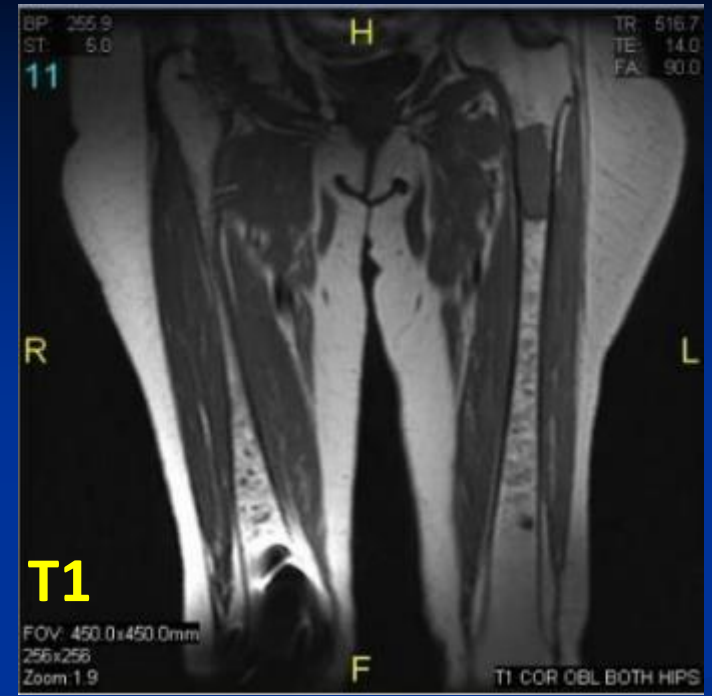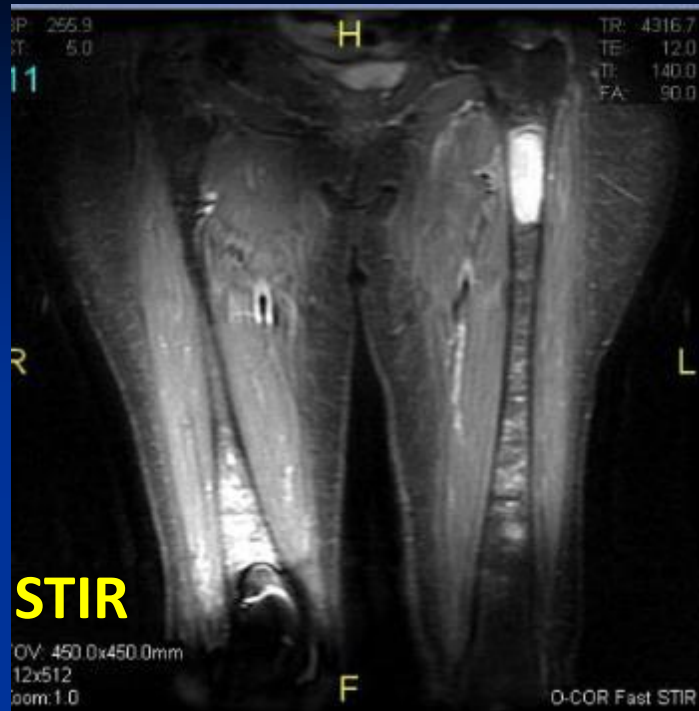Adamantinoma

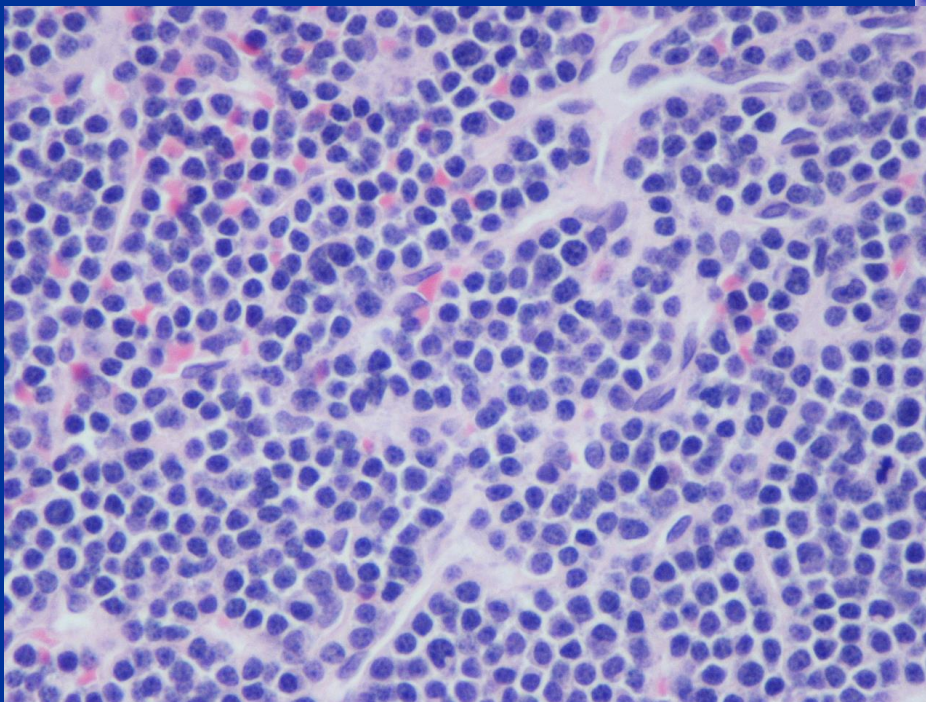
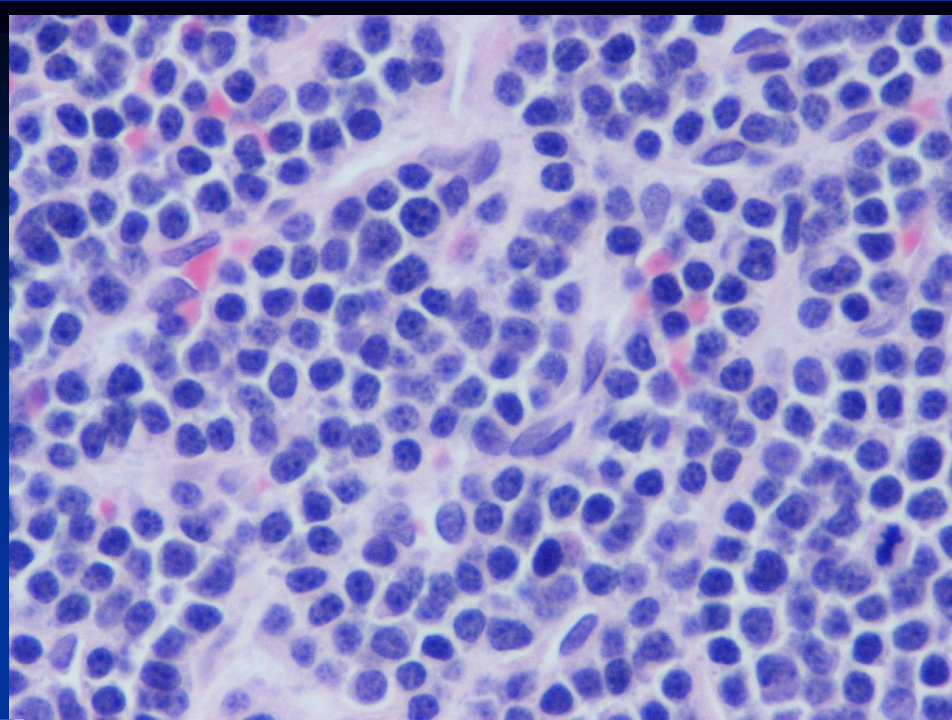
CASE #4

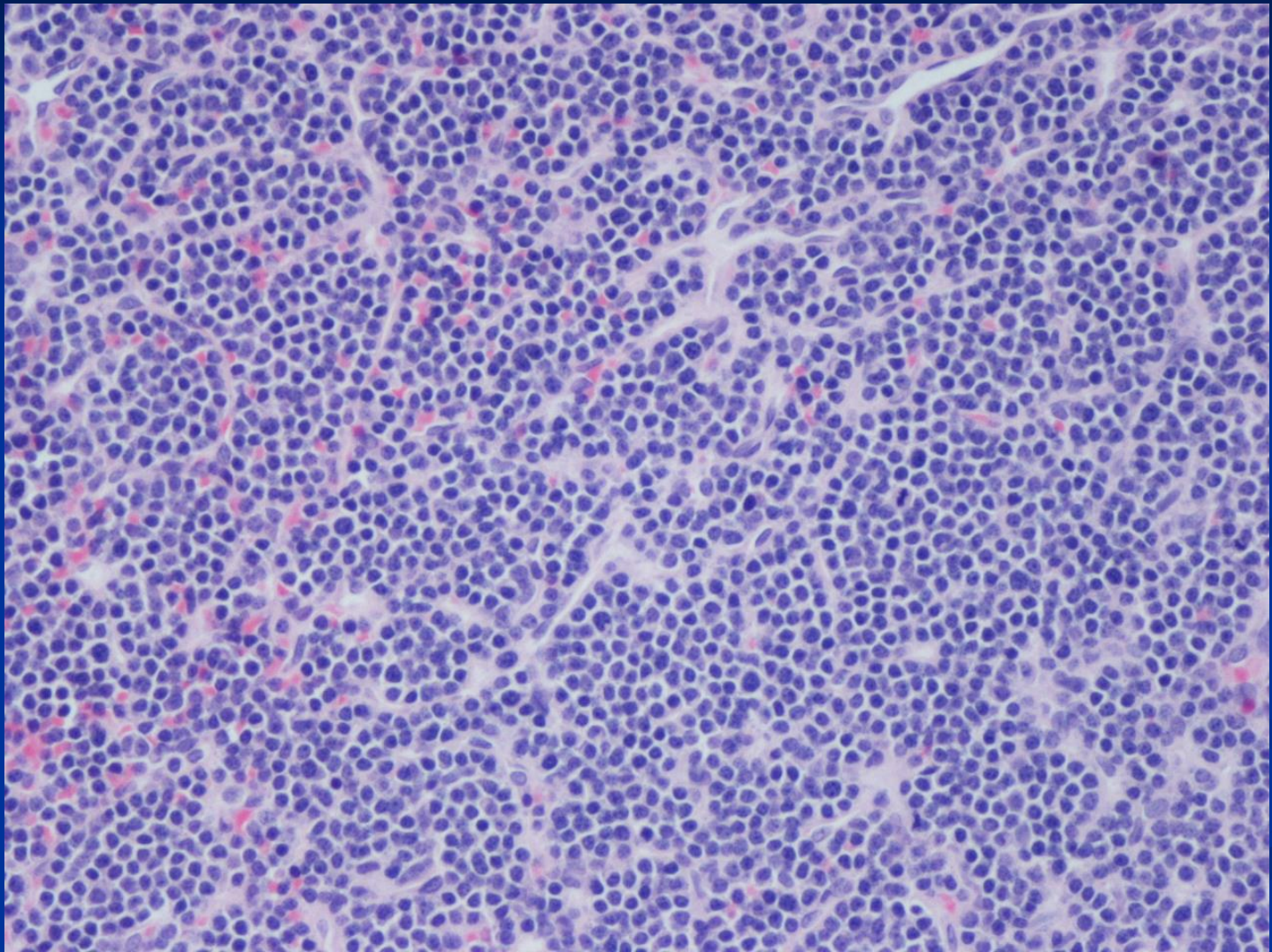
- 63 yo female
- Progressive pain in the left thigh

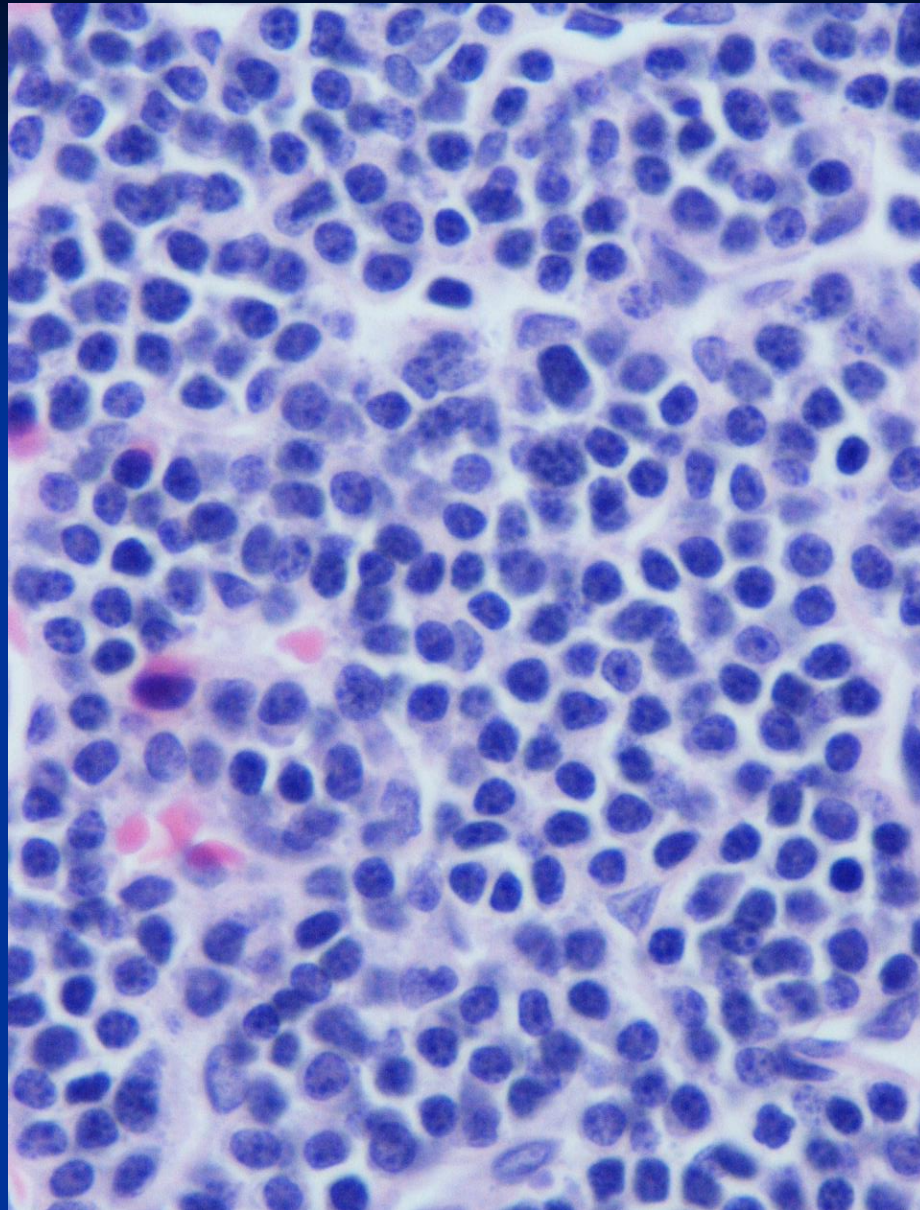












*Diagnosis Next

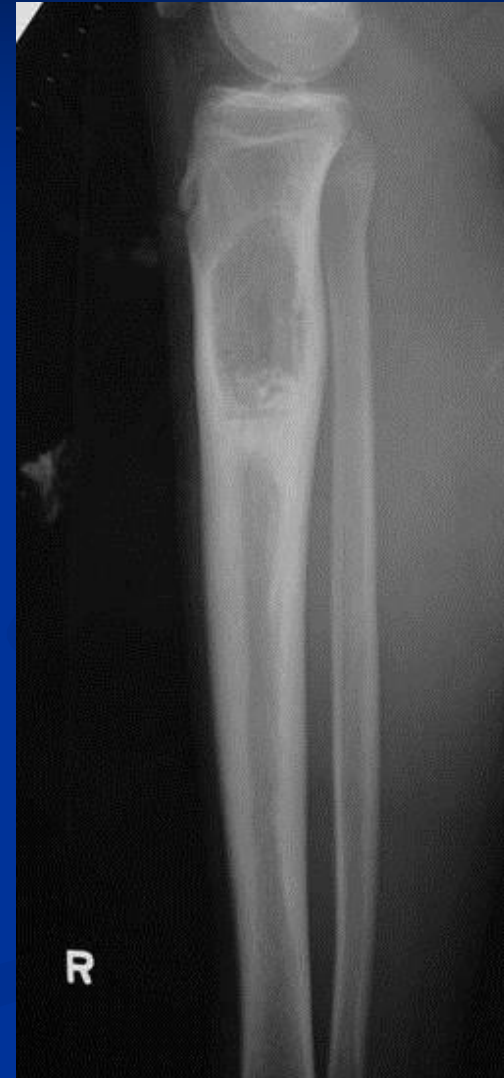
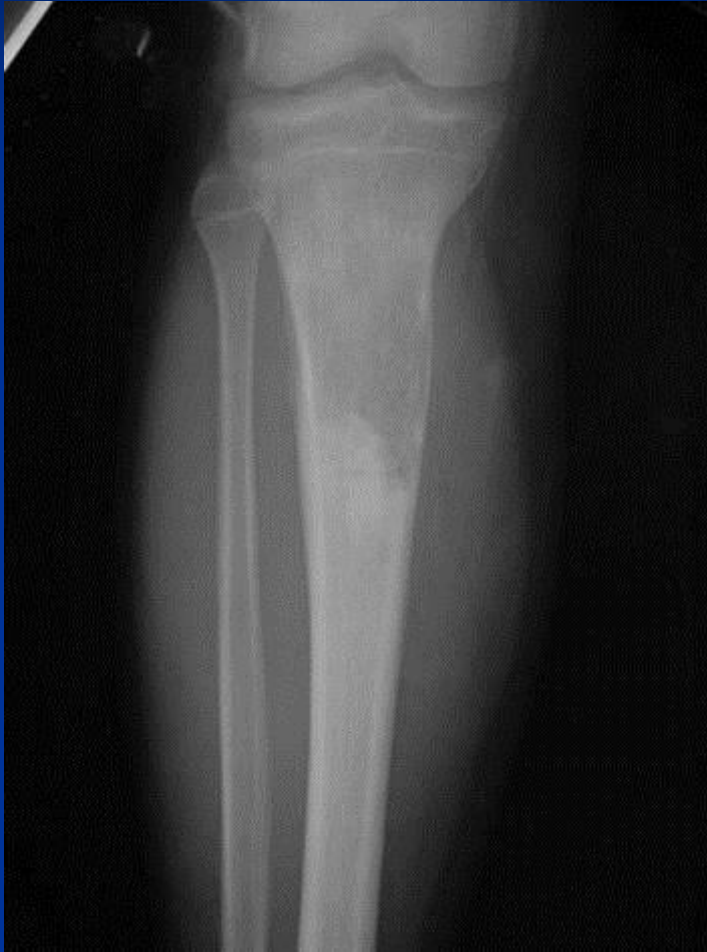
Multiple Myeloma

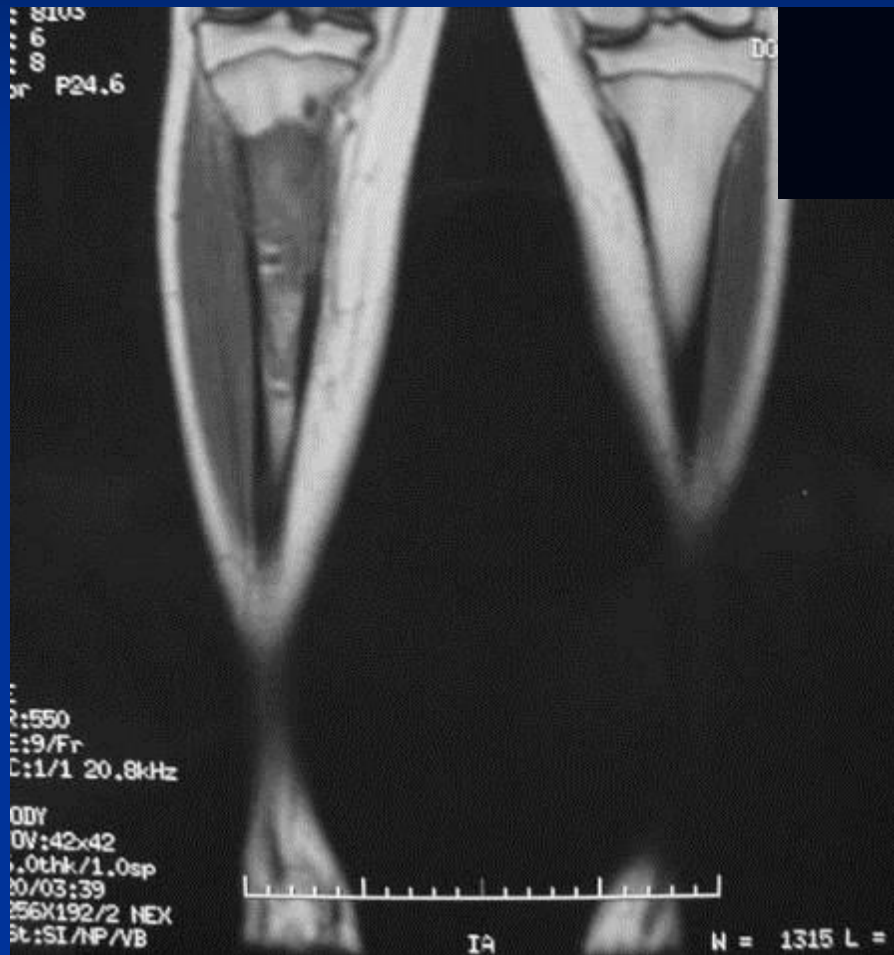CASE #5

- A 14 year old boy presented with 4 months of right knee pain and swelling. The child was an avid basketball player. There was no fever, night sweats or weight loss. His laboratory studies demonstrated an elevated alkaline phosphatase level. His ESR was normal. Workup included Plain radiographs, MRI, CT scan and bone scan. A CT scan of his chest was negative. A biopsy was also performed. The results of his workup are shown on the following slides.

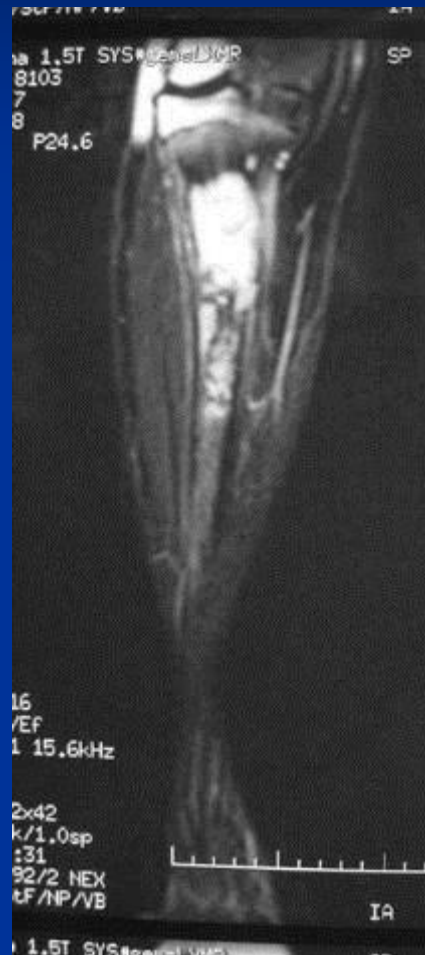X-Ray AP / Lateral



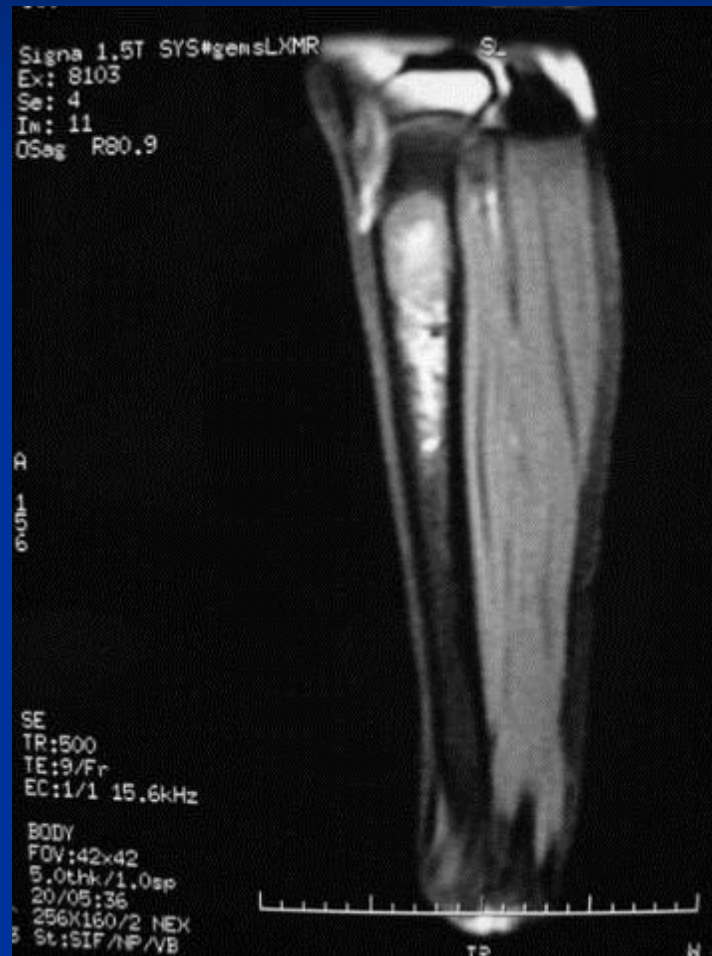T1 Weighted MRI



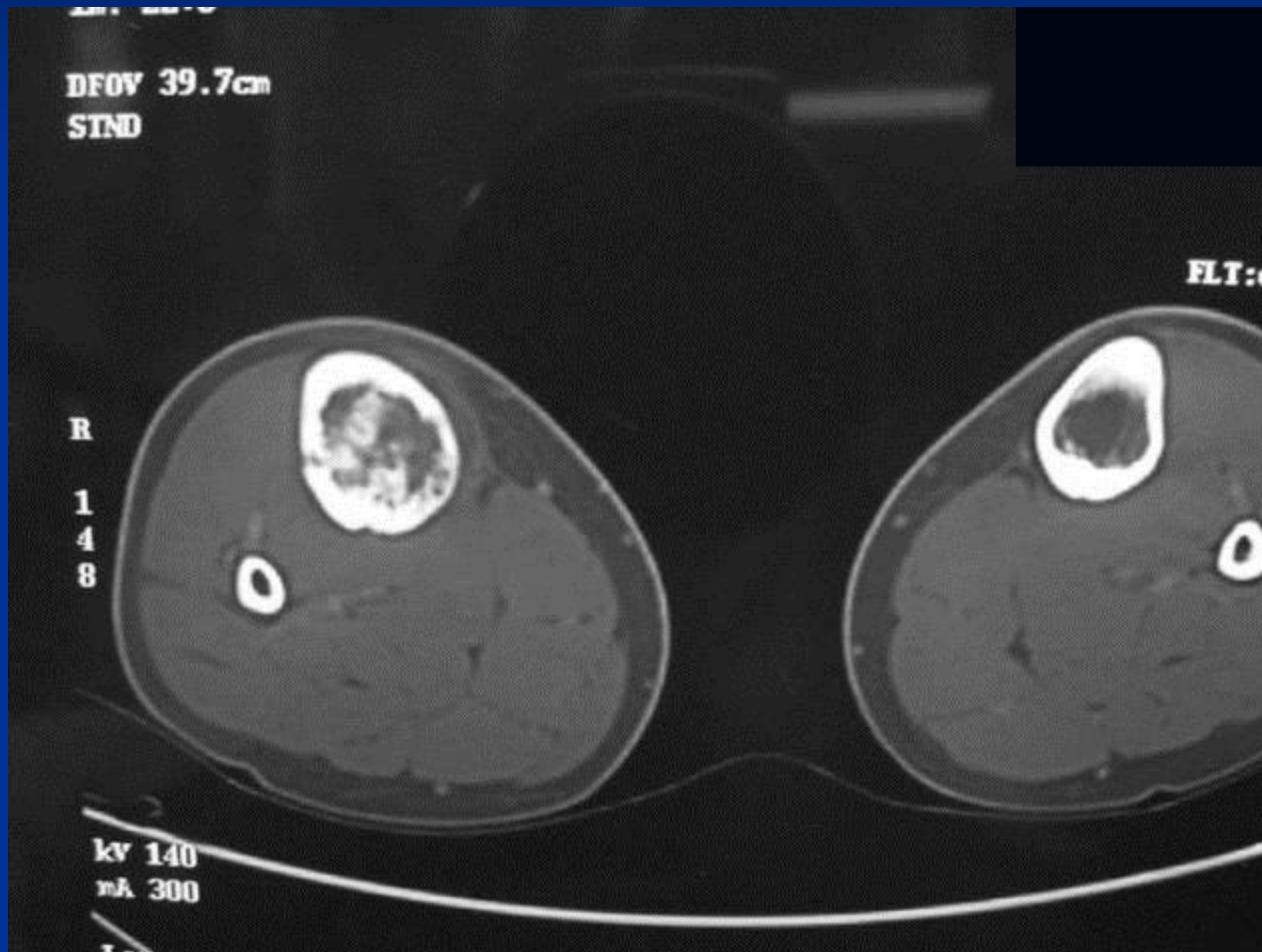
T2 Weighted MRI



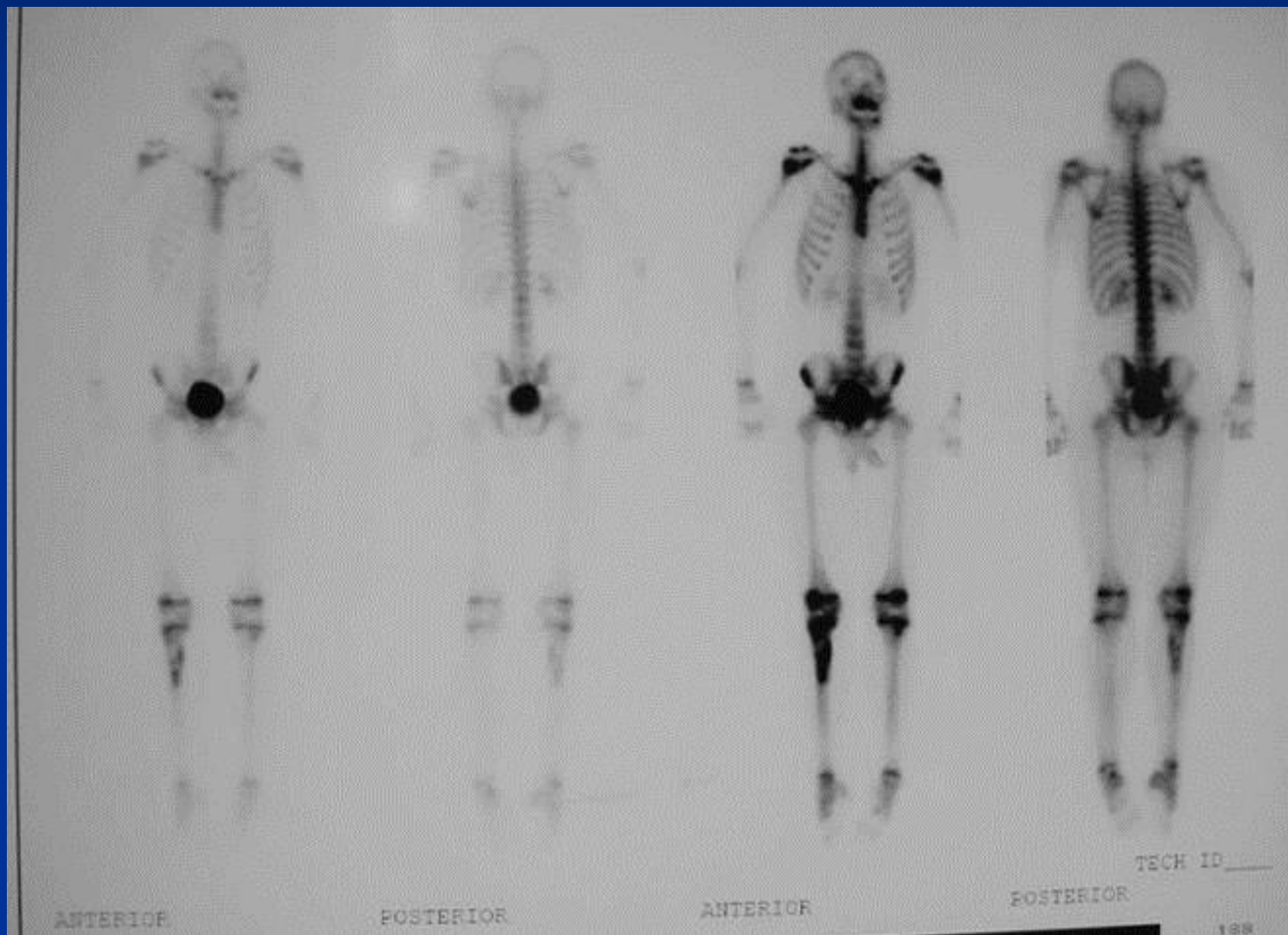T1 Fat Suppressed with Gadolinium

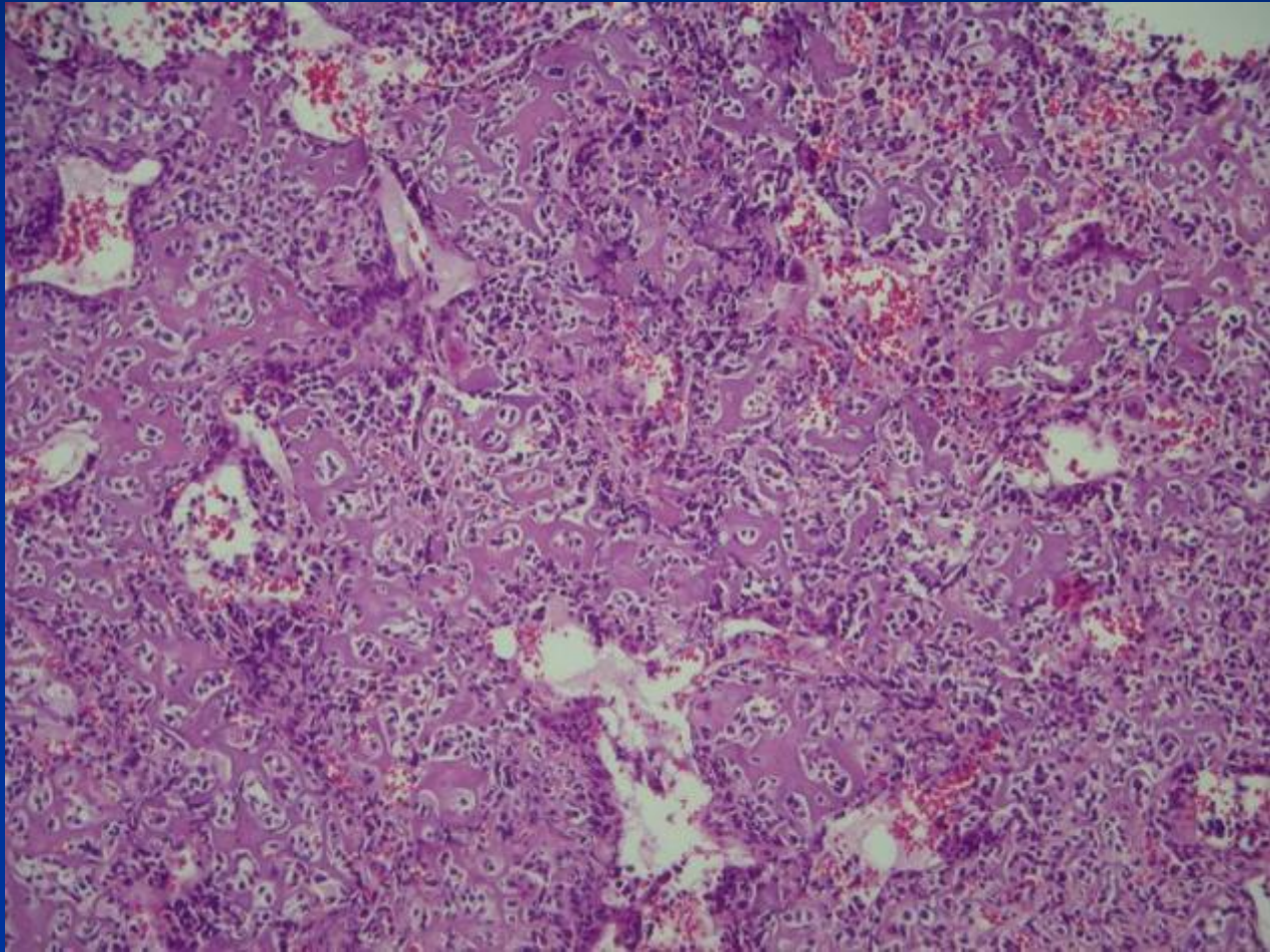


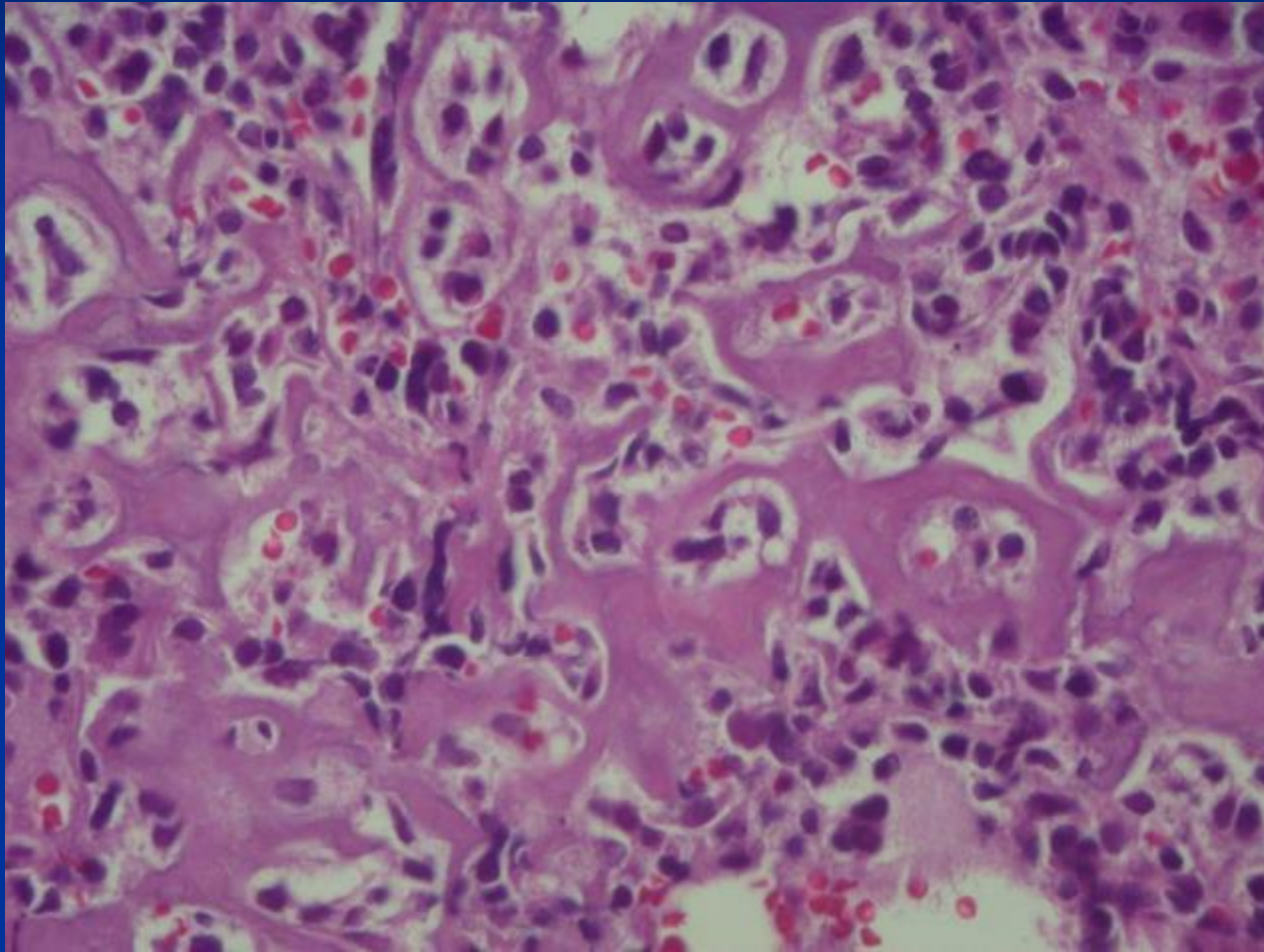
CT Scan



Bone Scan







*Diagnosis Next

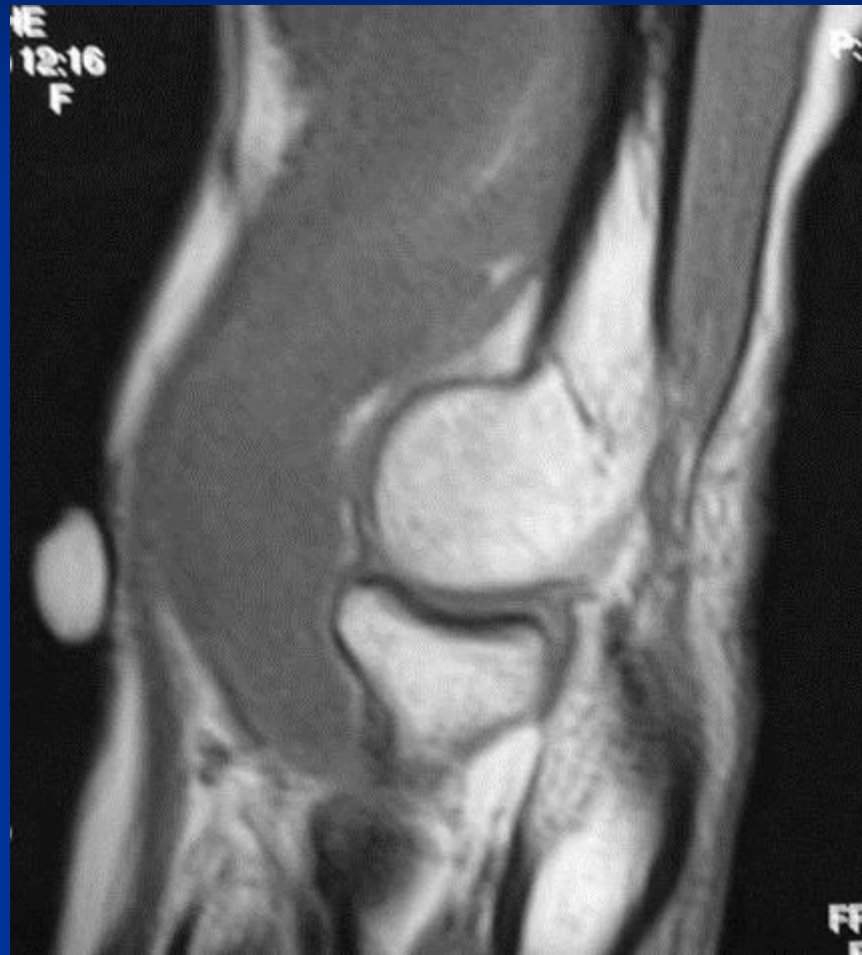

Conventional Intramedullary Osteosarcoma

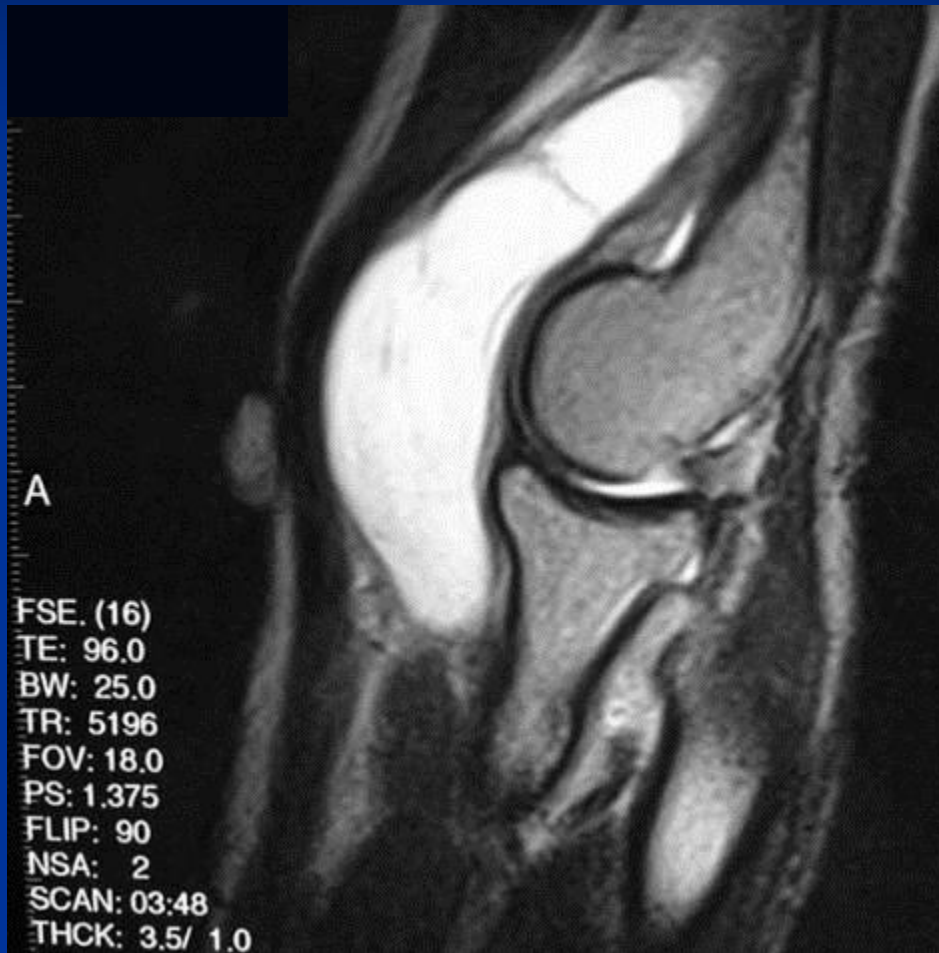CASE #6

50 year old male, left hand dominant, who presented with a mass overlying his left anterior elbow joint. He thought the mass was present for about 1 year and slowly increased in size. There was no pain. His neurological examination of his left upper extremity was normal. There were no lymph nodes palpable in his left axilla. The patient recalled pulling very hard on a doorknob about 1 year ago and he felt a slight pain in the elbow that went away after 1 week. The mass then began to grow.

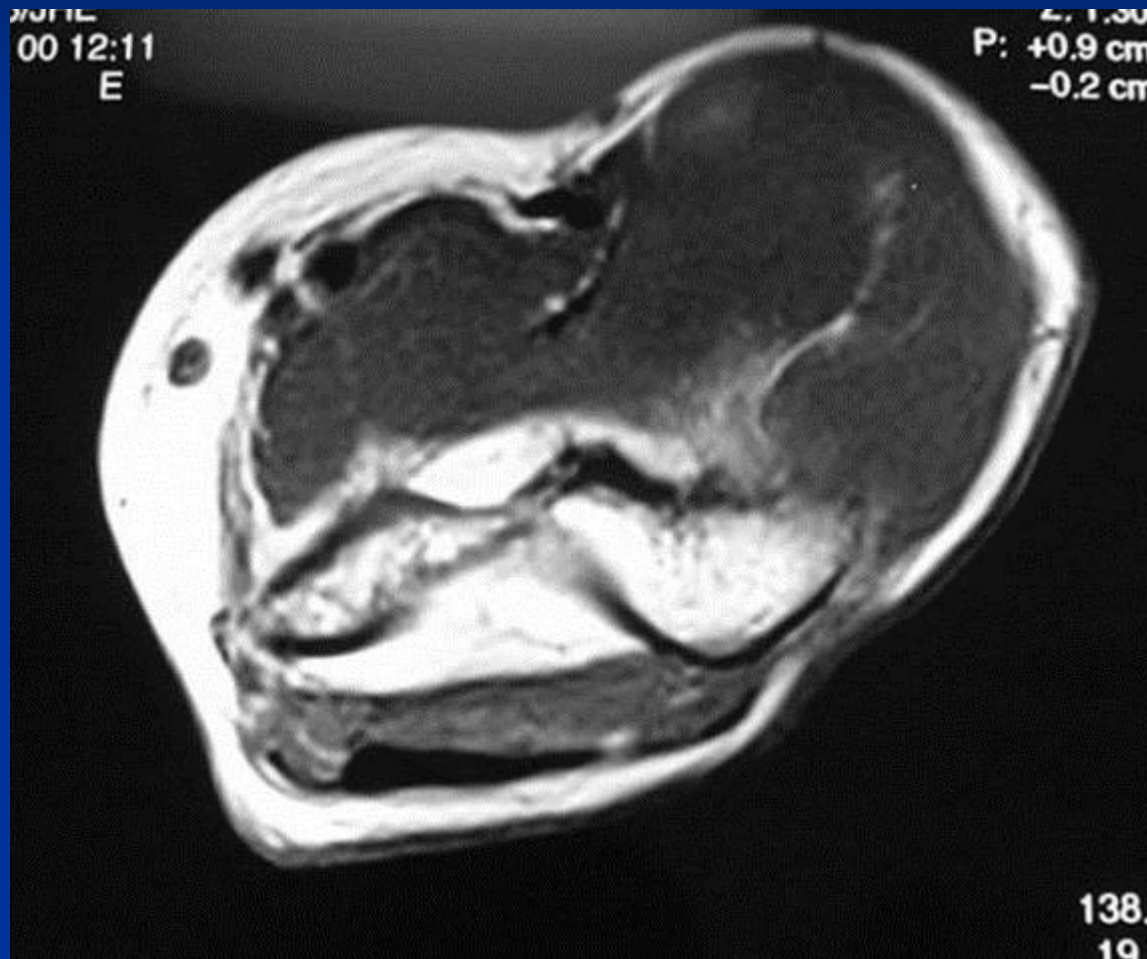T1 Sagittal MRI



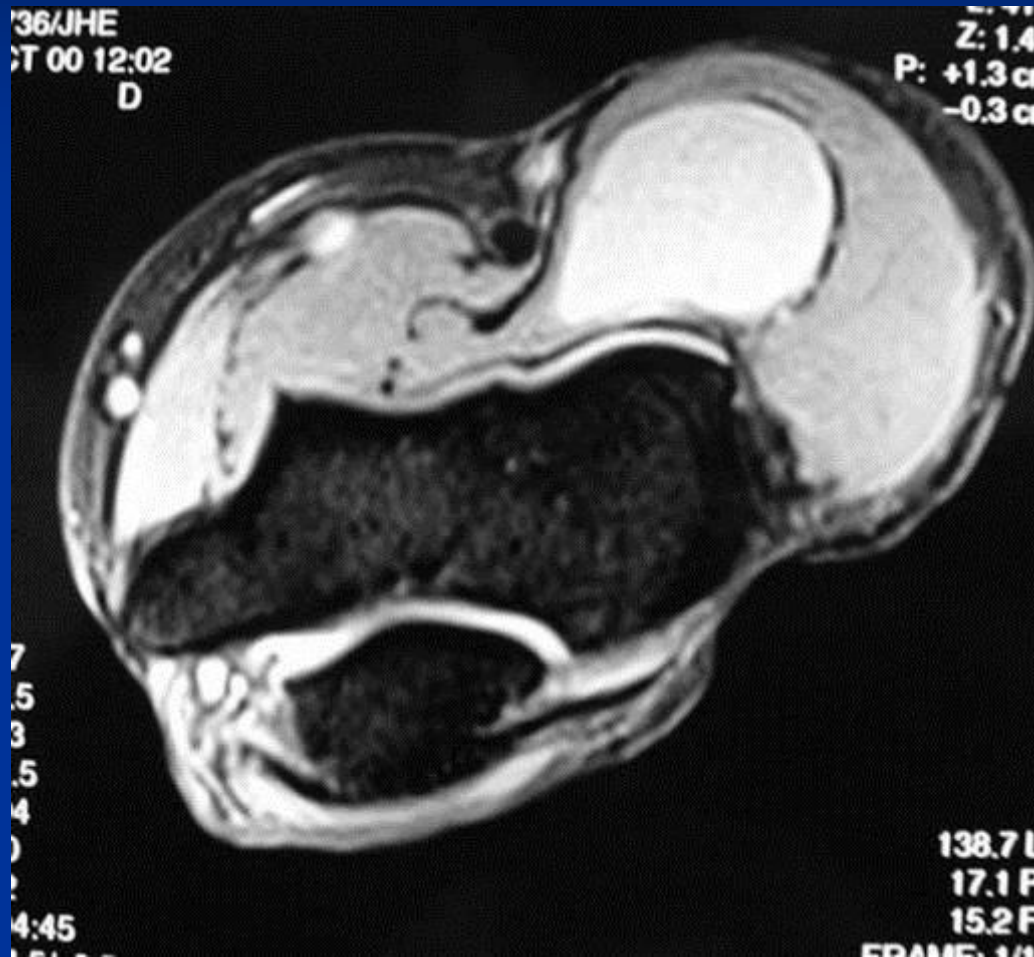T2 MRI



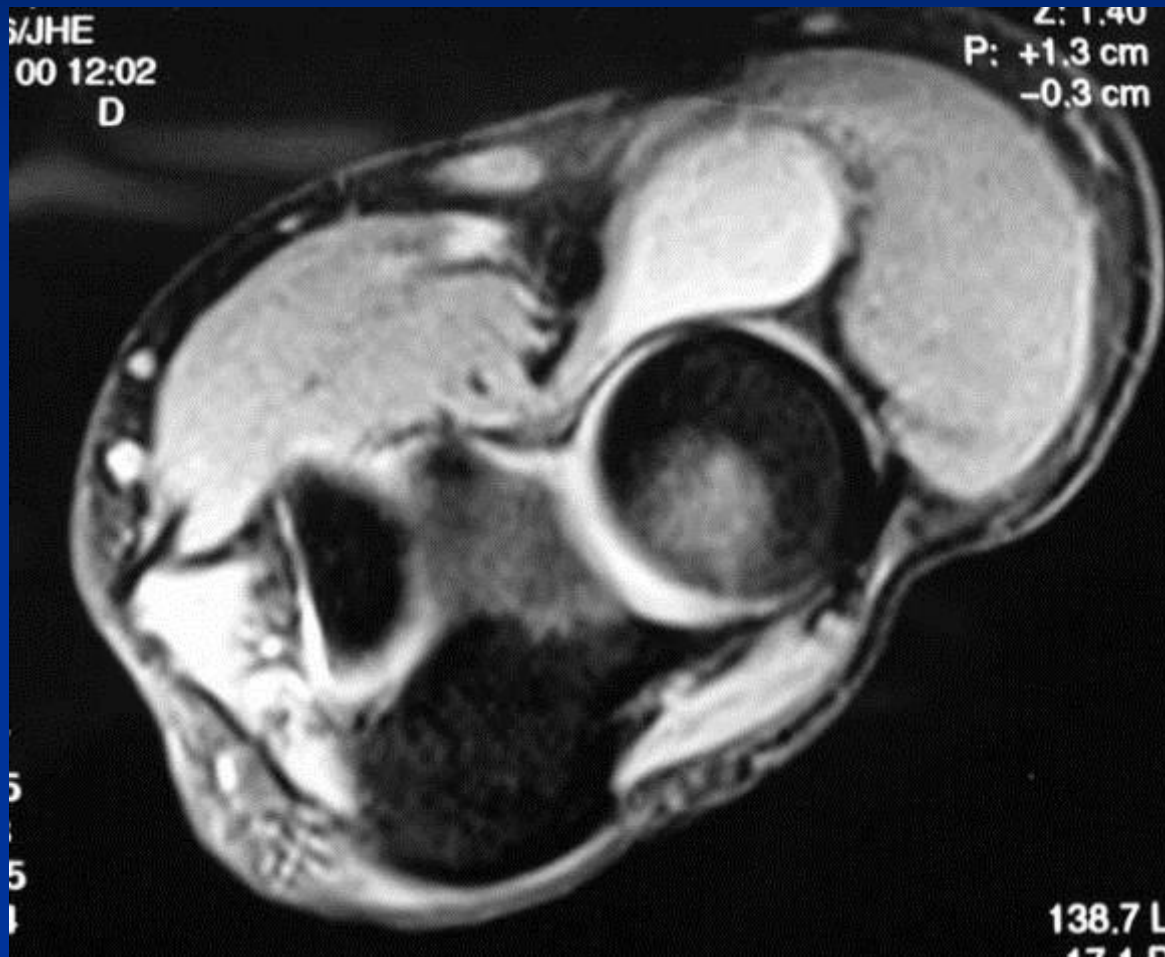T1 Axial MRI



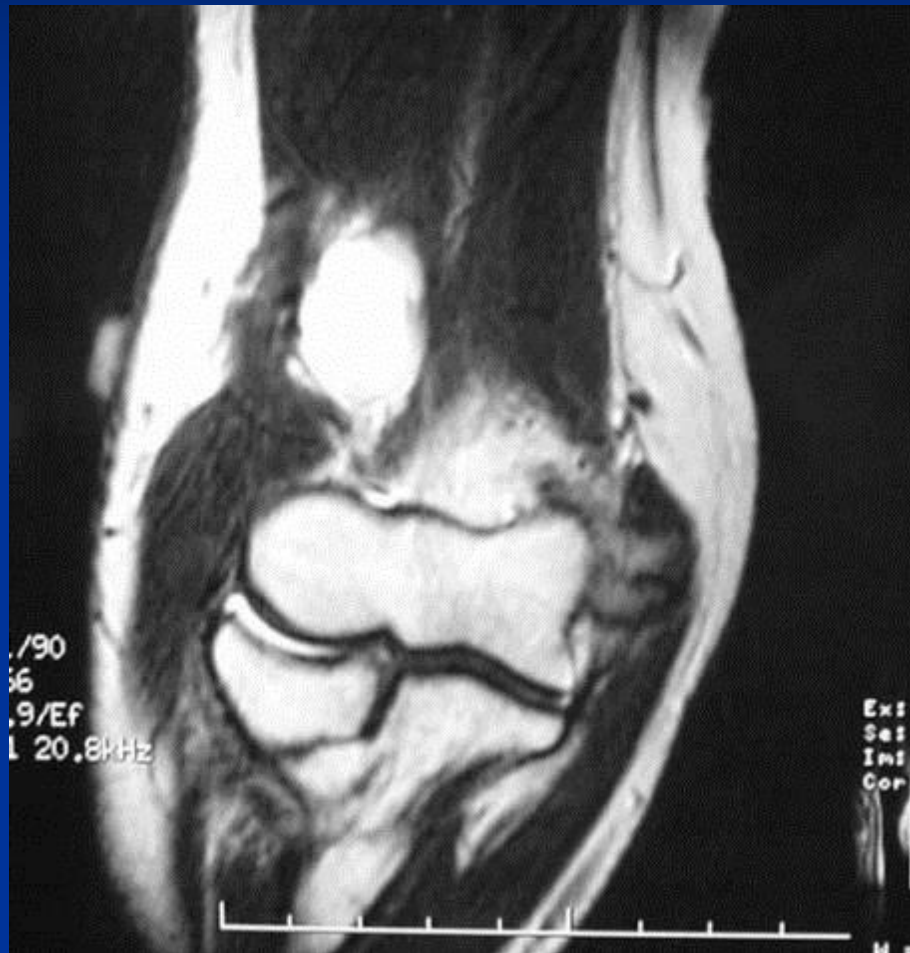
T2 Axial MRI

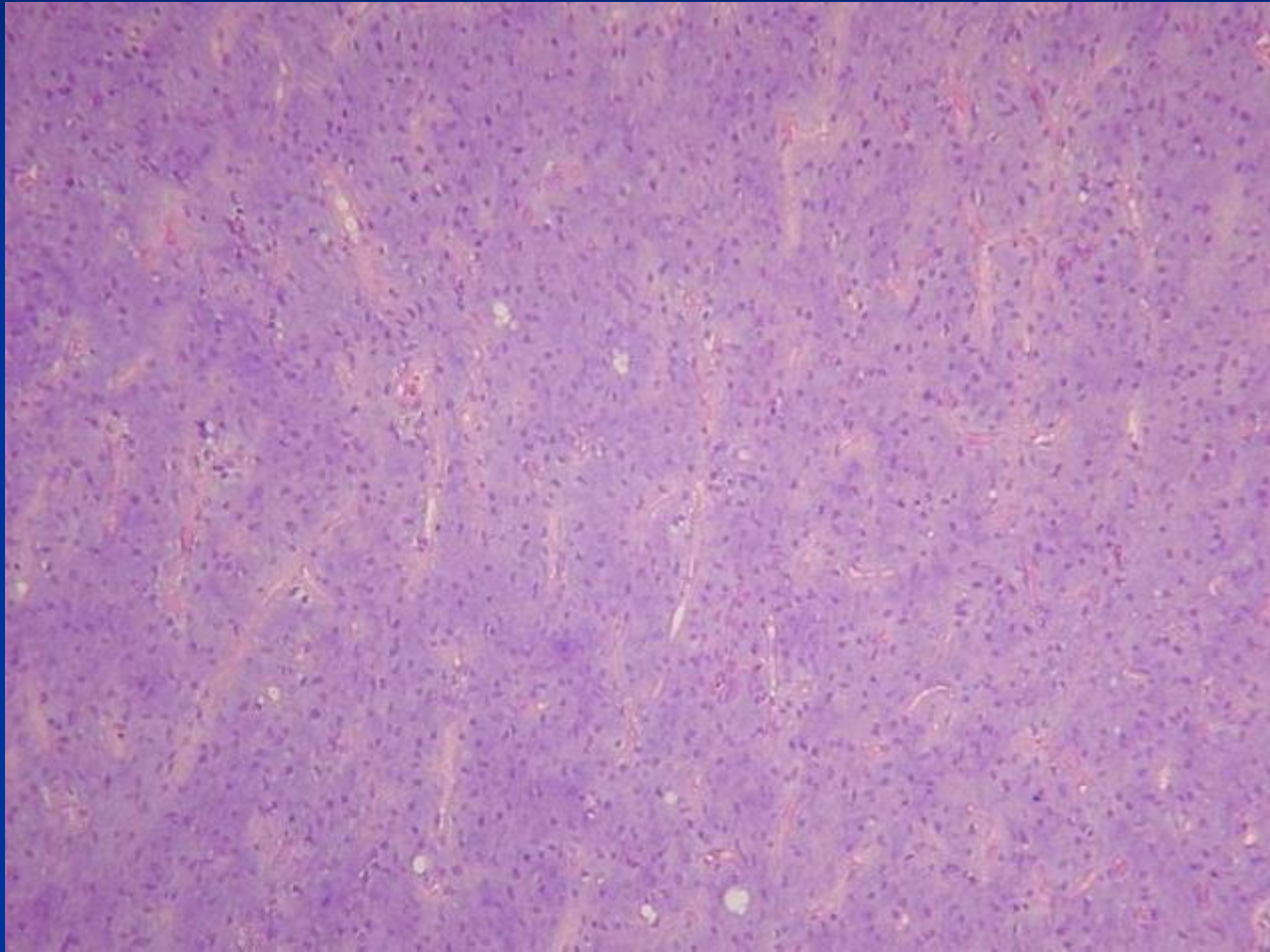


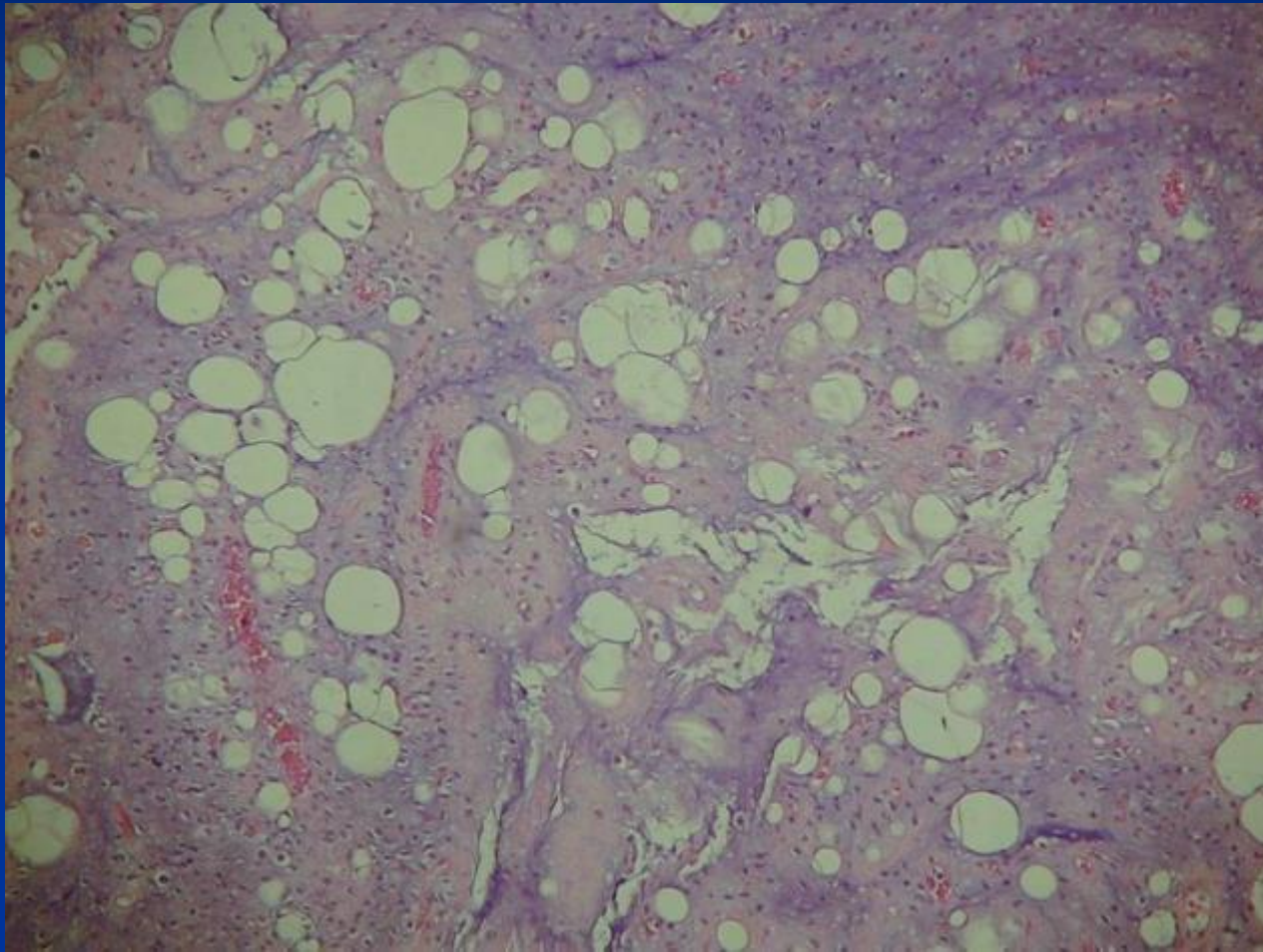
T2 Axial MRI

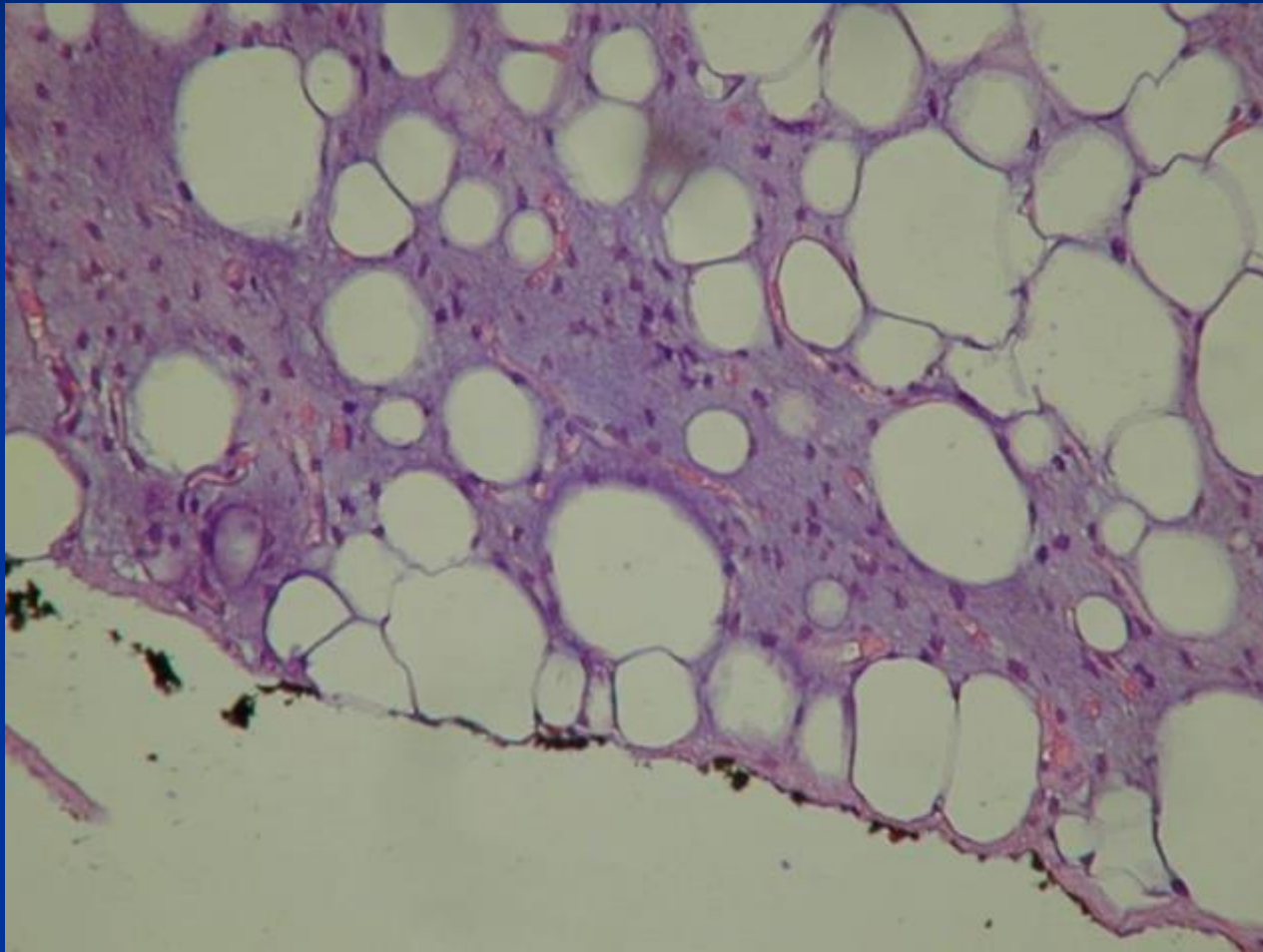


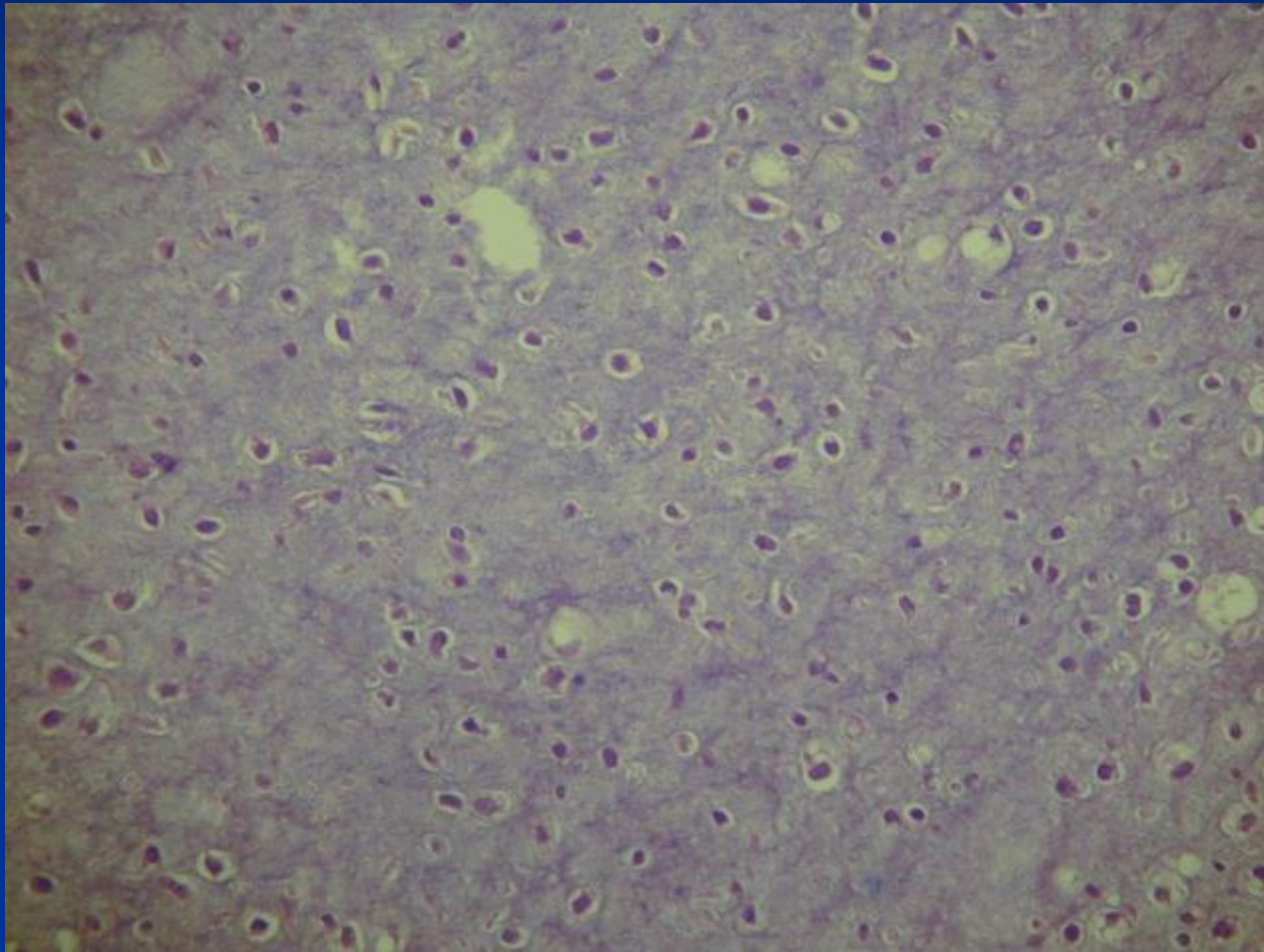
T2 Coronal MRI

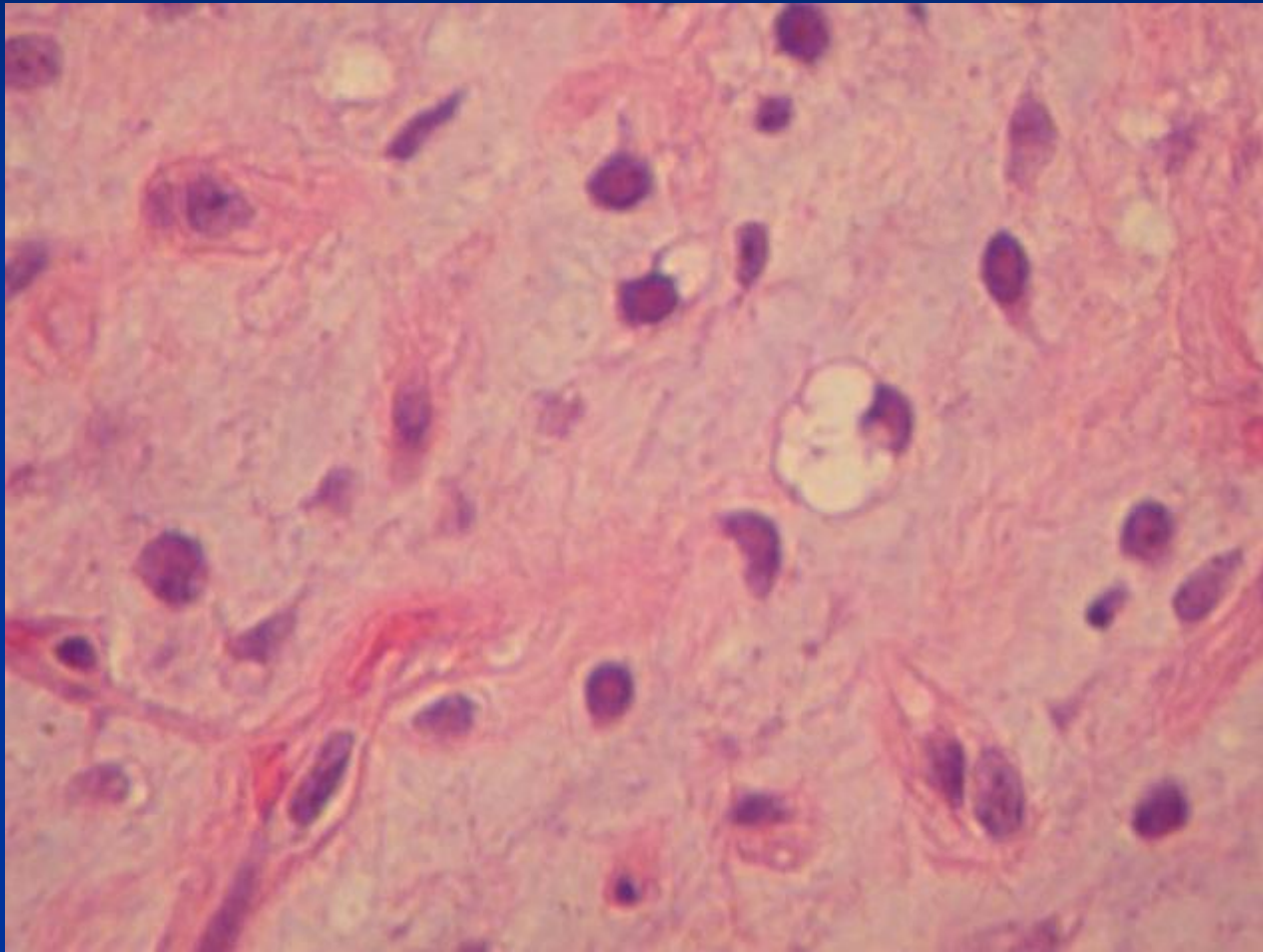












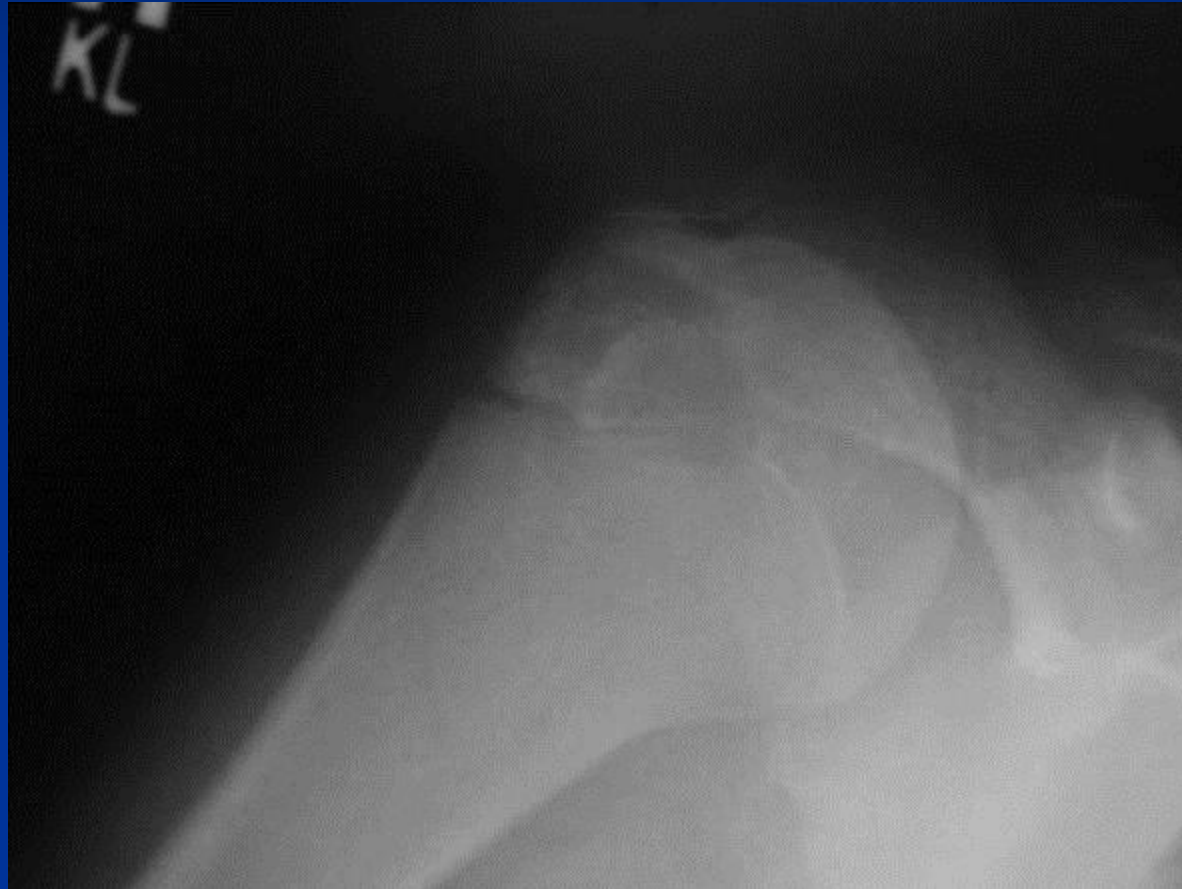*Diagnosis Next

Myxoid Liposarcoma

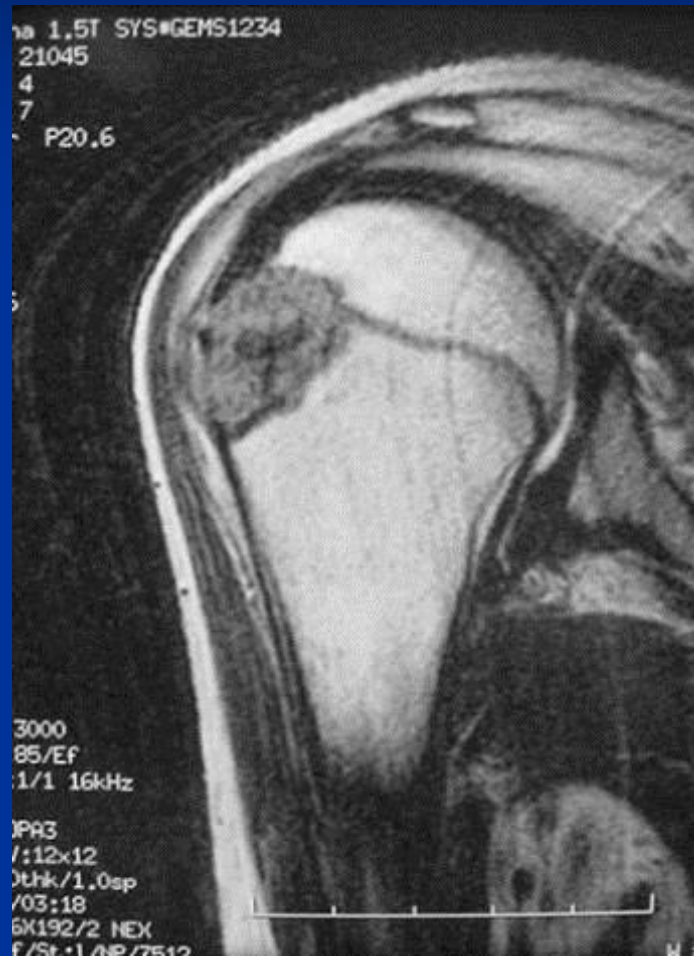CASE #7

- This is a 14 year old female basketball player who presented with 3 months of pain in her right shoulder. The pain initially started as a dull ache and progressively worsened. Over the past 3 weeks there has been swelling in the shoulder. There have been no fevers. The patient reported slight relief of the pain after taking ibuprofen. On physical examination the right shoulder demonstrated mild swelling and mild restriction in range of motion.

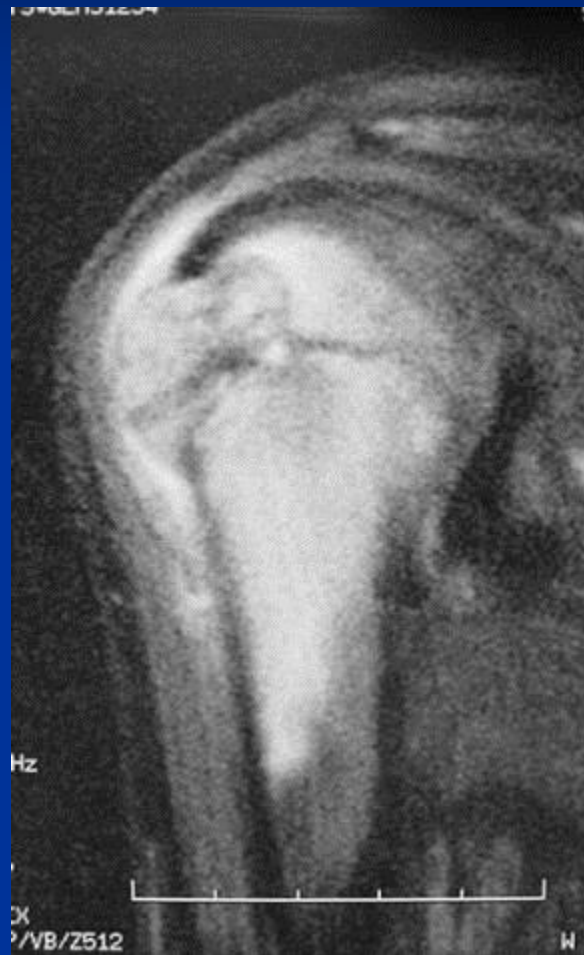Plain Radiograph



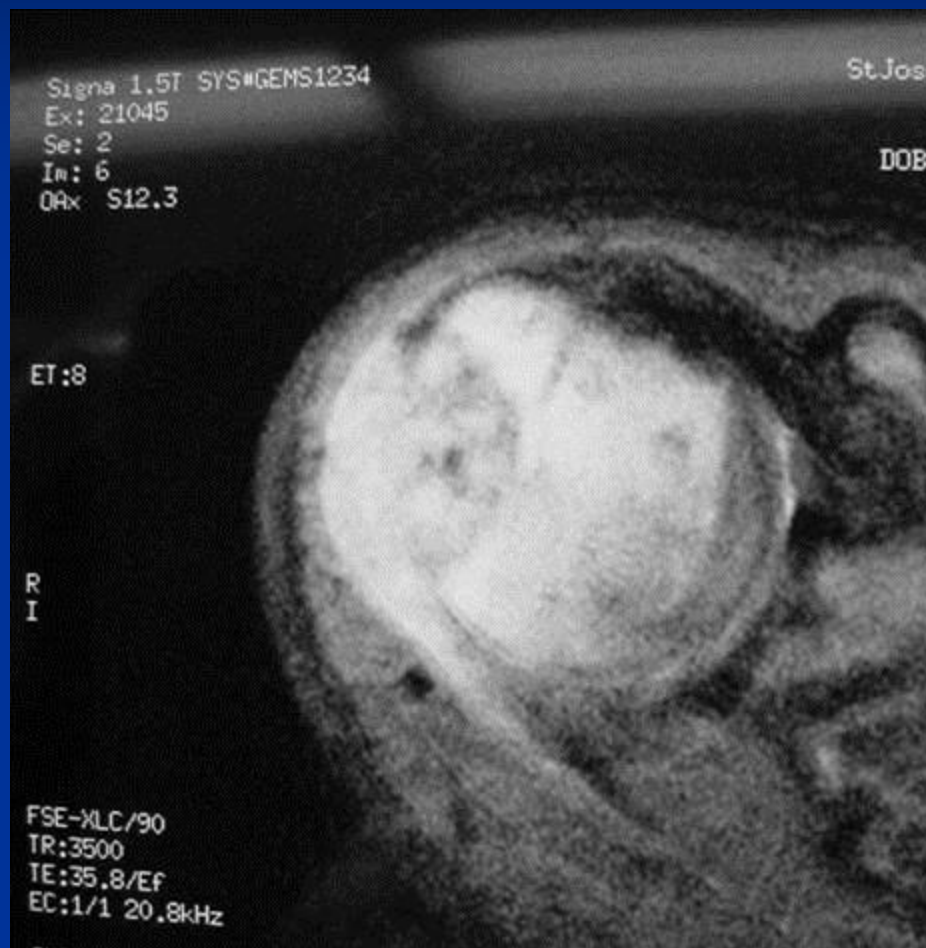
MRI T1 Weighted Coronal



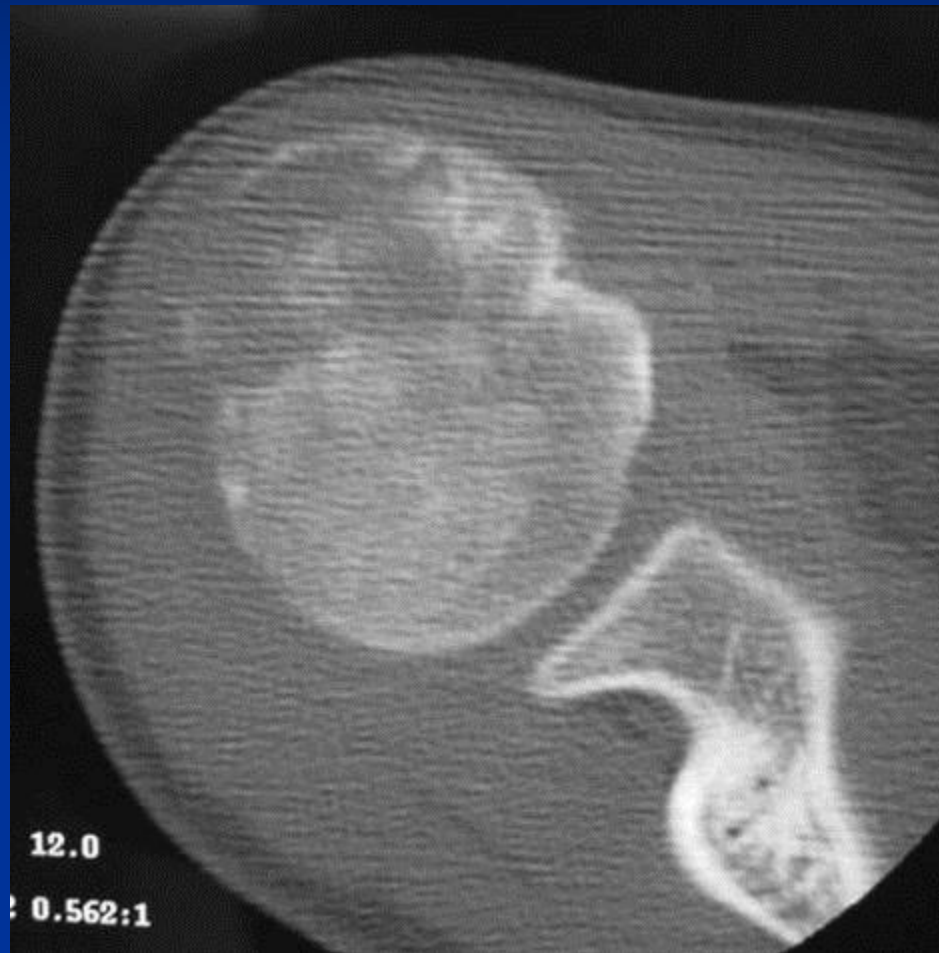
MRI T2 Weighted Coronal



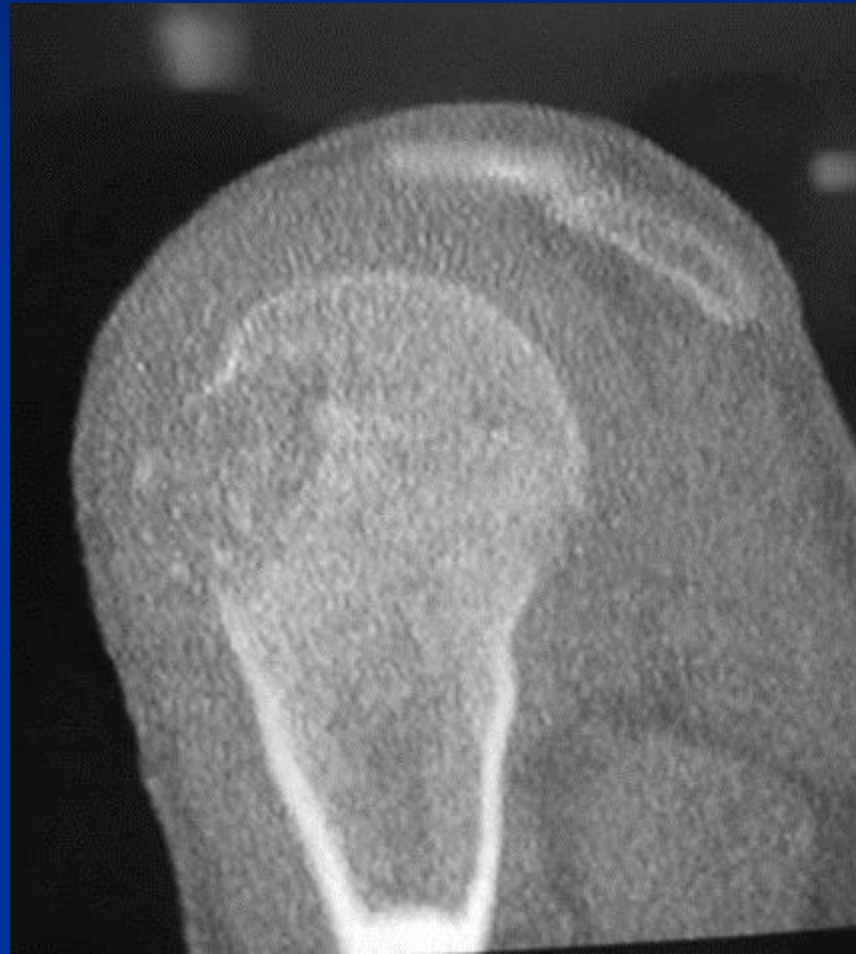MRI T2 Weighted Axial



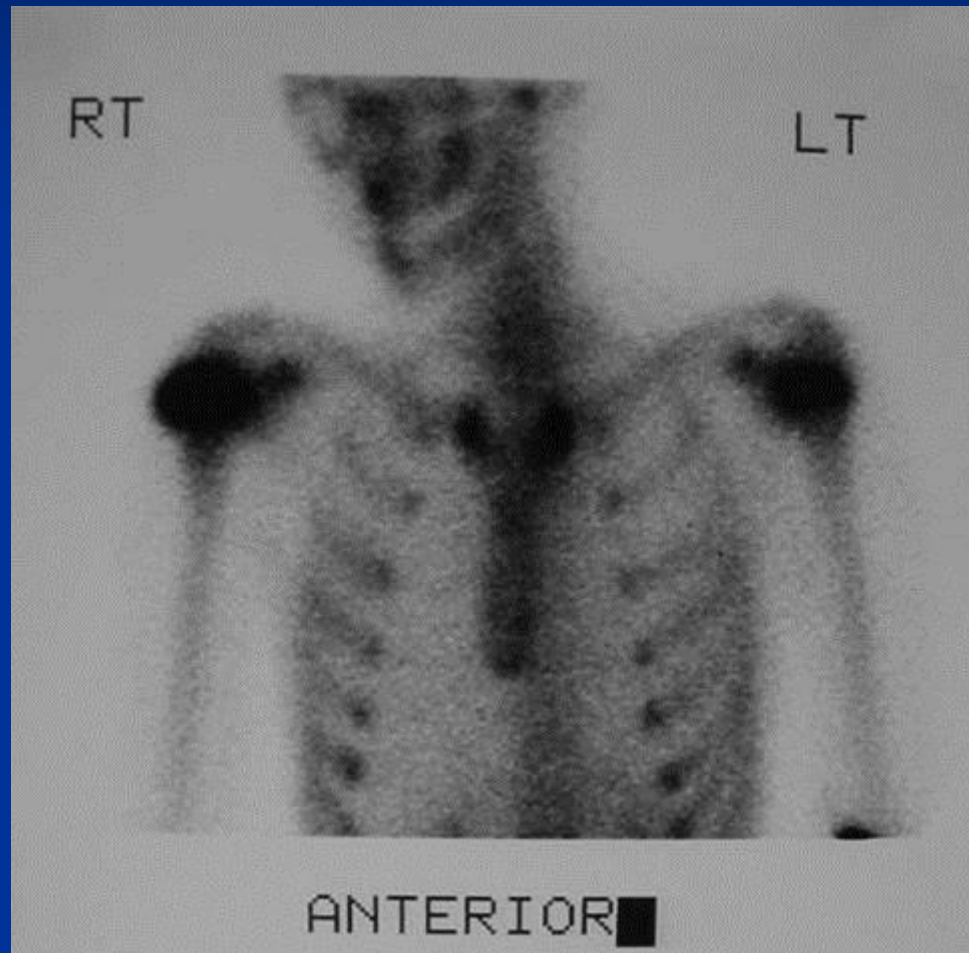CT Axial Slice



CT Reconstruction



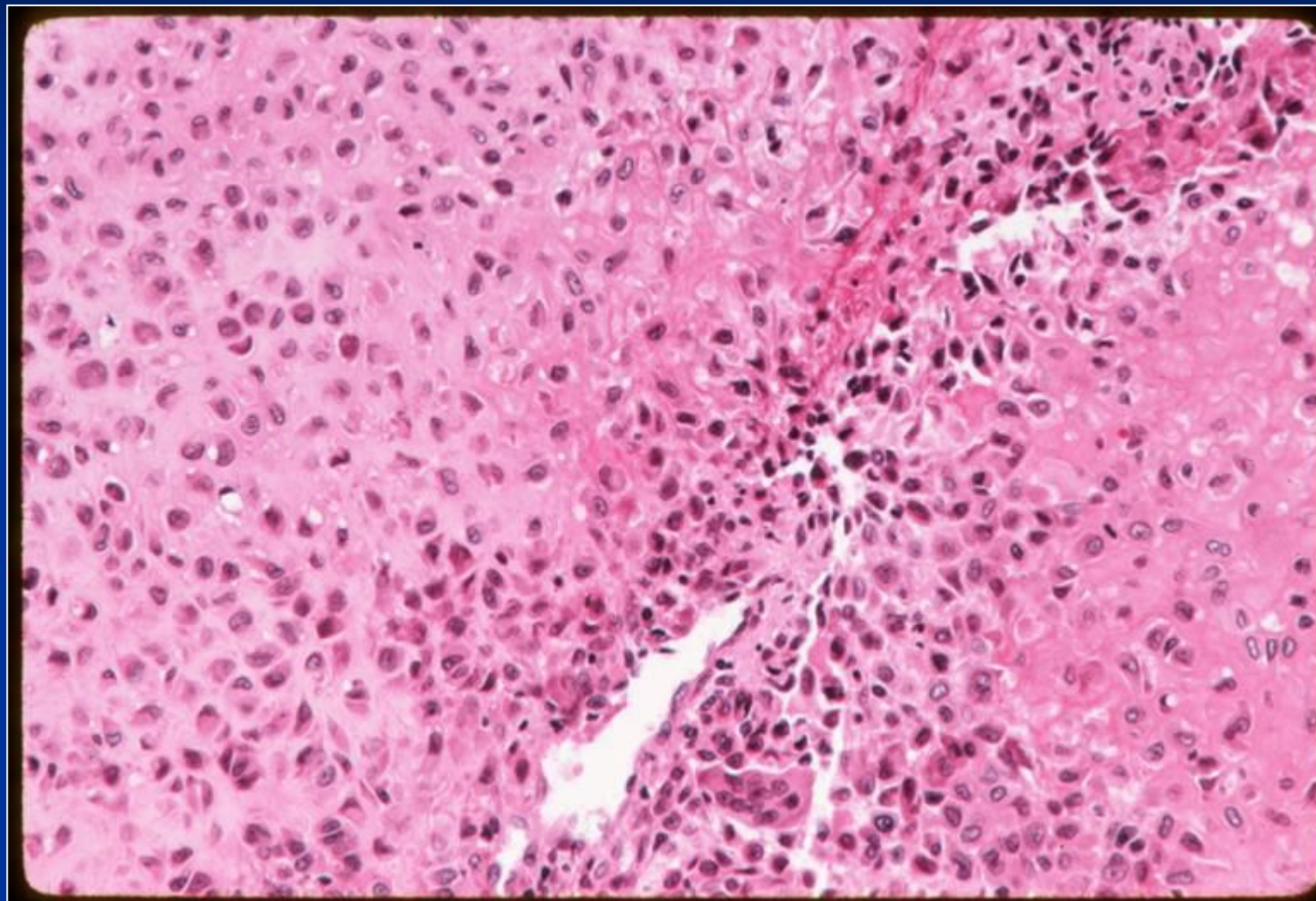
Bone Scan



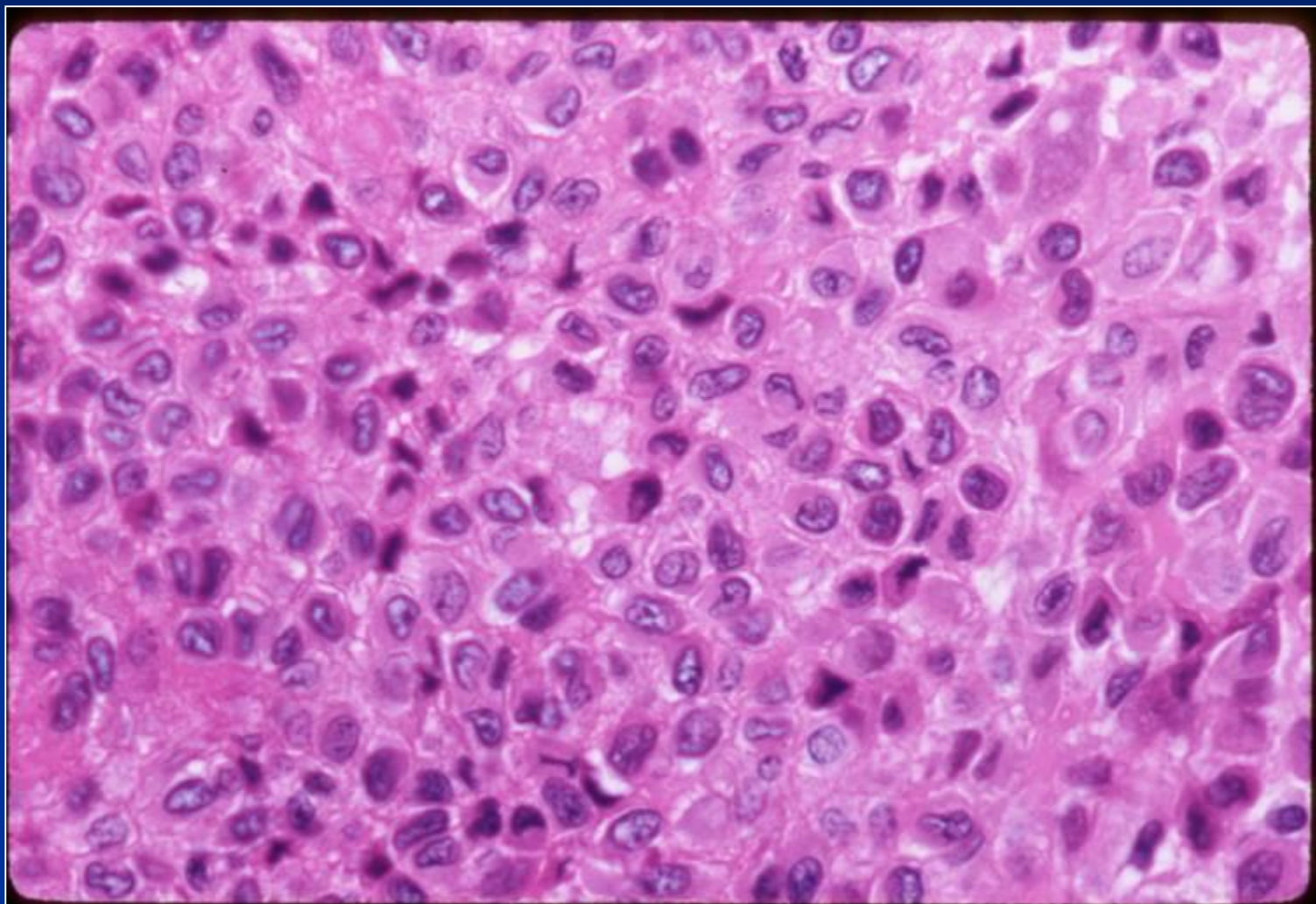
Gross Pathology



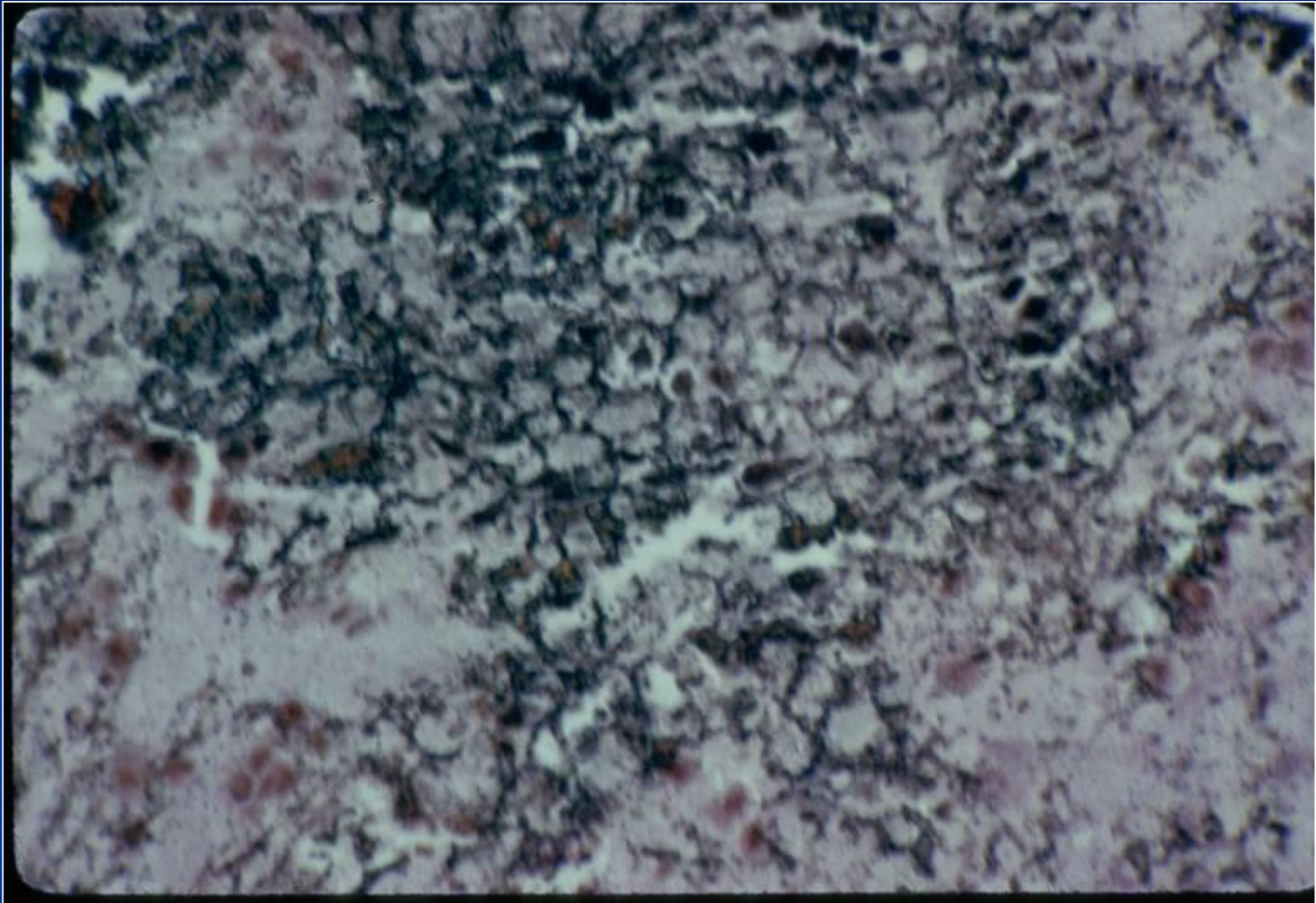
Pathology—Low Power



Pathology—High Power



Van Kossa Stain



*Diagnosis Next

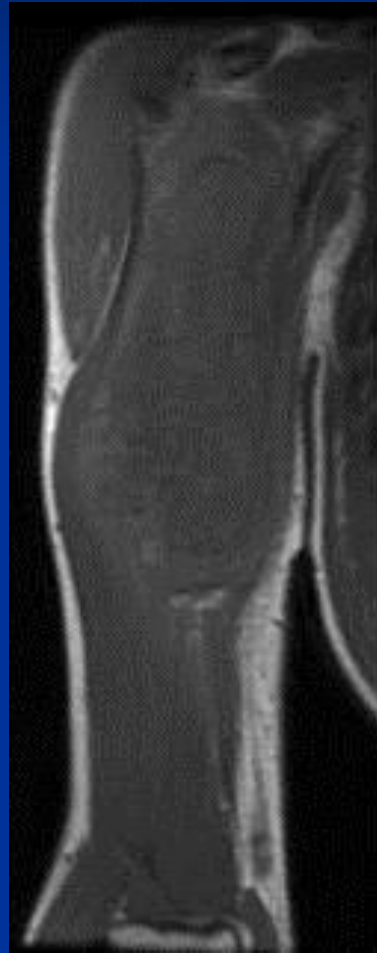

Chondroblastoma

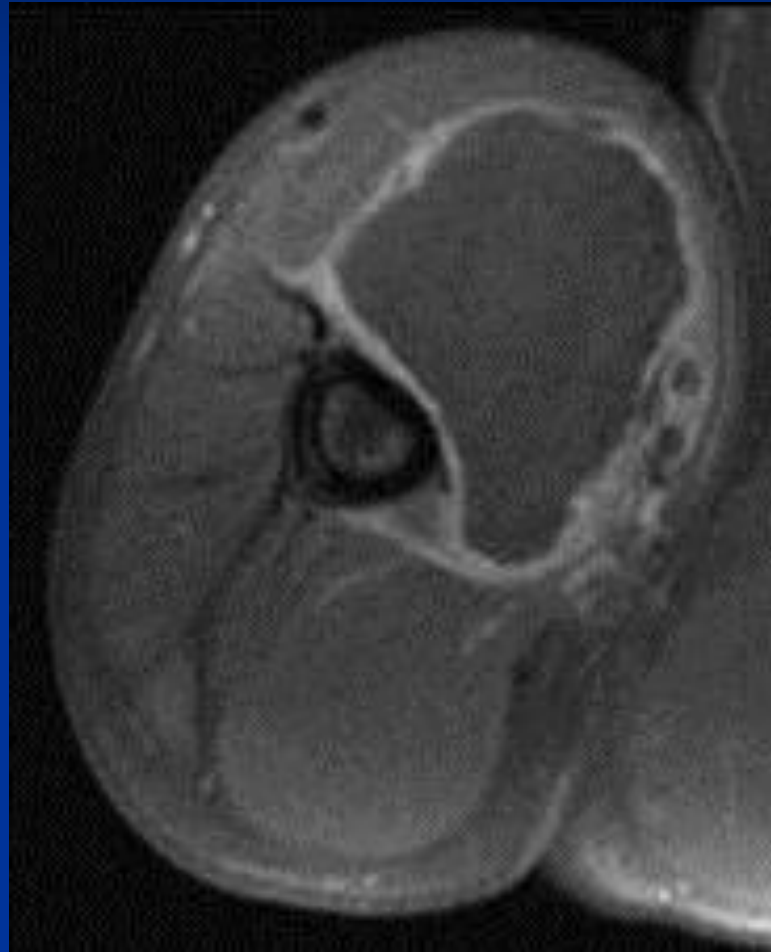
CASE #8

- A 15-year-old male presented a mass in his right upper extremity. He felt a minor twinge in his arm while playing baseball 6 months before the visit and noticed a mass 2 months prior to initial evaluation. He complained of a rapidly enlarging, firm, immobile, and painless mass in his upper arm. Physical examination showed a large, non-tender mass in his right biceps region. There was neither erythema nor axillary adenopathy. There was no fever, weight loss, or night sweats. He had full range of motion in his right shoulder, elbow, wrist and digits without discomfort and exhibited normal motor function. The patient had full sensation throughout his shoulder, arm, and hand. Immunohistochemical stains were positive for CD31, CD34, and D2-40.

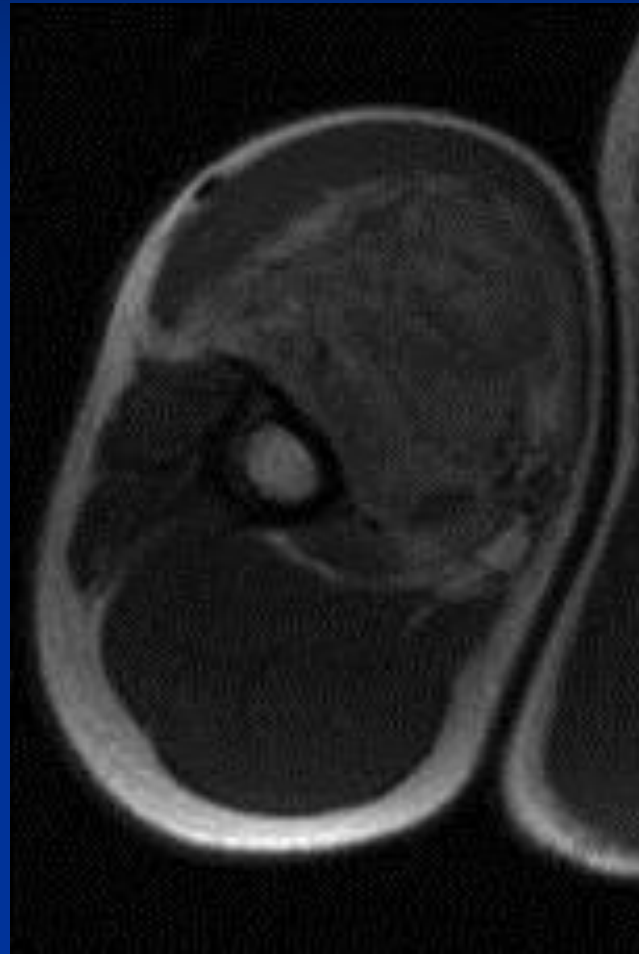
T1- weighted MR

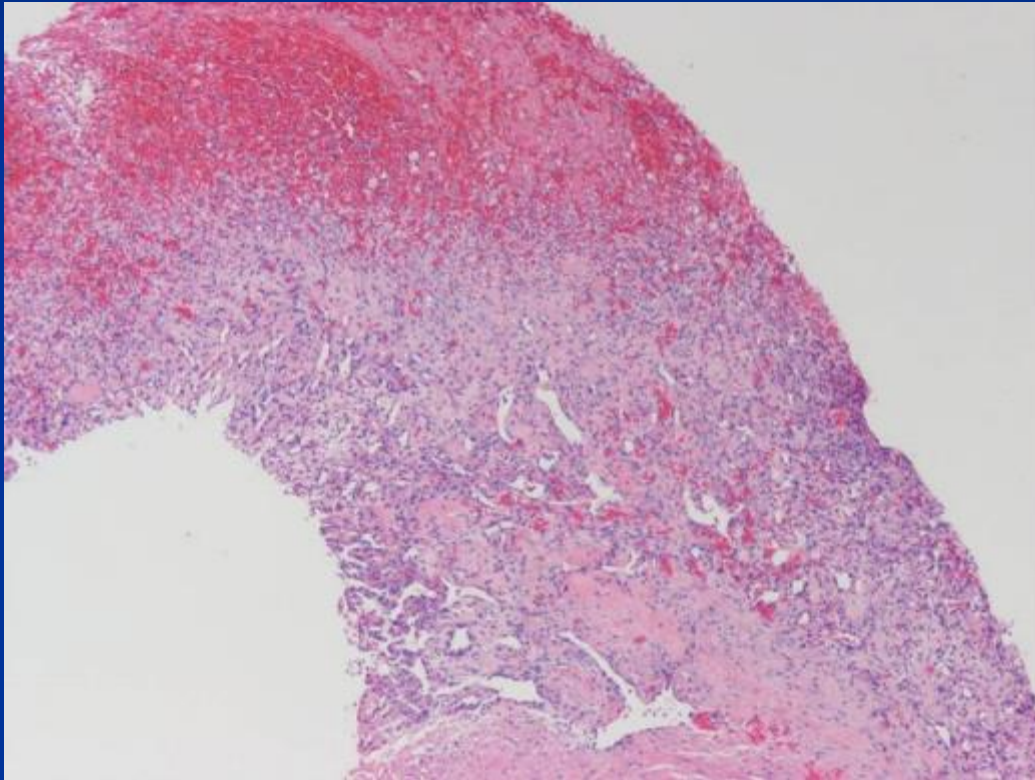


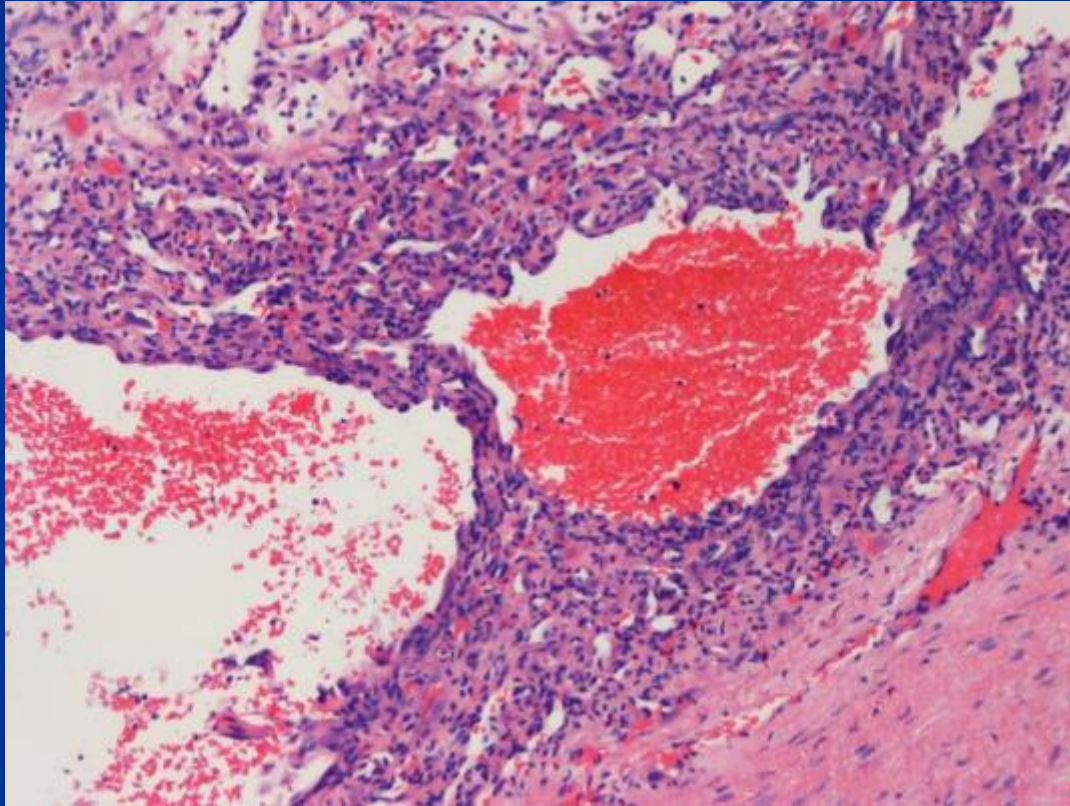
T1- weighted fat suppressed contrast

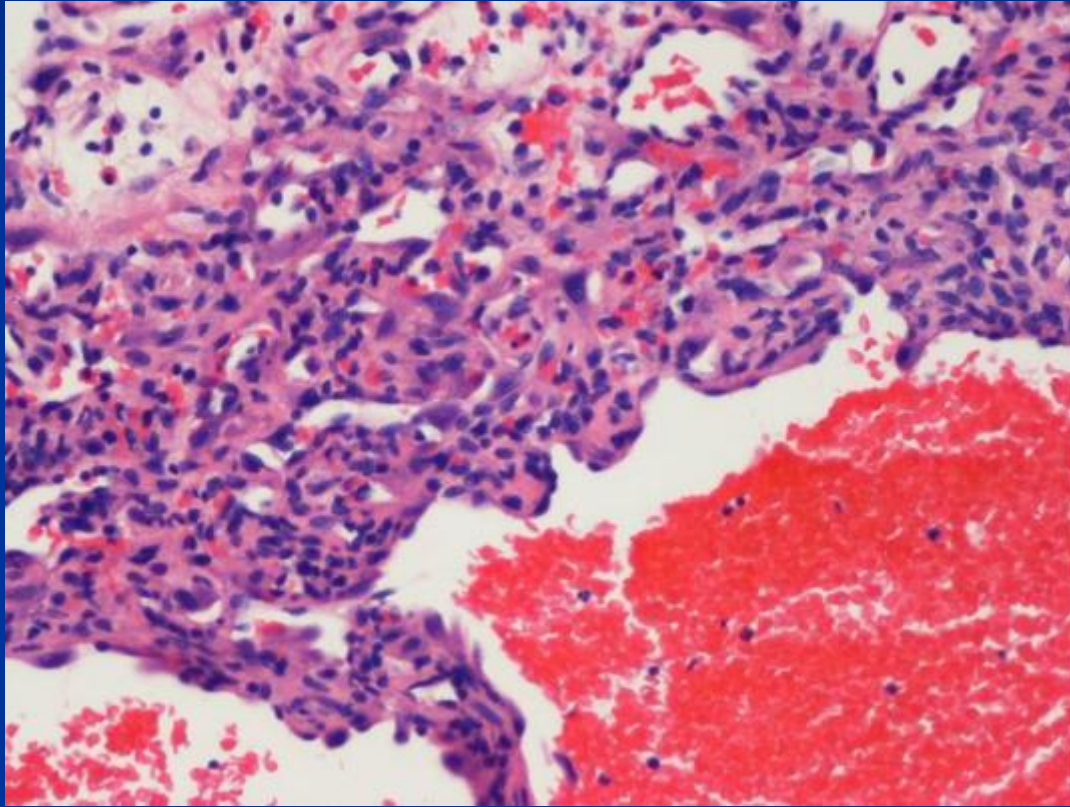


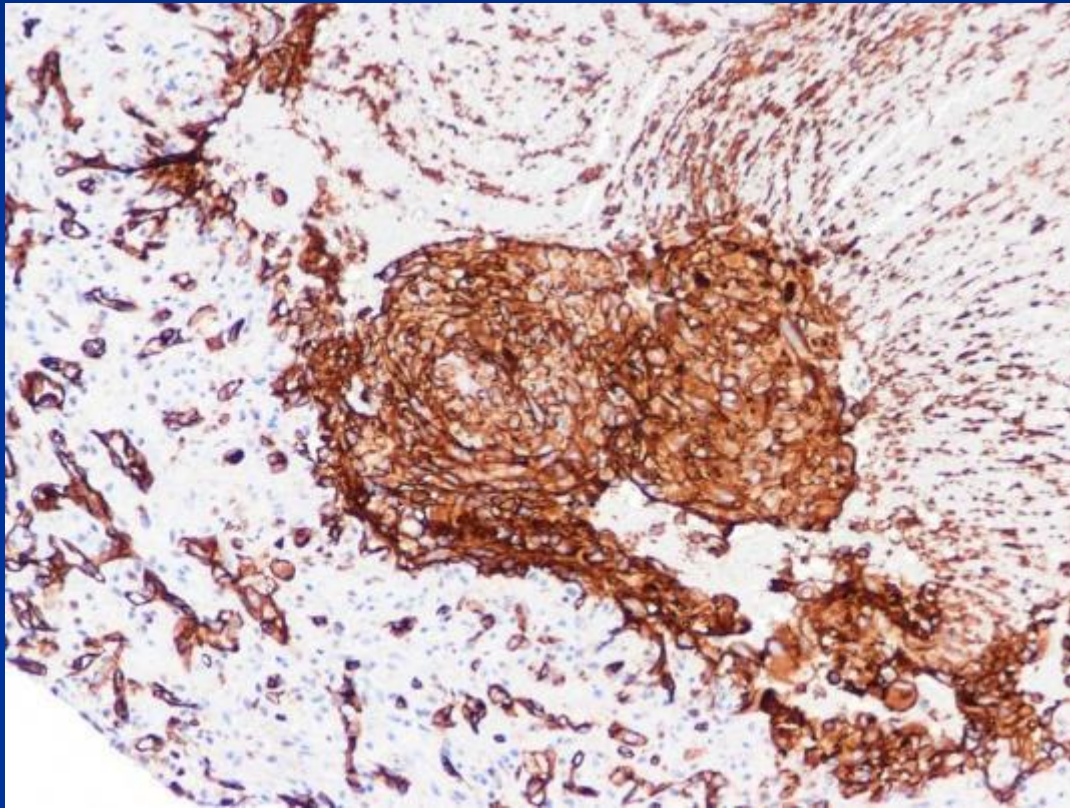
T2- weighted MR

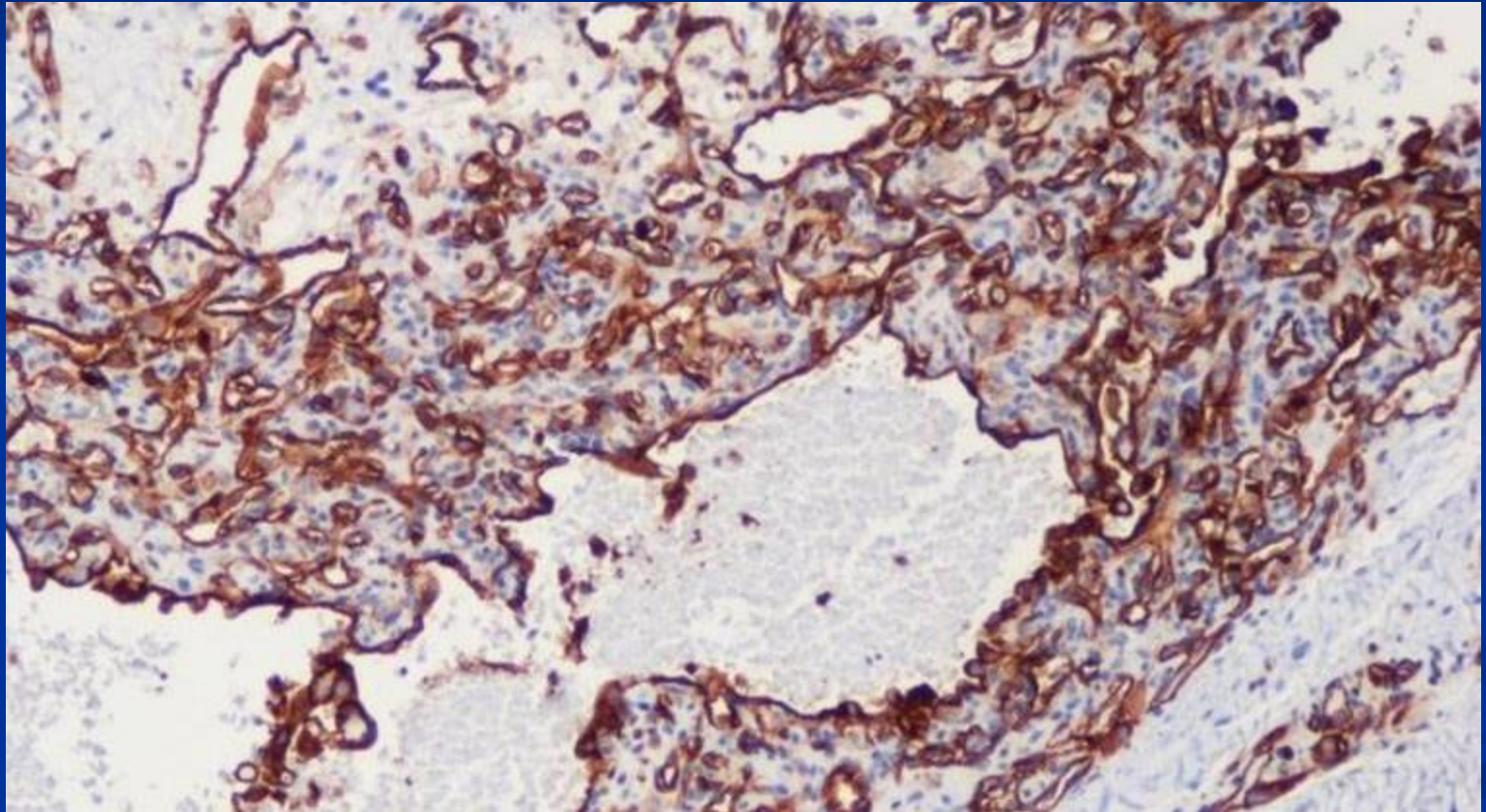












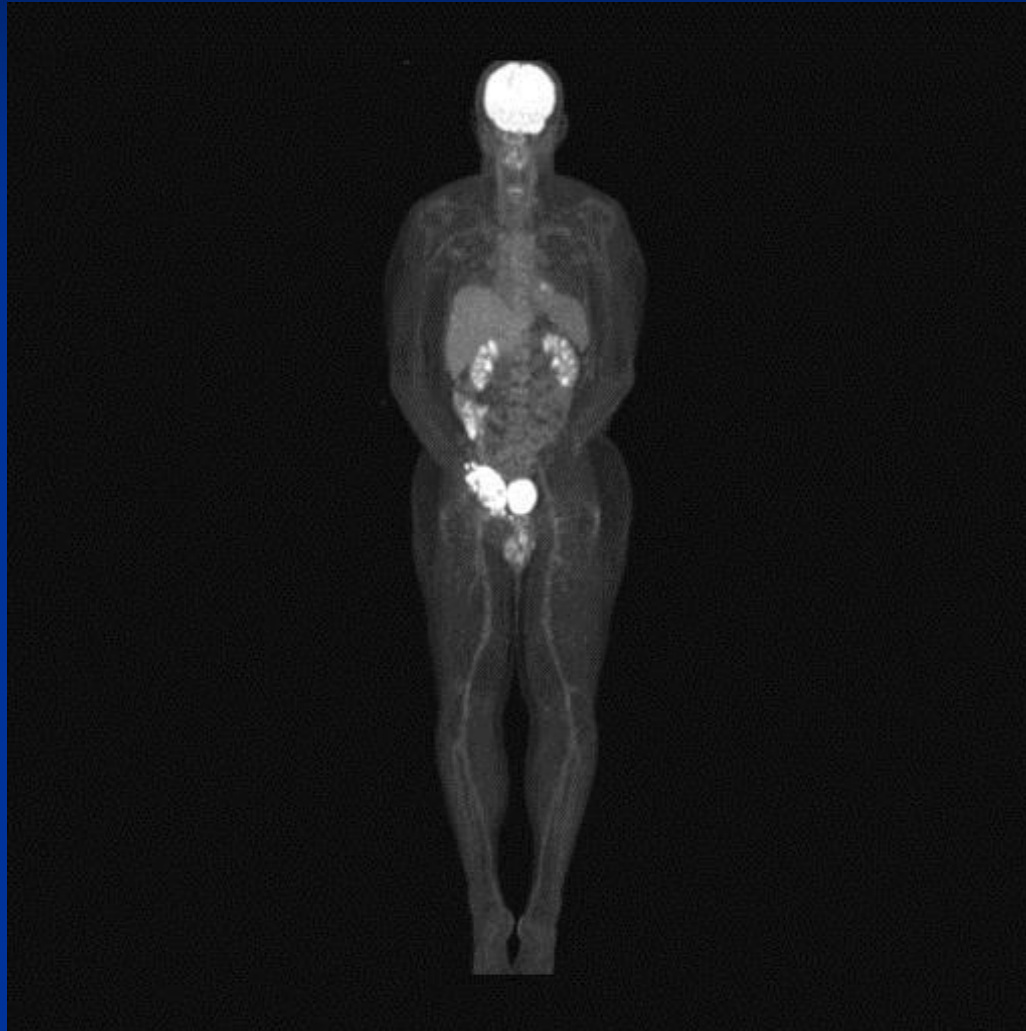
*Diagnosis Next

Angiosarcoma

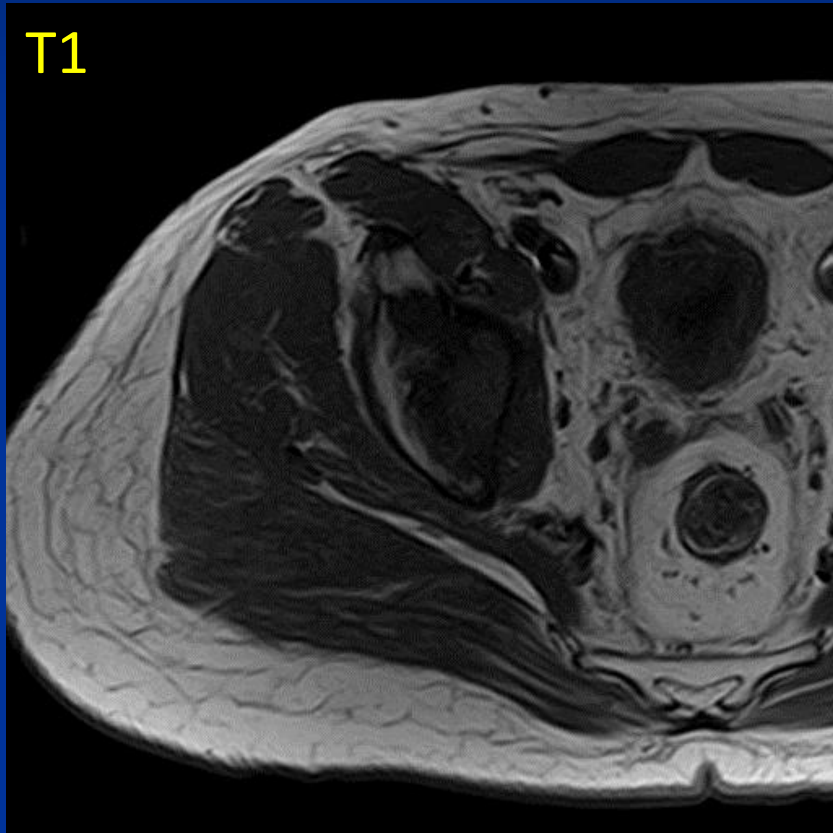
CASE #9

- 48 year old male complaining of right hip pain that radiated down his leg. ROM was limited in his right lower extremity. MRI showed a lesion in the right acetabulum/pelvis with soft tissue involvement. WBBS showed increased uptake in the right acetabulum. Patient's sections demonstrated necrosis. Immunohistochemistry stained positive for CD-99 and stained negative for CD-56, S-100 protein, and Desmin.

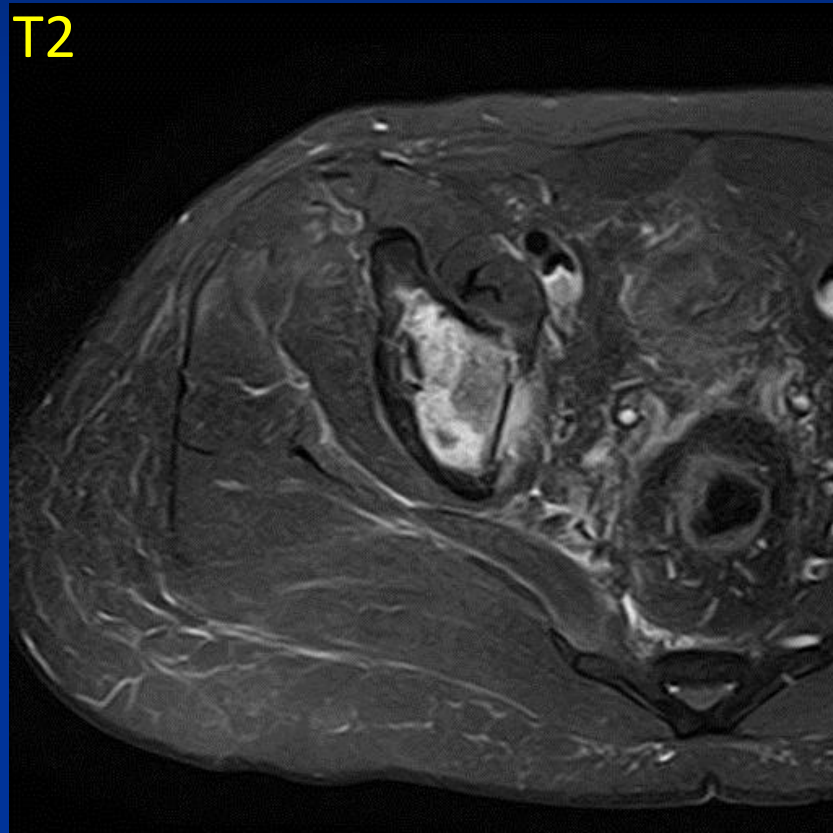
PET/CT of body



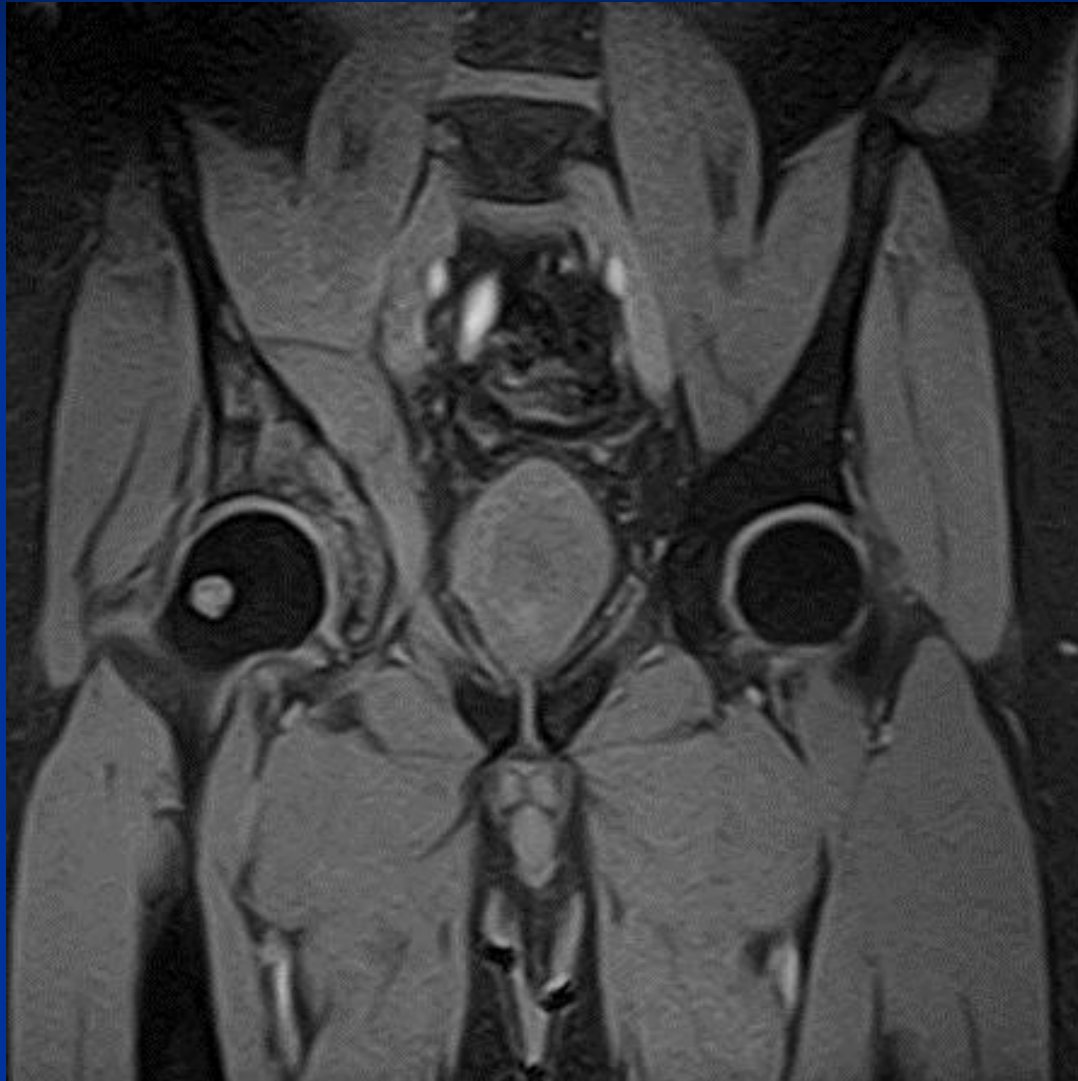T1



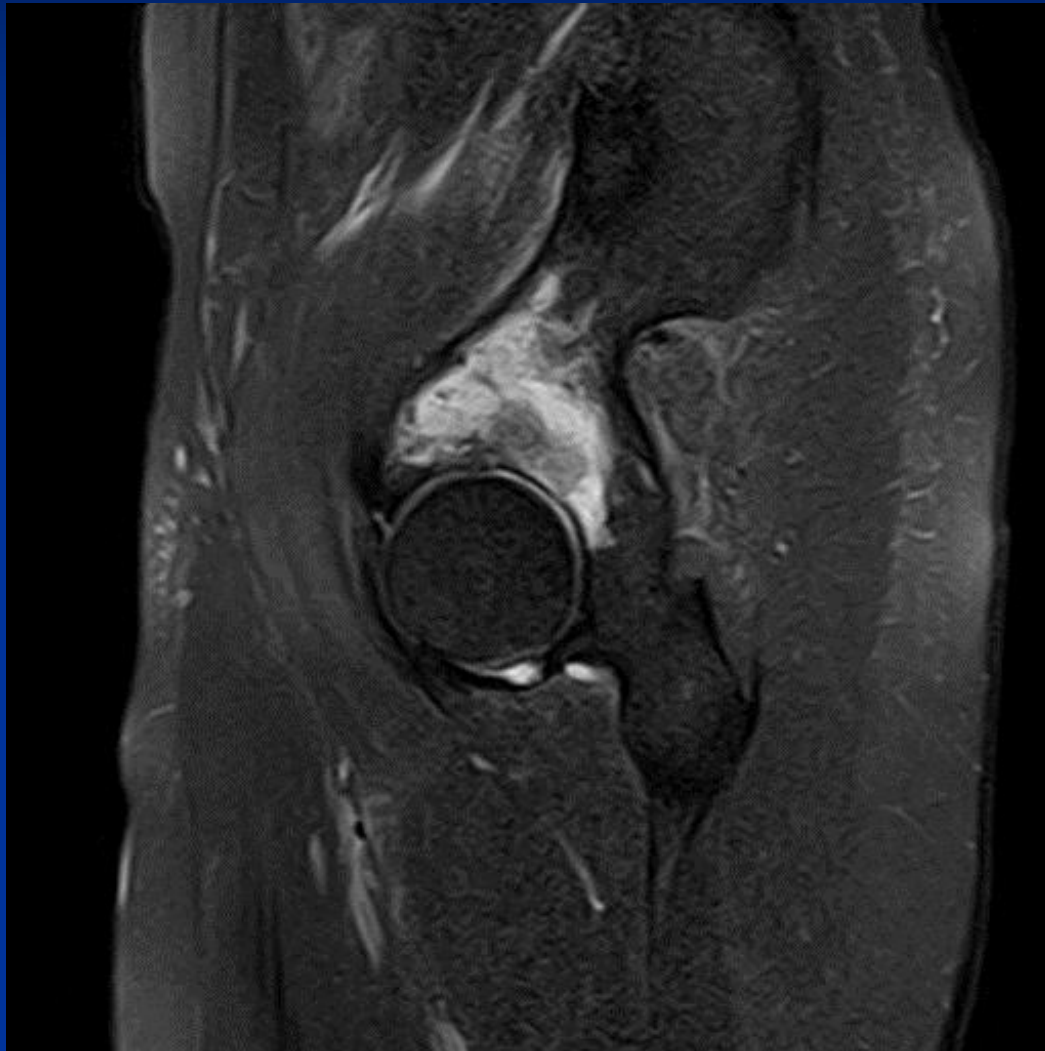T2

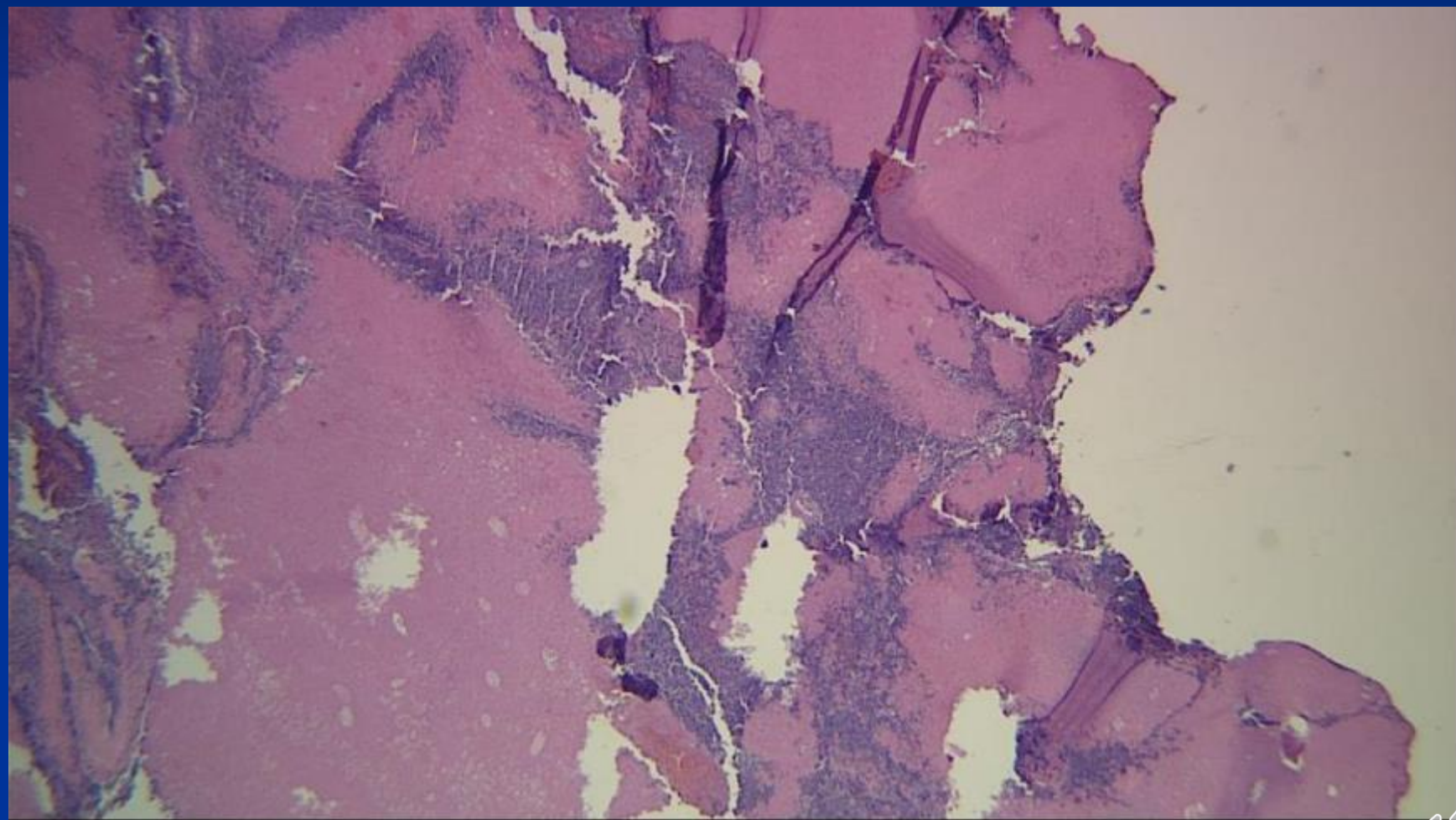


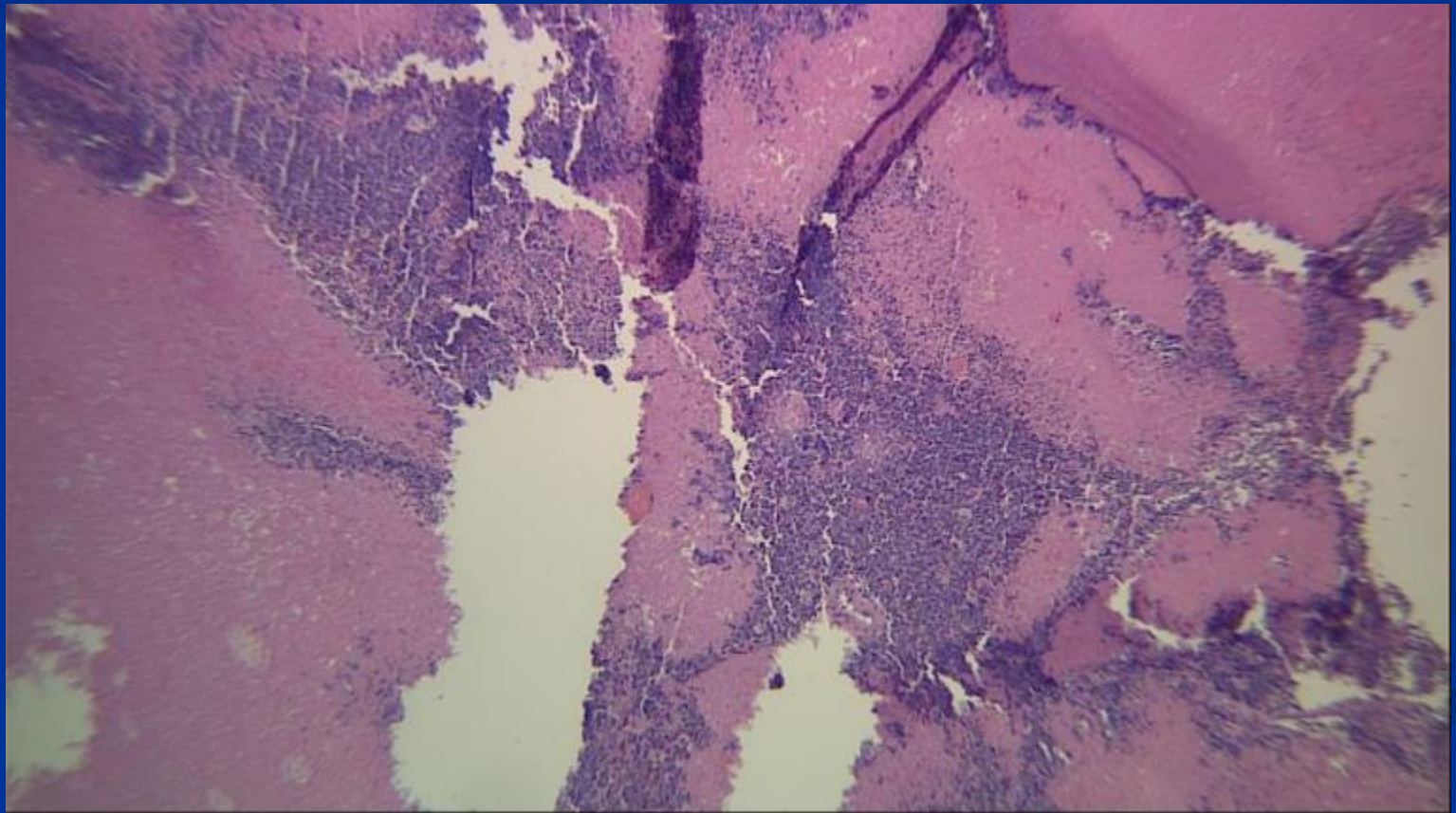
MR Axial T-1 Pelvis

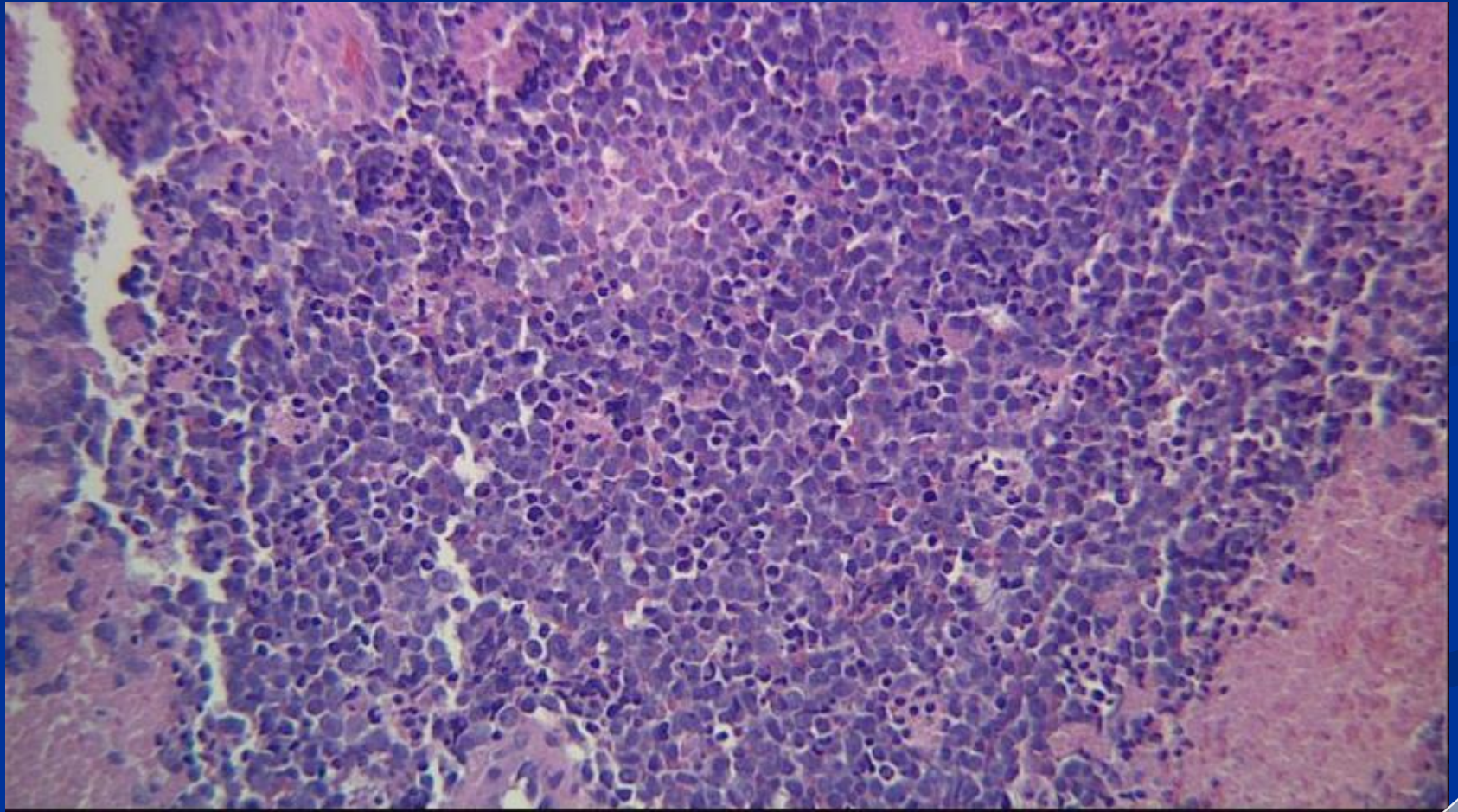


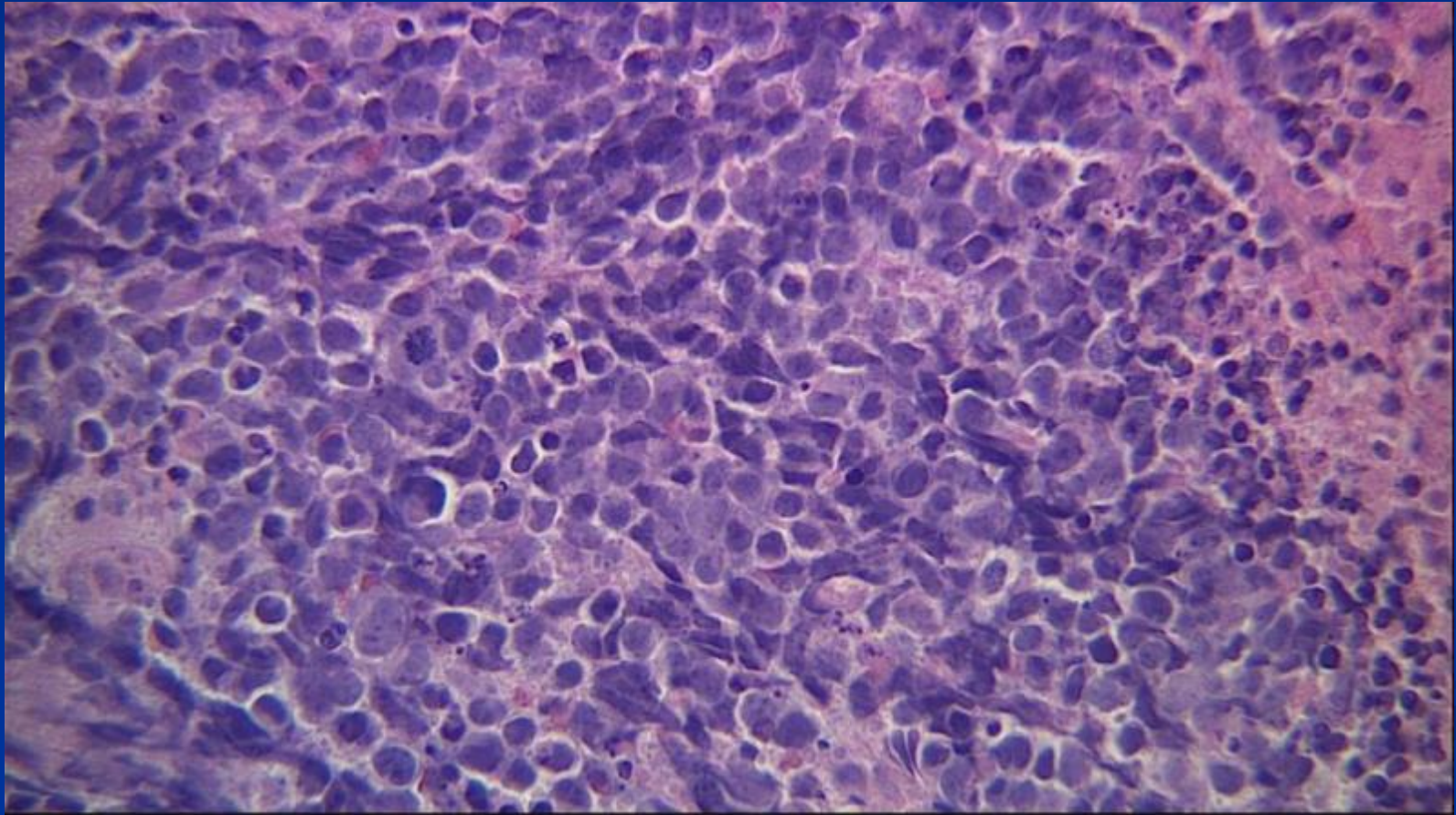
T-2 Sagittal Fat Saturated











*Diagnosis Next

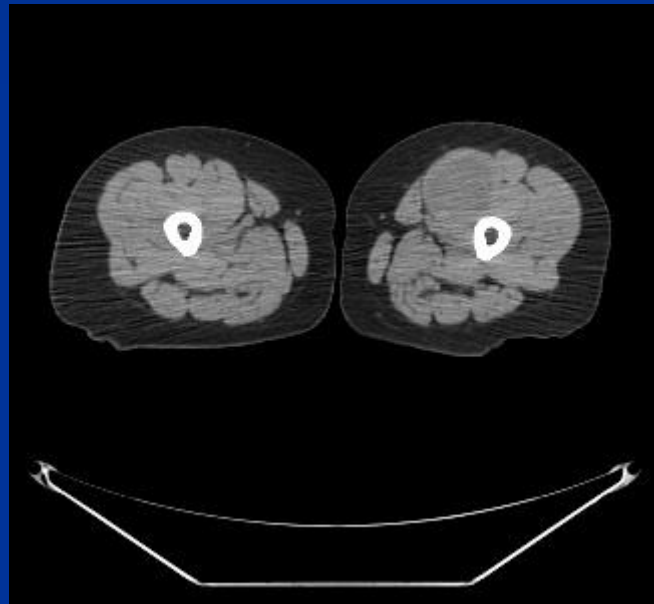

Ewing's Sarcoma

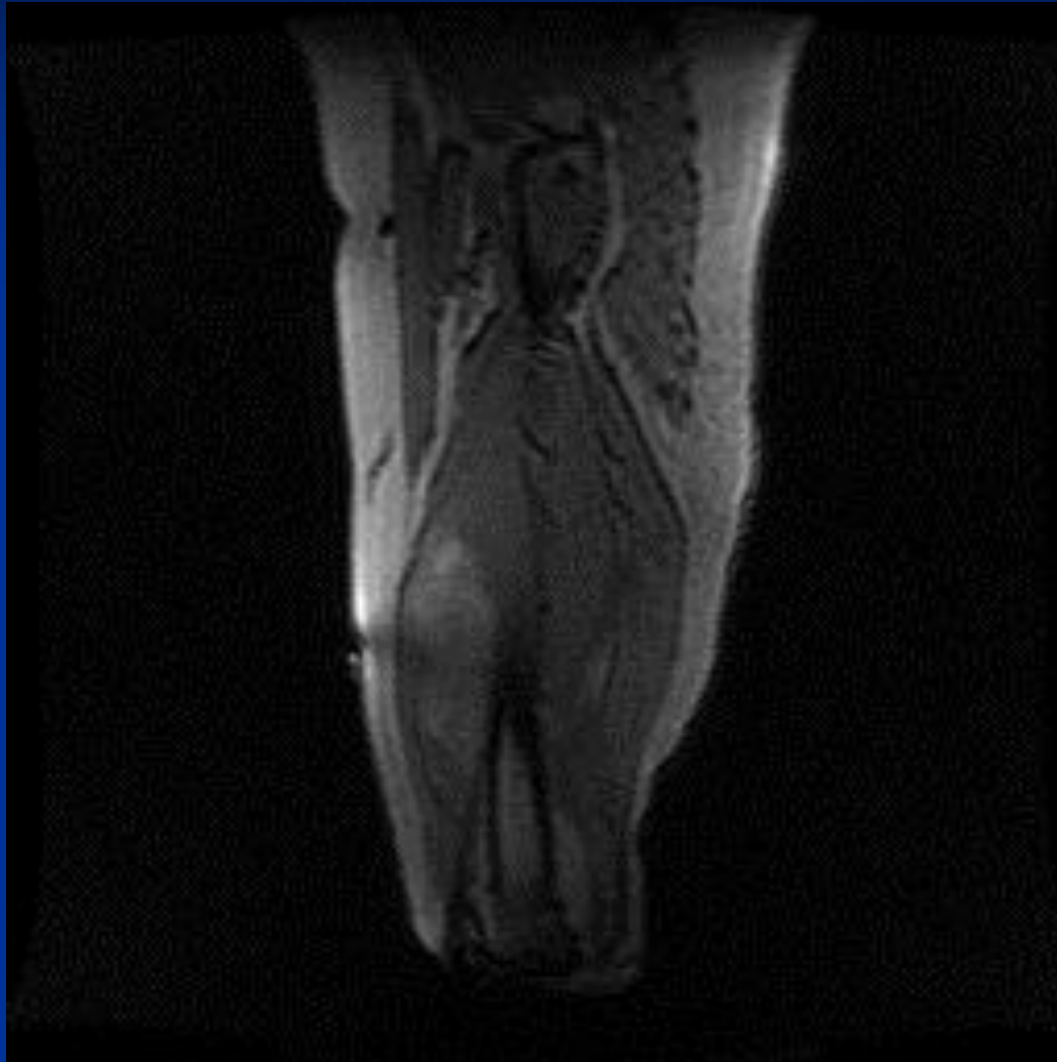CASE #10

- A 53 year old active female presented with swelling in her left upper thigh for 2-3 weeks. The patient complained of muscle soreness after intentionally losing weight by running. She had full ROM with no numbness or tingling. MRI showed a solid, partially necrotic and nonspecific mass on her vastus medialis muscle. The mass measured 82 mm in craniocaudad dimension. Immunohistochemistry revealed positivity for Vimentin and MIC1. Stains for myoglobin, S-100 protein, and pankeratin were negative. There was patchy staining for smooth muscle actin, myogenin, and desmin.

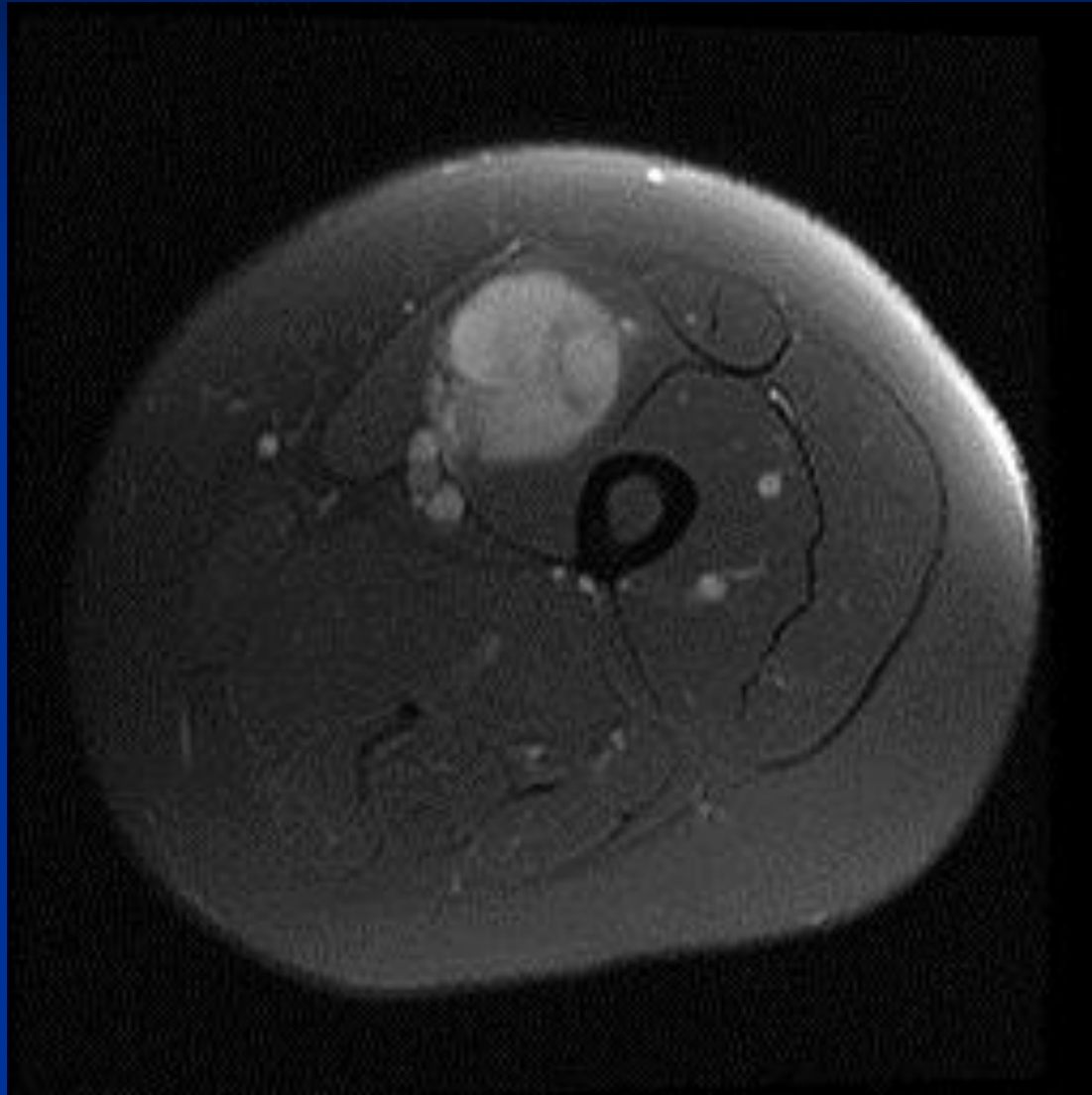
PET/CT Whole Body Exam



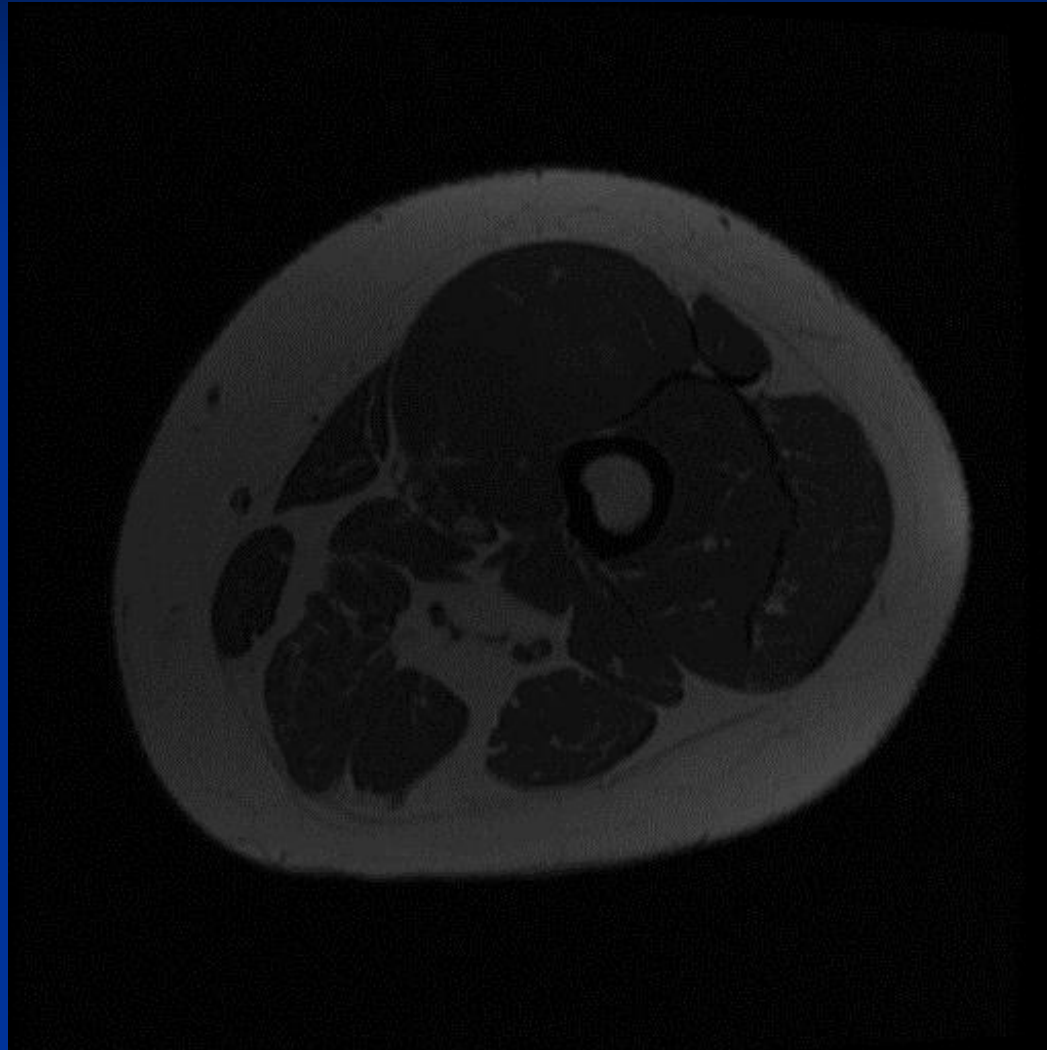
Axial T2 FGRE S



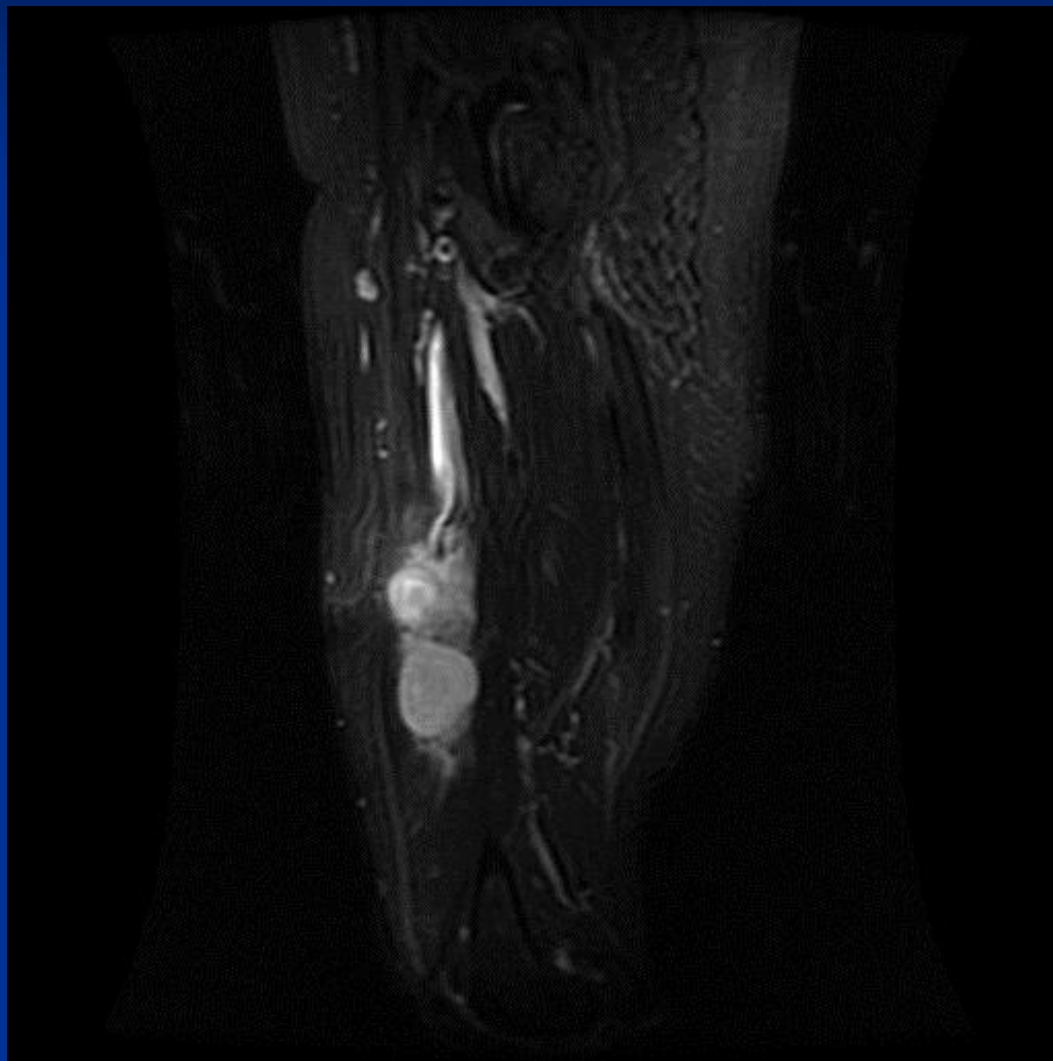
Axial FSE T2 FAT SAT



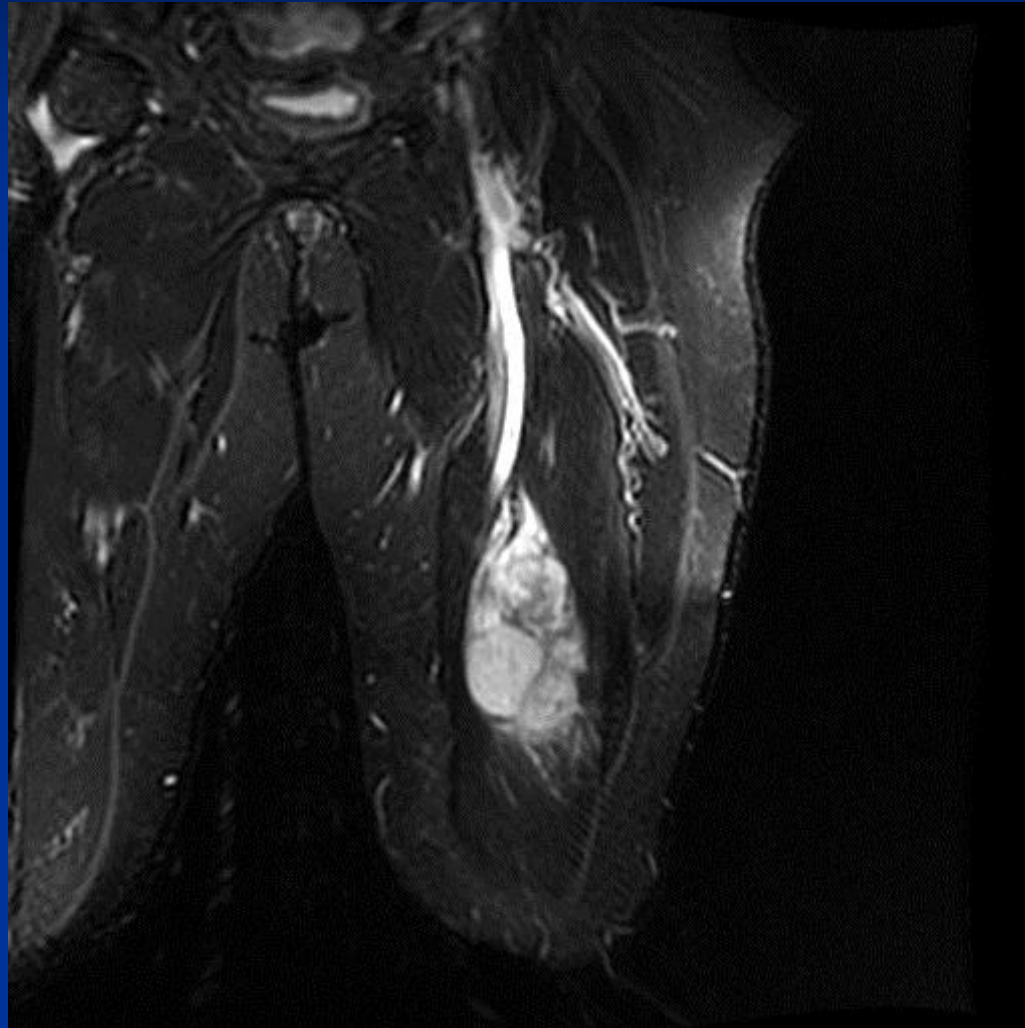
Axial FSE T-1

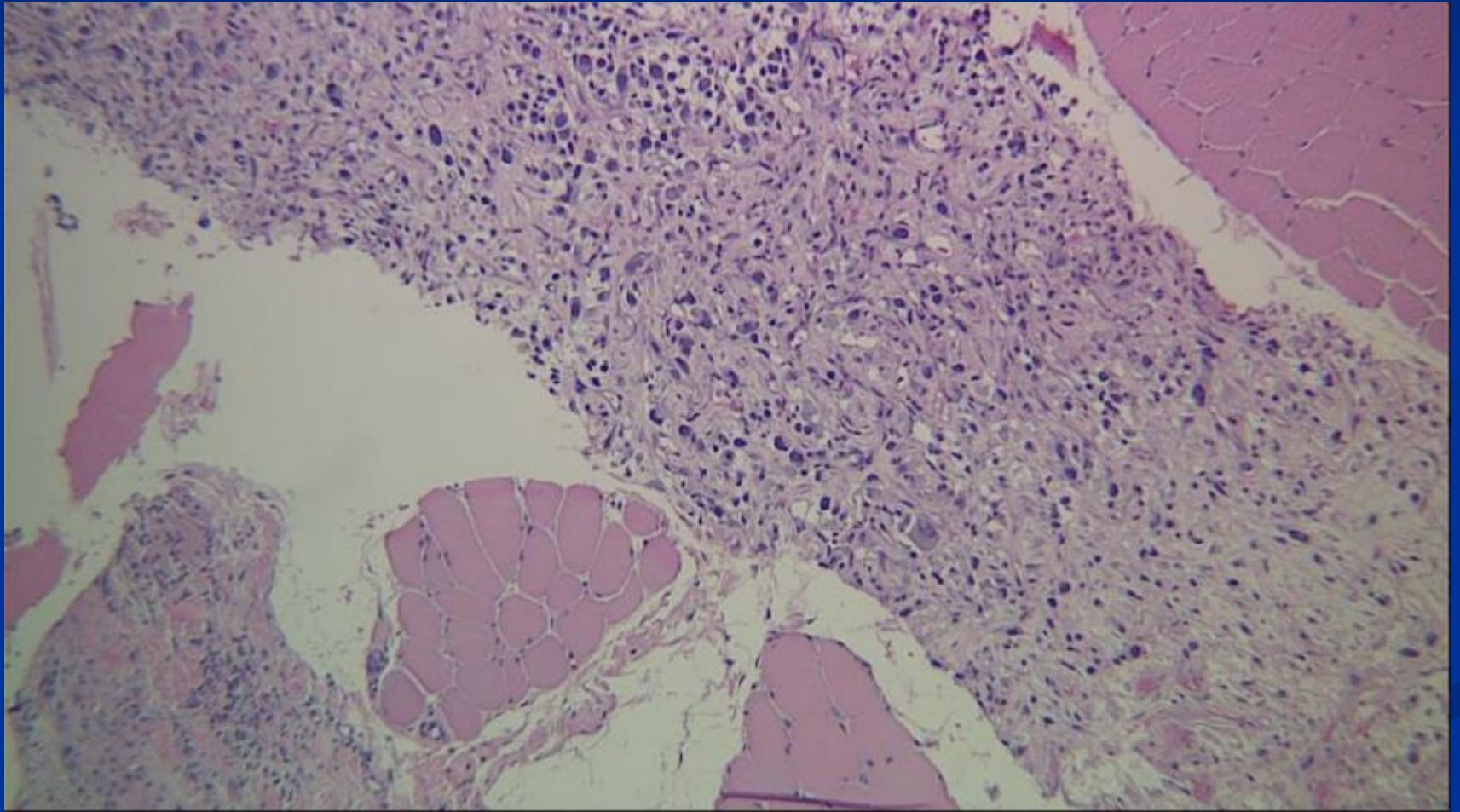


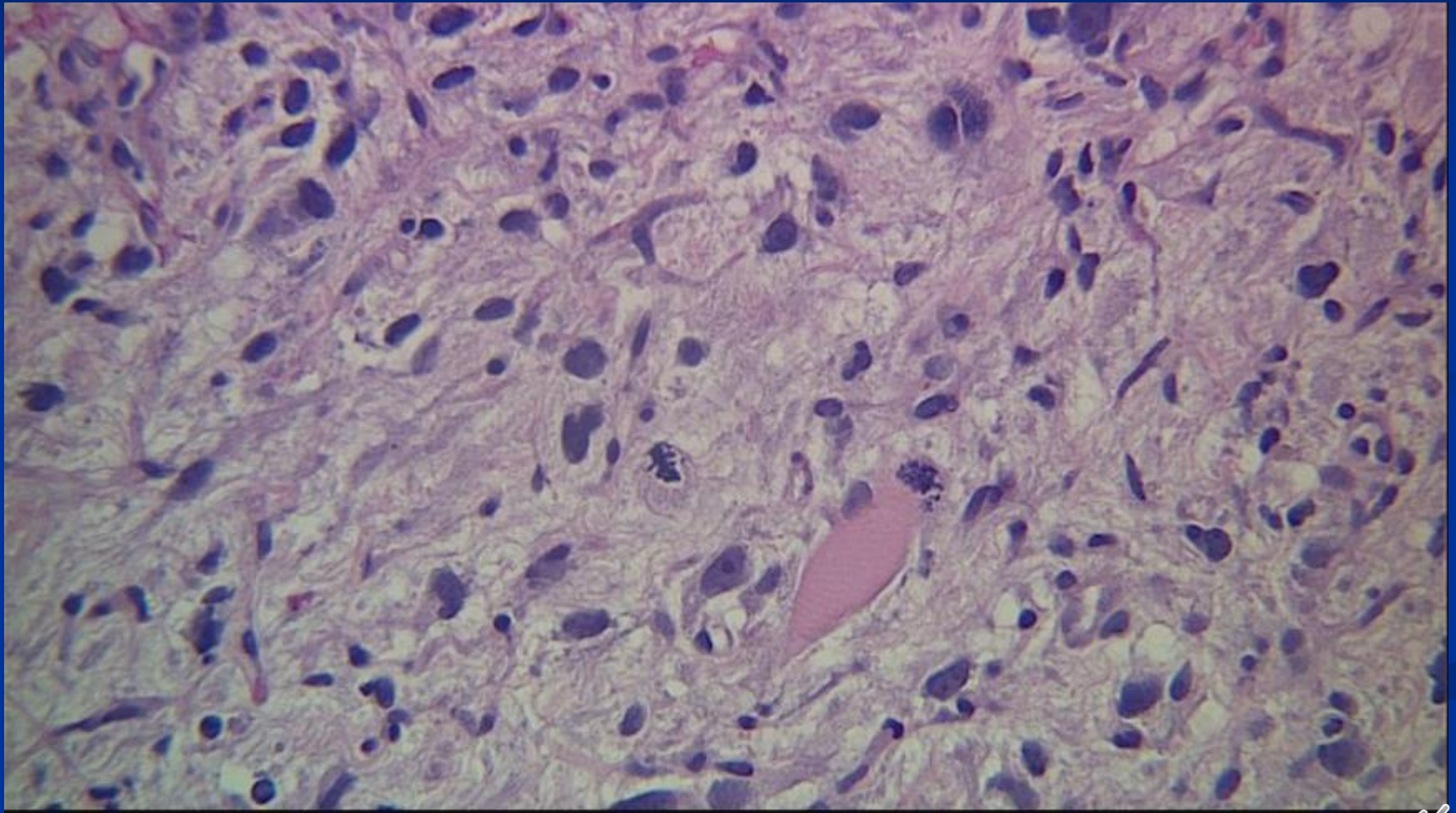
Sagittal STIR

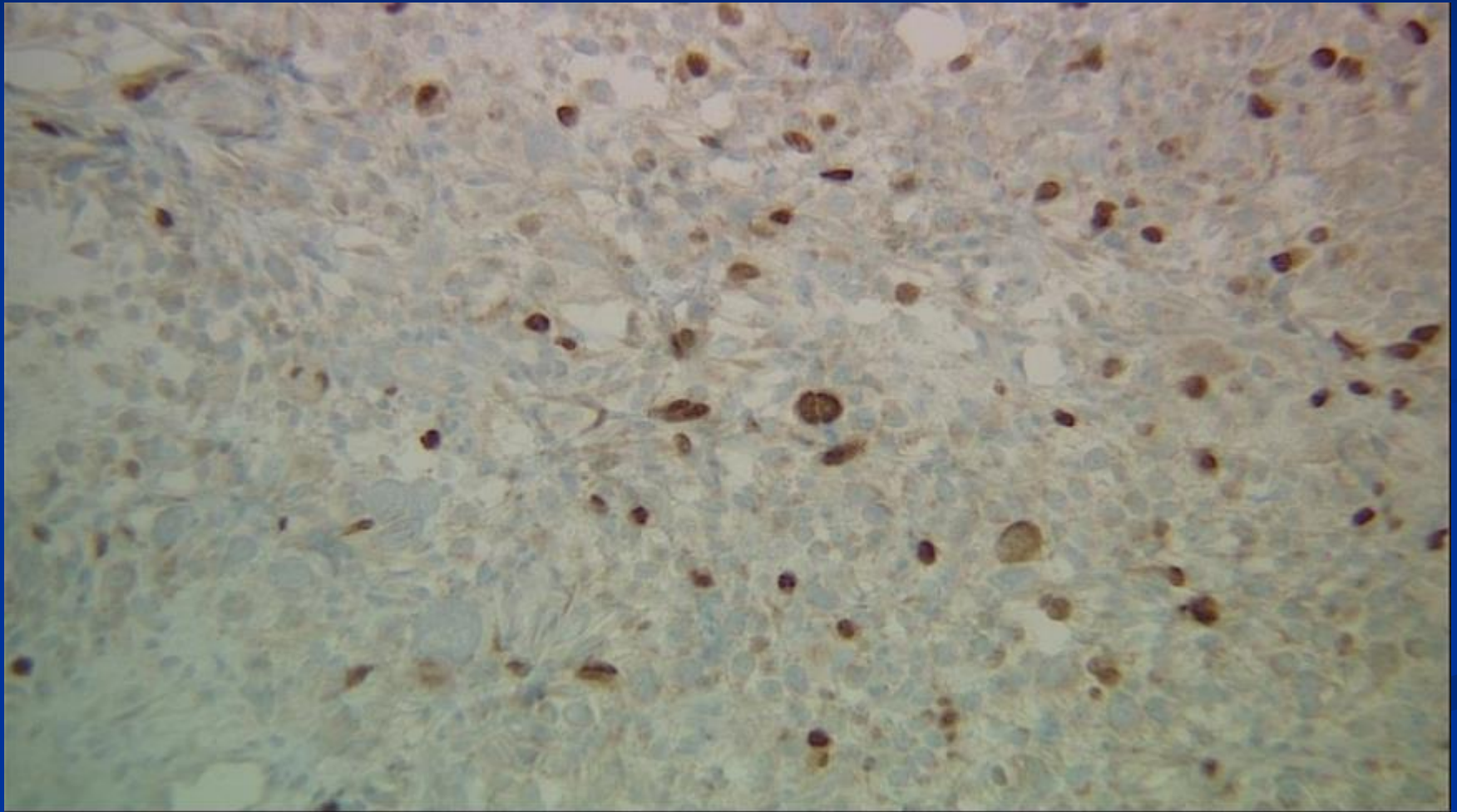


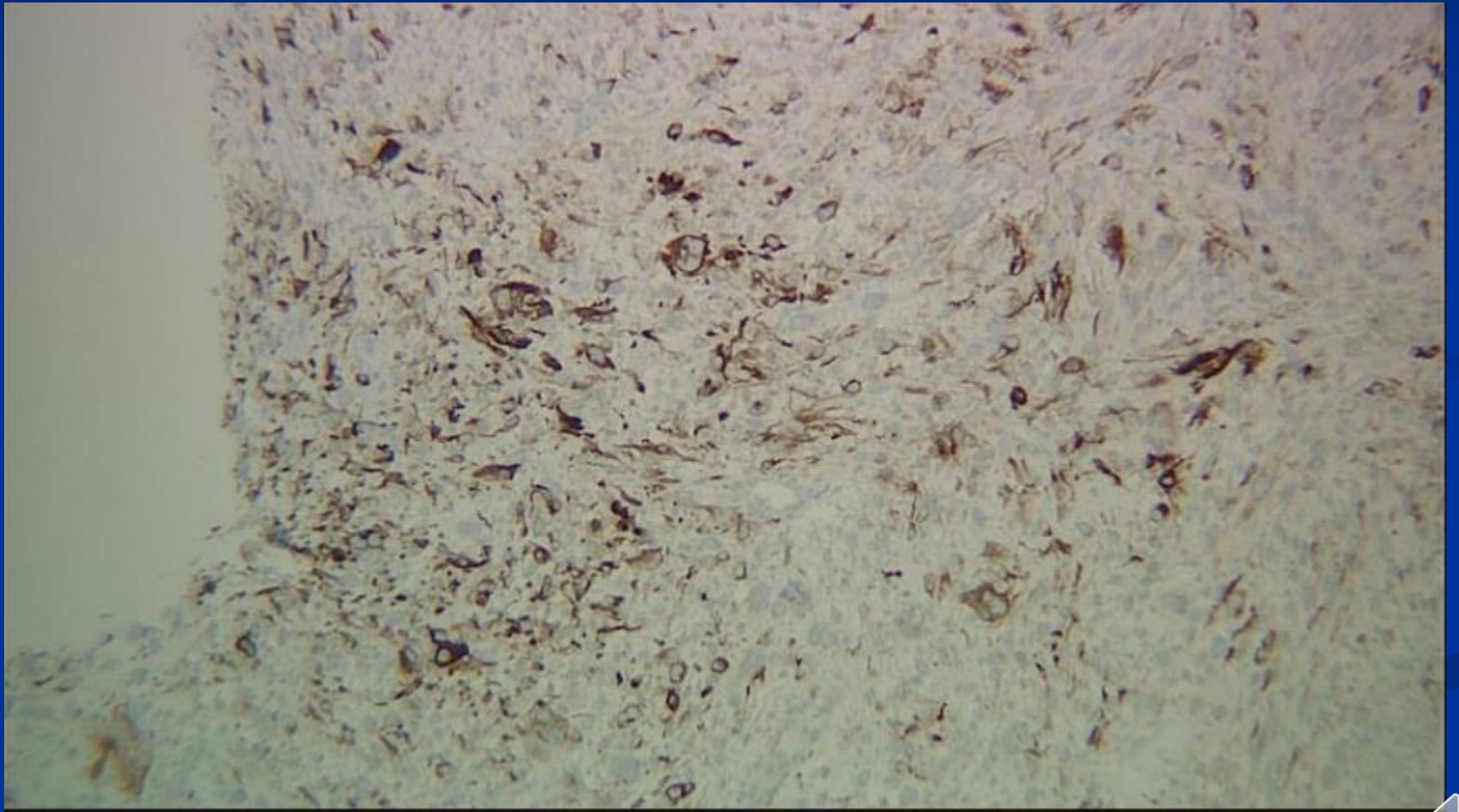
COR STIR

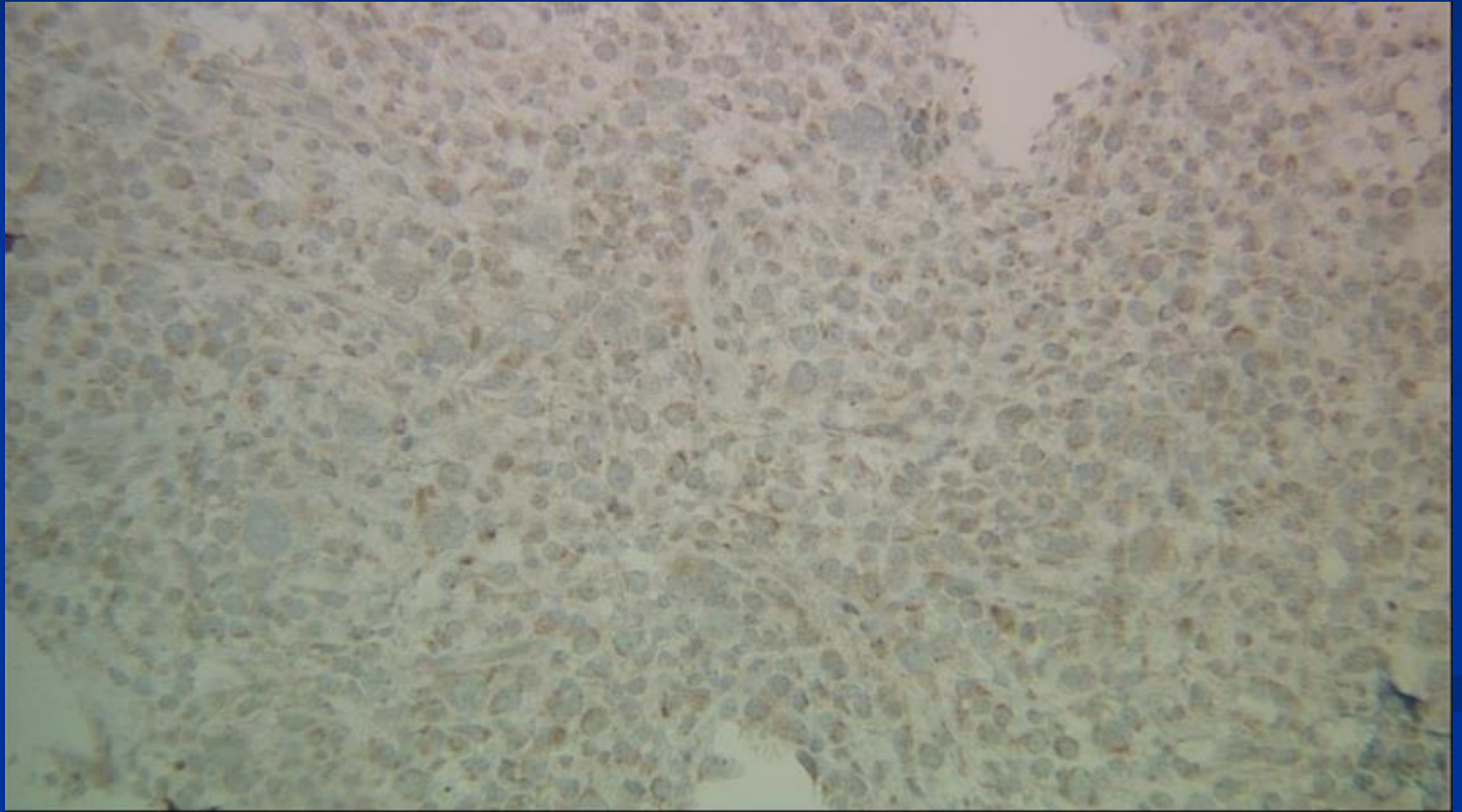












*Diagnosis Next



High Grade Pleomorphic Sarcoma

Thank You!
www.TumorSurgery.org