

Soft Tissue Sarcomas

Liposarcoma, MFH/UPS, Synovial Sarcoma,
Fibrosarcoma, Rhabdomyosarcoma
Leiomyosarcoma

James C. Wittig, MD
Orthopedic Oncologist
Sarcoma Surgeon
www.TumorSurgery.org

Malignant Soft Tissue Tumors

- MFH #1
- Liposarcoma #2
- Leiomyosarcoma #3
- Synovial Sarcoma
- Fibrosarcoma
- Rhabdomyosarcoma
- Epithelioid Sarcoma
- Malignant Peripheral Nerve Sheath Tumor
- Extraskeletal Osteosarcoma, Ewings, Chondrosarcoma

Malignant Soft Tissue Tumors

- **Presenting Ages:**
- All soft tissue sarcomas primarily affect adults 40-70 years of age except
 - Rhabdomyosarcoma—Children up to 20
 - Synovial Sarcoma— young adults and teenagers (15 to 35 years of age)

Malignant Soft Tissue Tumors

- Usually Painless mass except synovial sarcoma
 - Other painful benign masses:
 - Hemangioma
 - Fibromatosis mildly painful
 - Schwannoma
 - Angiolipoma
- MRI Appearance Sarcomas:
 - Nonspecific heterogeneous soft tissue mass on T1, T2 except
 - Well Differentiated Liposarcoma
 - Myxoid Tumors: Liposarcoma, MFH

Malignant Soft Tissue Tumors

- Calcification/Mineralization: Any sarcoma can calcify
 - Synovial Sarcoma notorious for calcification
 - Extraskkeletal Chondrosarcoma/Osteosarcoma
 - Lipoma or Liposarcoma with Necrosis
 - Hemangioma—benign soft tissue tumor with calcification
 - Synovial Chondromatosis
- Metastases: usually always to the **lungs** first, then bones, then liver
 - Myxoid liposarcoma mets to other soft tissues and bones
 - Lymph Node Mets
 - Synovial Sarcoma
 - Epithelioid Sarcoma
 - Rhabdomyosarcoma

Malignant Soft Tissue Tumors

- Sites:
 - Thigh is most common for MFH, fibrosarcoma, liposarcoma
 - Fibromatosis common around shoulder girdle
 - Synovial Sarcoma—around but usually not within major joints
 - Foot and Ankle—Synovial sarcoma most common soft tissue sarcoma
 - Hand: Epithelioid Sarcoma—often ulcerates
 - Retroperitoneum: Liposarcoma and Leiomyosarcoma are the most common

Malignant Soft Tissue Tumors

- Adjacent Osseous Involvement:
 - MFH
 - Synovial Sarcoma
 - Rhabdomyosarcoma (also mets to bone marrow)
- Translocations:
 - Synovial Sarcoma: $t(X;18)$ SYT-SSX
 - Myxoid/Round Cell Liposarcoma: $t(12;16)$
 - Alveolar Rhabdomyosarcoma: $t(2;13)$ PAX3/FKHR
or $t(1;13)$ PAX7/FKHR

Malignant Soft Tissue Tumors

- All Soft Tissue Sarcomas are spindle cell tumors except
 - Biphasic Synovial Cell Sarcoma: Has Epithelioid Elements
 - Epithelioid Sarcoma: Epithelioid like cells (polygonal)
 - Rhabdomyosarcoma: Small Round Blue Cell/Rhabdomyoblasts
 - Extraskeletal Ewings Sarcoma

Malignant Soft Tissue Tumors

- Immunohistochemistry:
 - Vimentin: All sarcomas are Vimentin Positive
 - Cytokeratin: All Carcinomas are Cytokeratin Positive
 - Synovial Sarcoma: Vimentin & Cytokeratin, EMA Pos
 - Epithelioid Sarcoma: Vimentin & Cytokeratin, EMA Pos
 - MPNST: Diffuse S-100+; Neurofibromatosis; Nerve Origin
 - Leiomyosarcoma: Strong Actin Pos; Desmin Pos also
 - Rhabdomyosarcoma: + Desmin, Actin, MyoD1, Myoglobin
 - Also translocation, young age, rhabdomyoblasts, cross striations
 - MFH and Fibrosarcoma: No special differentiation
 - (myofibroblasts in MFH show scant and scattered Actin+)

Malignant Soft Tissue Tumors

- Most High Grade Sarcomas of an extremity present >5cm and Deep to Fascia, No mets (stage III AJC classification)
Stage IV is with mets anywhere
- Treatment:
 - Wide excision and radiation
 - Chemotherapy for Rhabdomyosarcoma in children and synovial sarcomas in young age groups
- Very General Survival Data:
 - 60-65% 5 year survival for nonmetastatic soft tissue sarcomas
 - 15% 5 year survival for pts with resectable mets to lungs

Liposarcoma

- 2nd most common ST sarcoma after MFH
- Adult tumor: 40-70 years of age
- Extremely rare in children/adolescents
- Extremities (thigh)
- Retroperitoneum
- Trunk

Liposarcoma Subtypes

- Well-differentiated (atypical lipoma)
- Myxoid
- Round cell (poorly diff./hypercellular)
- Pleomorphic
- Dedifferentiated
 - Well-differentiated liposarcoma demonstrating an area of poorly differentiated tissue

Liposarcoma Imaging

- Intermuscular location more common
- The more well-differentiated the lesion, the more fat it will appear to have
- WDLS may have large adipose-containing regions and thickened, nodular septations
- Fat more difficult to identify within other variants but **small scant amounts** often present

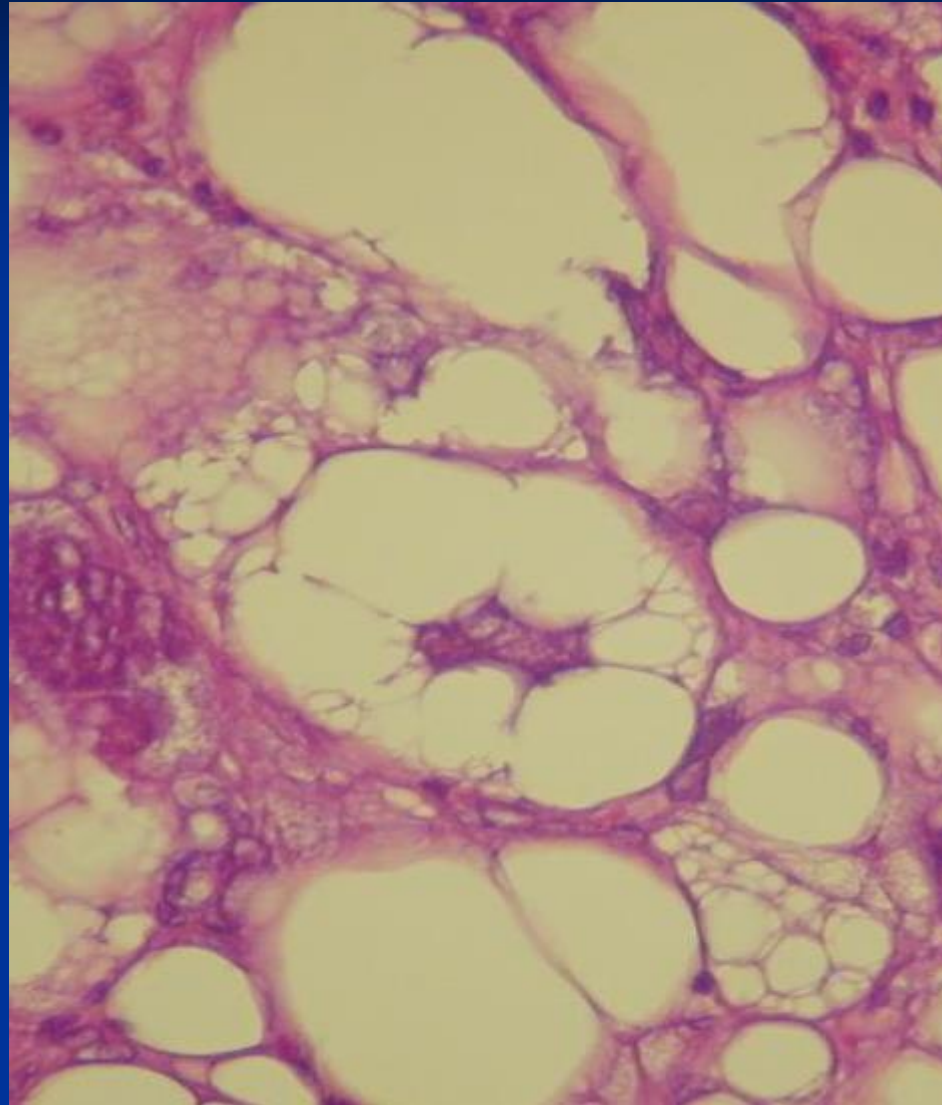
Liposarcoma Variants

- Myxoid LS homogeneous and majority of lesion follows fluid SI on all sequences
- Myxoid LS may be misinterpreted as a cyst
- Round cell/Pleomorphic LS more heterogeneous
- Dedifferentiated LS
 - Look for focal nodular area of soft tissue within an otherwise well-defined fatty mass

Low Grade Well Differentiated Liposarcoma (Atypical Lipoma)

- **Definition:** Mature fat cells and almost always fibrous or myxoid tissue.
- **Lipoblasts:** Adipocytes have enlarged, irregular hyperchromatic nuclei; scattered throughout tumor.
- Low grade malignant lesion
- Do not metastasize
- Grow slowly
- Potential to dedifferentiate into a high grade tumor that can metastasize
- Higher potential for local recurrence than a lipoma

Lipoblast



Well Differentiated Liposarcoma (Atypical Lipoma)

- **Age:** Adults (middle age to older adults)
- **Sites:**
 - Intermuscular/Intermuscular most common
 - Thigh: most common
 - Arm
 - Buttock
 - Retroperitoneum
 - Subcutaneous: rare

Well Differentiated Liposarcoma (Atypical Lipoma)

- Clinical:
 - Painless mass
 - Soft to firm depending on amount of fibrous tissue
 - Can grow very large
 - Abdominal swelling—retroperitoneal tumors

Lipoma vs. WDLS

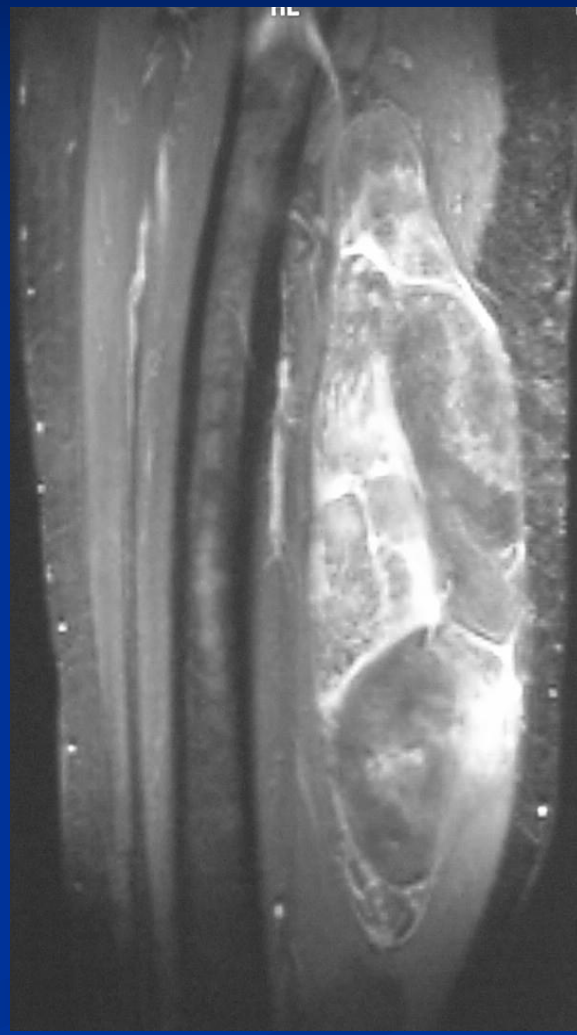
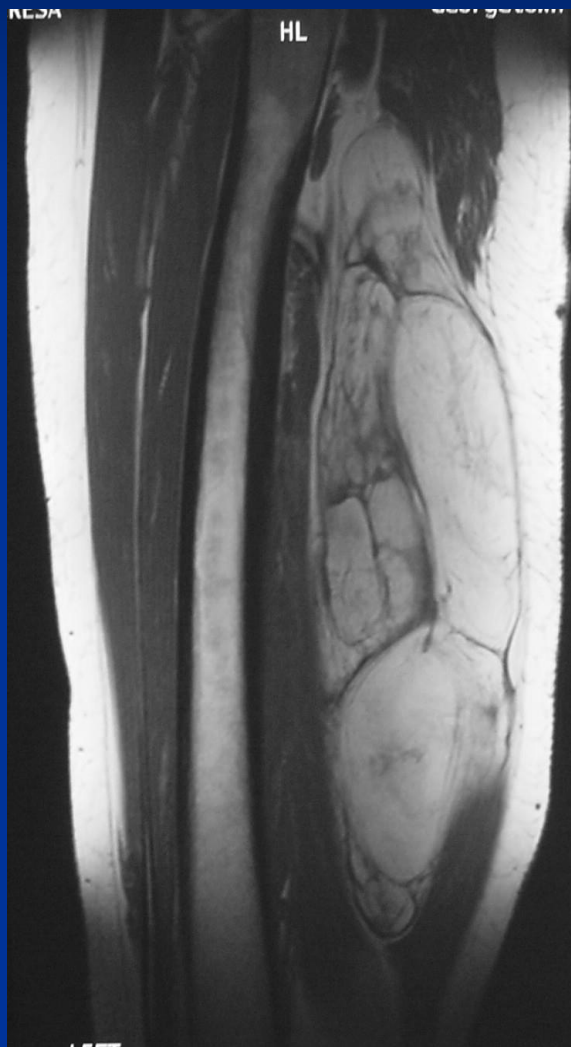
- Thickened septae WDLS
- Nodular/irregular/globular areas of nonadipose tissue
- Associated nonadipose mass
- Total amount of nonadipose tissue $>25\%$
- Marked enhancement of nonadipose portions
- Older patient/large size

Radiology

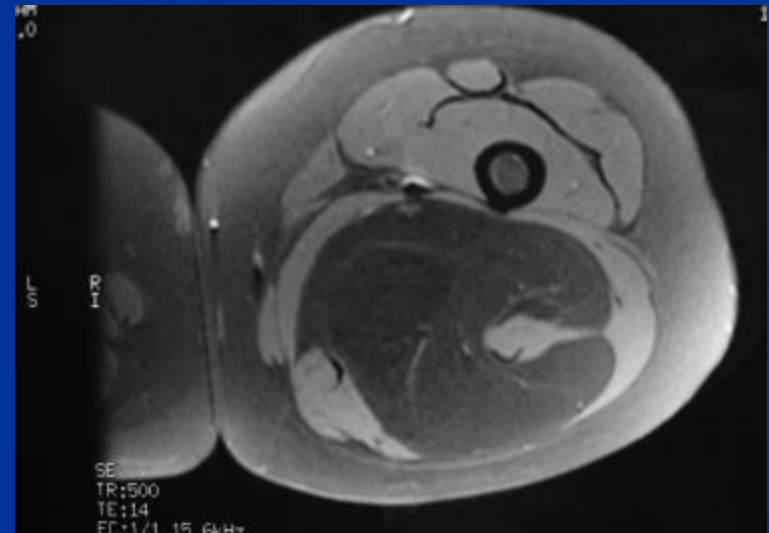
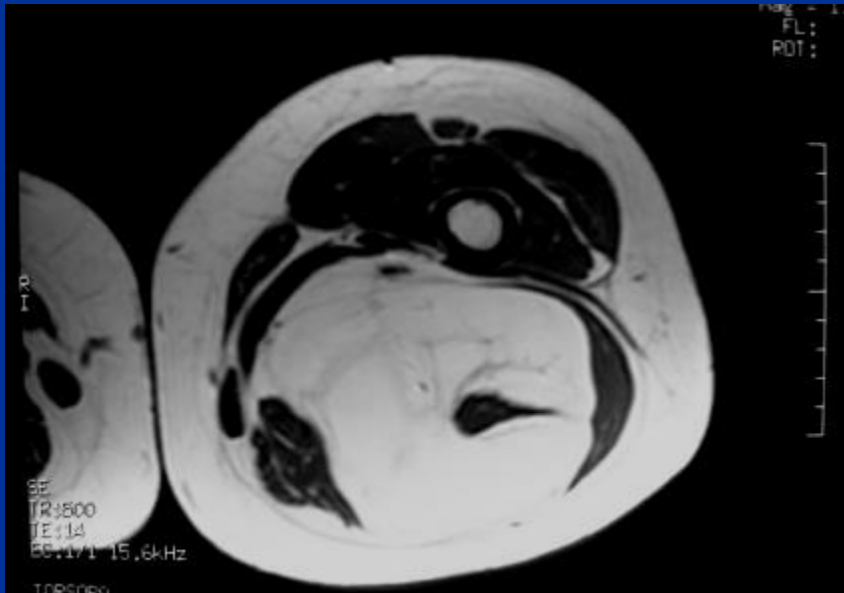
Well Differentiated Liposarcoma

- CT:
 - Nonspecific soft tissue mass with fat and soft tissue elements
 - May enhance with contrast (lipomas do not enhance)
- MRI:
 - Predominantly fat on all sequences (T1, T2) with irregularly thickened linear or nodular septa
 - The septa are low signal T1 (similar to muscle) and high signal T2

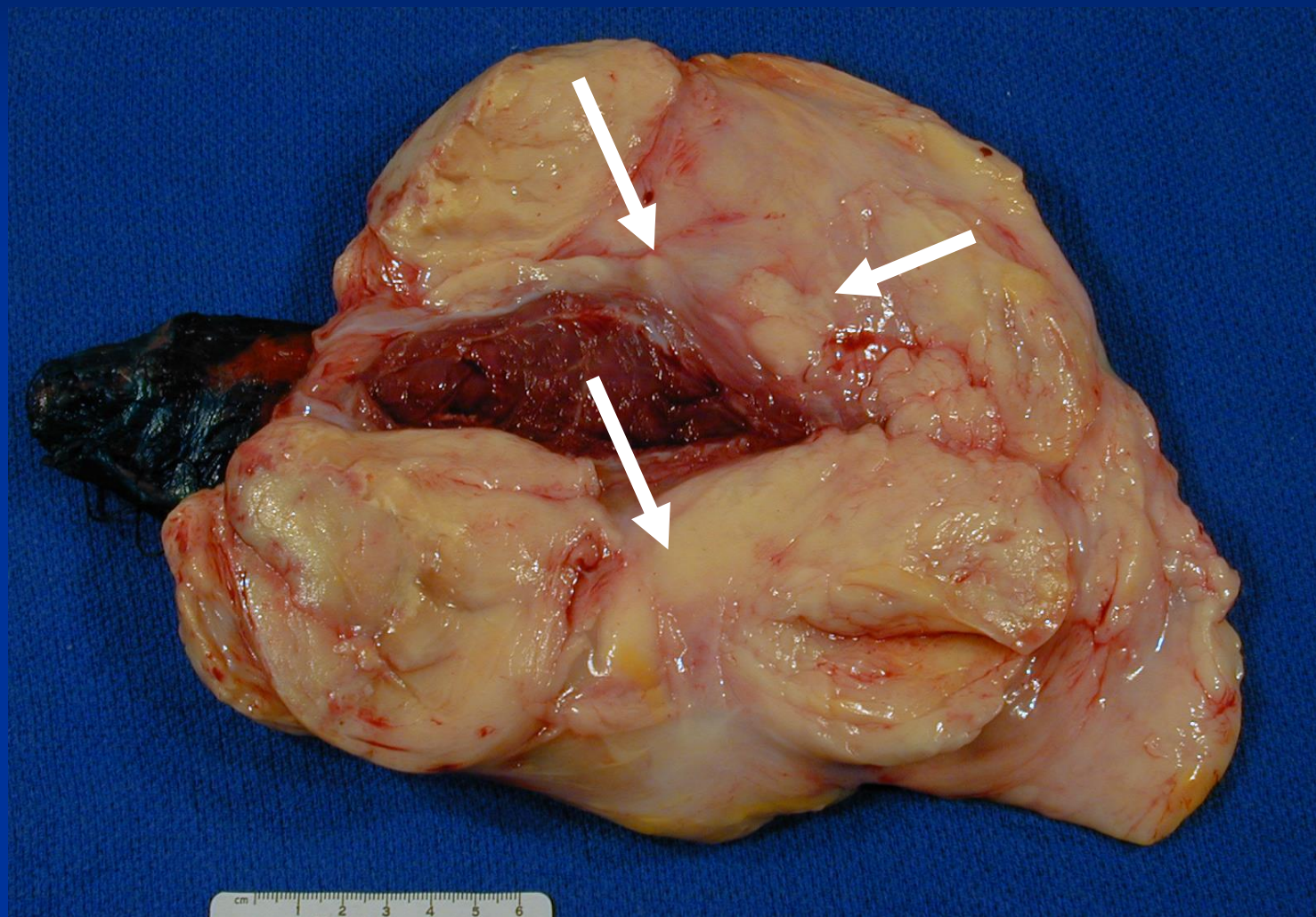
Well-differentiated Liposarcoma



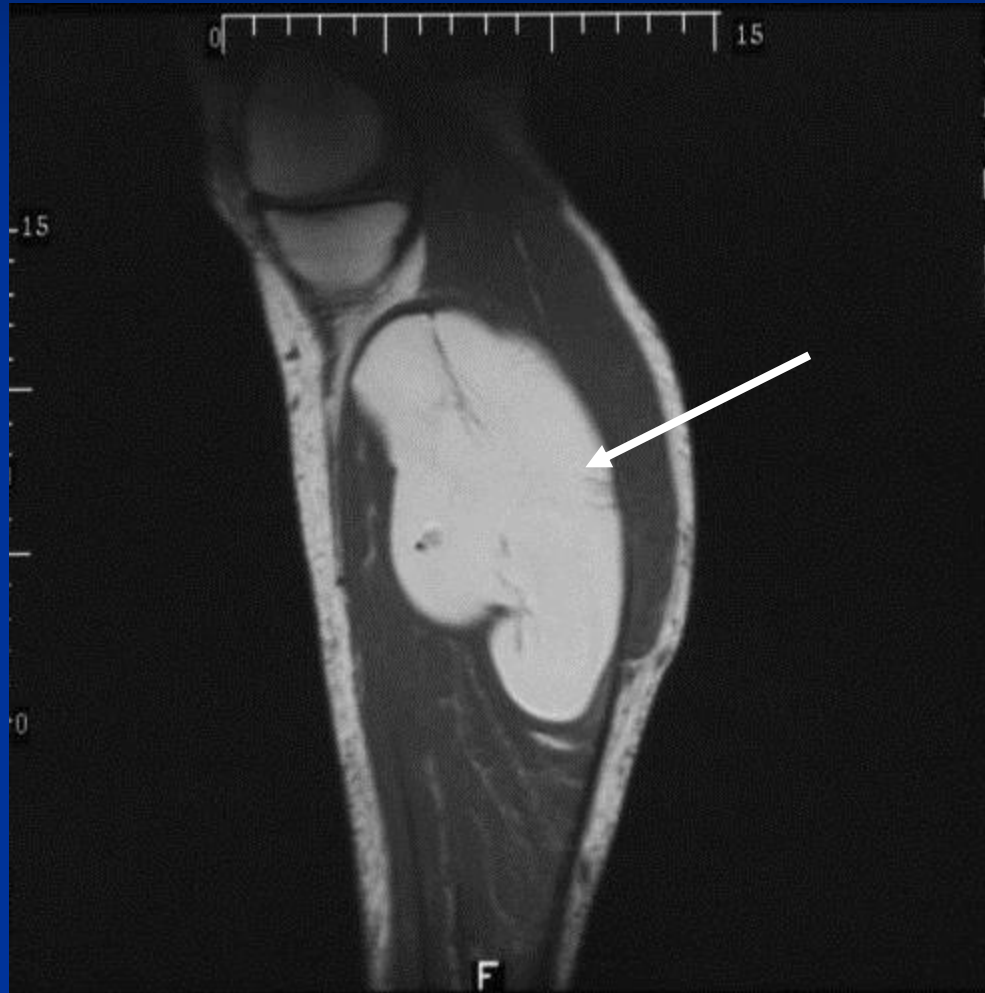MRI: Well Differentiated Liposarcoma



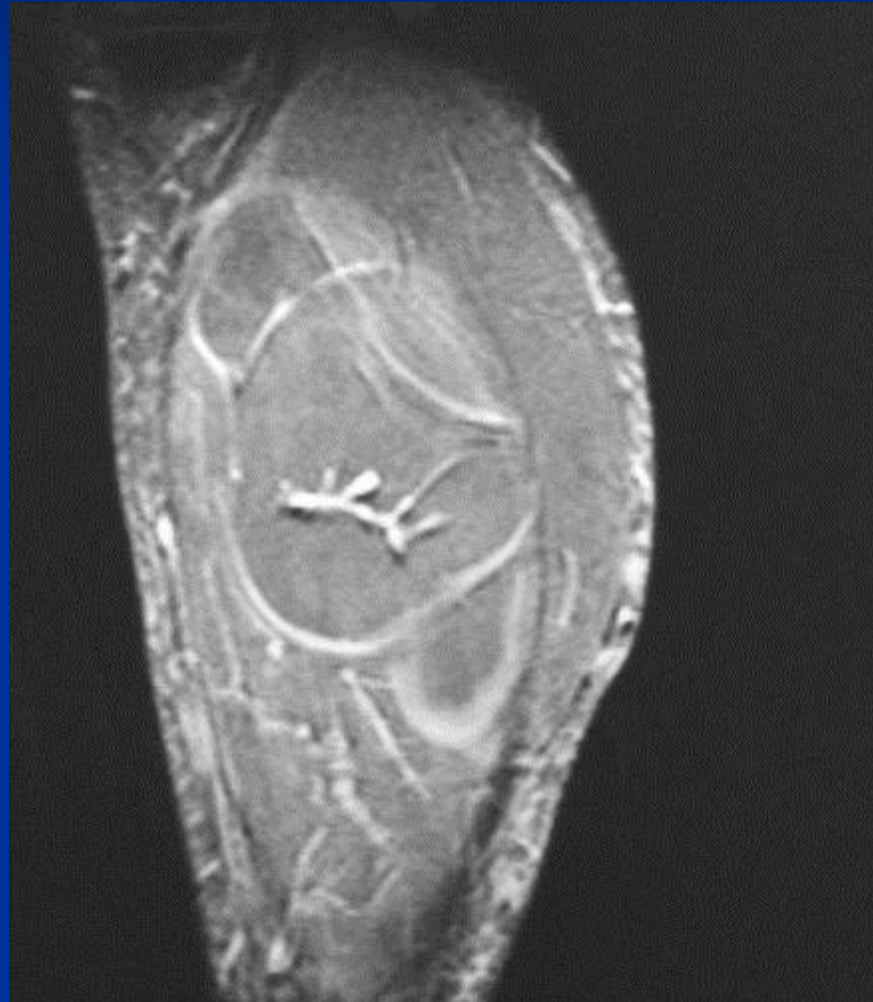Well-differentiated Liposarcoma



MRI T1: Well Differentiated Liposarcoma of Calf

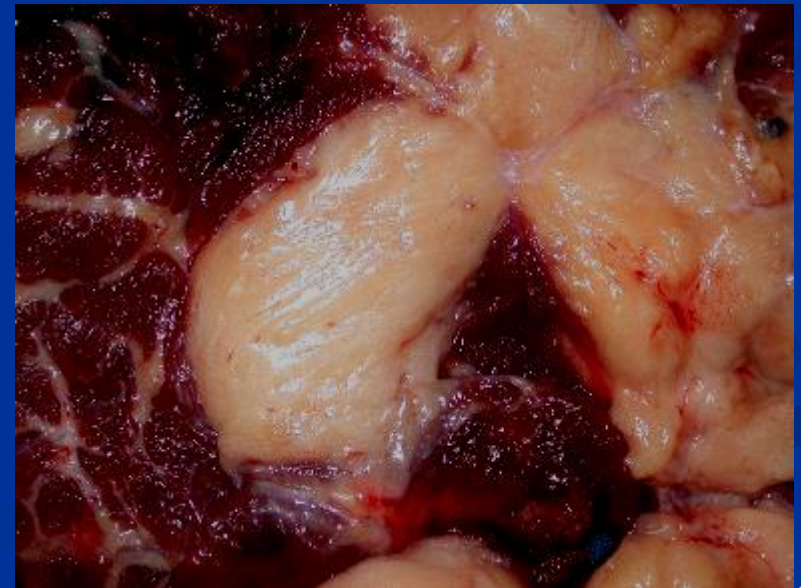
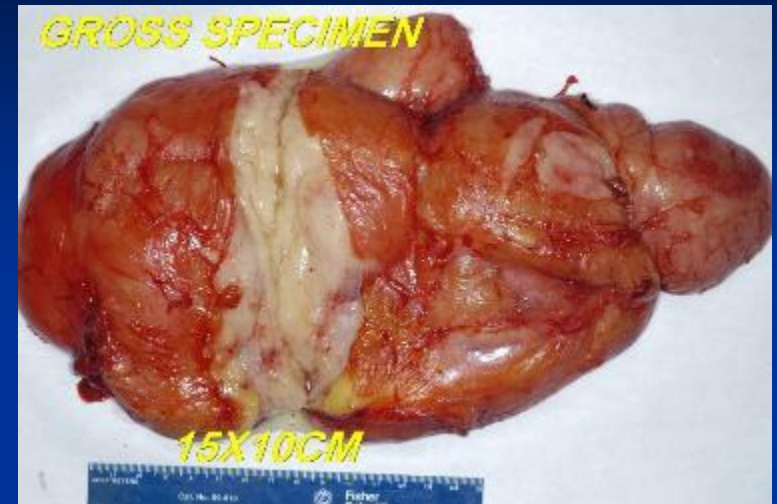

MRI T2: Well Differentiated Liposarcoma



Gross Specimen Well Differentiated Liposarcoma

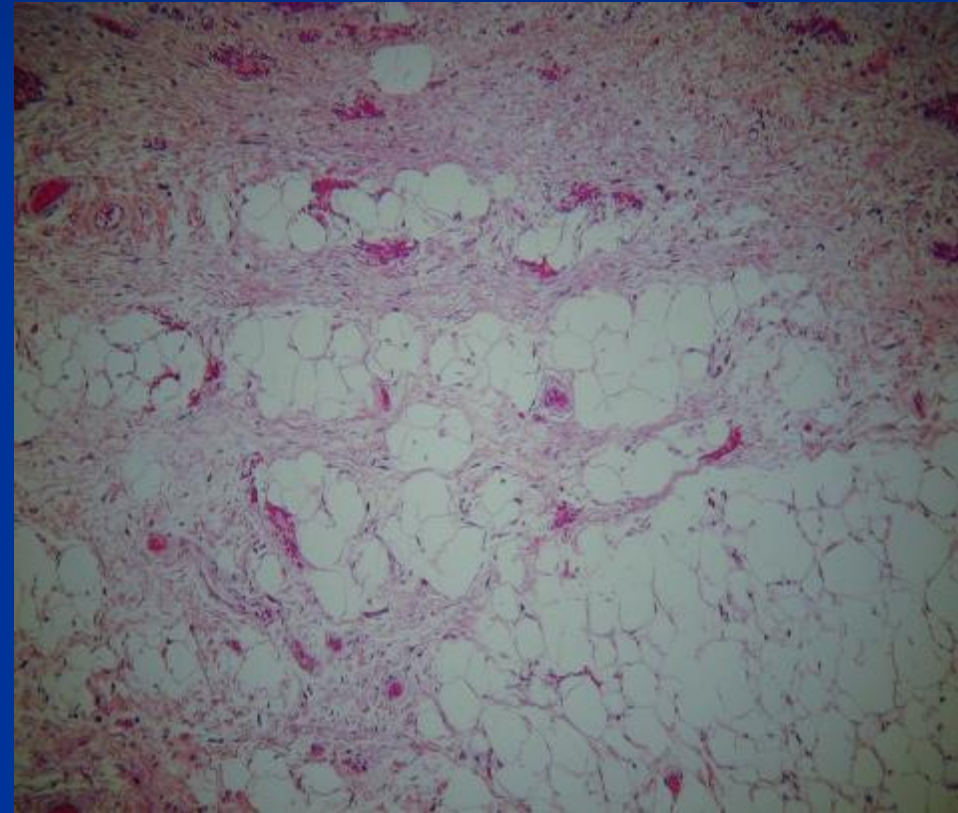
- Gross Path:
 - Yellow, mature appearing fat mixed with fibrous and myxoid tissue



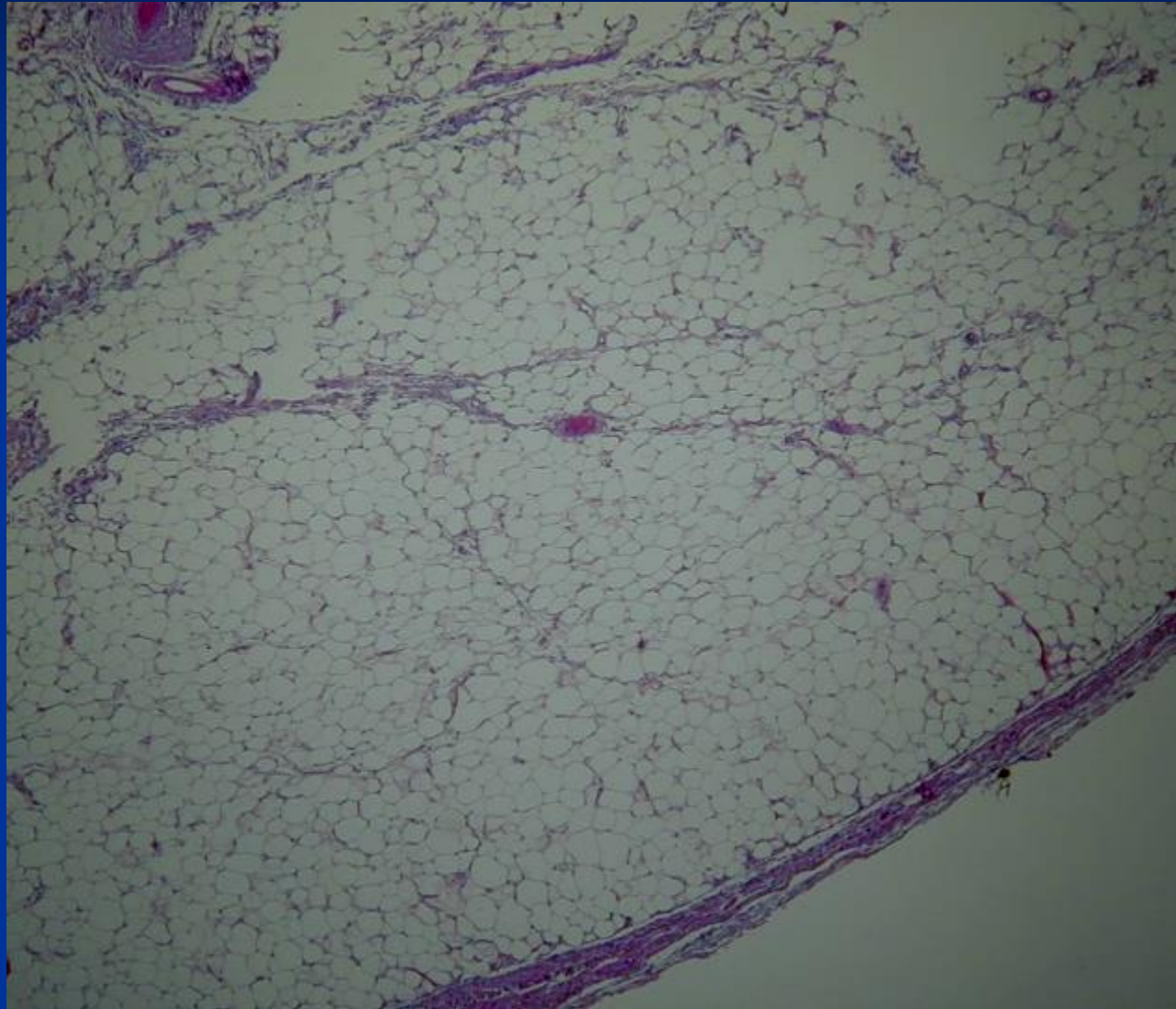
Pathology

Microscopic Pathology:

- **Lipoblast:** scattered fat cells with irregular, dense nuclei and often multiple cytoplasmic fat vacuoles
- Adult, mature fat cells, variable sizes
- Variable amounts of fibrous and/or myxoid with scattered cells with irregular nuclei
- Rare mitoses but may be enlarged and atypical

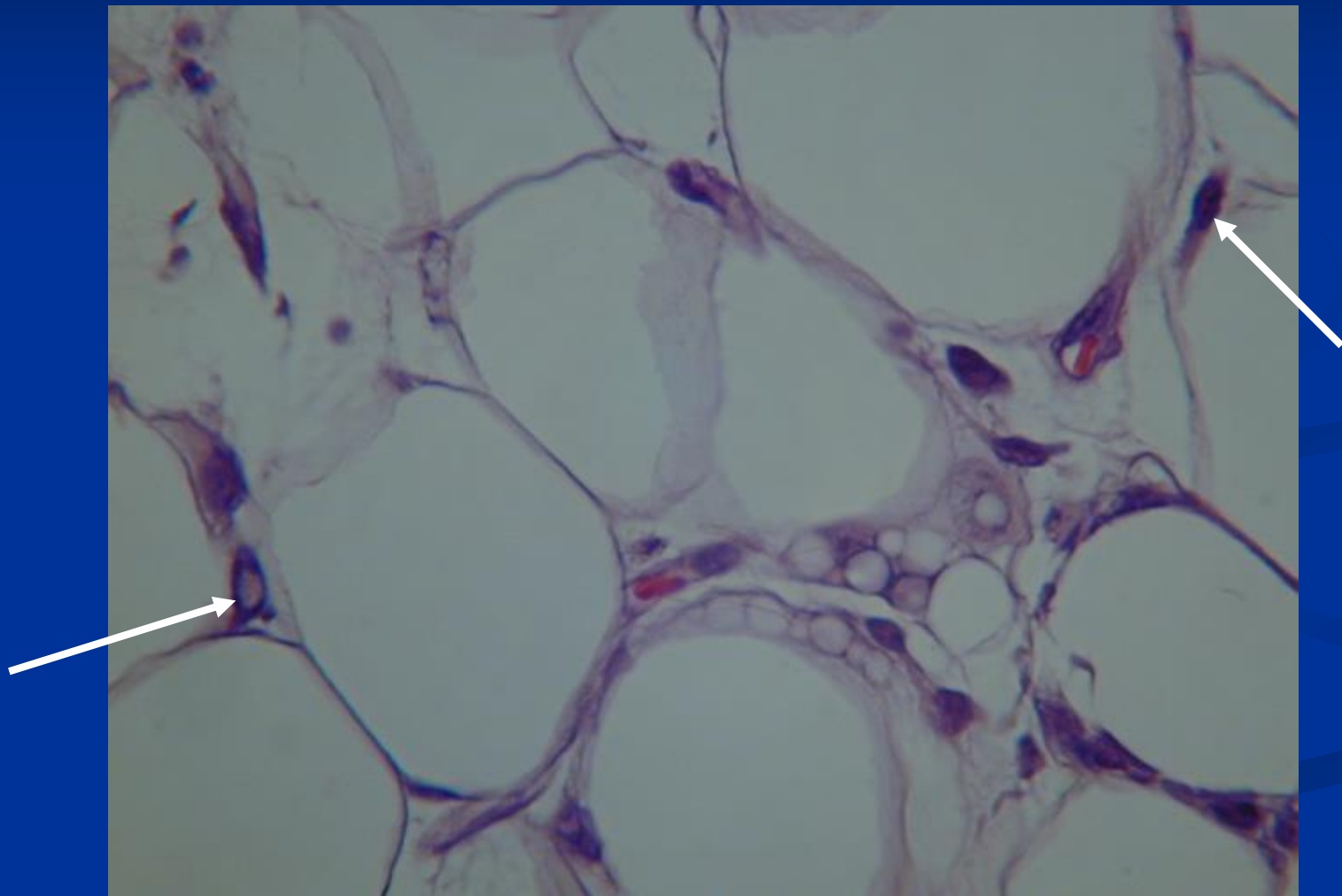


Well Differentiated Liposarcoma



Well Differentiated Liposarcoma

Lipoblasts



Treatment and Prognosis

- Surgery: Wide surgical excision
- Does not metastasize: 100% 5 year survival
- Recurrence occurs 10-20% with intramuscular tumors
 - Recurrence depends on size of tumor and location
 - May take years to recur (median time: 42 months)
- Dedifferentiation is a rare event but can occur with recurrences
 - MFH is most common dedifferentiated component

Myxoid Liposarcoma

- **Definition:** Variably cellular, fatty tumor that contains small, uniform, “signet ring” lipogenic tumor cells in a myxoid matrix
- The amount of adipose tissue may be scant
- Also contains small uniform non-fatty cells with scant cytoplasm
- Arborizing capillaries

Myxoid Liposarcoma

- Myxoid liposarcoma and round cell liposarcoma are a spectrum of the same type of tumor
- Round cell liposarcoma is a more cellular variant of myxoid liposarcoma
- Same Chromosomal Translocation
t(12;16)(q13;p11)
- Round cell liposarcoma is high grade and has greater metastatic potential
- Myxoid liposarcomas can have round cell components. If greater than 25% higher metastatic potential

Myxoid Liposarcoma

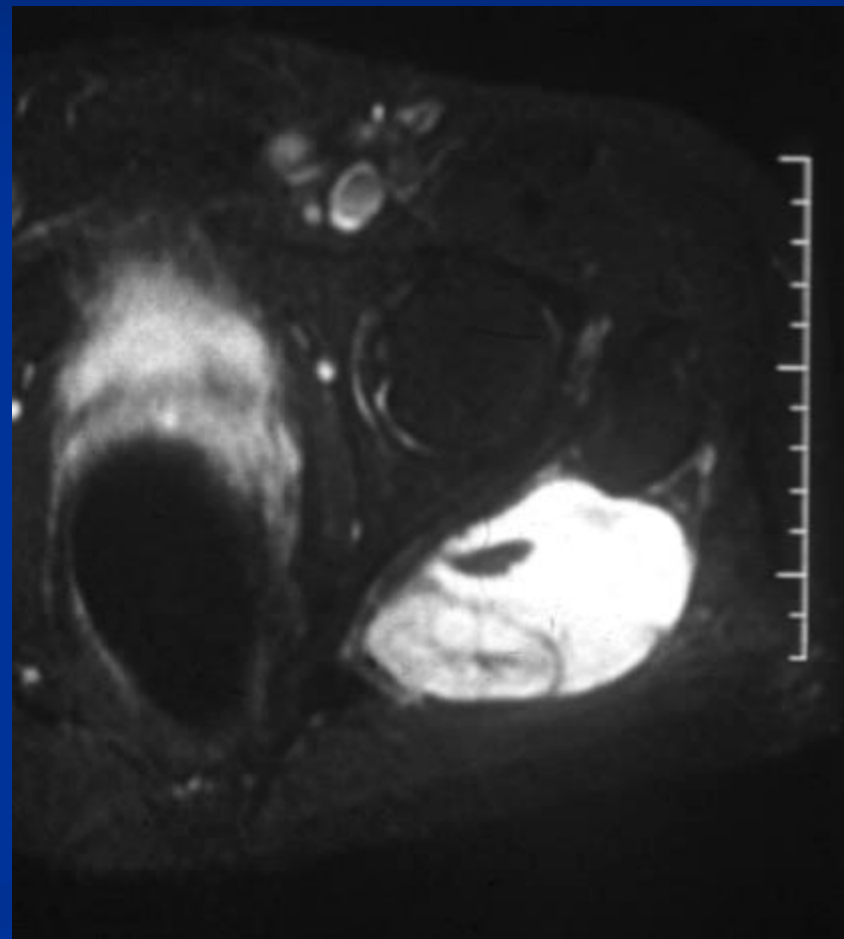
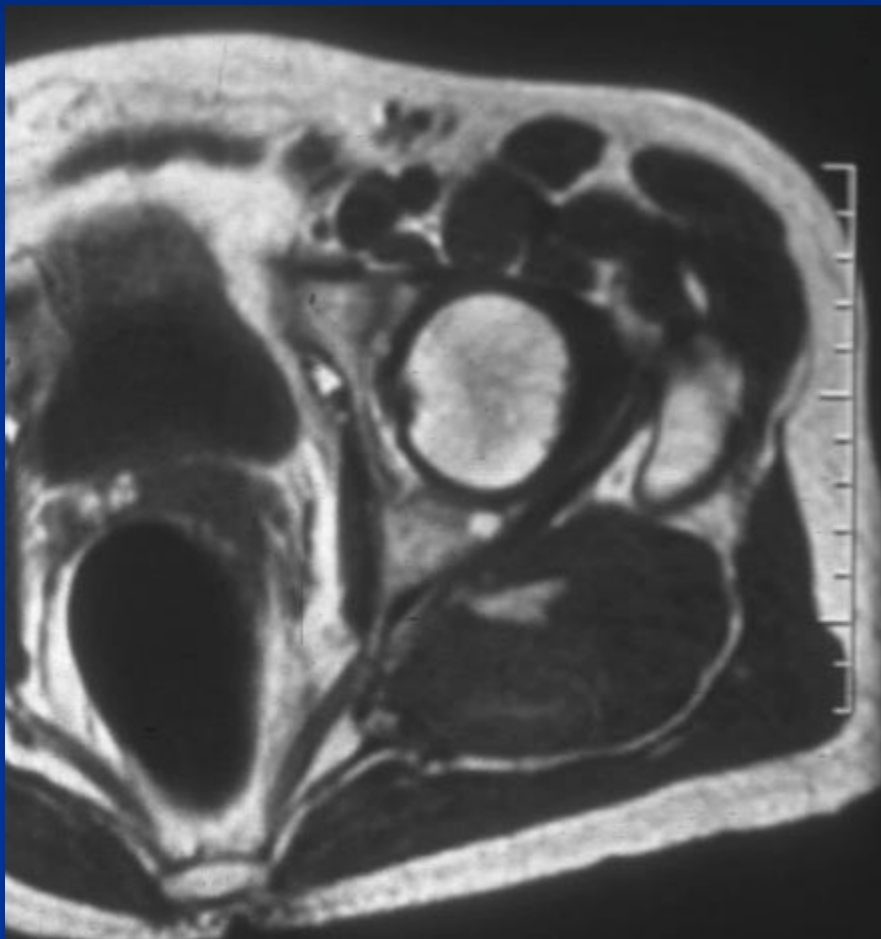
- 45-55% of Liposarcomas
- 40 to 50 years of age; rare <20 yrs of age
- **Sites:** Deep soft tissues (rare to occur in subcutaneous tissue)
 - Thigh
 - Buttock
 - Groin
 - Popliteal space
 - (unusual to occur in retroperitoneum)
- **Clinical:** Painless mass

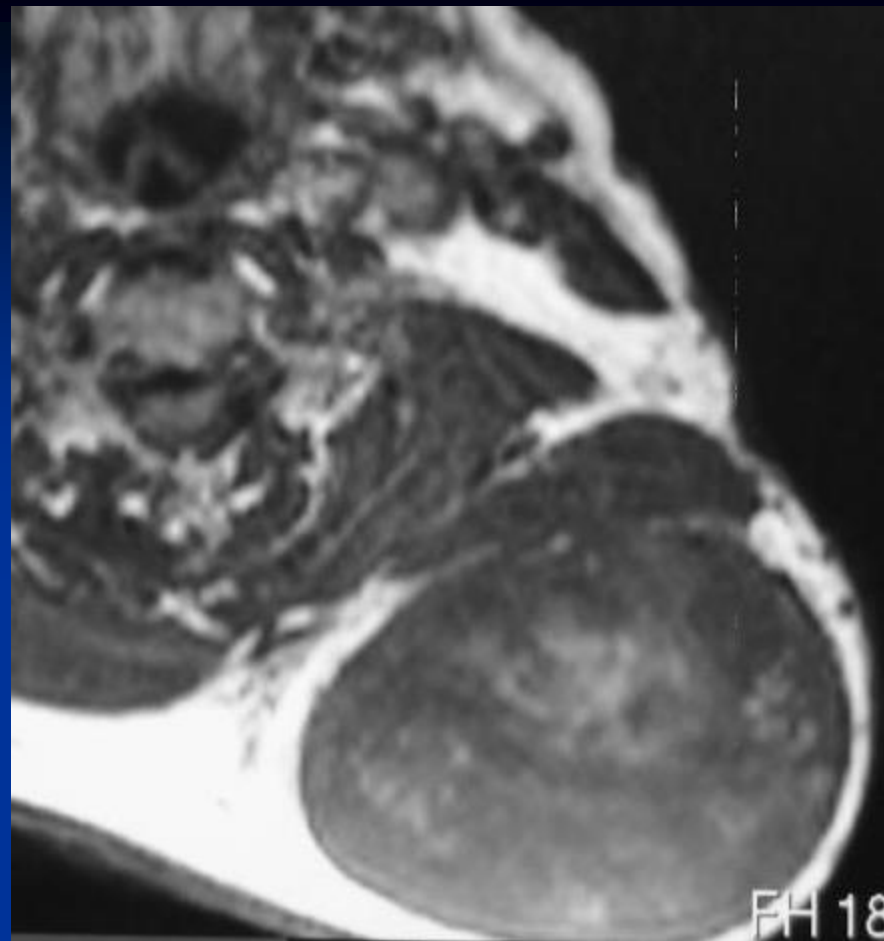
Radiology

Myxoid Liposarcoma

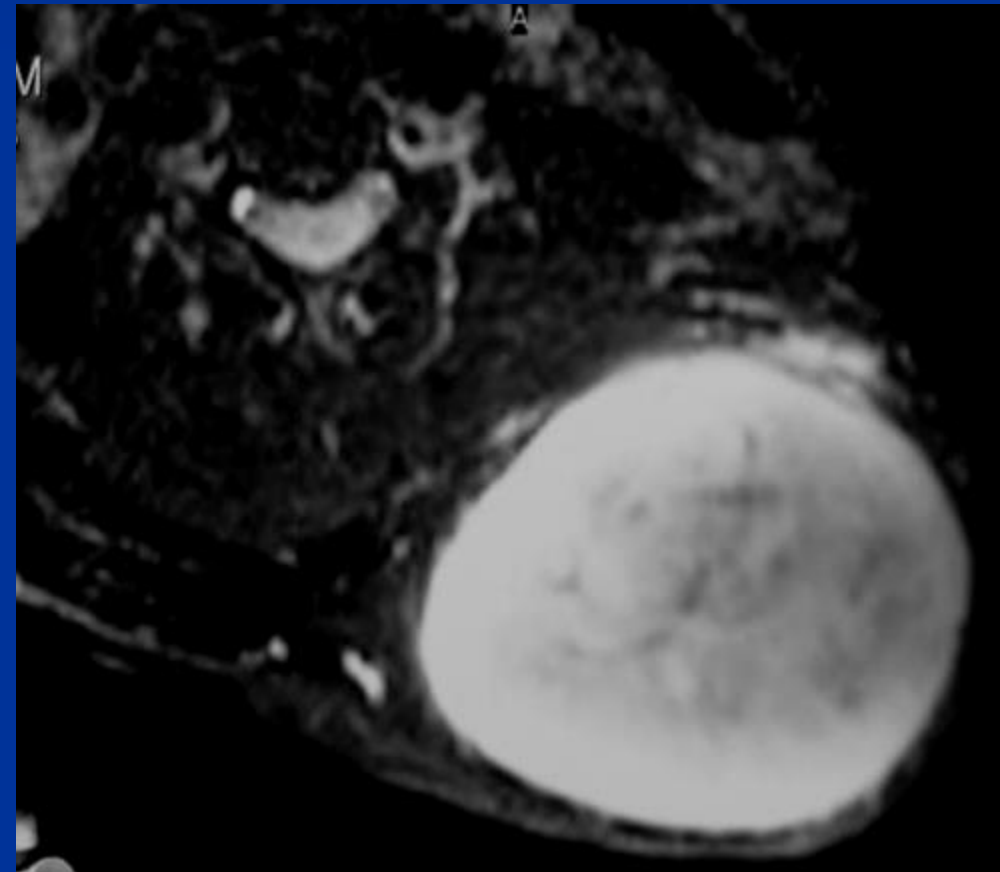
- MRI:
 - Does not contain substantial amounts of fat detectable on MRI (30%)
 - Follows **fluid signal** on MRI
 - T1: Intermediate signal similar to muscle
 - May see some high signal areas indicative of fat
 - T2: High Signal
 - Fat Suppressed: High signal areas on T1, suppress on T2 if truly fat
 - Fat if detectable: lacelike, wispy, cloudy, amorphous, clumplike
 - Often misdiagnosed as a cyst

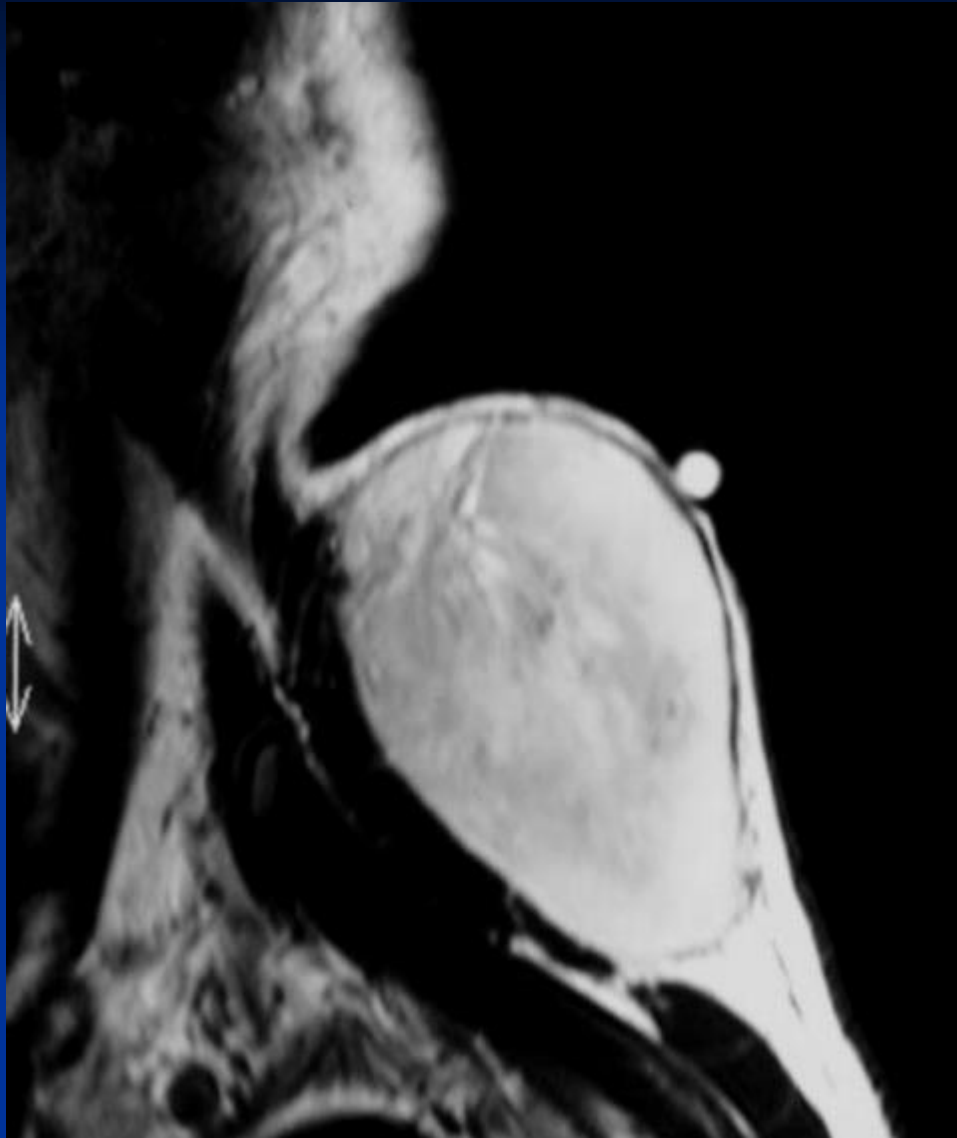
Myxoid Liposarcoma



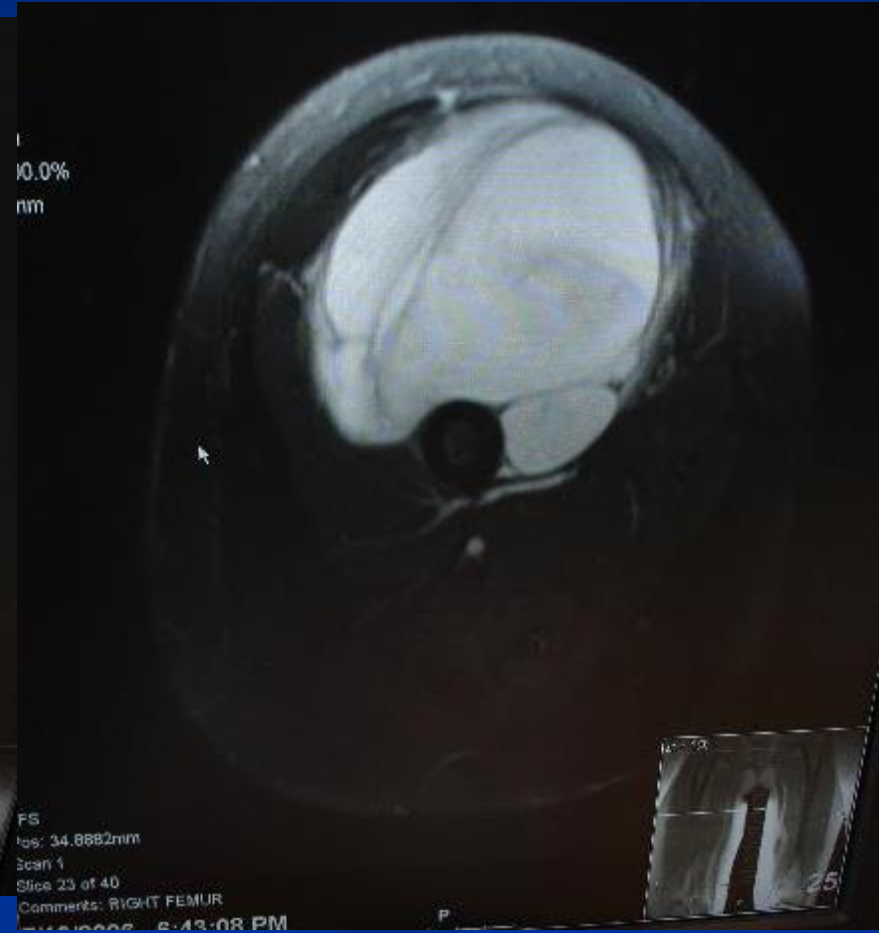
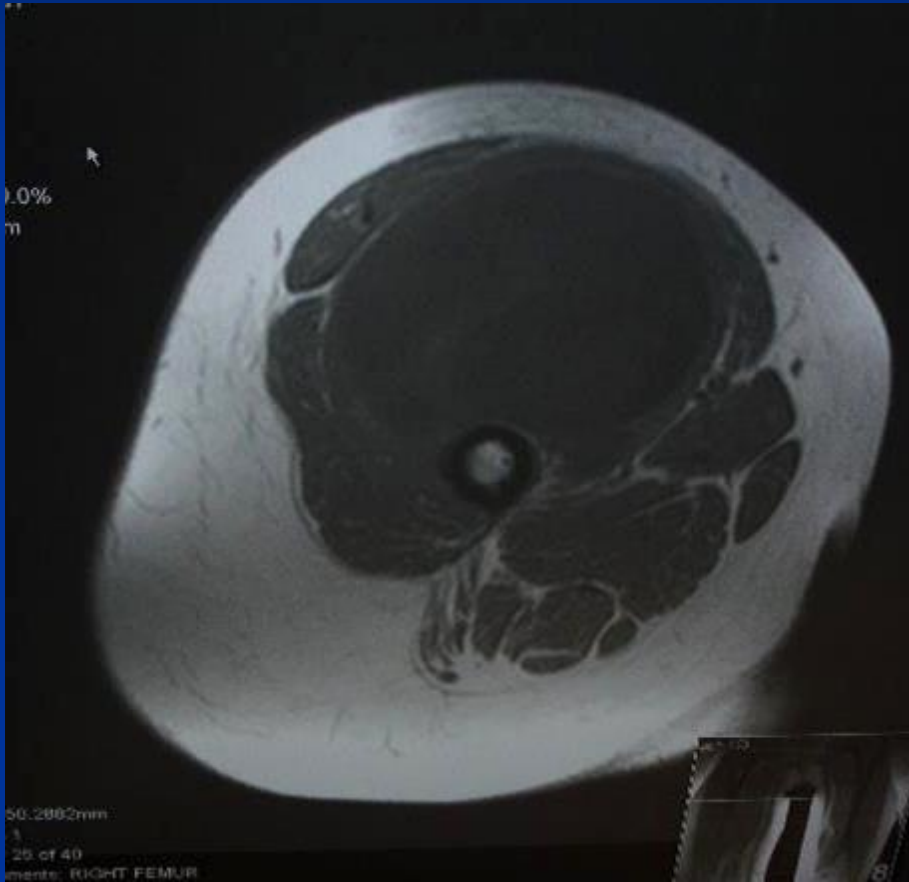


FH 18

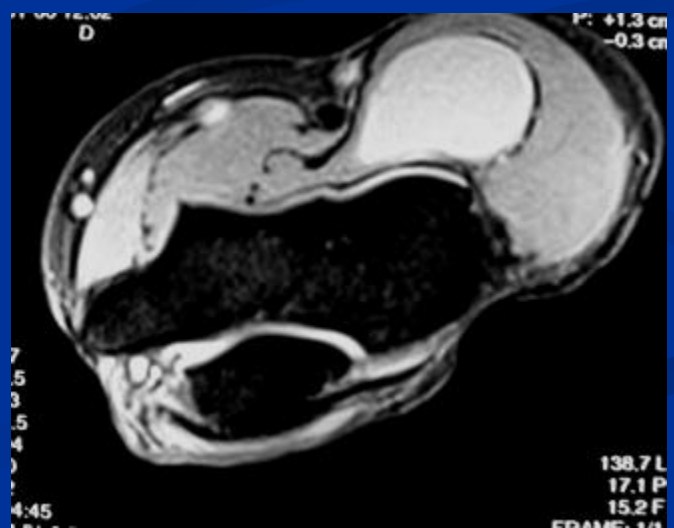
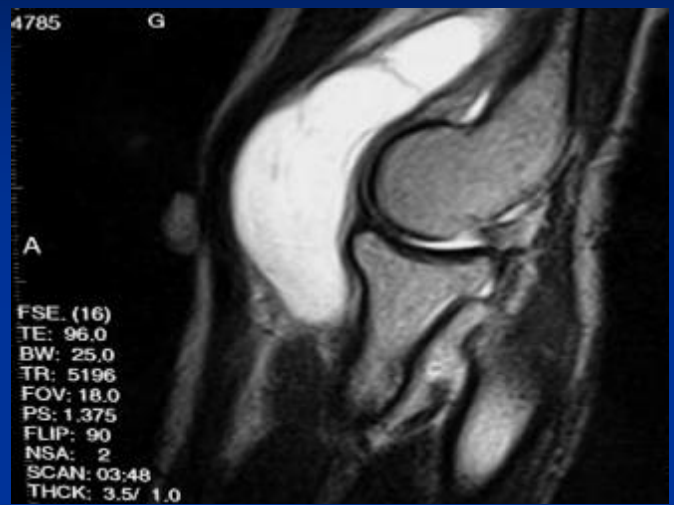
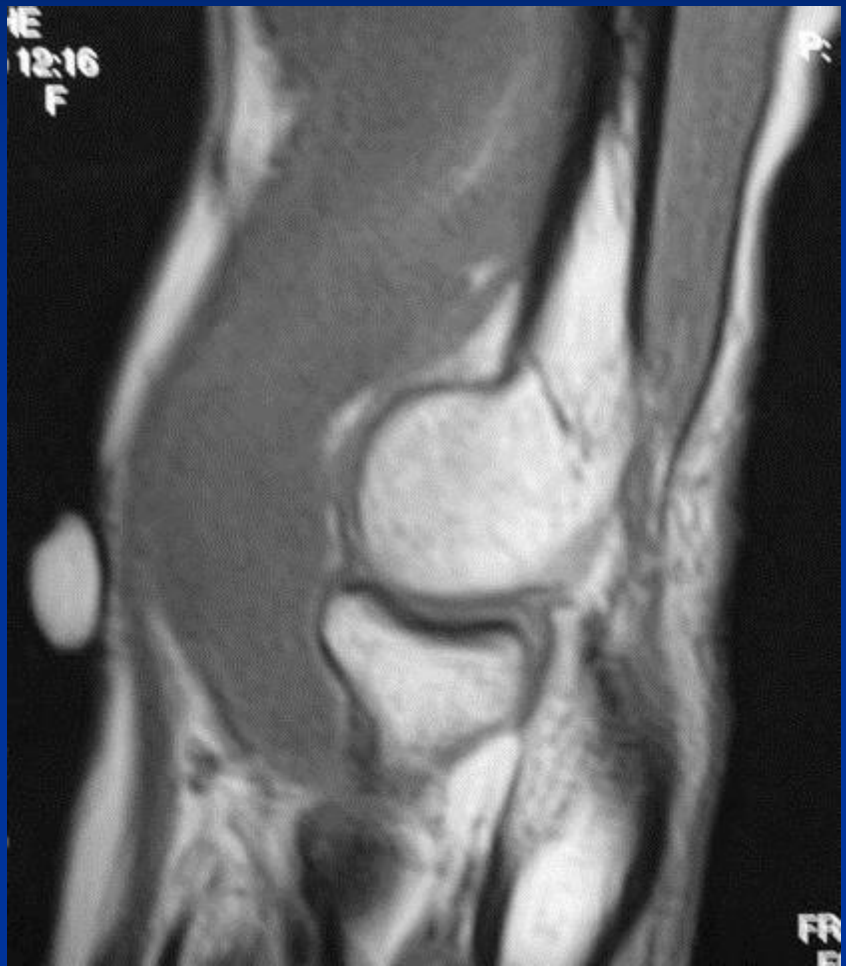



Myxoid Liposarcoma of Thigh



Myxoid Liposarcoma of Elbow Brachialis Muscle



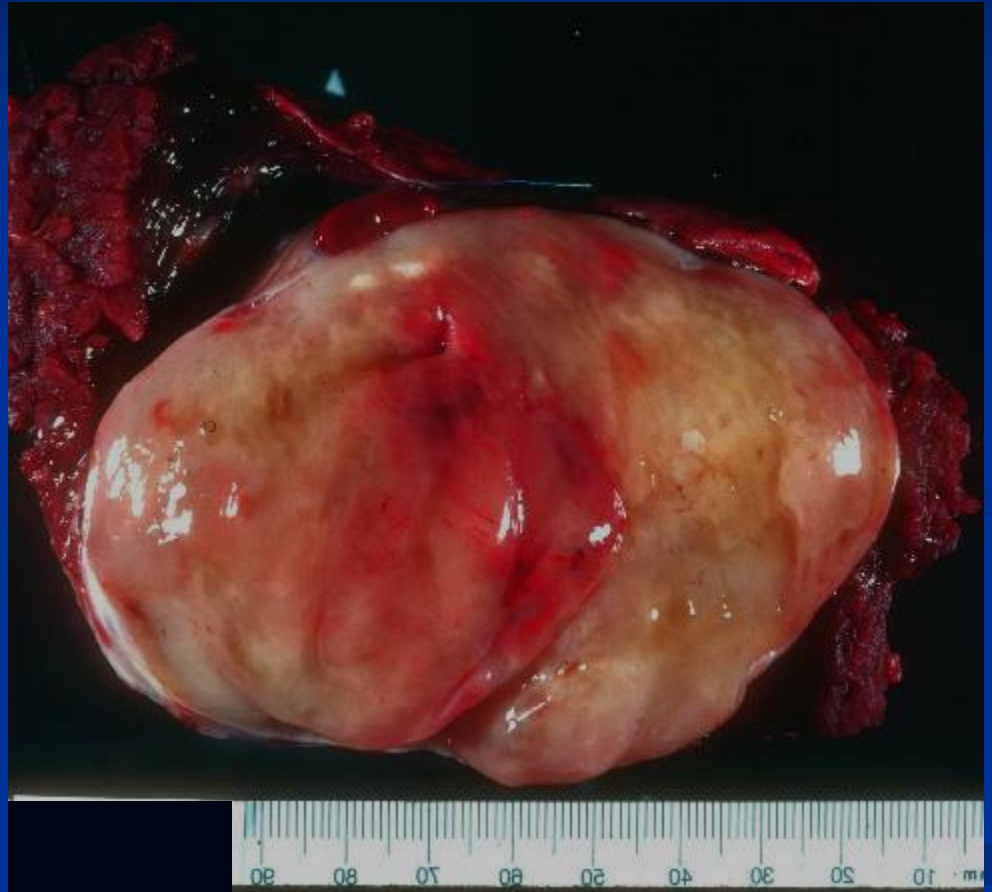DDX Myxoid ST Tumors

- Myxoid MFH
- Myxoid liposarcoma
 - Most diff. to distinguish/look for fat
- Neurogenic tumors
- Myxoma (mild rim enhance. post contrast)
- ES myxoid chondrosarcoma
- Leiomyosarc. (nec. simulates myxoid tissue)

Pathology

Myxoid Liposarcoma

- Gross Path:
 - Slimy, gelatinous, mucous-like surface
 - Cellular (round cell) areas have fleshy sarcoma appearance



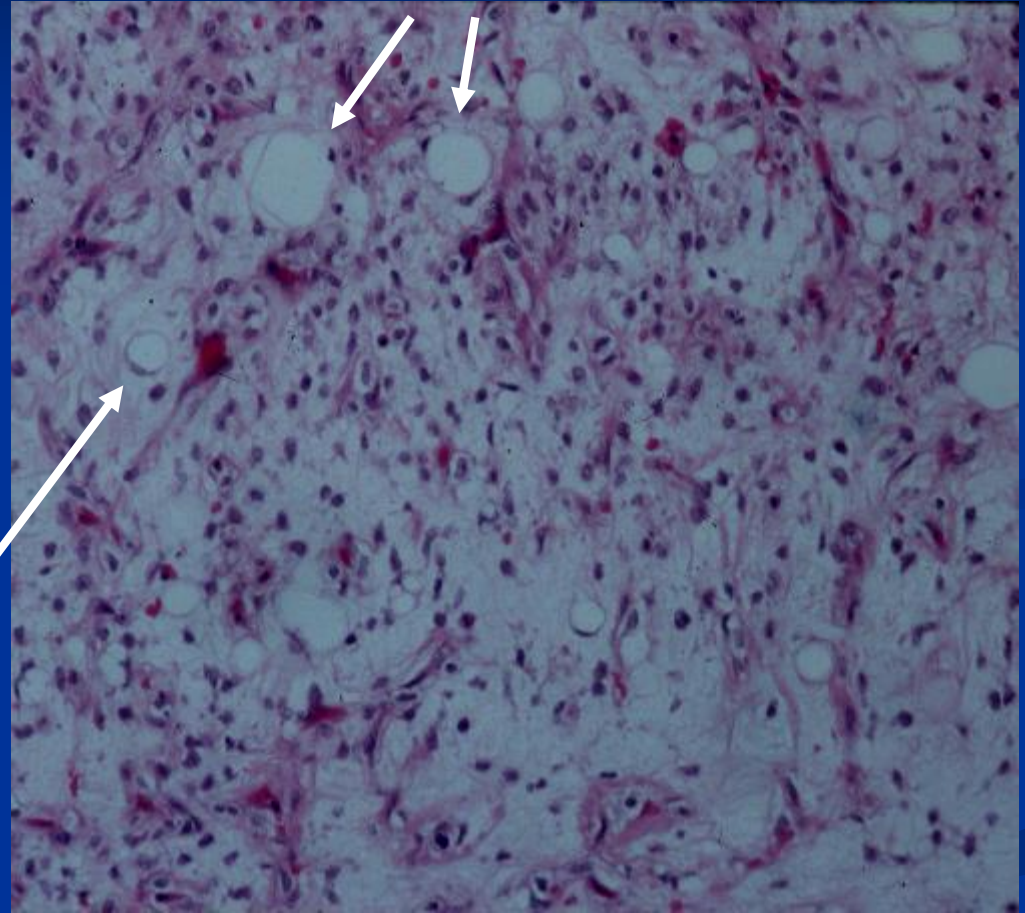
Pathology: Myxoid Liposarcoma

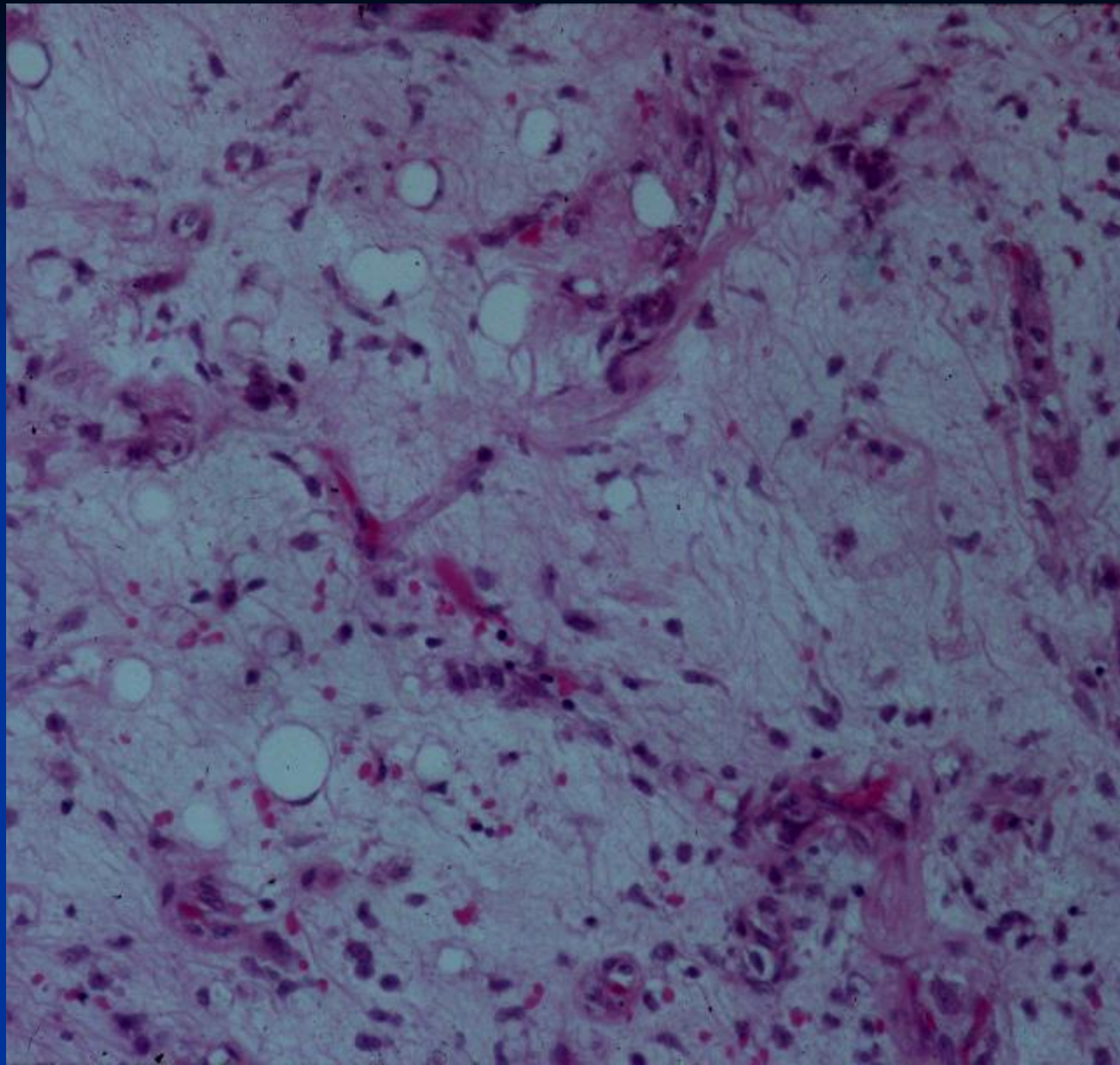
- Microscopic Path:
 - Small uniform cells with scant cytoplasm in **Myxoid Matrix**
 - Signet ring **lipoblasts**: nucleus deformed into crescent
 - Scattered adipocytes of various sizes
 - Few mitoses
 - Round cell areas—more cellular areas; more mitoses; more pleomorphism but not marked

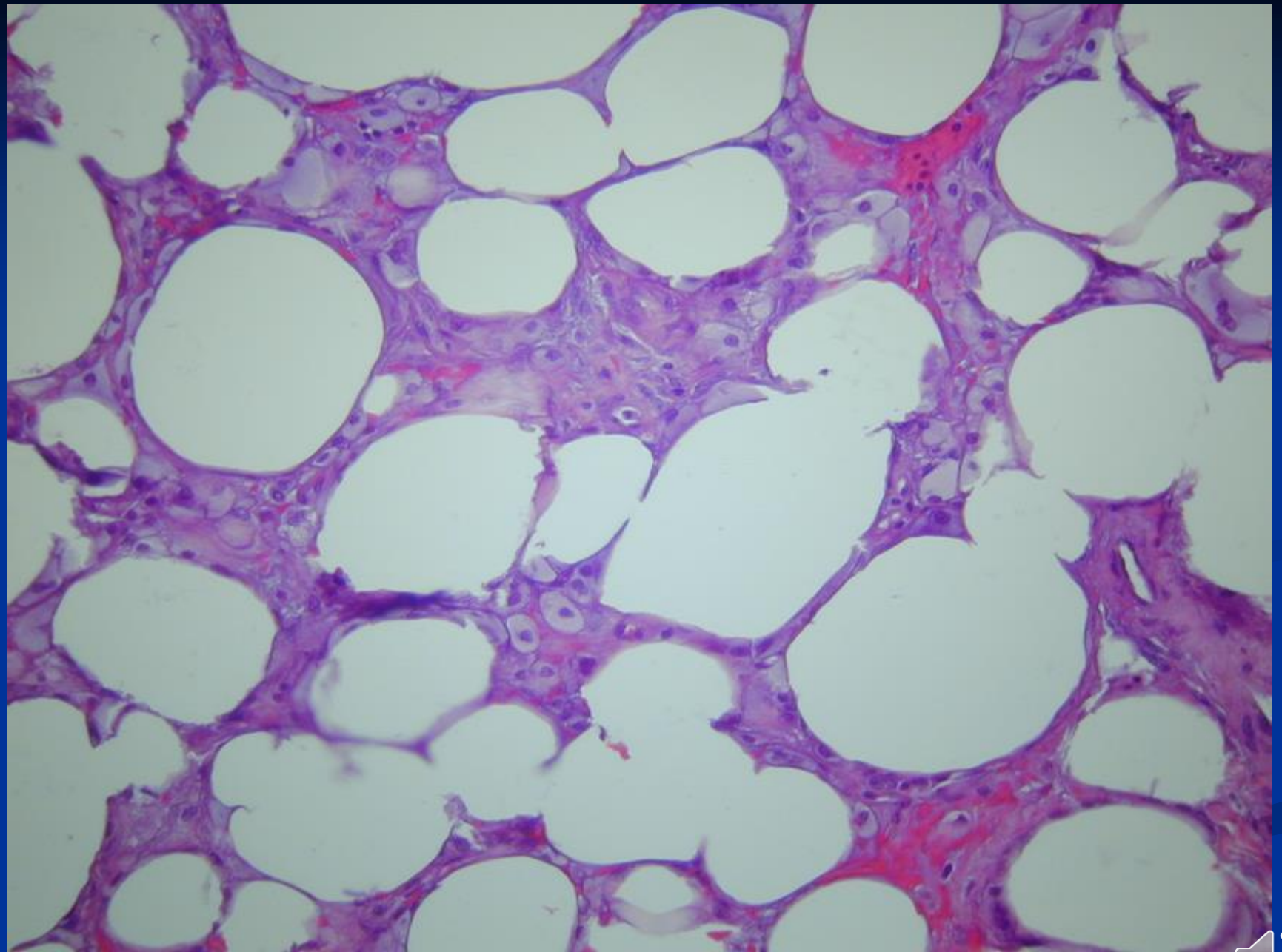
Myxoid Liposarcoma

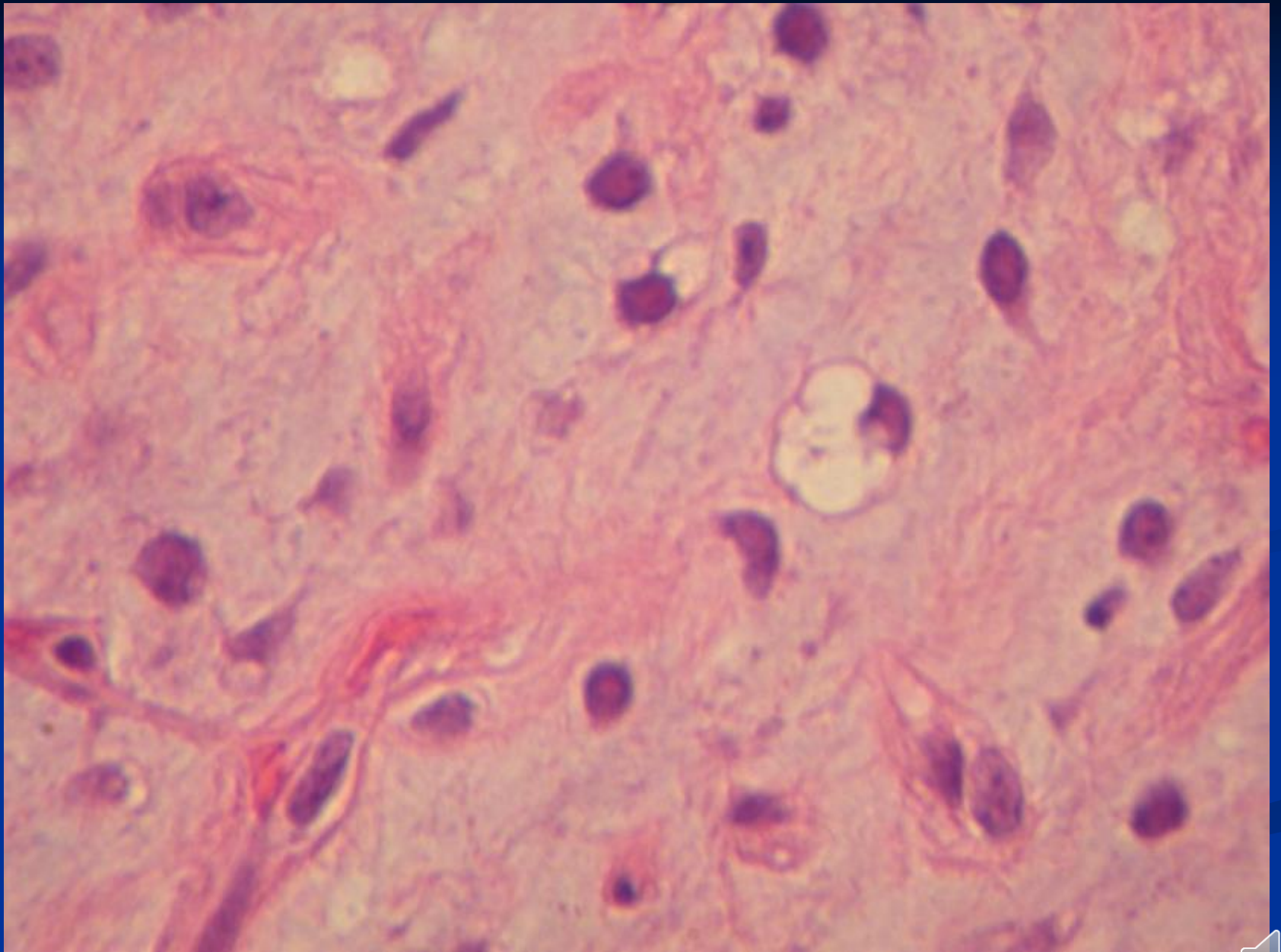
- Lipoblasts
- Myxoid Stroma
- Myxoid Cells
- Arborizing Capillaries

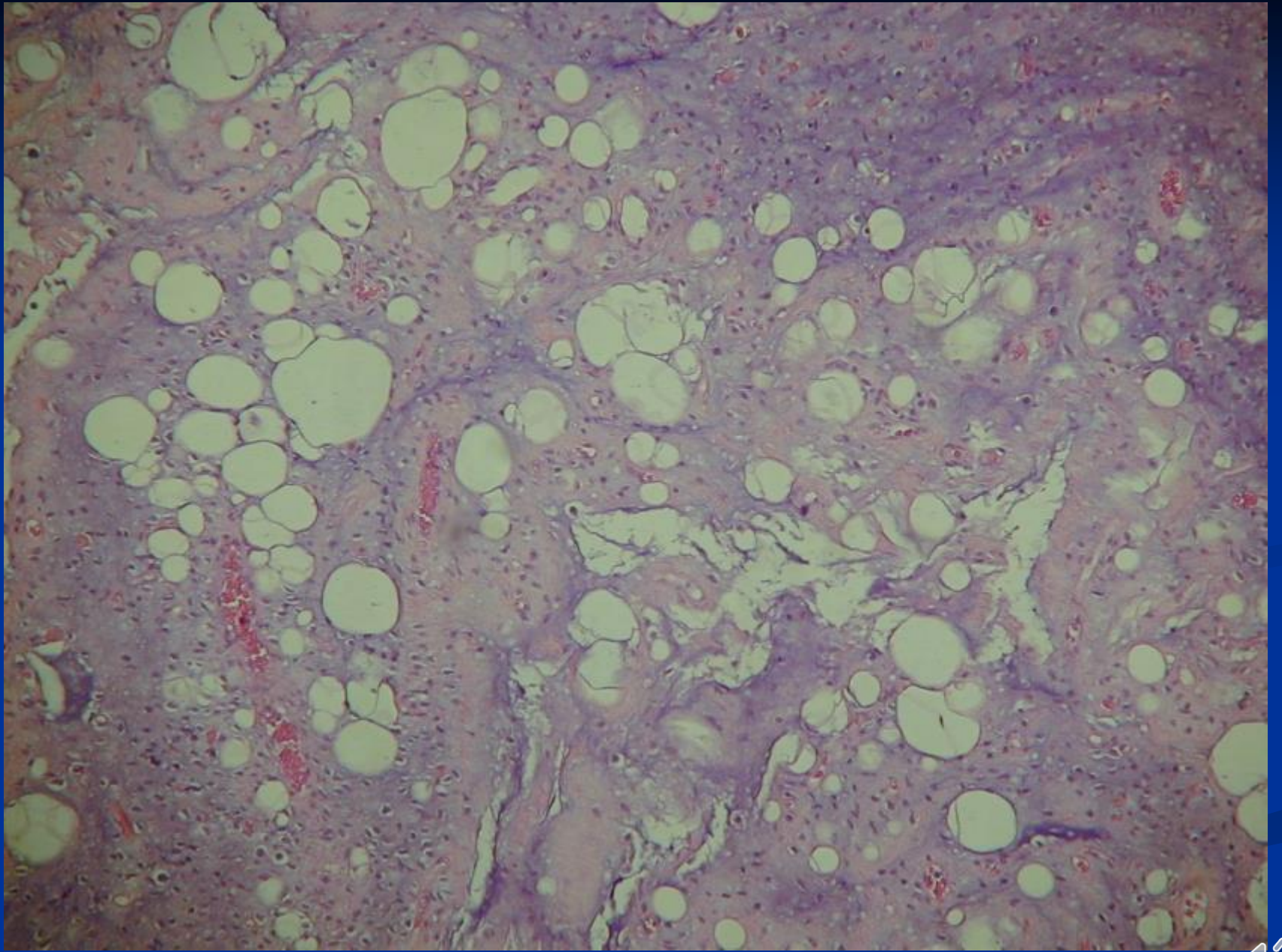
Signet Ring Lipoblasts

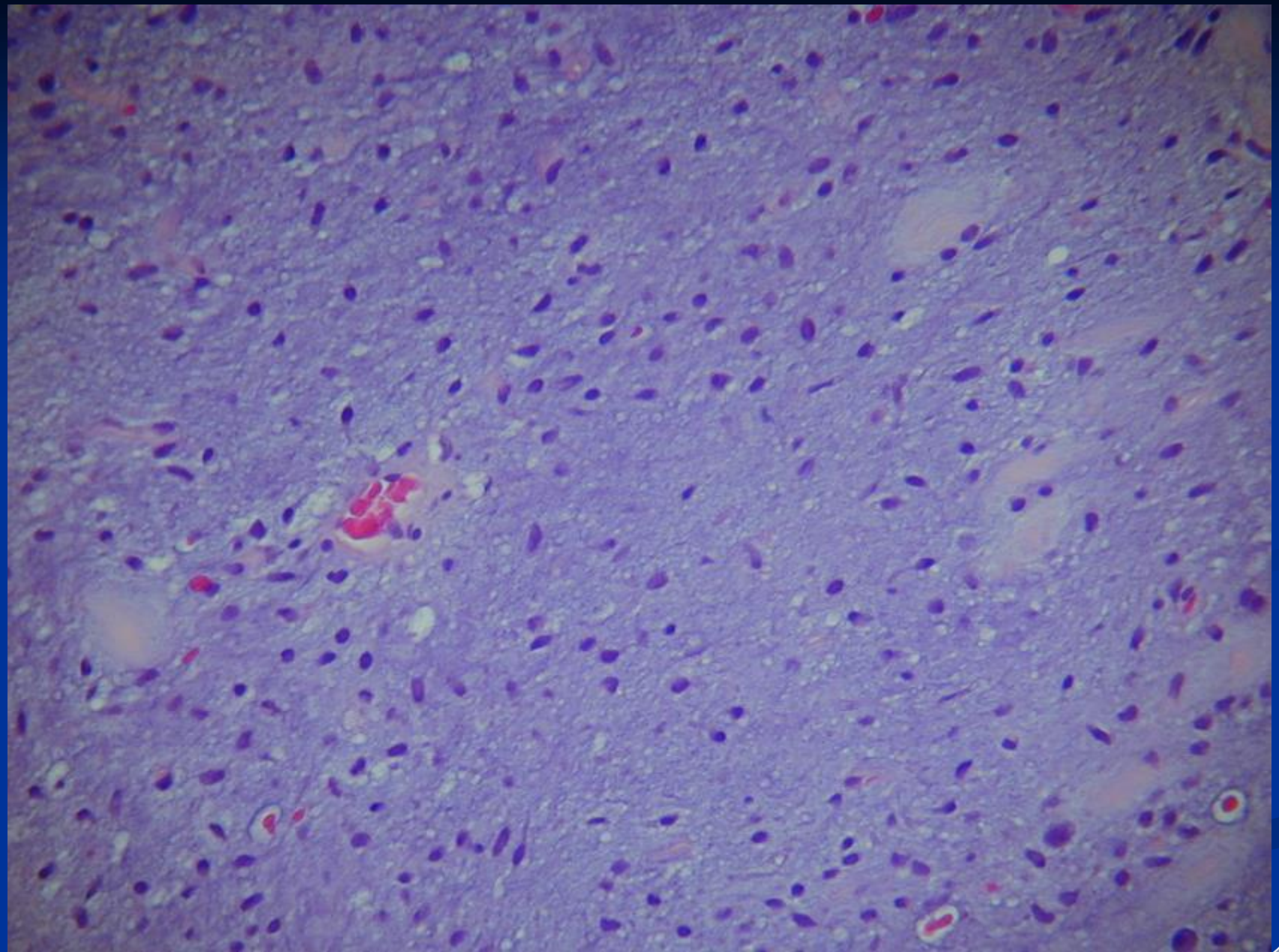












Treatment and Prognosis

- Surgery: Wide resection and postop radiation
 - High rate of local recurrence without RT
- Myxoid Liposarcoma is a low to intermediate grade tumor
- 88% 5 year survival for pure myxoid liposarcoma
- Rate of metastasis is related to proportion of round cell component
- Unusual pattern of mets
 - Distant soft tissues: Retroperitoneum, Mediastinum
 - Spine
 - Lungs

Malignant Fibrous Histiocytoma (MFH)

- **Definition:** Pleomorphic, high grade, anaplastic sarcoma composed of varying portions of fibroblasts, myofibroblasts, histiocyte-like cells, multinucleated giant cells and undifferentiated cells
- May have substantial myxoid components, inflammatory tissue and giant cell rich areas
- No recognizable line of differentiation such as smooth muscle, skeletal muscle, bone, cartilage, fatty differentiation

Malignant Fibrous Histiocytoma

- Most common ST sarcoma (20-30% of all soft tissue sarcomas)
- 70-75% occur in extremities/15% in RP
- Most common post XRT sarcoma (2/3)
- Occurs at sites of chronic ulcers and scars
- Association with shrapnel/total joint replacements
- Multiple subtypes
 - Pleomorphic
 - Myxoid
 - Giant Cell Variant
 - Inflammatory

Malignant Fibrous Histiocytoma

- Usually >50 years of age
- Rare in children
- Sites:
 - Deep soft tissue; Intramuscular—most common
 - Thigh
 - Buttock
 - Retroperitoneum
 - Shoulder Girdle
 - Calf
 - Trunk
 - Subcutaneous

Malignant Fibrous Histiocytoma (MFH)

- Clinical:
 - Painless mass
 - Rarely fever, weight loss but very unusual
 - Occasional leukocytosis, hypoglycemia and systemic manifestations

Radiology

Malignant Fibrous Histiocytoma

- Deep intramuscular mass (often adjacent to diaphysis of long bones)
- Osseous involvement can occur (Xray or CT)
- MRI:
 - Heterogeneous T1 and T2/large/lobulated/well-defined
 - Necrosis and hemorrhage
 - Intermediate SI on T1
 - Predominantly high SI on T2
 - Viable areas enhance with contrast

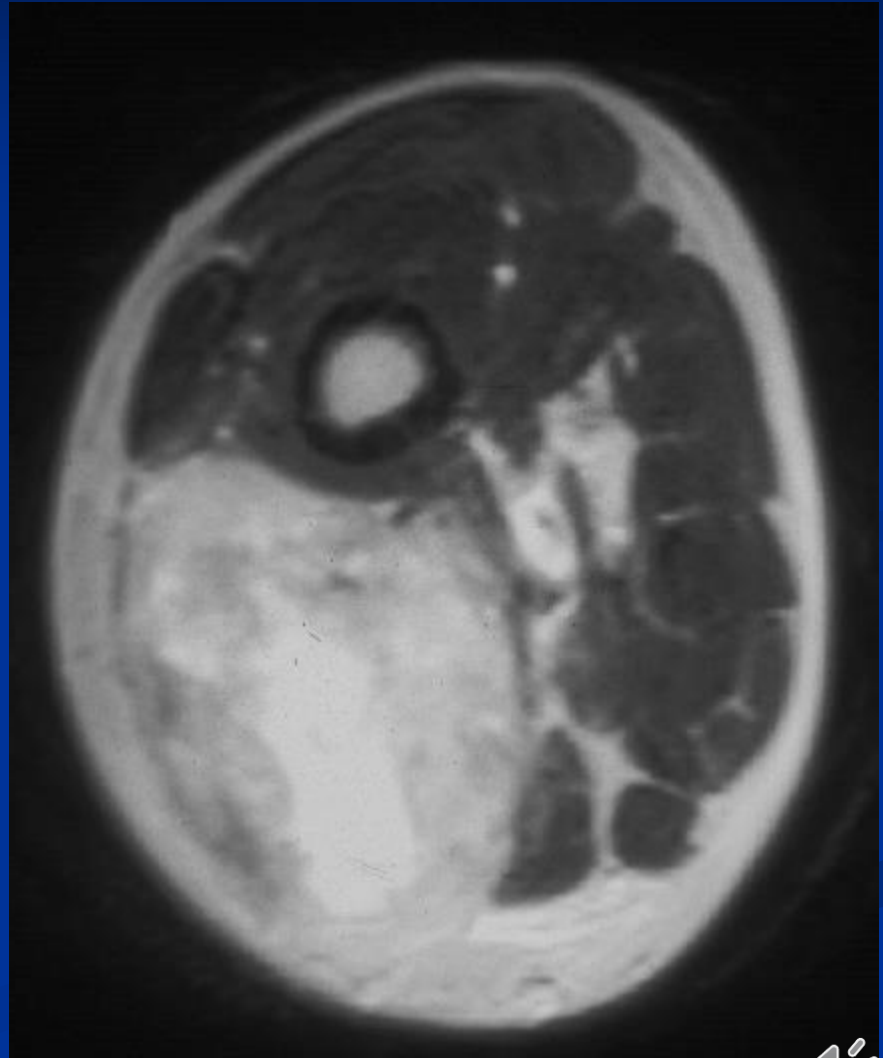
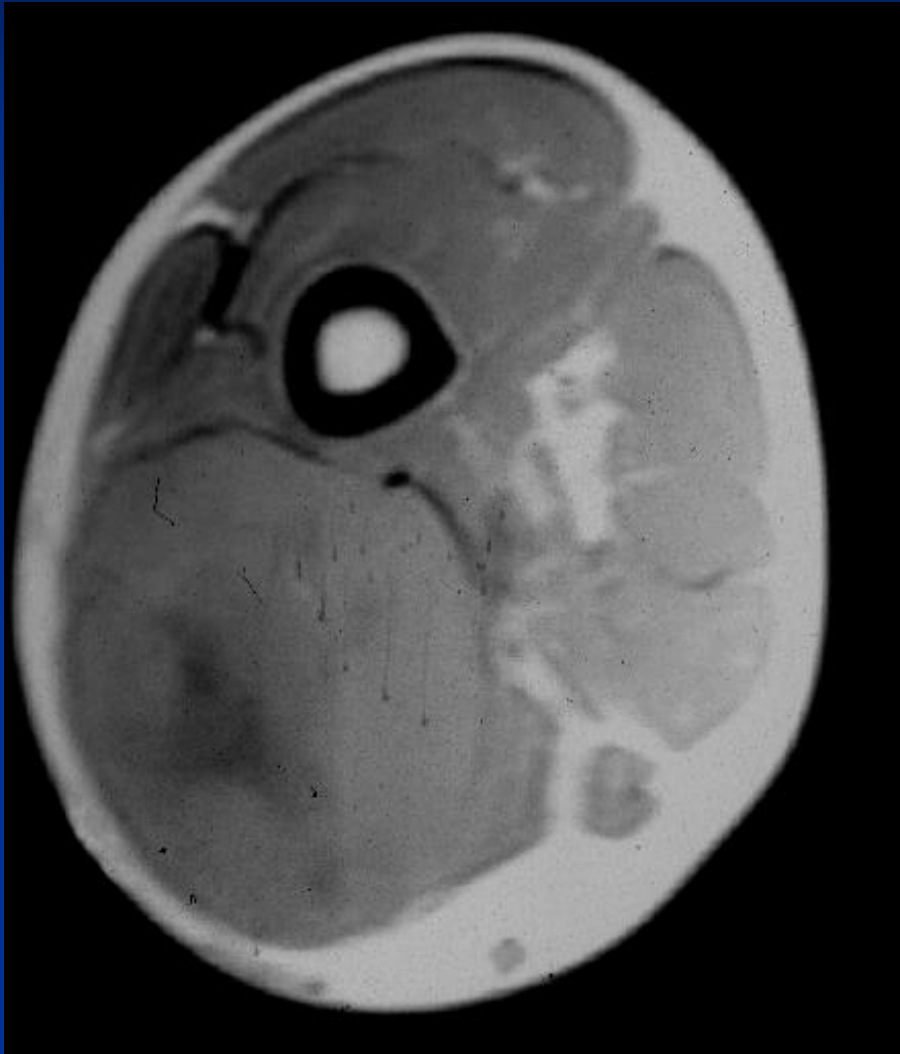


Radiology

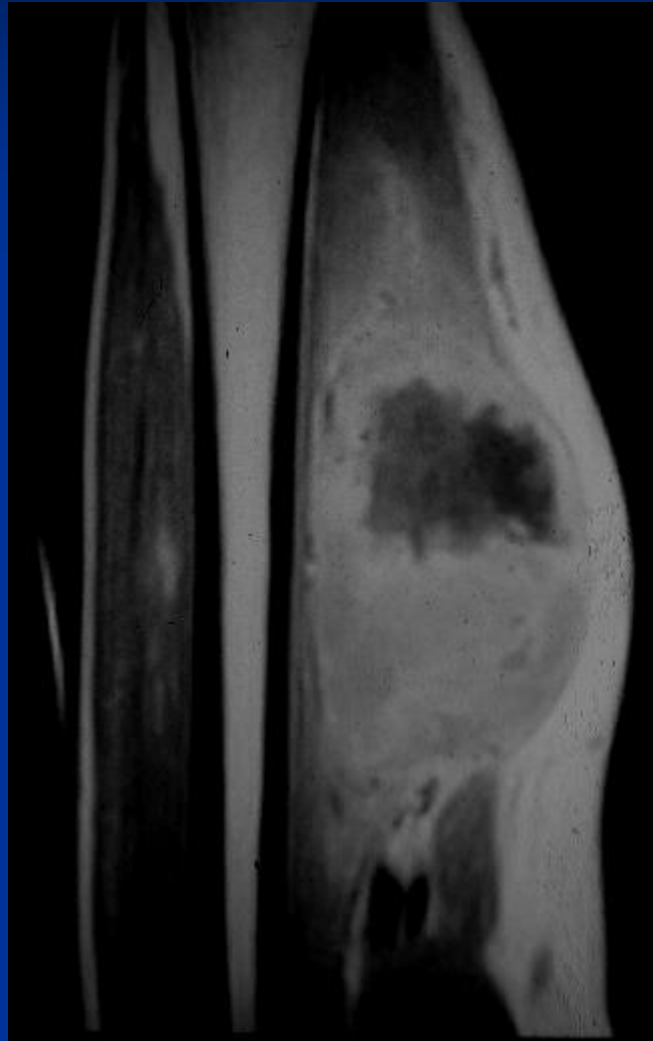
Malignant Fibrous Histiocytoma

- Peripheral pseudocapsule misleading
 - Circumscribed appearance
- Myxoid variant very high signal on T2
- Myxoid variant may show peripheral and septal or diffuse enhancement
 - Look for fat to r/o liposarcoma

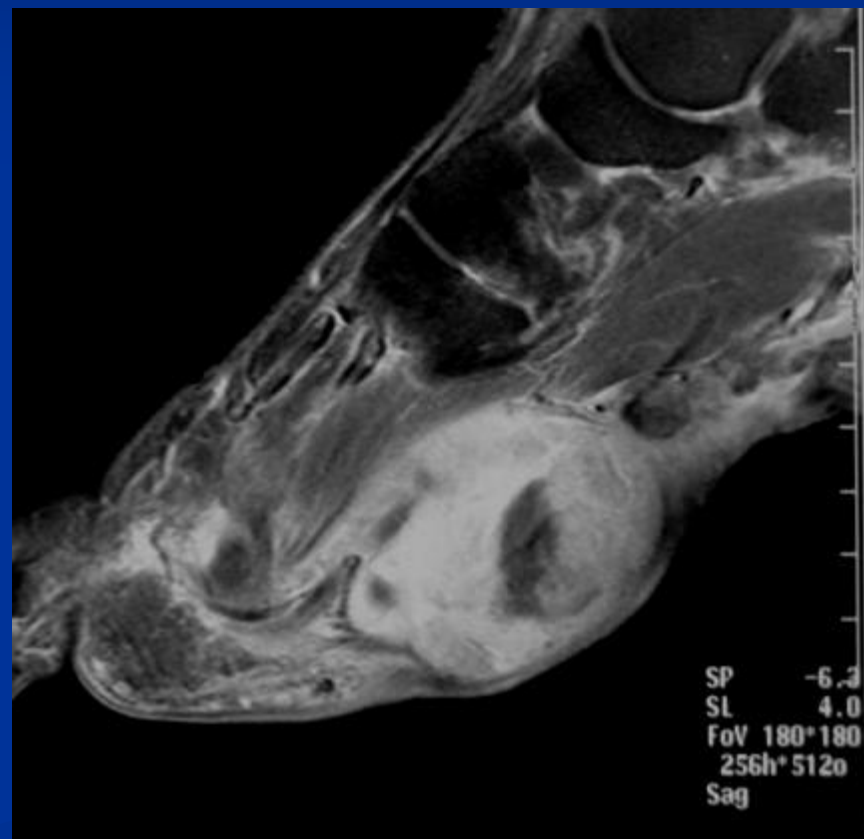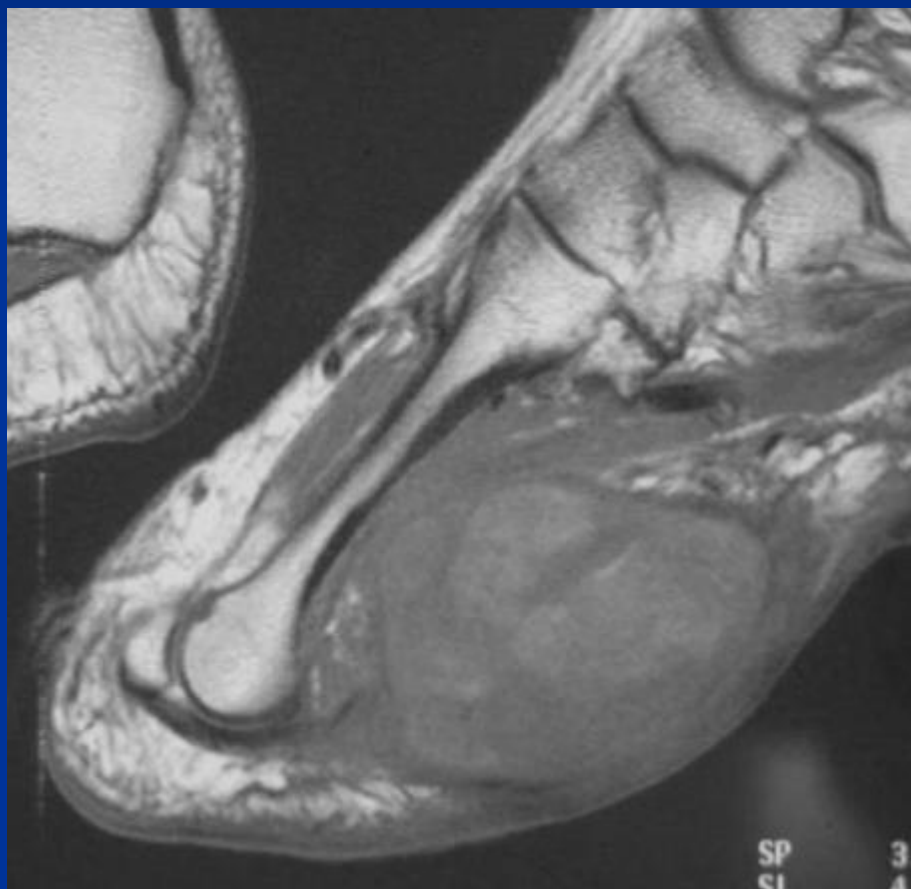
MFH



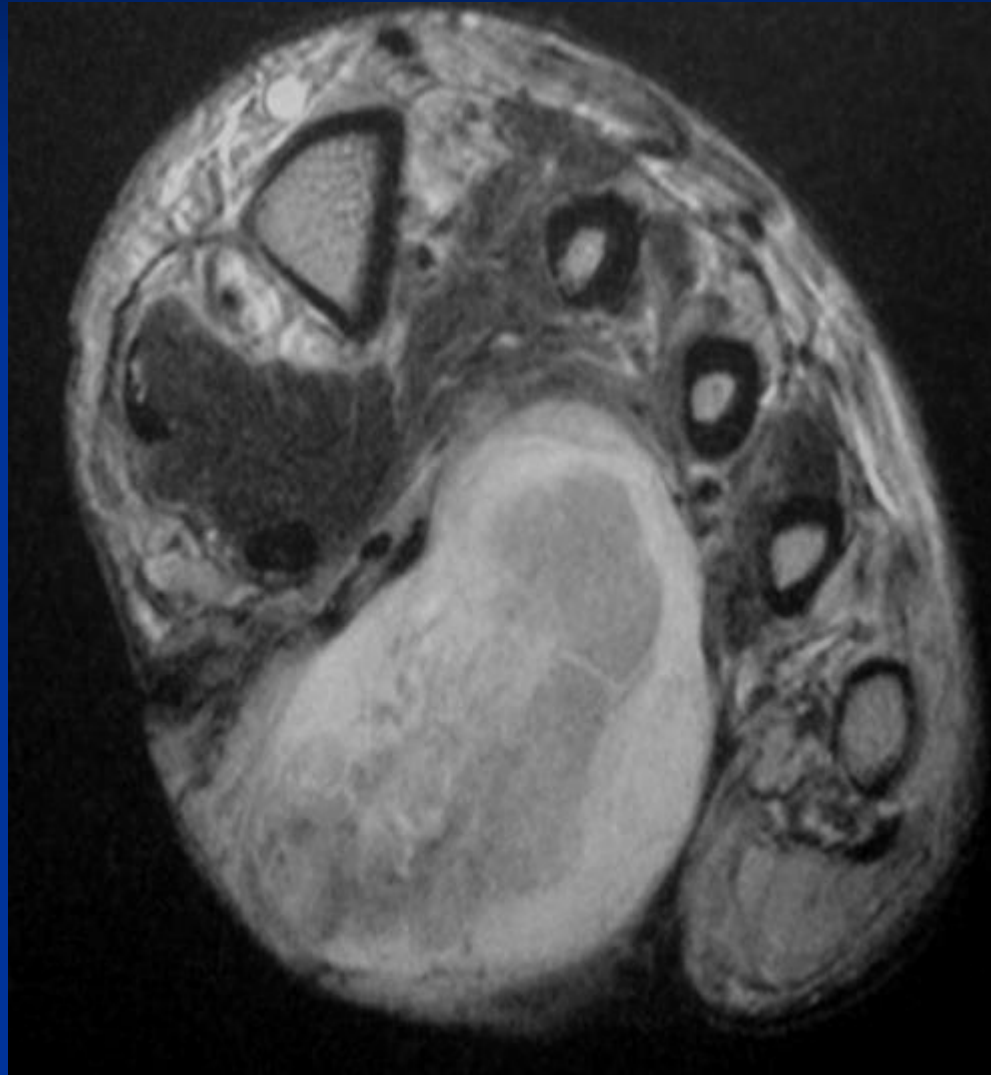
MFH



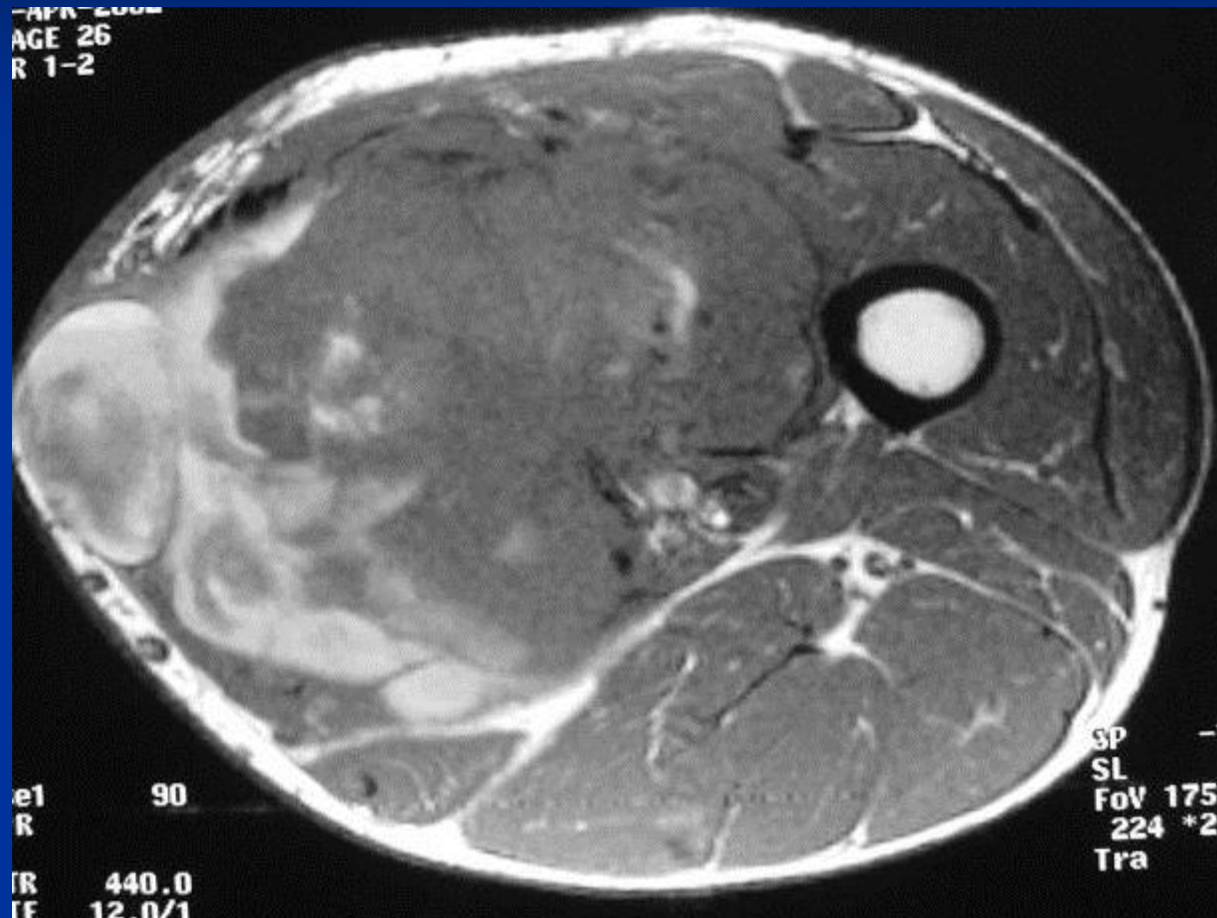MFH Foot



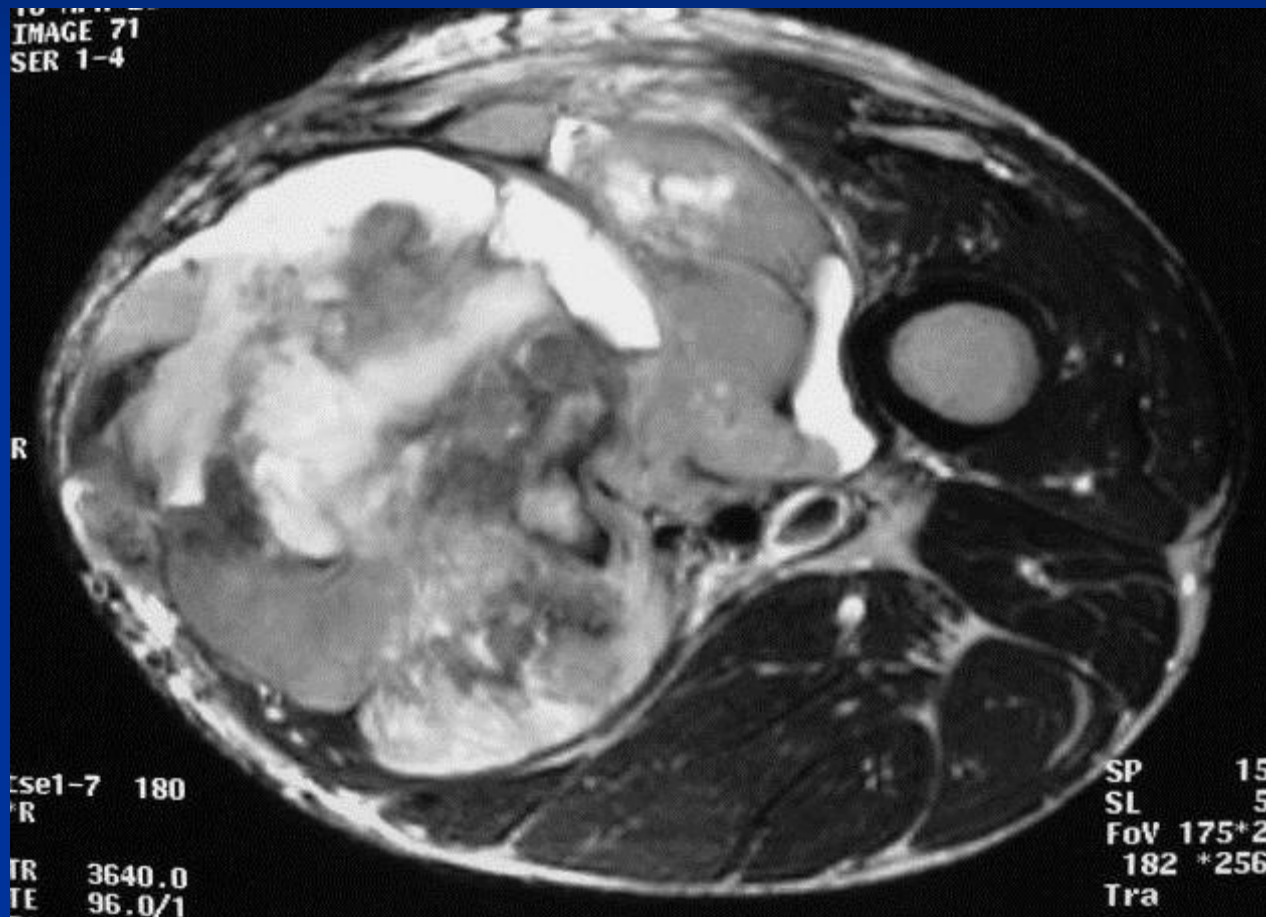MFH of Foot



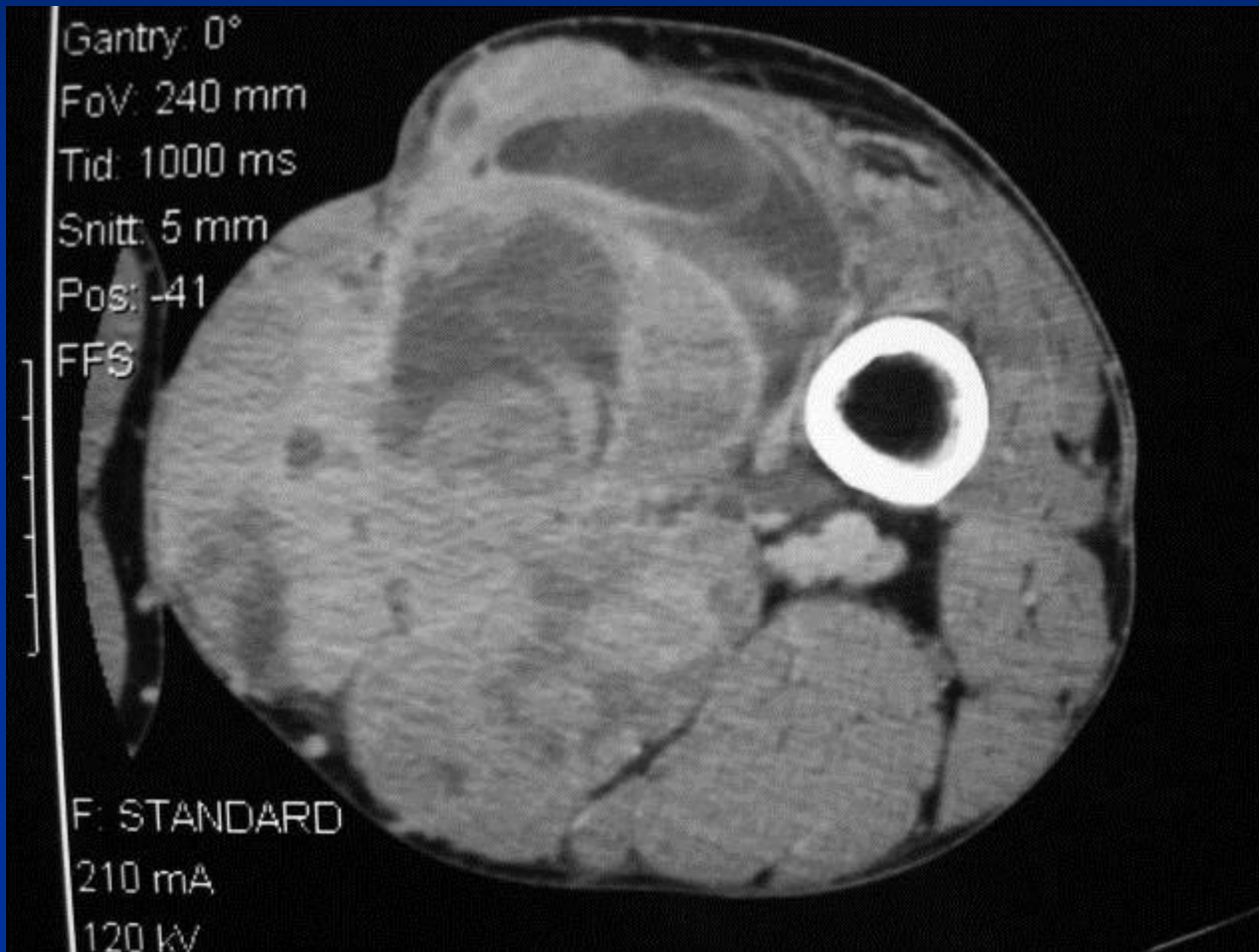
MRI T1 MFH of Thigh



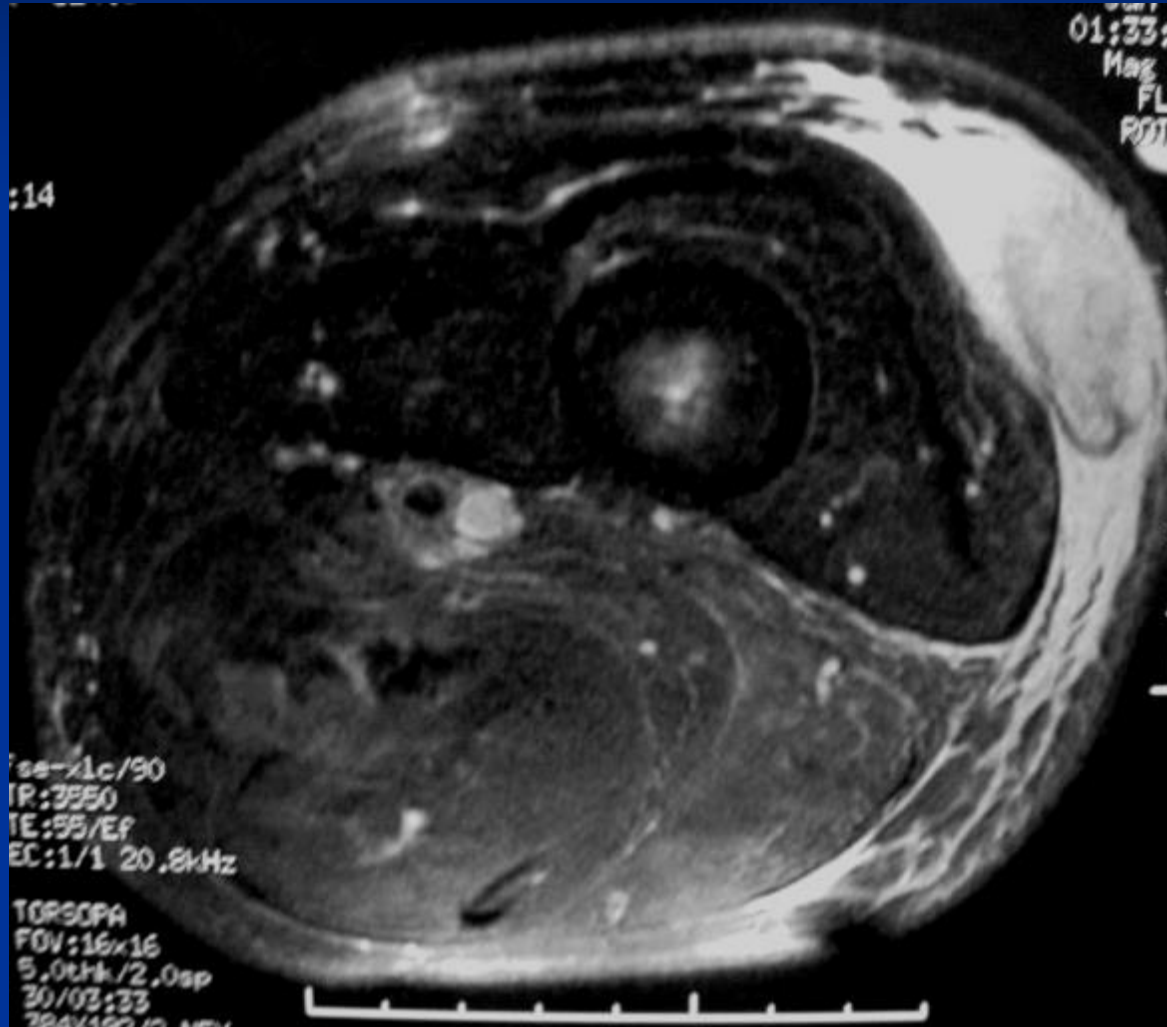
MFH of Thigh T2



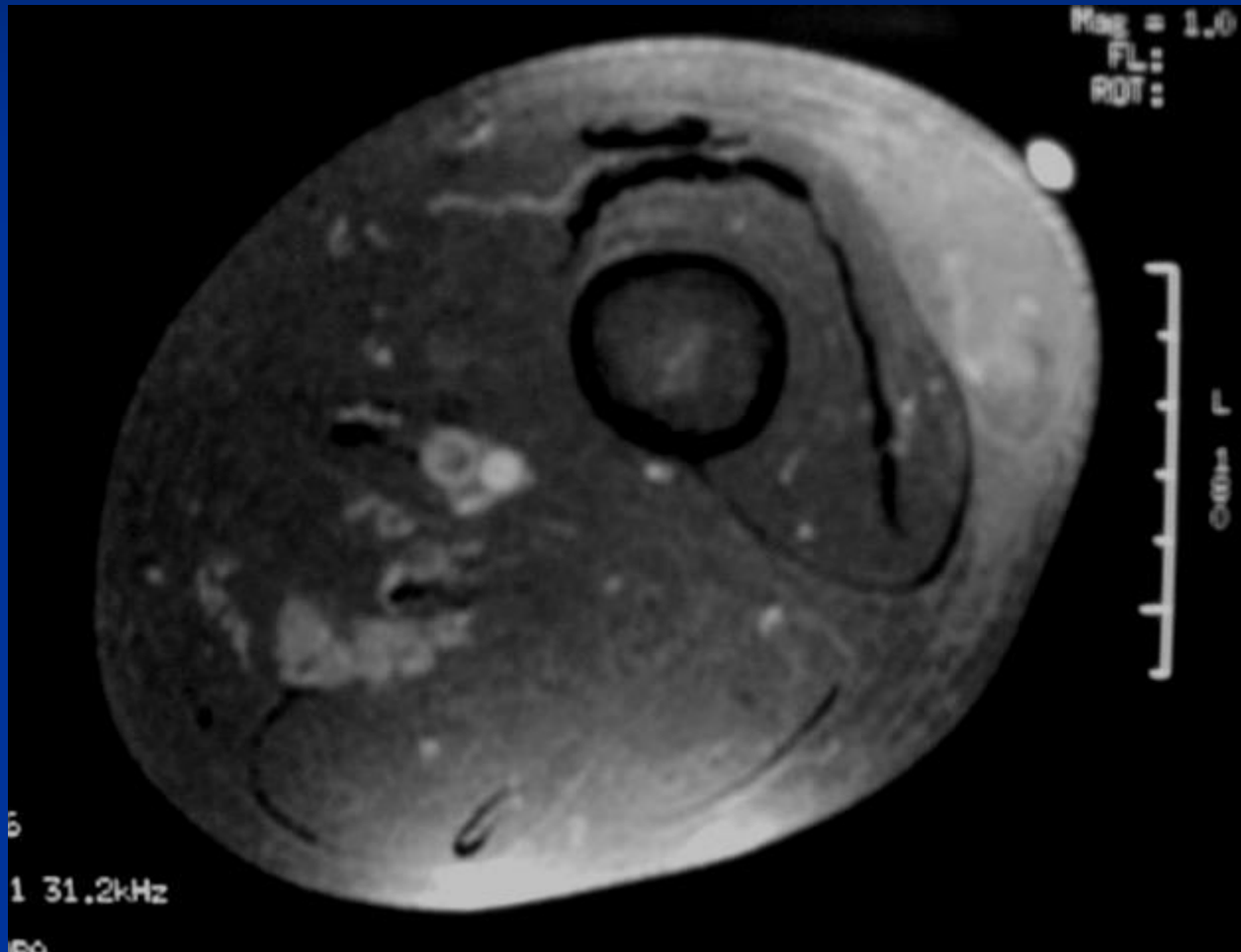
CT Scan: MFH of Thigh



MRI T2 Subcutaneous MFH of Thigh



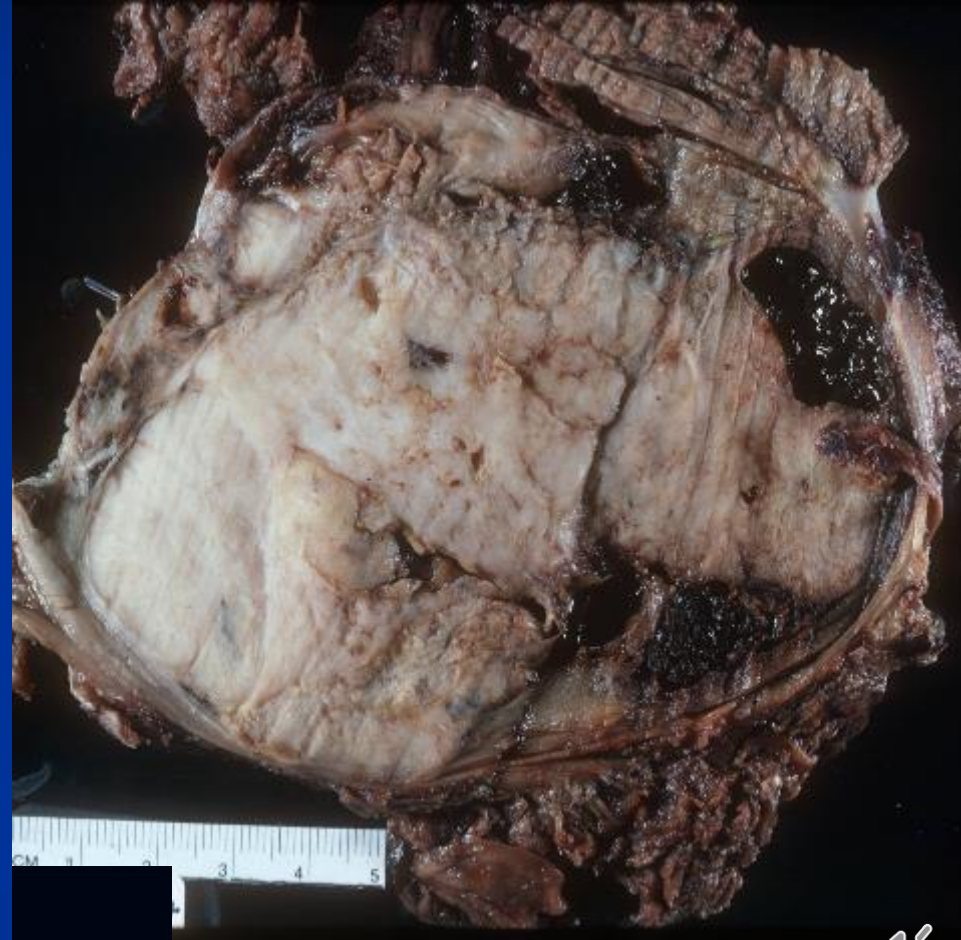
MRI with Gado: Subcutaneous MFH



Pathology

MFH

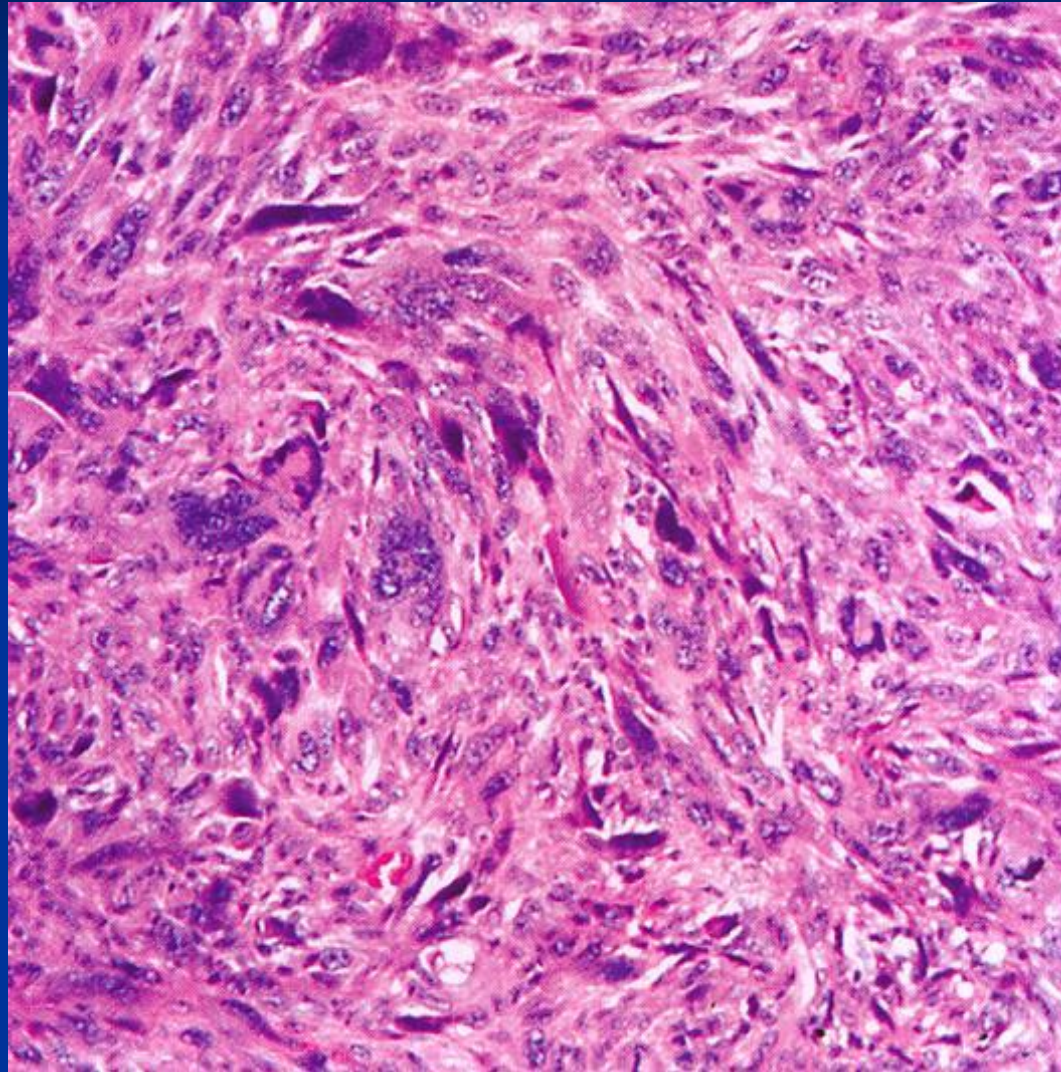
- Gross:
 - Fleshy, multilobulated with areas of hemorrhage and necrosis



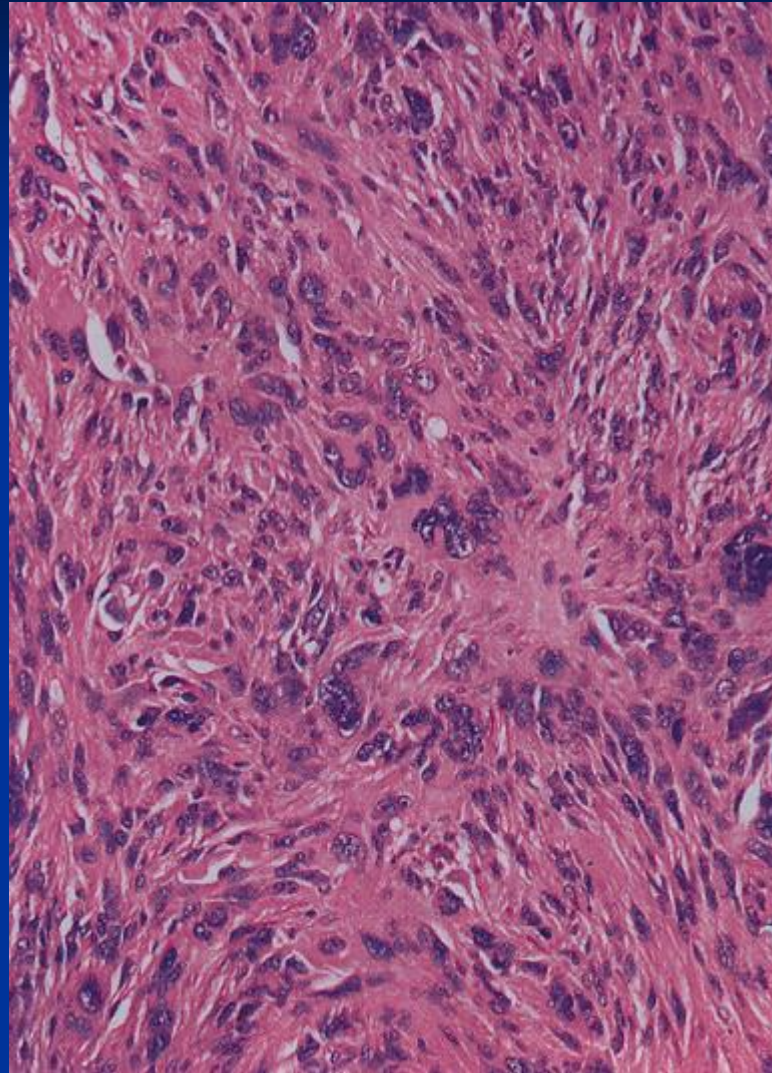
Pathology: MFH

- Microscopic:
 - Bizarre, pleomorphic spindle cells
 - Large, irregular, bizarre nuclei
 - Fibroblasts, myofibroblasts, undifferentiated cells, histiocyte-like cells
 - Fibrous tissue stroma/matrix
 - Extensive pleomorphism
 - Abundant atypical mitotic figures
 - **Storiform pattern** of arrangement of cells and matrix (swirling pattern of collagen bundles and cells)

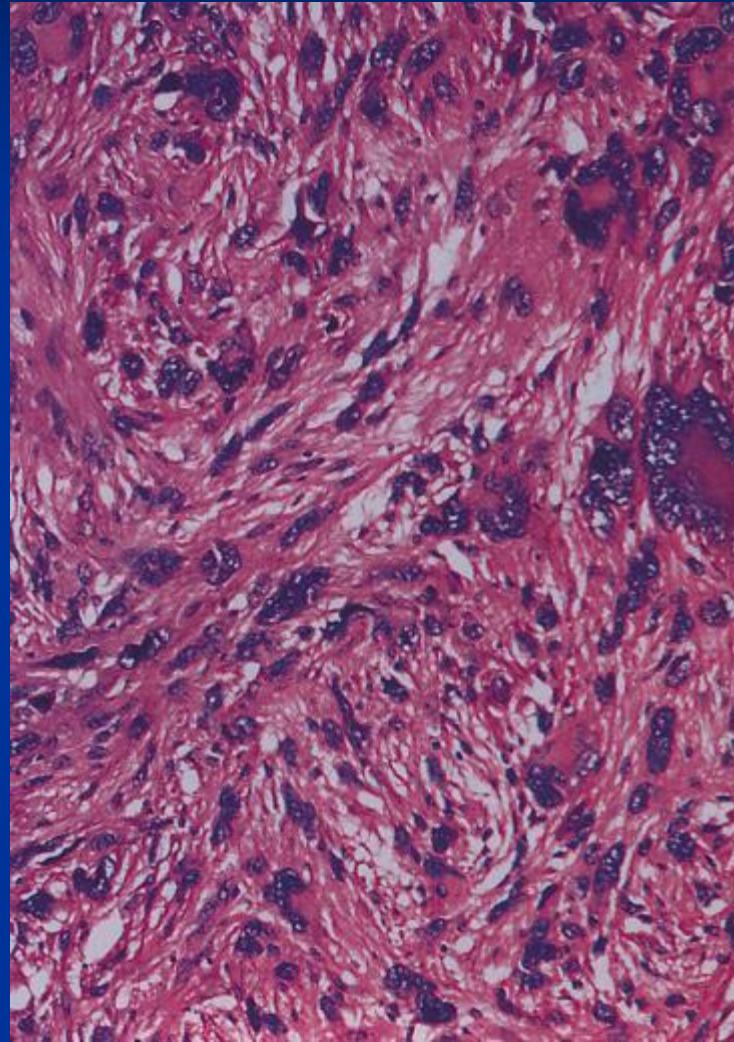
Pleomorphic MFH



Storiform Pattern in MFH



MFH Pleomorphic Bizarre Cells



Treatment and Prognosis

- Surgery:
 - Wide surgical resection and postoperative radiation whenever feasible
 - Amputation for unresectable cases
- Metastases: 35%-45% of patients
 - Lung (90%)
 - Bone (8%)
 - Liver (1%)
 - Lymph Nodes (1%)
- Prognosis: Overall 65% 5 year survival

Fibrosarcoma

- **Definition:** Malignant tumor of fibroblasts that shows no other evidence of differentiation. The spindle cells are usually uniform and demonstrate **minimal pleomorphism**.
- **Rare:** 5% of all soft tissue sarcomas
- 40 to 55 years of age; Infantile form <10 yrs of age
- **Sites:** Intramuscular; rarely in subcutaneous tissue
 - Thigh, knee area, buttock
 - Arm/shoulder girdle
 - Trunk
 - Forearms and legs
- **Clinical:** Painless mass

Fibrosarcoma

- May arise secondarily
 - Irradiated soft tissues
 - Scars and burns
 - Dedifferentiated component of Dermatofibrosarcoma protuberans
 - Dedifferentiated component of liposarcoma

Fibrosarcoma

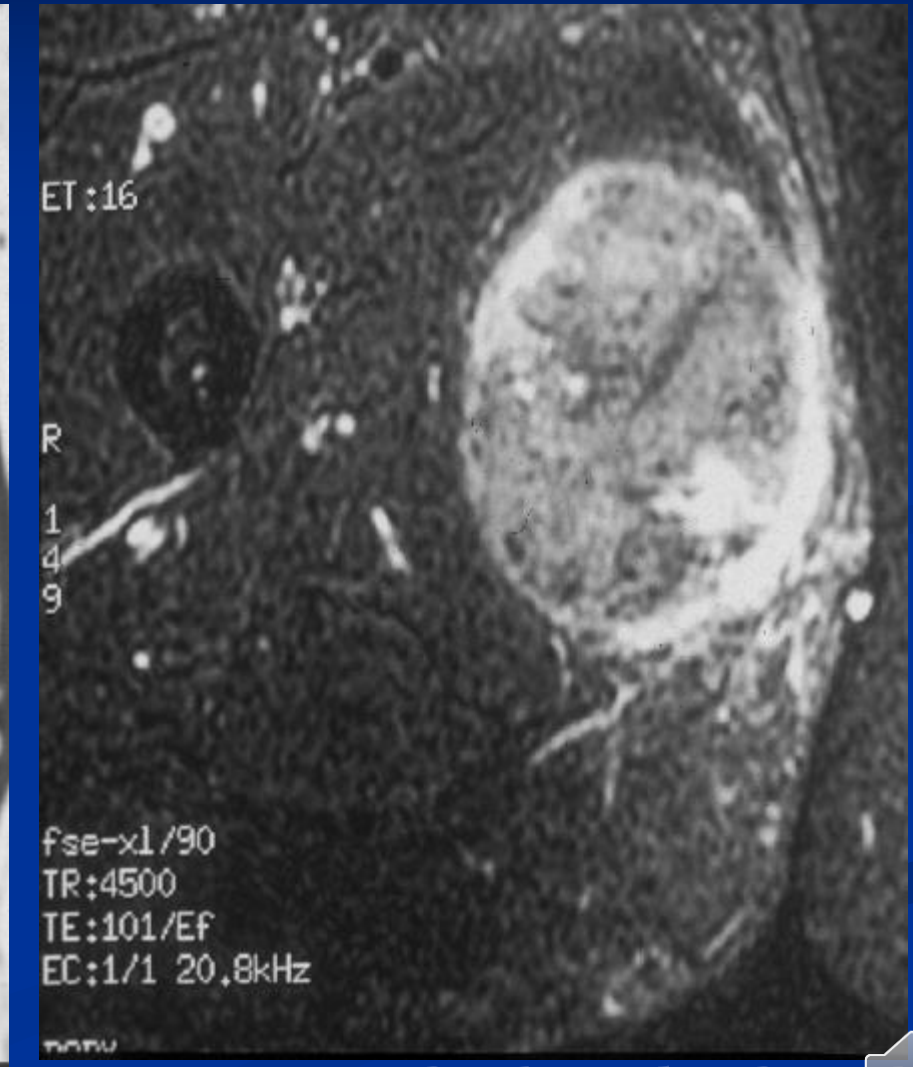
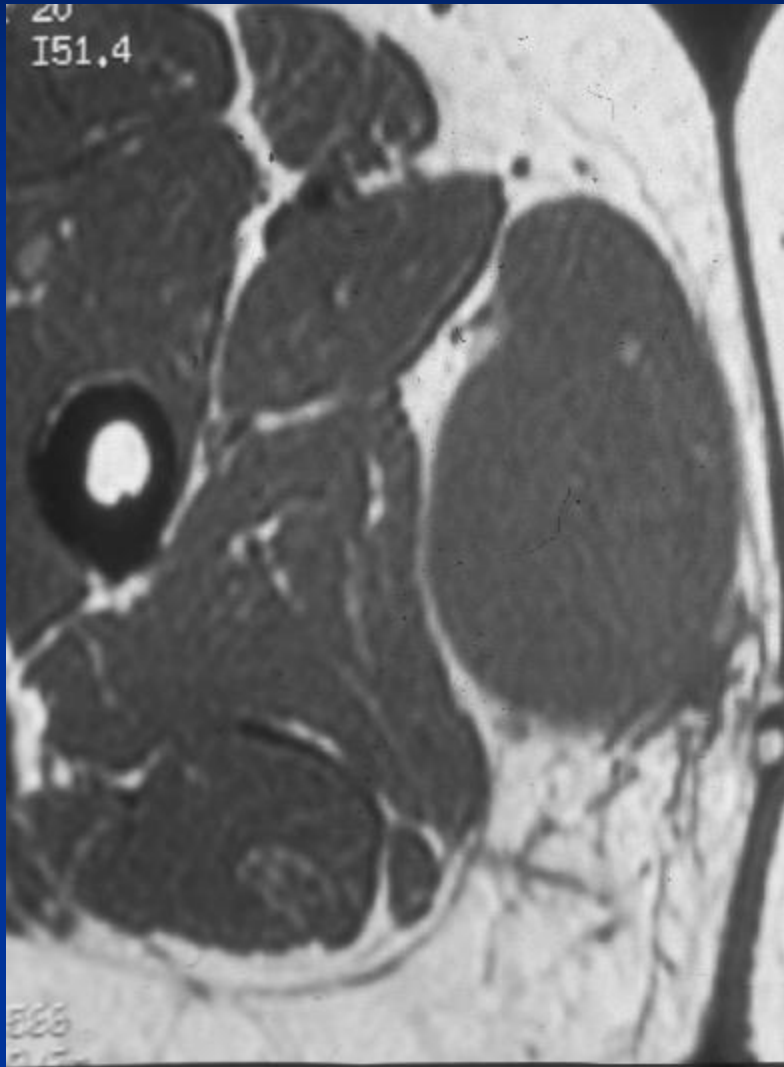
- Overall 5 yr. survival of 40%
- >60% metastatic rate
- Virtually indistinguishable from MFH on imaging

Radiology

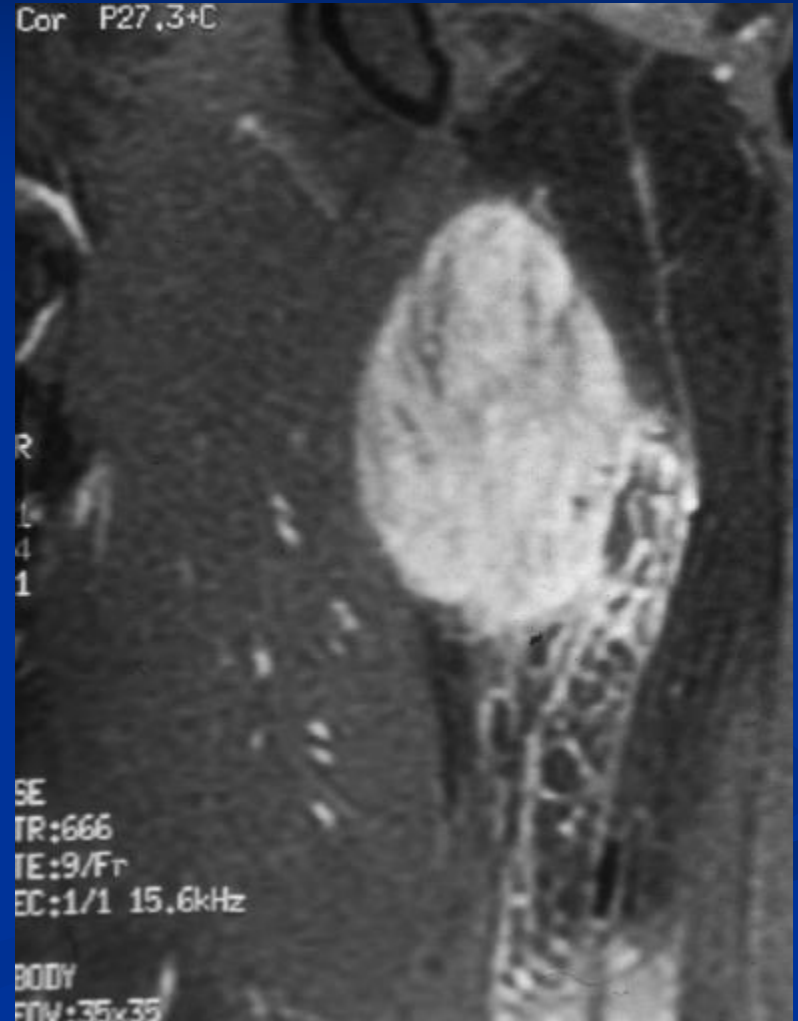
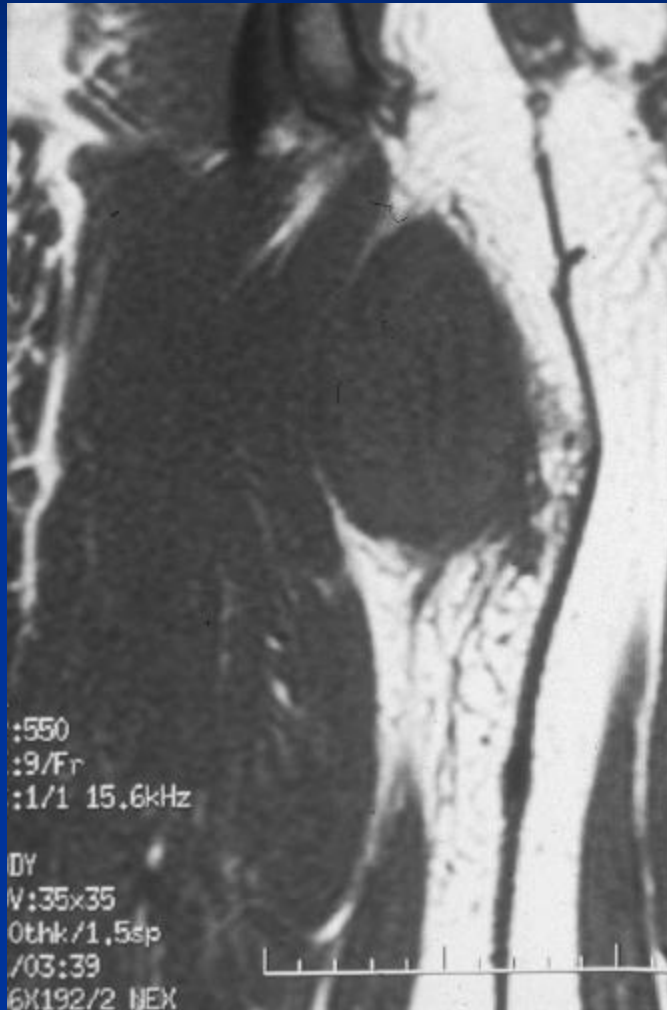Fibrosarcoma

- MRI
 - 2/3 of tumors are intramuscular
 - Well defined heterogeneous mass
 - Necrosis and hemorrhage are common especially in higher grade tumors
 - Viable areas enhance with contrast; Areas of significant necrosis and hemorrhage do not enhance

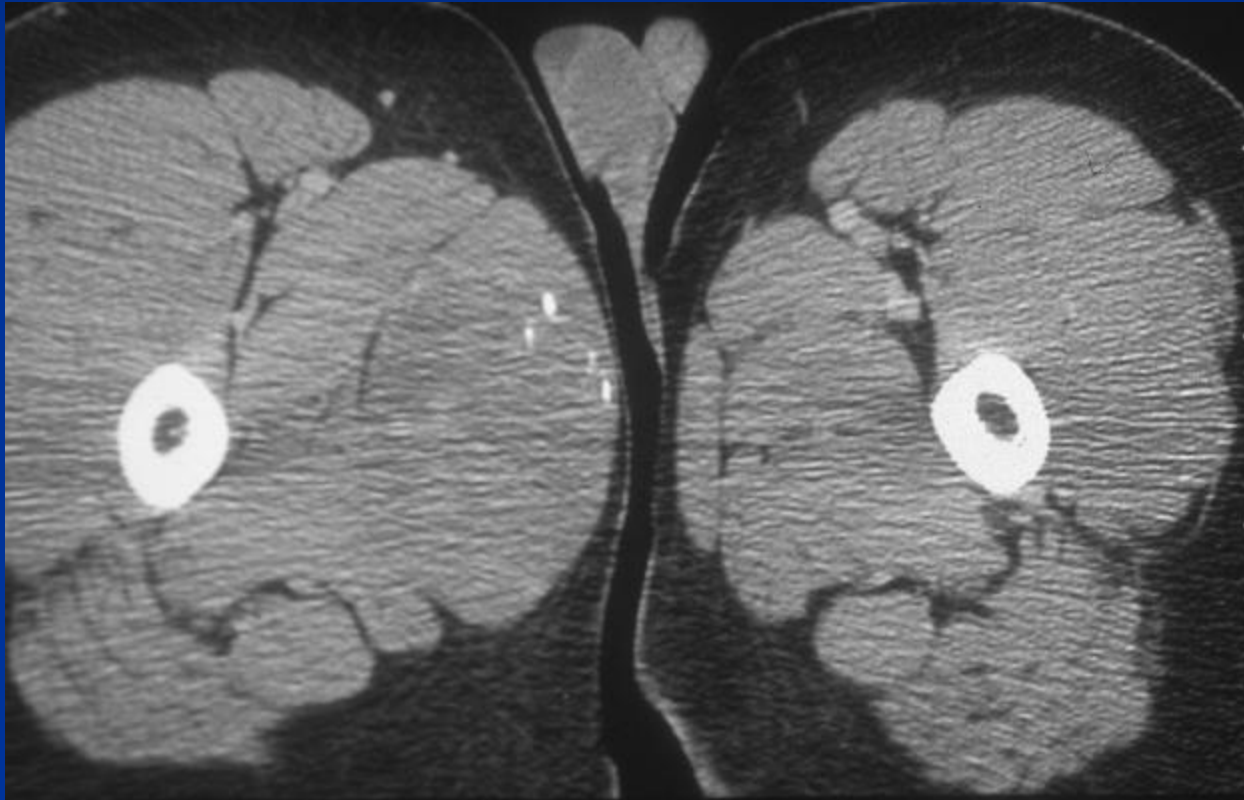Fibrosarcoma



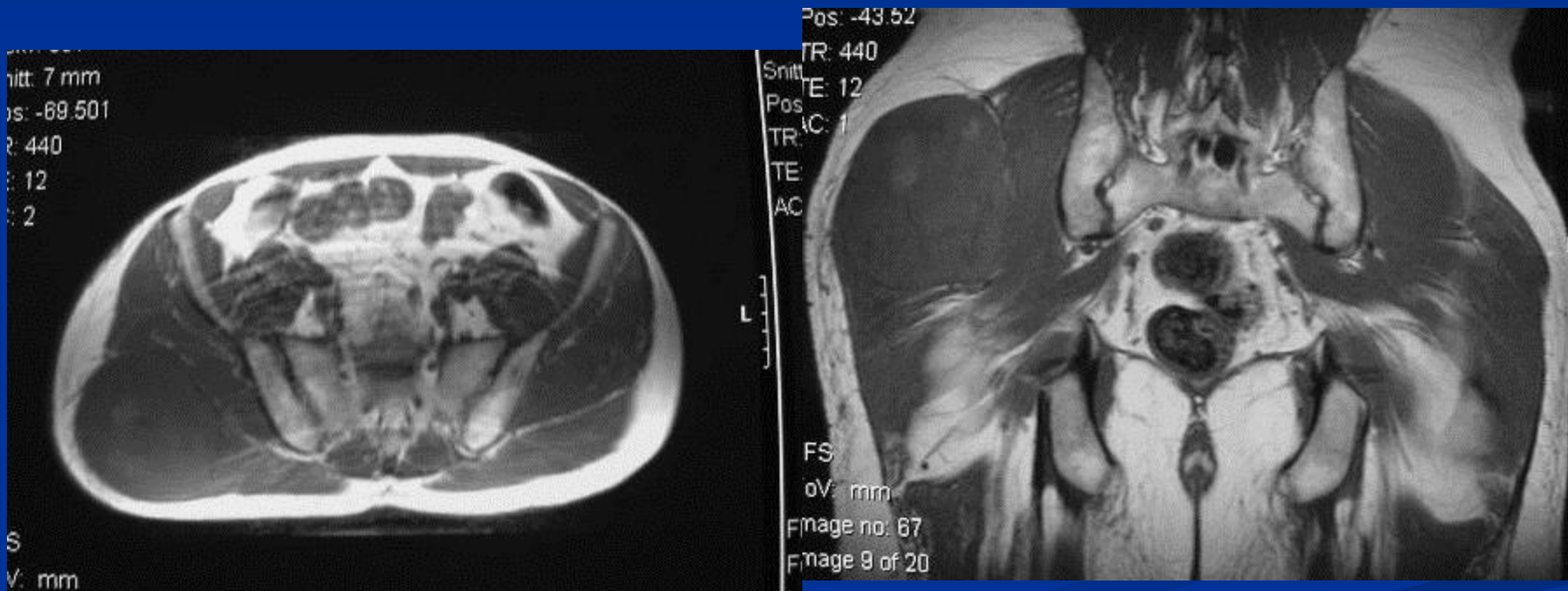
Fibrosarcoma



Fibrosarcoma

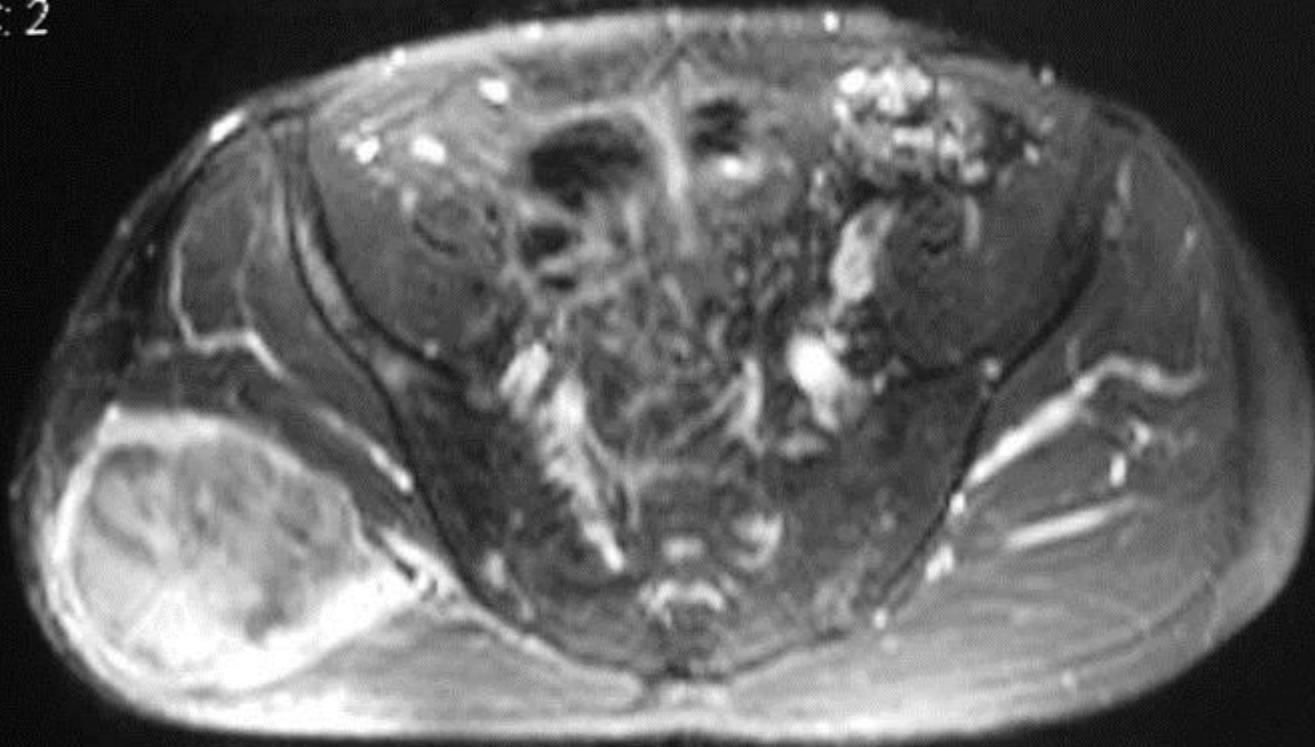


Fibrosarcoma of Right Buttock



Sekv: tse 1-1
Snitt: 7 mm
Pos: -51.3009
R: 4000
E: 96
C: 2

Snitt: 7 mm
Pos: -42.2
TR: 4000
TE: 96
AC: 2



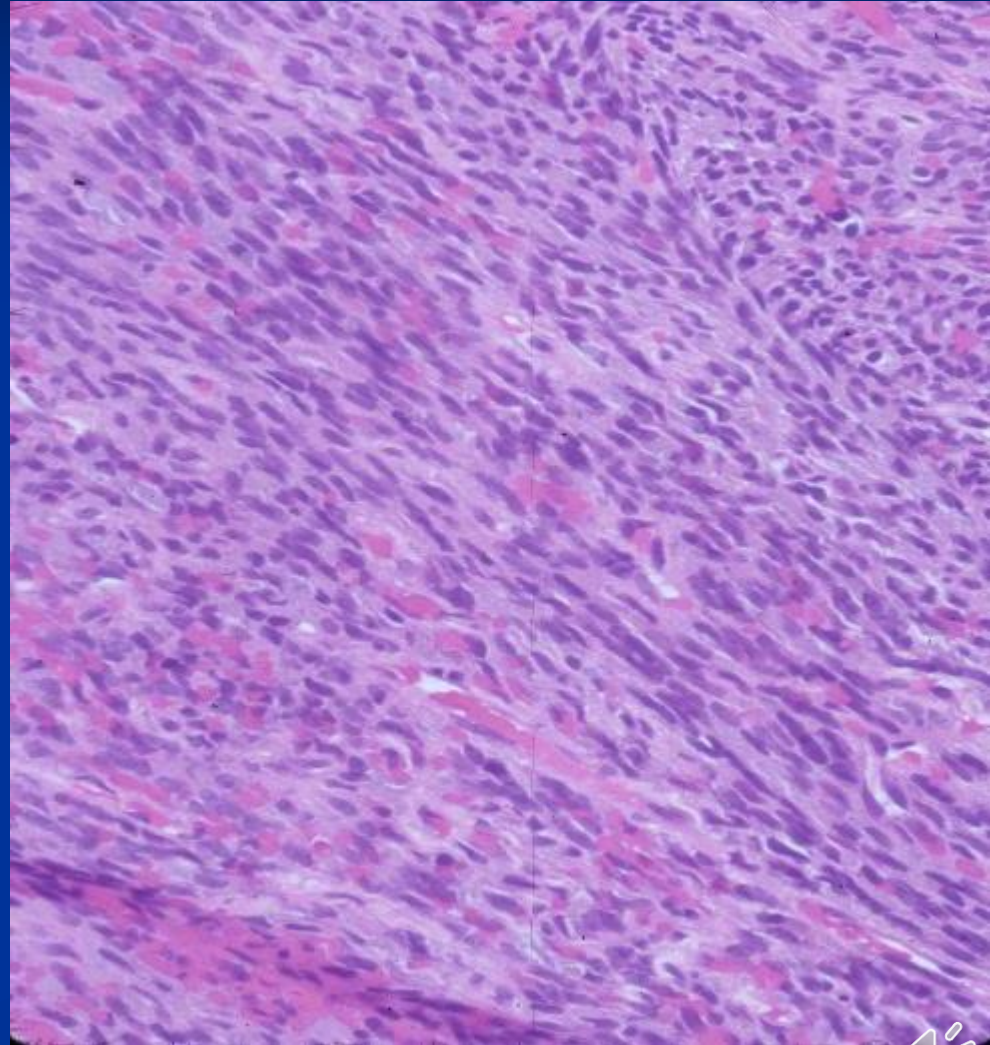
L

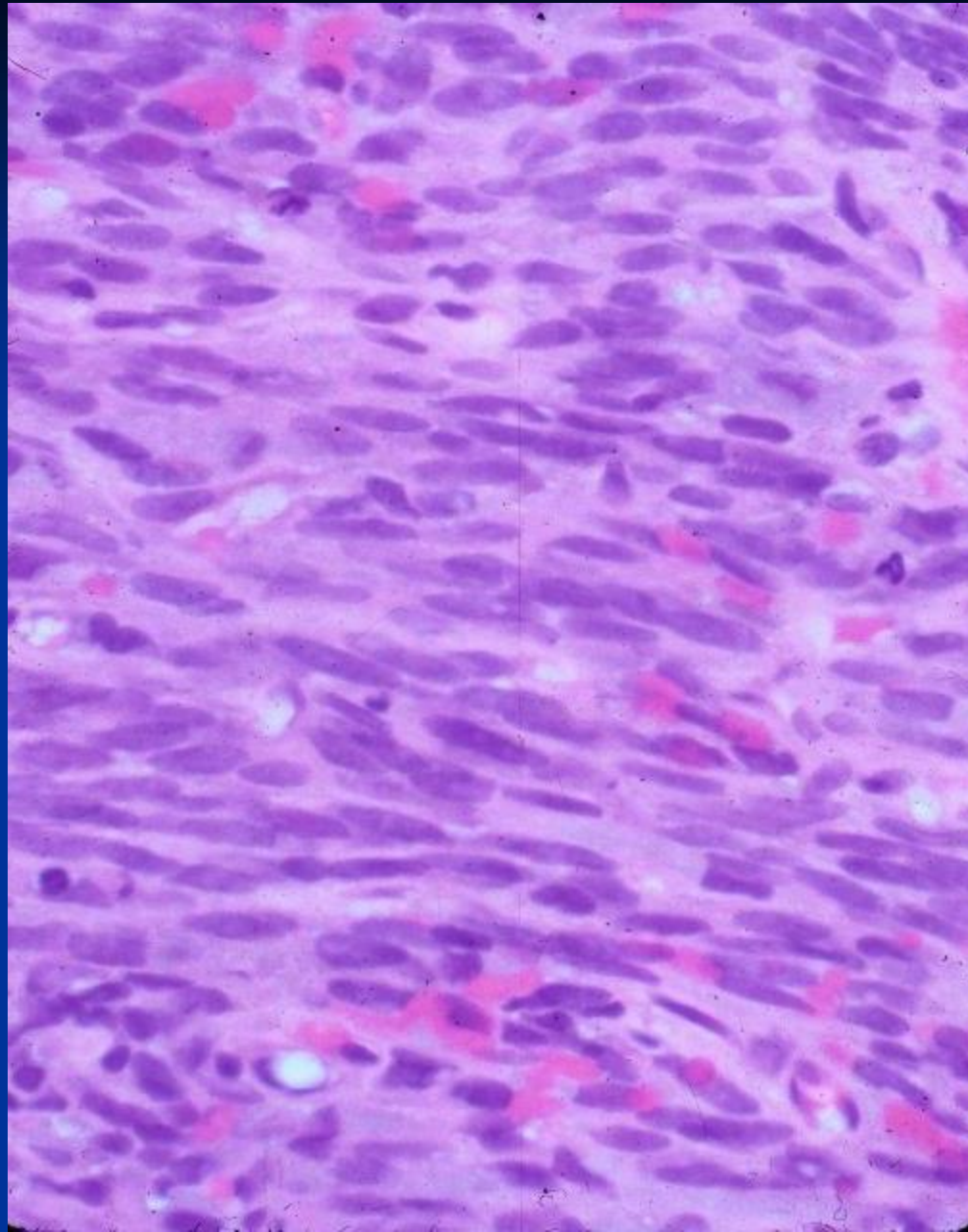
Pathology: Fibrosarcoma

- Gross:
 - Fleshy, focally necrotic and hemorrhagic mass (high grade)
 - Firm and rubbery masses (low grade, well differentiated, collagenized)
- Microscopic:
 - Elongate, fairly uniform spindle cells with scant cytoplasm and large nuclei in a variable amount of fibrous stroma
 - Minimal pleomorphism
 - **Herringbone pattern:** Arranged in fascicles that intersect at right angles
 - Mitoses present; also abnormal mitoses (Increase in Grade 2 and Grade 3 Tumors)

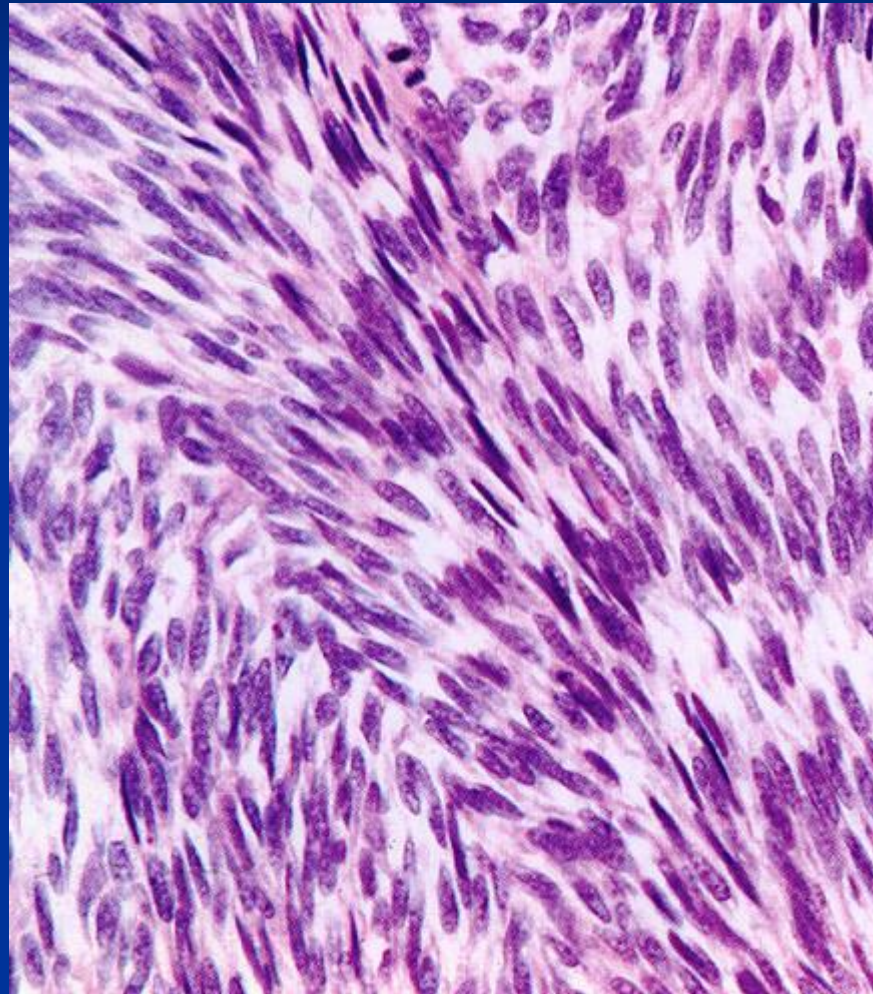
Pathology: Fibrosarcoma

- Hypercellular
- Uniform Spindle cells
- Minimal Pleomorphism
- Fibrous Matrix
- Herringbone Pattern





Grade 1 Fibrosarcoma: Herringbone Pattern



Pathology: Fibrosarcoma

- Differential Diagnosis:
 - Monophasic Synovial Sarcoma
 - Cytokeratin or EMA (epithelial membrane antigen) positive
 - Translocation tX;18 (90% of cases) SYT-SSX
 - Leiomyosarcoma: Actin and Desmin Positive
 - MPNST: S-100 positive
 - Fibromatosis: Morphological features

Treatment and Prognosis

- Treatment: Wide surgical excision and postop radiation whenever feasible
 - Amputation for unresectable cases
- Metastases:
 - Lungs
 - Bone
 - Liver
- Prognosis: 35% to 55% 5 year survival rate
- Related to grade, size and location
 - Grade 1: Metastasize rarely
 - Grade 2-3: Mets 35-45%

Synovial Sarcoma

- **Definition:** Typically a biphasic soft tissue sarcoma with epithelial and spindle cell components
- Monophasic, spindle cell only varieties, also exist
- Not of synovial origin
- 5-10% of all soft tissue sarcomas
- Young adults and teenagers (15 to 35 years of age)

Synovial Sarcoma

- **Sites:**

- Deep location in close proximity to large joints
- Lower extremities > Upper extremities
 - 60% in Lower Extremity
- Feet and Hands
- Most common soft tissue sarcoma of the foot and ankle
- Intimately related to tendons, tendon sheaths, bursa, muscles
- Rarely occurs within and actual joint <5%
 - Knee most commonly
- Unusual in retroperitoneum and head and neck

Synovial Sarcoma

- Males: females 1.2:1
- Predilection for white>black
- **Clinical:**
 - Painful mass in greater than 50% of cases
 - Slow growing mass
 - May grow over a period of 2-4 years

Radiology

Synovial Sarcoma

- Radiographs:
 - Calcification in 20% of cases (Stippled or Large Amounts)
 - Underlying bony invasion 10%-20% cases
- CT:
 - **Lobular mass** close to a joint
 - Heterogeneous mass sometimes with calcification and underlying bone erosion
 - Detect subtle calcification
- MRI: Hemorrhage, necrosis and cystic change are common

Radiology

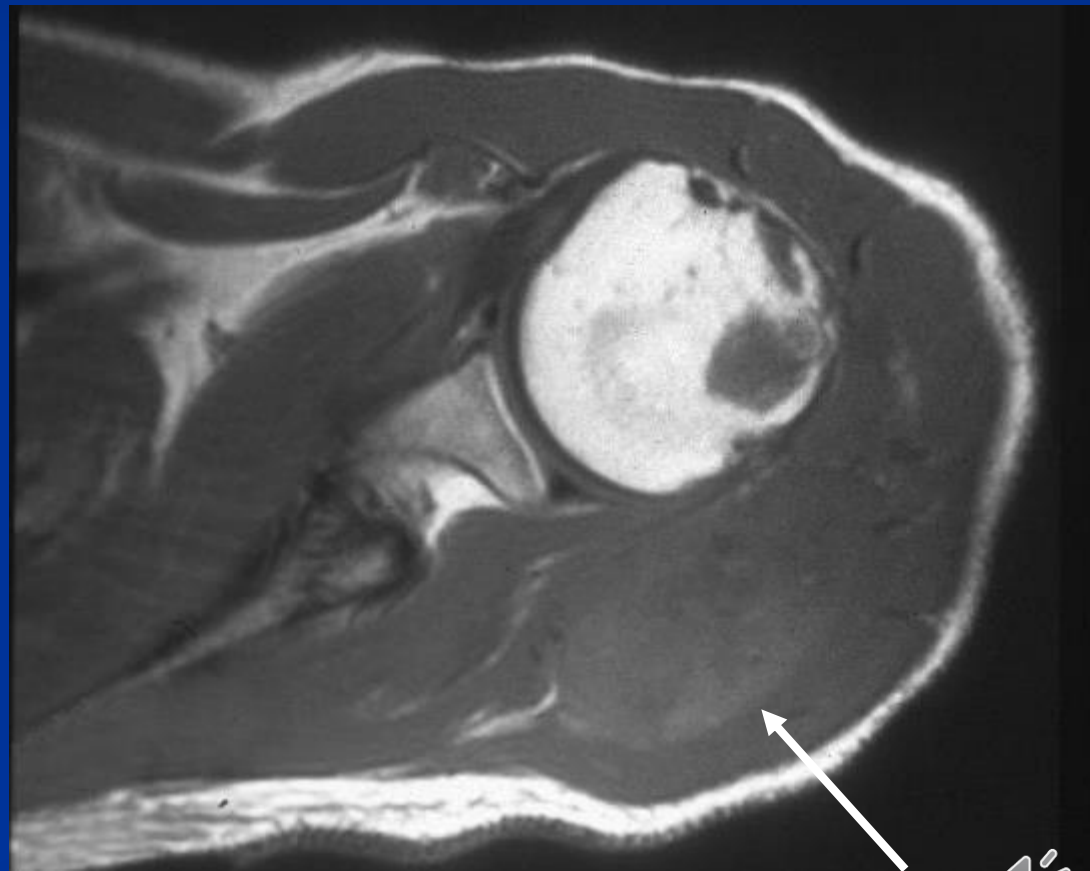
Synovial Sarcoma

- MRI:
 - Highly heterogeneous mass; Enhances heterogeneously
 - Hemorrhage, necrosis and cystic change are common
 - Lobular growth with internal septations
 - T1: Intermediate signal similar to muscle
 - T2: **Triple Signal Intensity**
 - **High, Low and Intermediate Signals**
 - Cyst, hemorrhage, solid elements, fibrous tissue in same tumor
 - Fluid-Fluid levels in 25% of patients

MRI Synovial Sarcoma of Shoulder

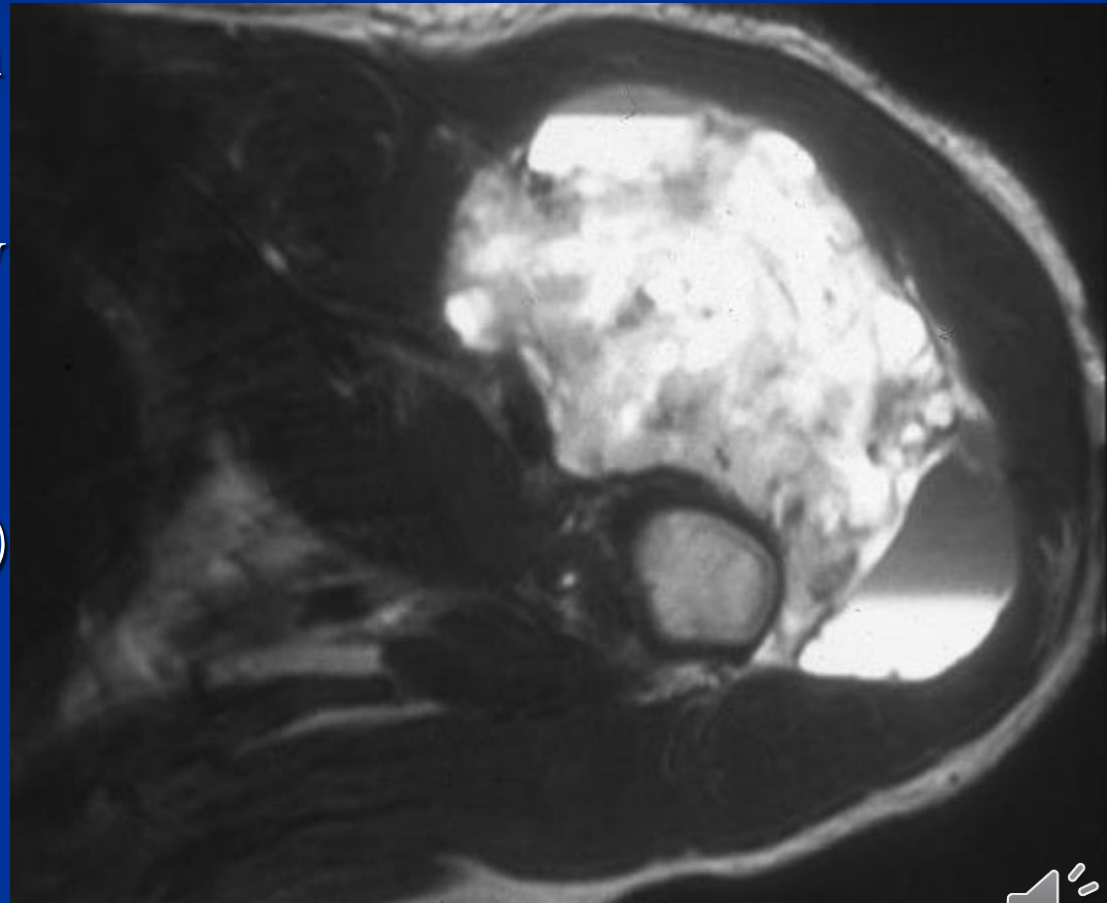
Bone Involvement

- Intermuscular near large joint
- Foot or ankle
- May be ill- or well-defined
- Ca^{+2} in 1/3 (lung metastases may also Ca^{+2})
- Osseous involvement in 11-20%

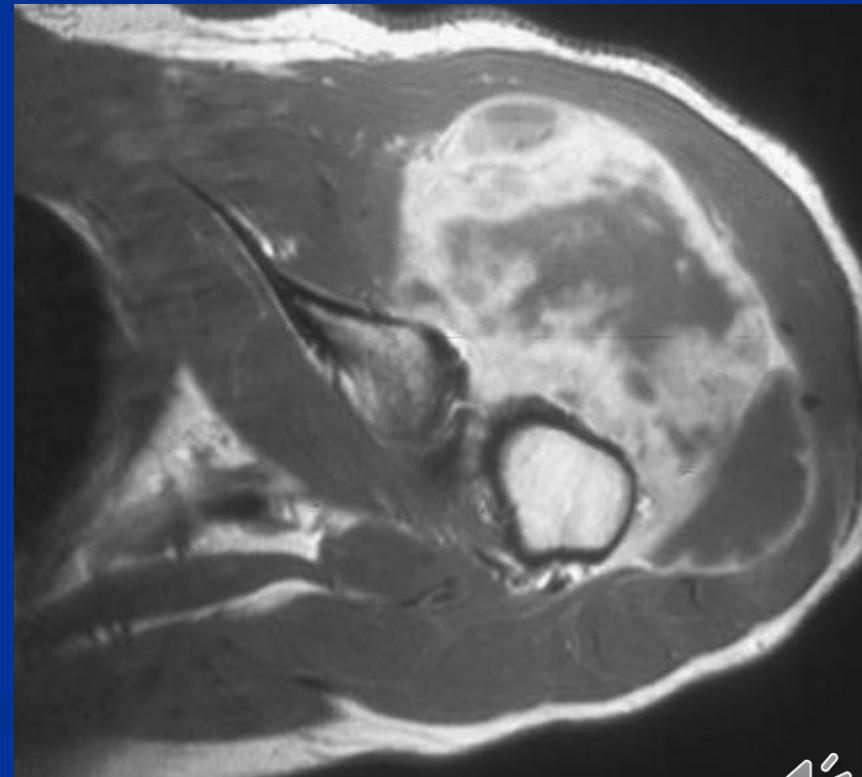
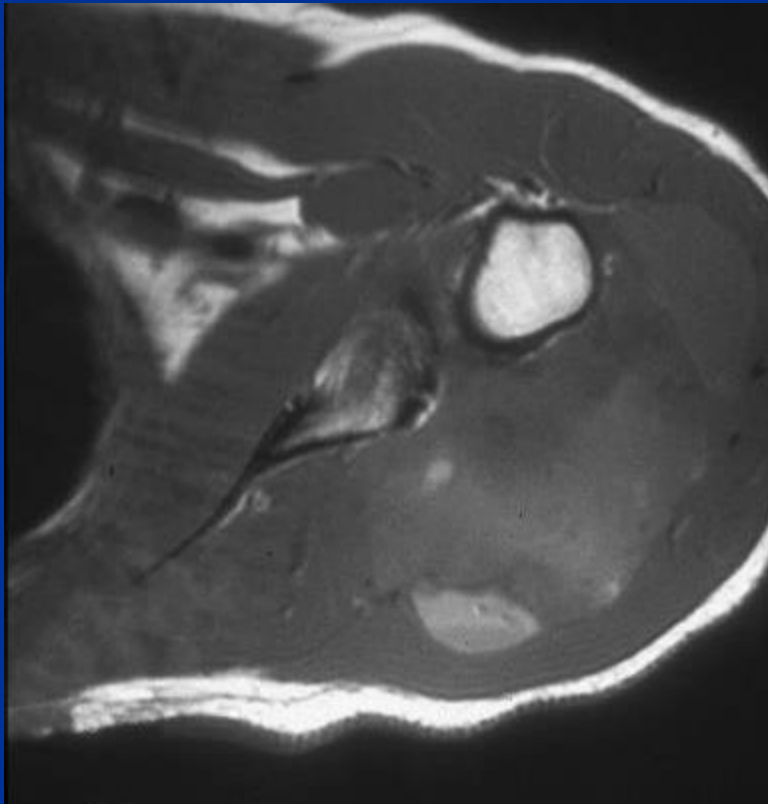


Synovial Sarcoma Imaging

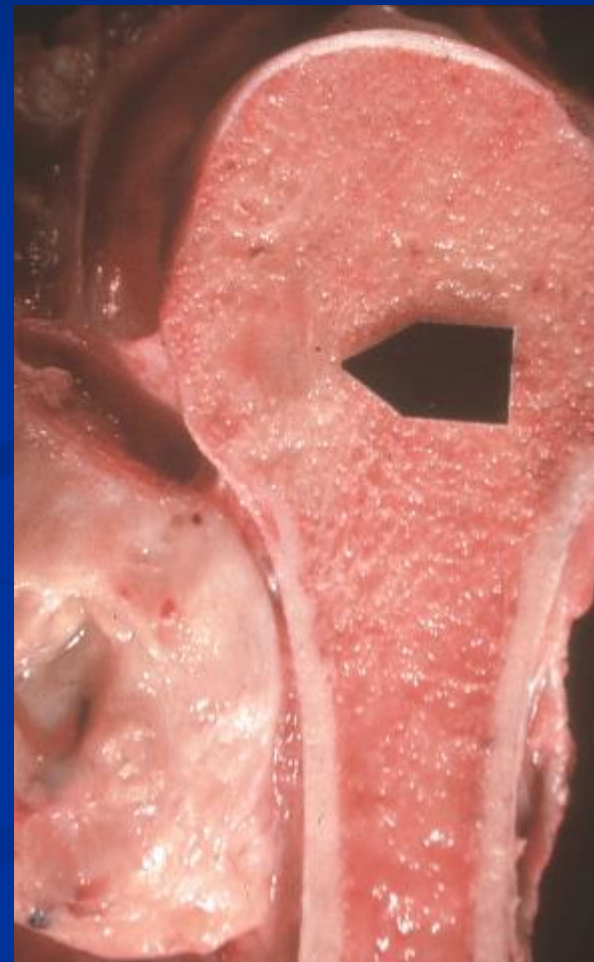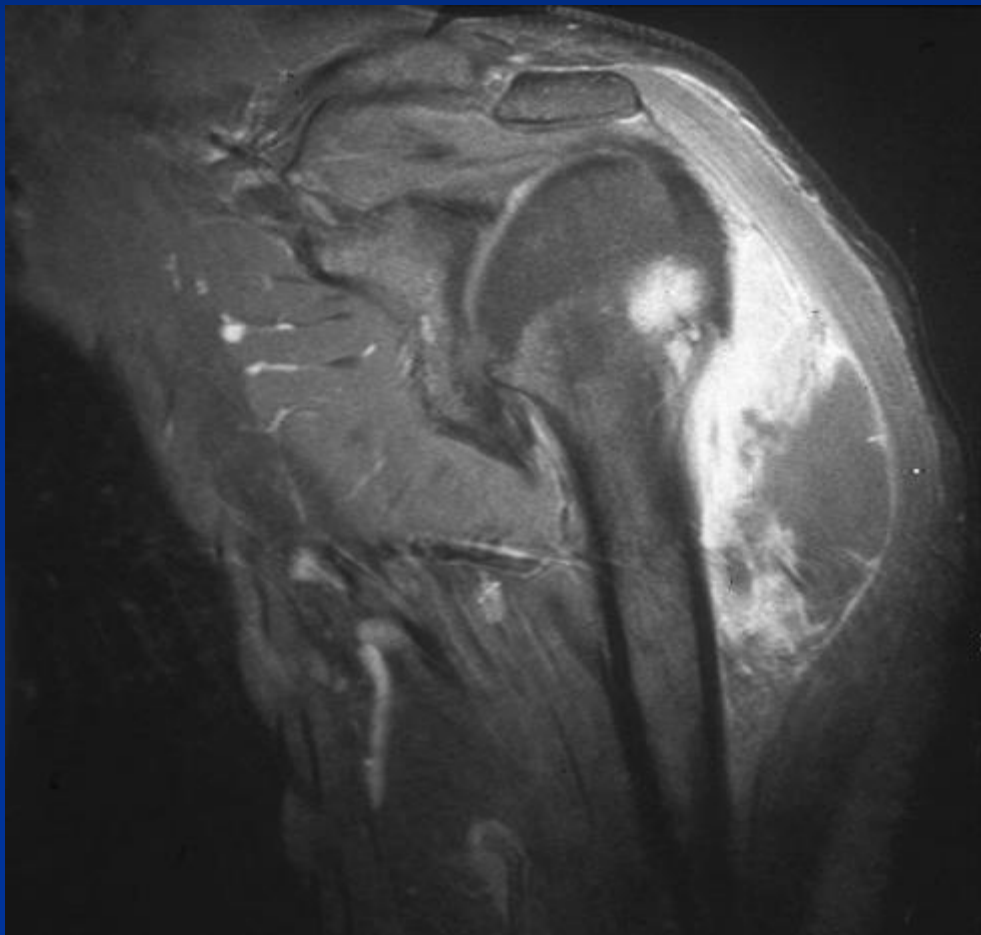- Large lesions often very heterogeneous on T2
- **Triple signal** intensity pattern suggestive
- Cluster of grapes (septated/multilocular)
- Hemorrhage/fluid levels/cystic areas



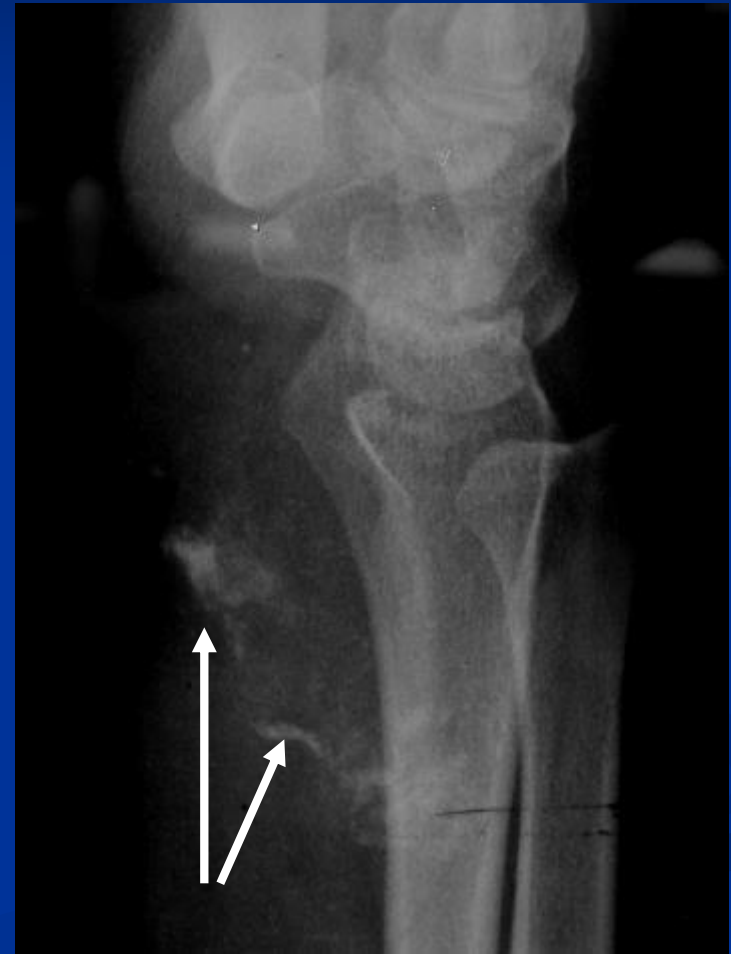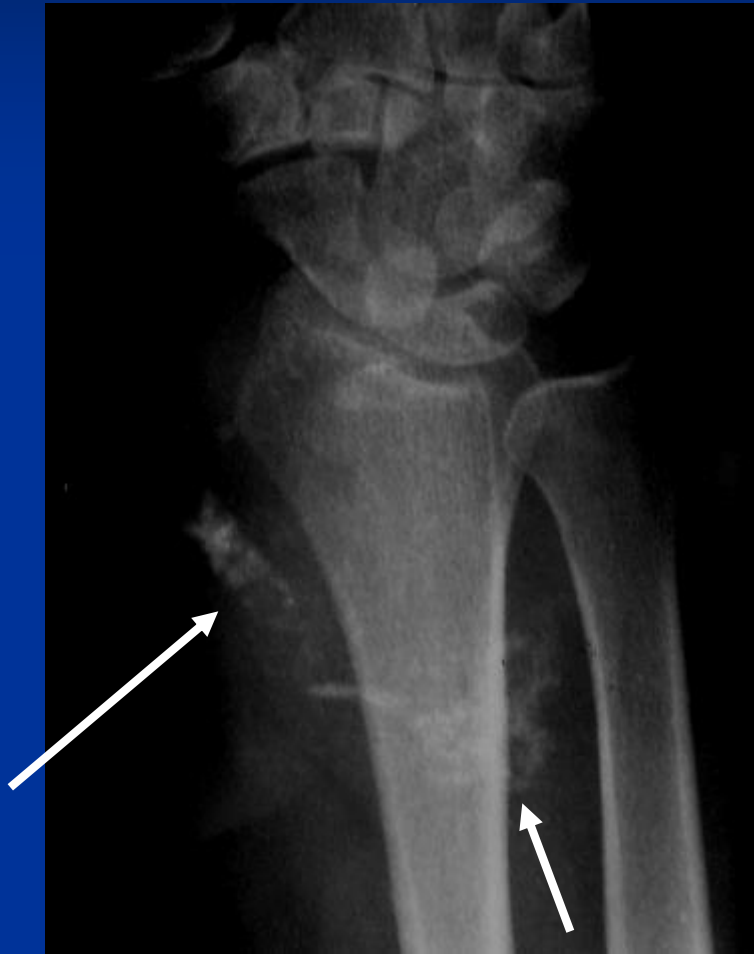Synovial Sarcoma: Heterogeneous Enhancement



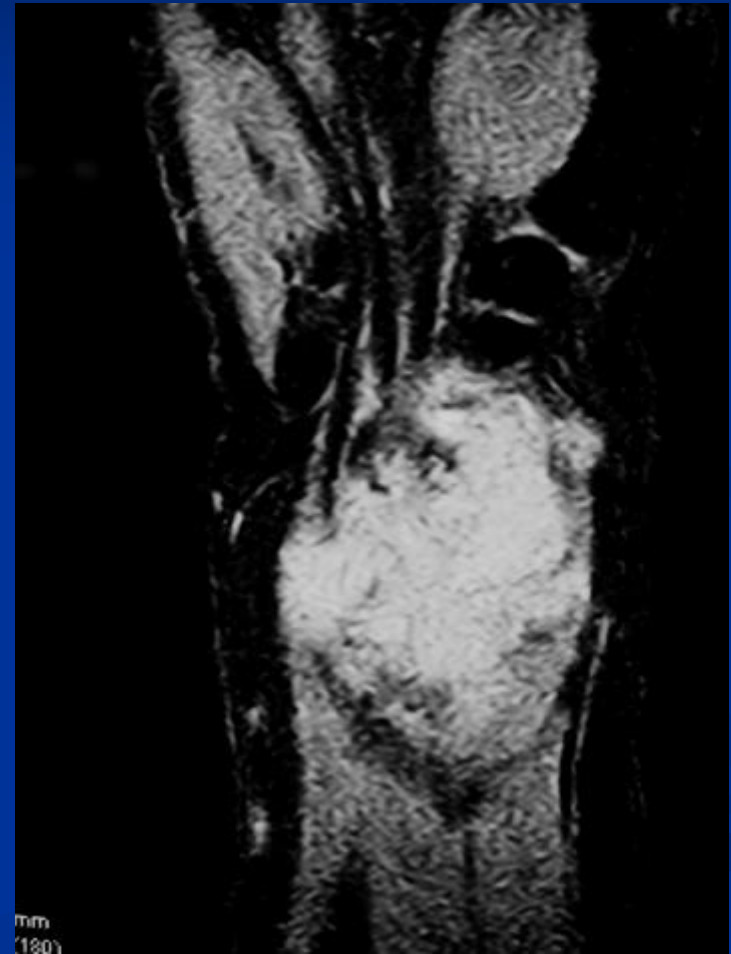
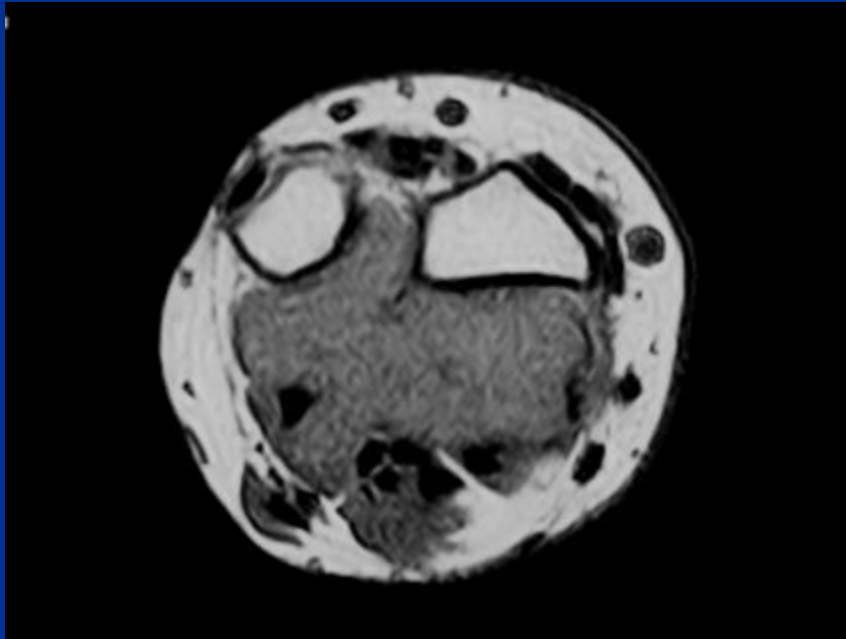
Synovial Sarcoma



Xray: Synovial Sarcoma Wrist Area Calcifications

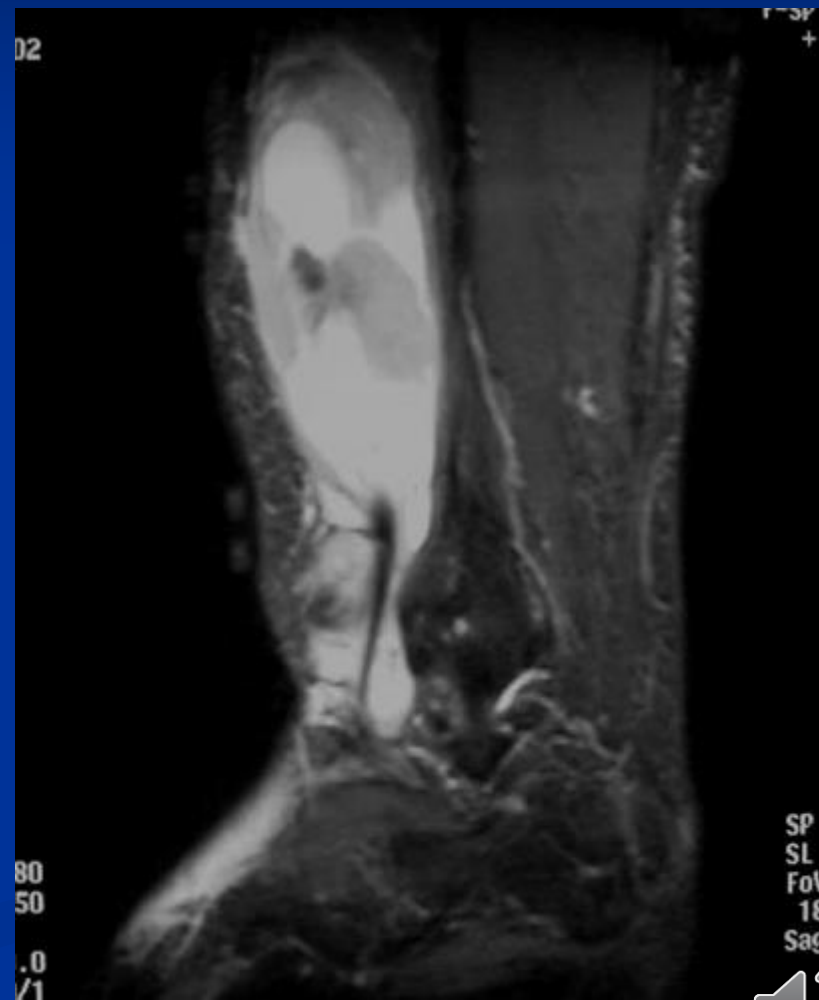
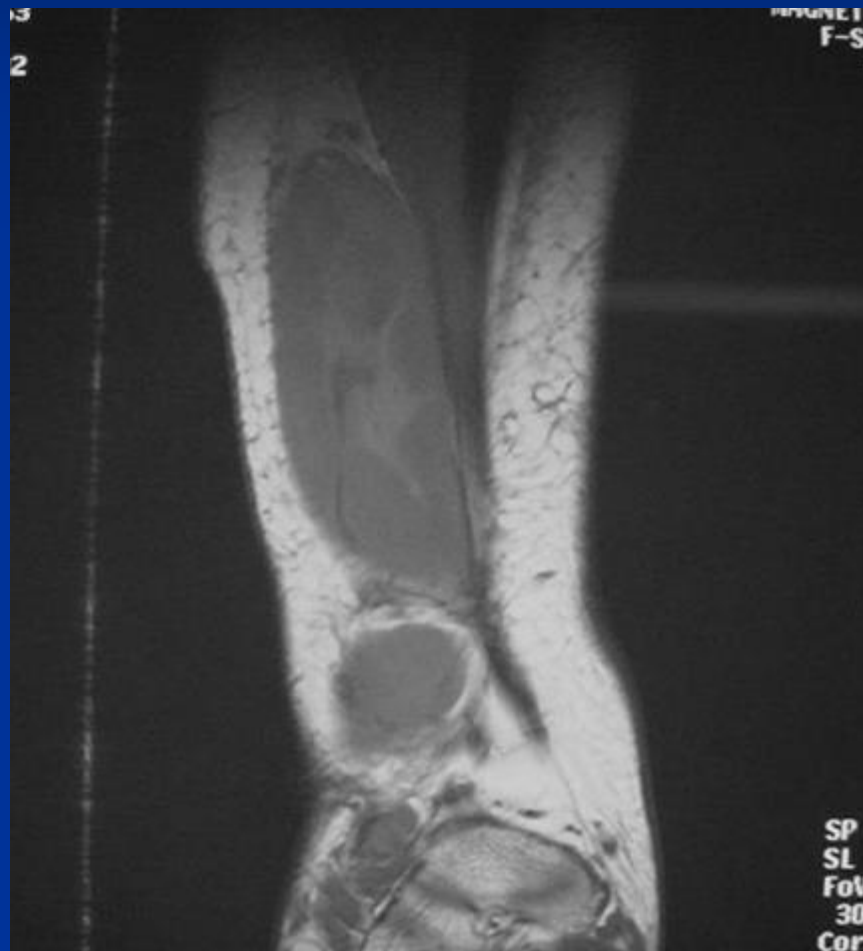
MRI: Synovial Sarcoma of Wrist/Forearm



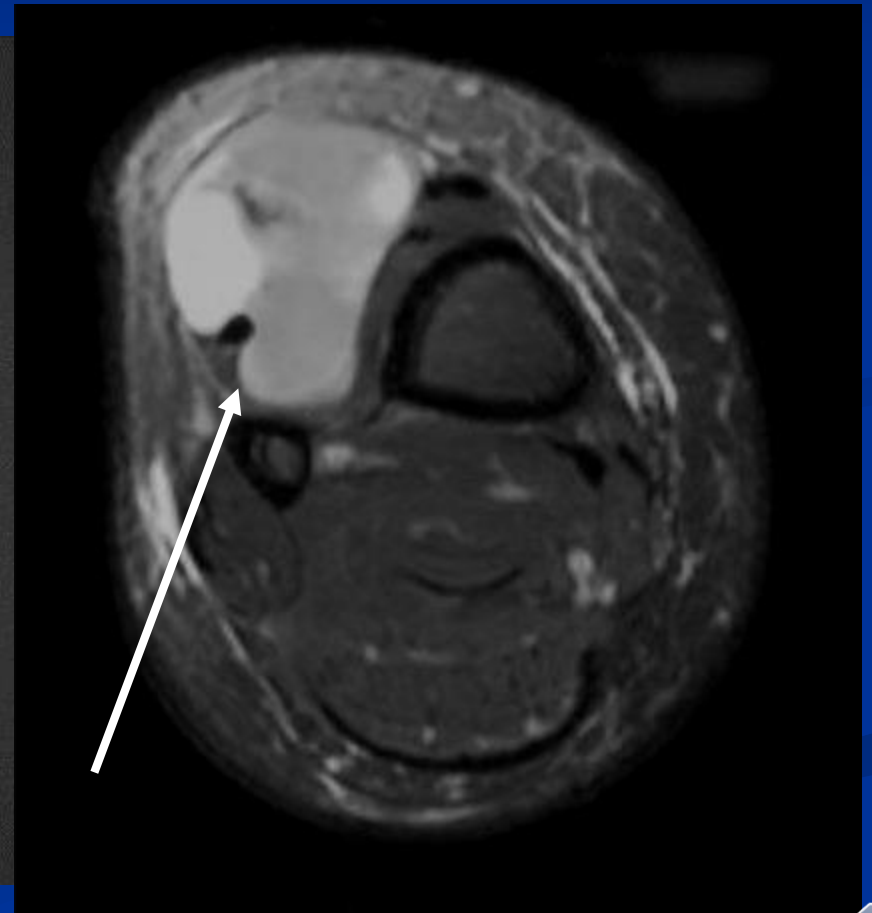
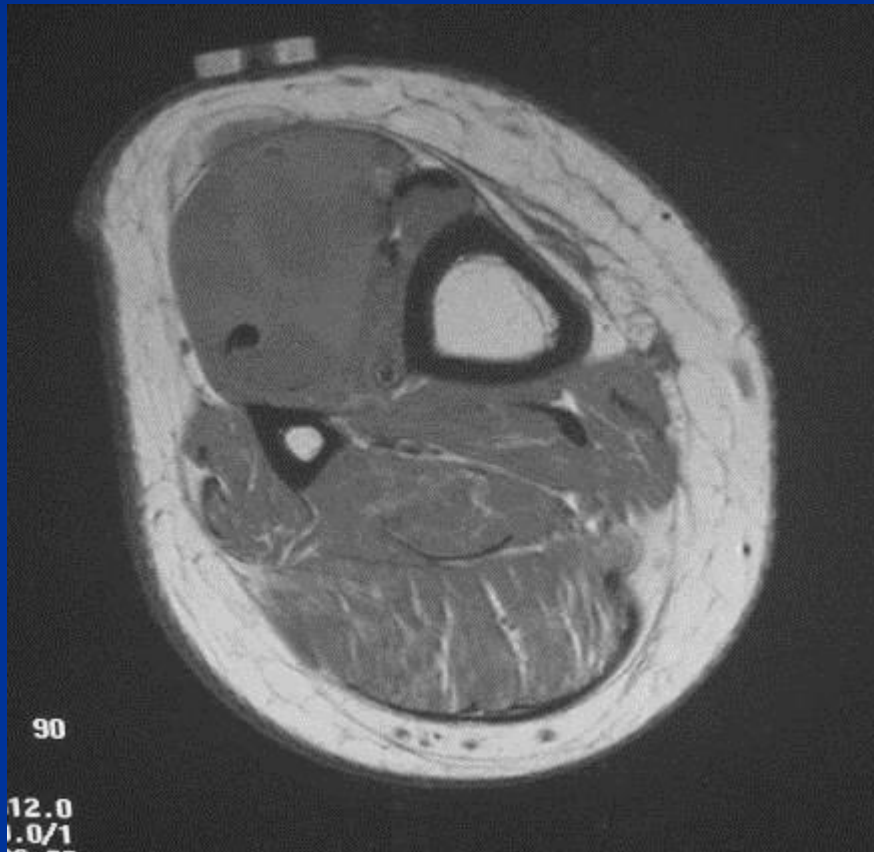MRI Synovial Sarcoma of Leg

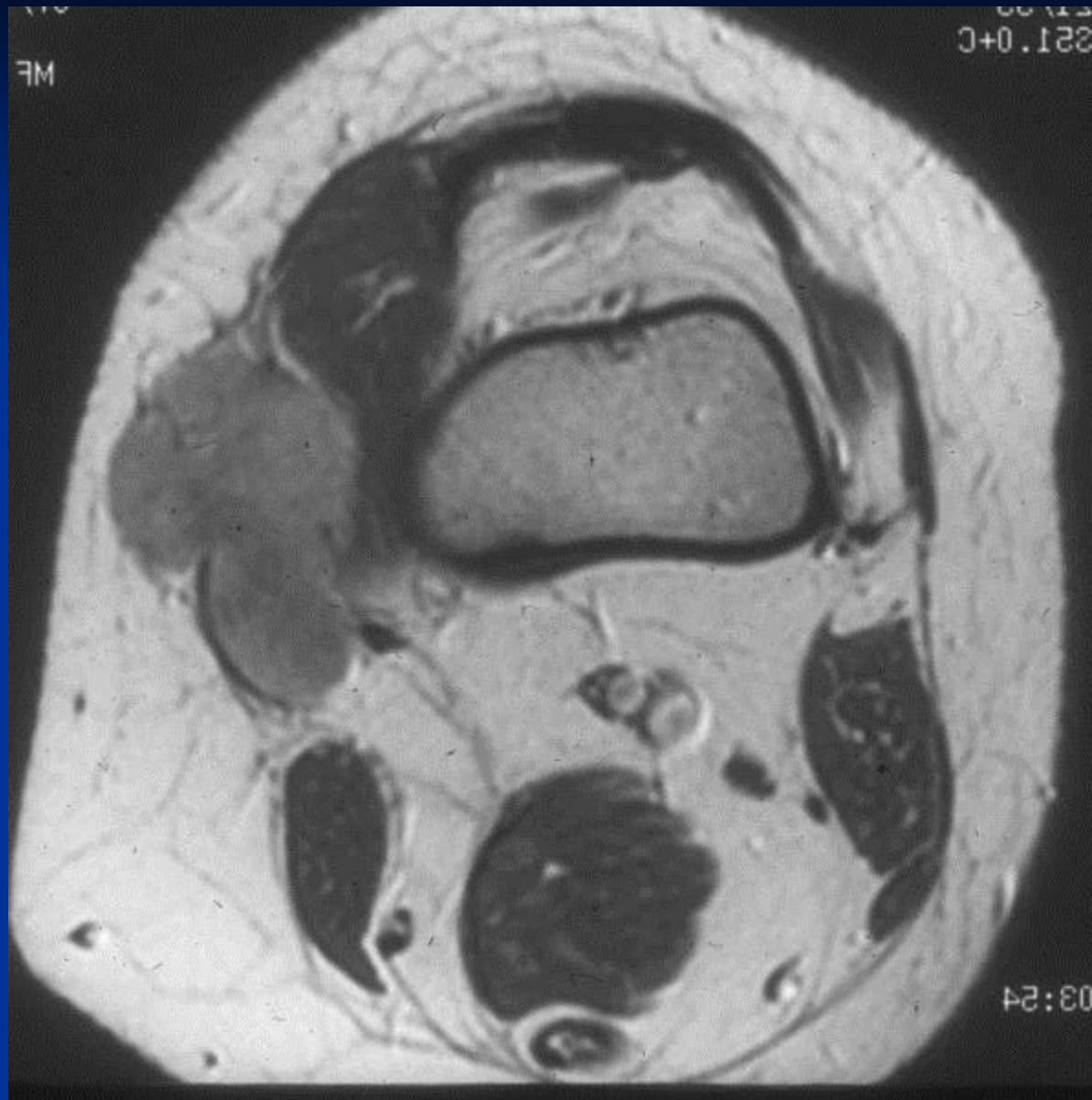
T2 Triple Signal



MRI Synovial Sarcoma of Leg

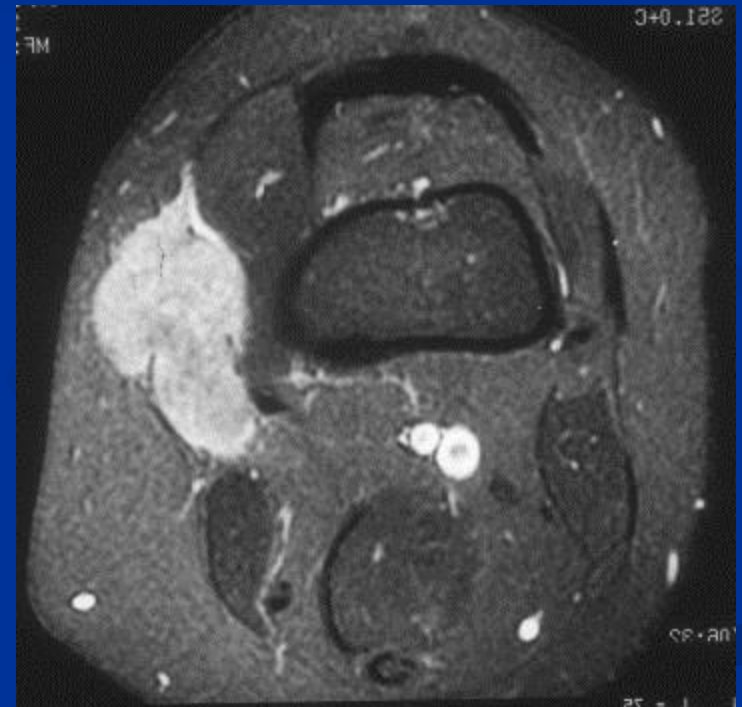
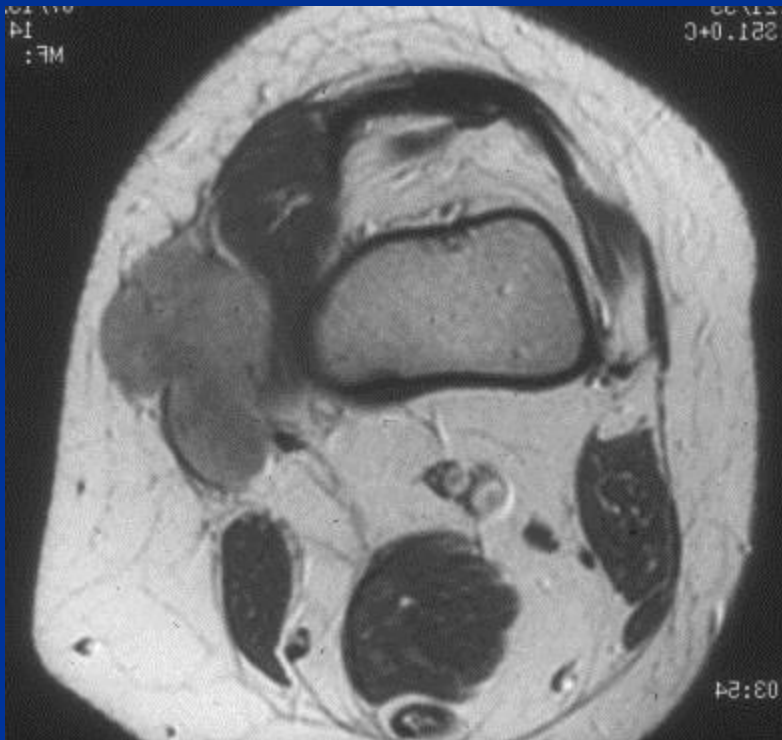Triple Signal on T2



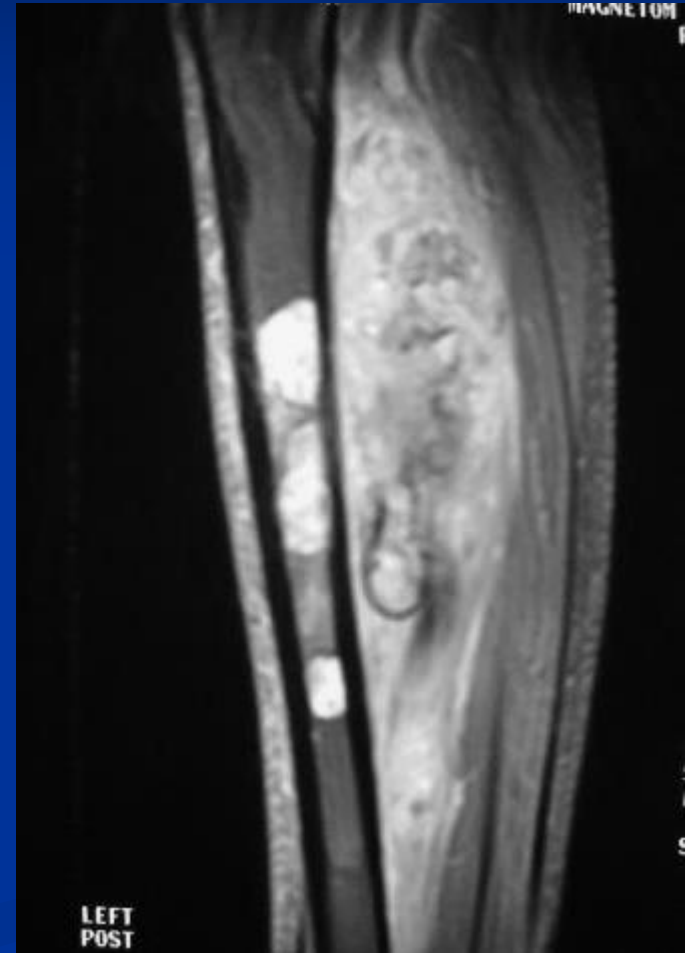
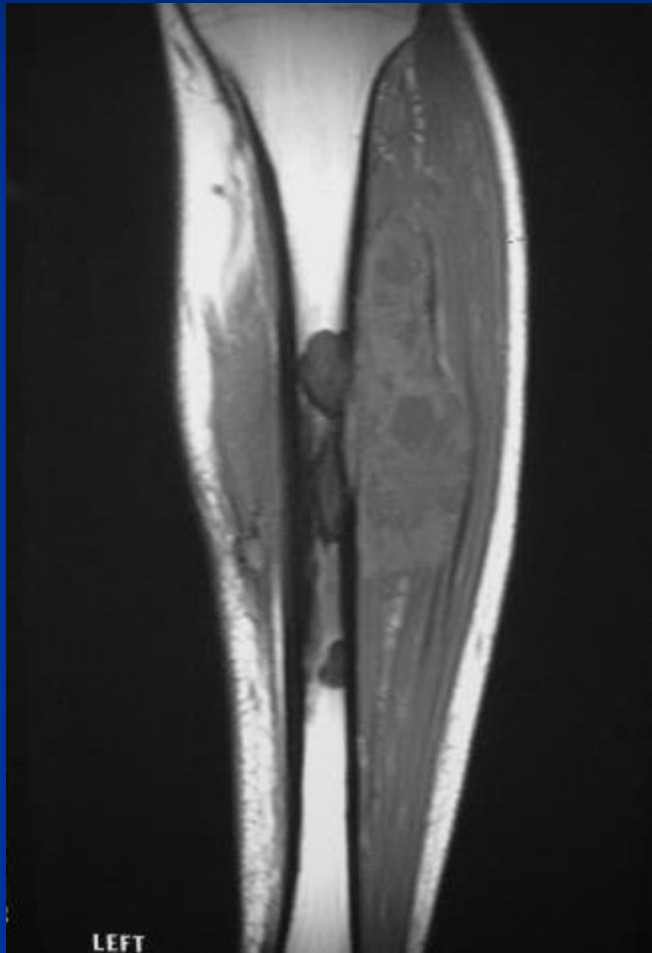


MRI Synovial Sarcoma

Lobular Growth Adjacent to Joint

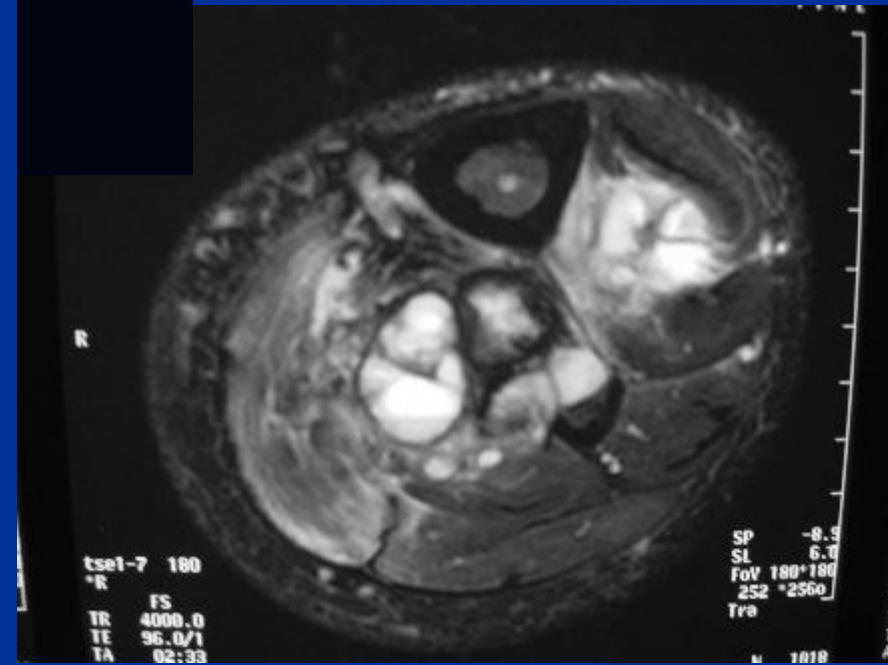
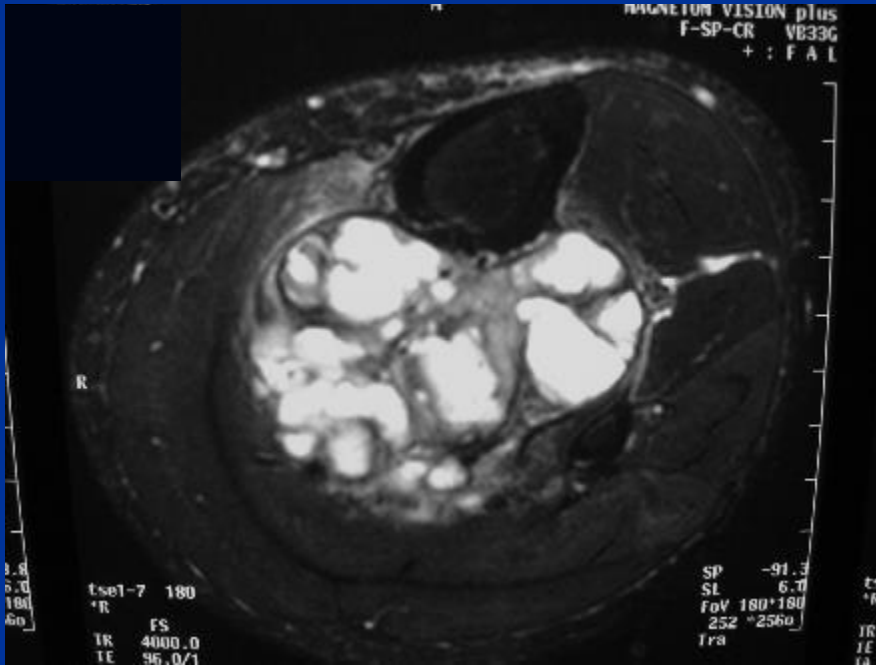


MRI Synovial Sarcoma of Leg Bone Invasion

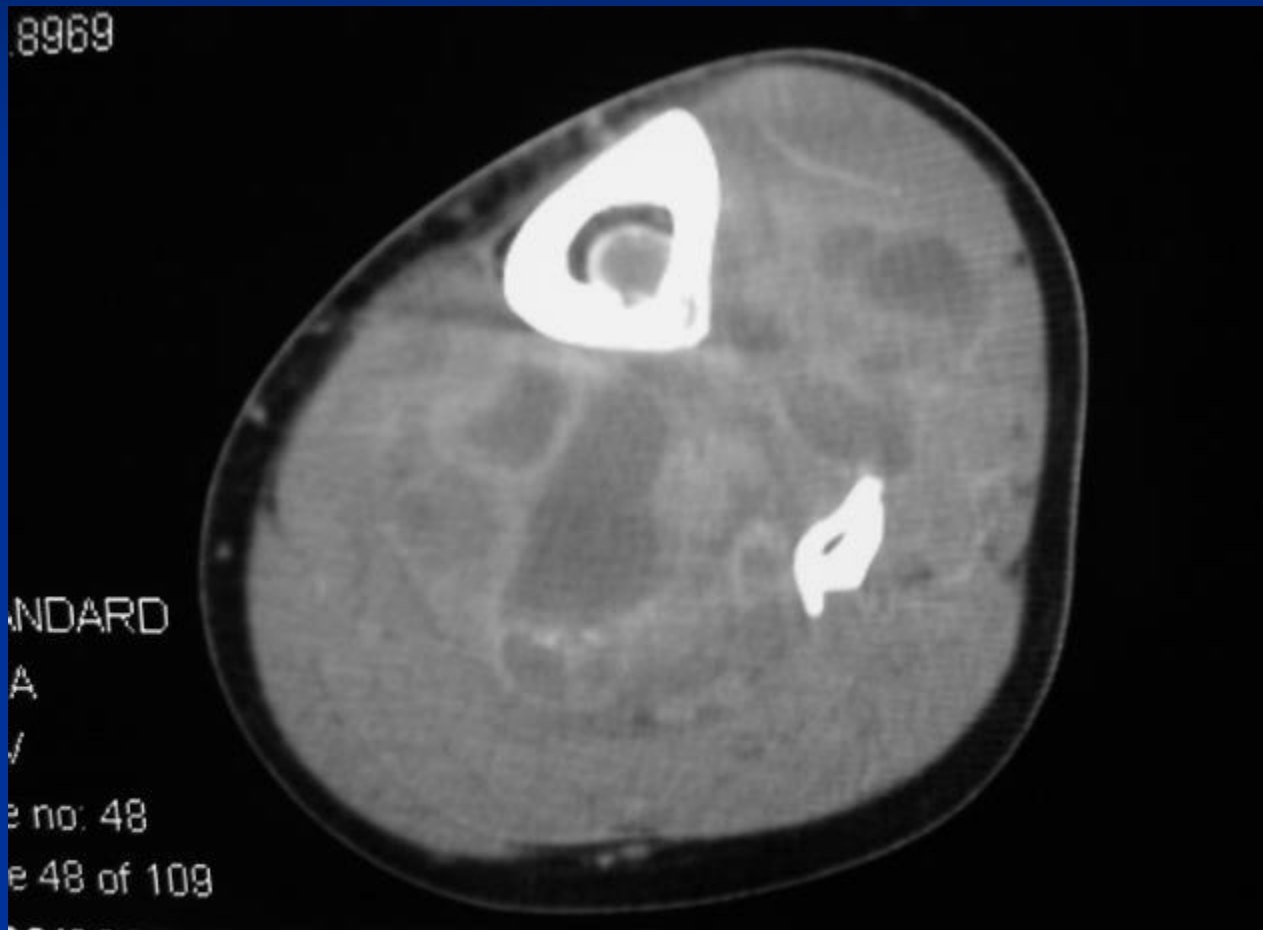

MRI T2 Synovial Sarcoma of Leg

Triple Signal on T2



CT Scan of Synovial Sarcoma of Leg Bone Involvement



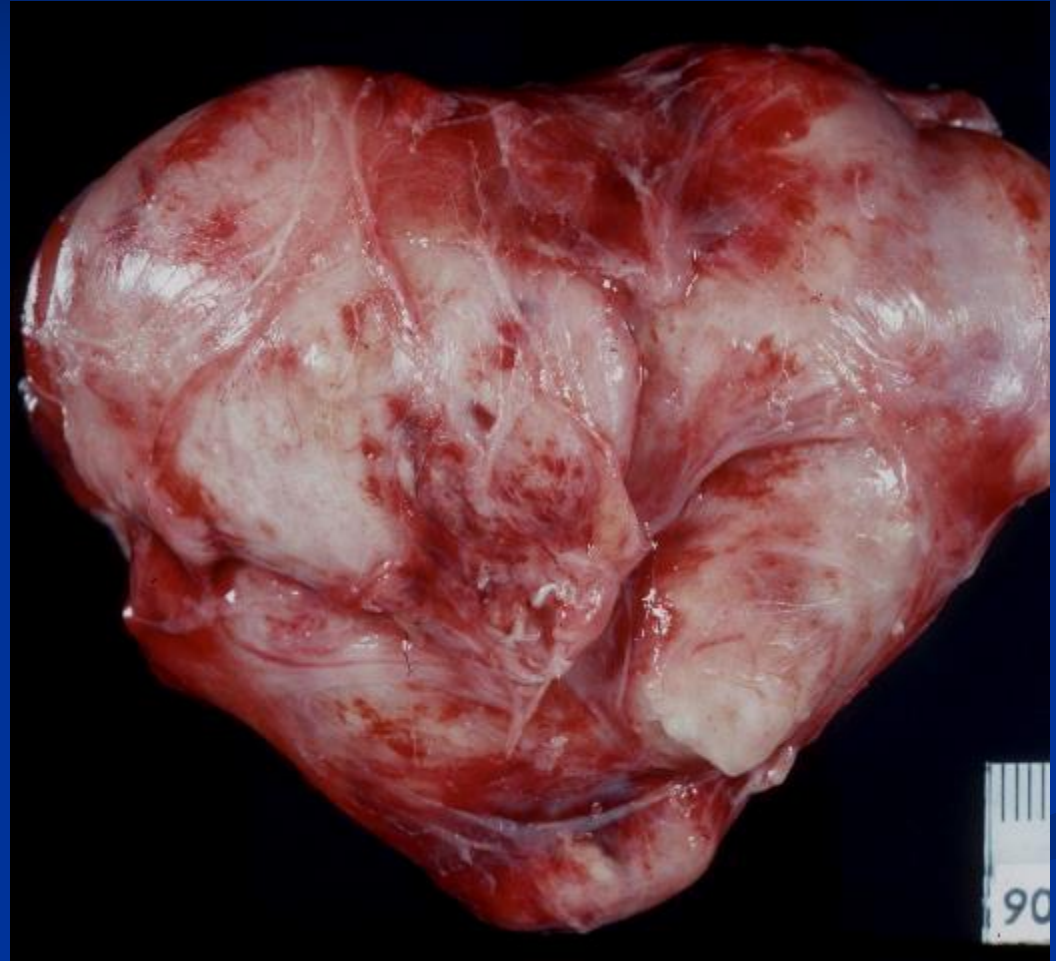
DDX Mineralization

- Synovial sarcoma (1/3)
- MFH
- Lipoma (benign mesenchymoma)
- Liposarcoma (osseous/cart. metaplasia)
- Malignant Mesenchymoma
- Hemangioma
- Synovial chondromatosis
- ST mets from GCT
- Tumoral calcinosis/gout
- ES
OGS/chondrosarcoma
- Melorheostosis
- Pilomatrixoma (SQ)

Pathology

Synovial Sarcoma

- Gross:
 - Yellow tan to gray
 - Soft to firm
 - Areas of cysts, necrosis and calcification



Pathology

Synovial Sarcoma

- Special Studies
 - Translocation **t(X;18) SYT-SSX** gene fusion transcript
 - 90% of cases
 - Immunohistochemistry: Biphasic and Monophasic forms
 - Vimentin positive (same as all sarcomas)
 - Cytokeratin and EMA (epithelial membrane antigen) positive
 - Positive in both biphasic and monophasic forms

Pathology: Synovial Sarcoma

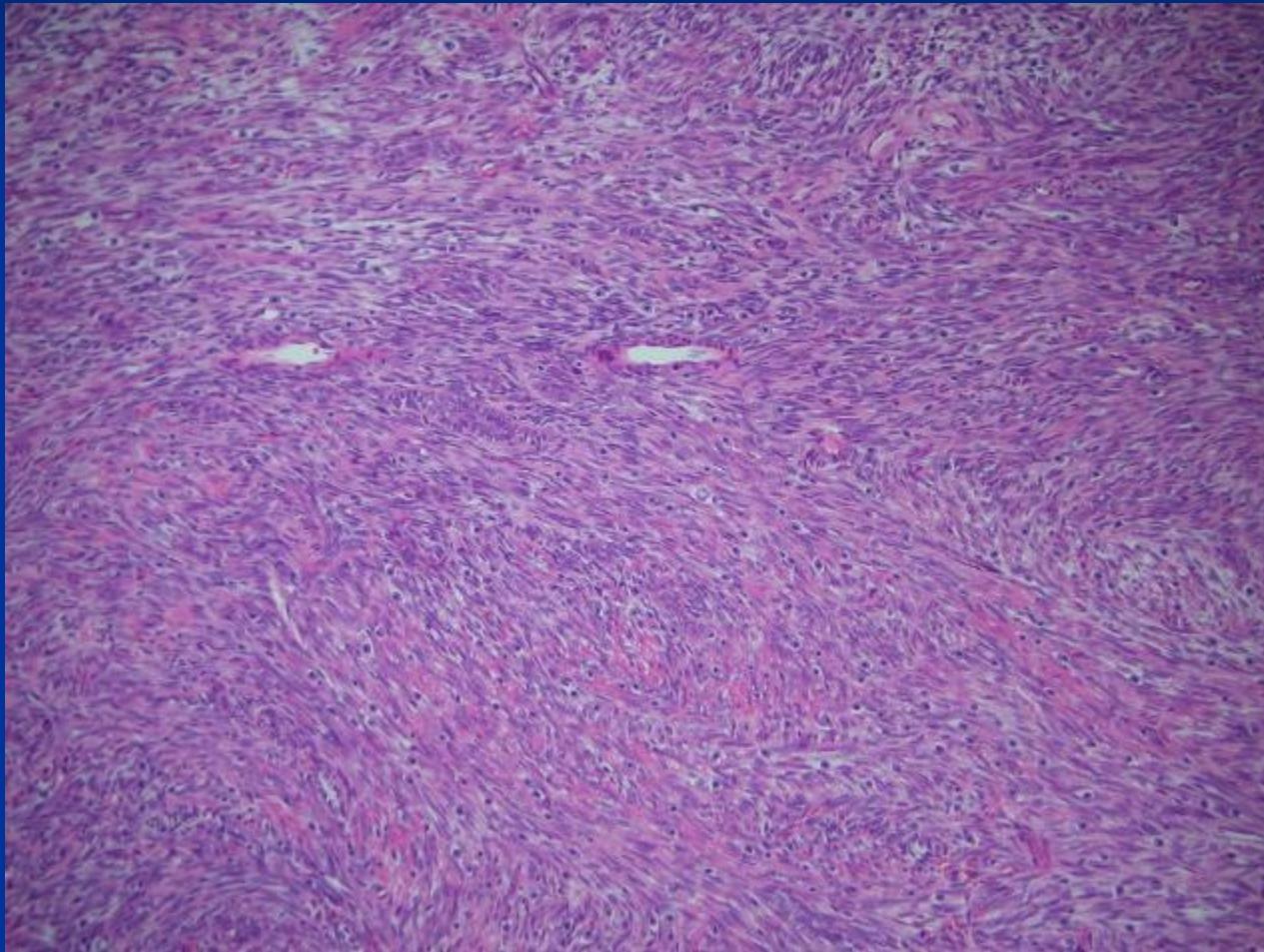
- Microscopic: **Biphasic**
 - Spindle cells intermingled with **epithelial components** (cuboidal or columnar cells)
 - Epithelial components form nests and glandular or tubular structures that may contain mucin

Pathology

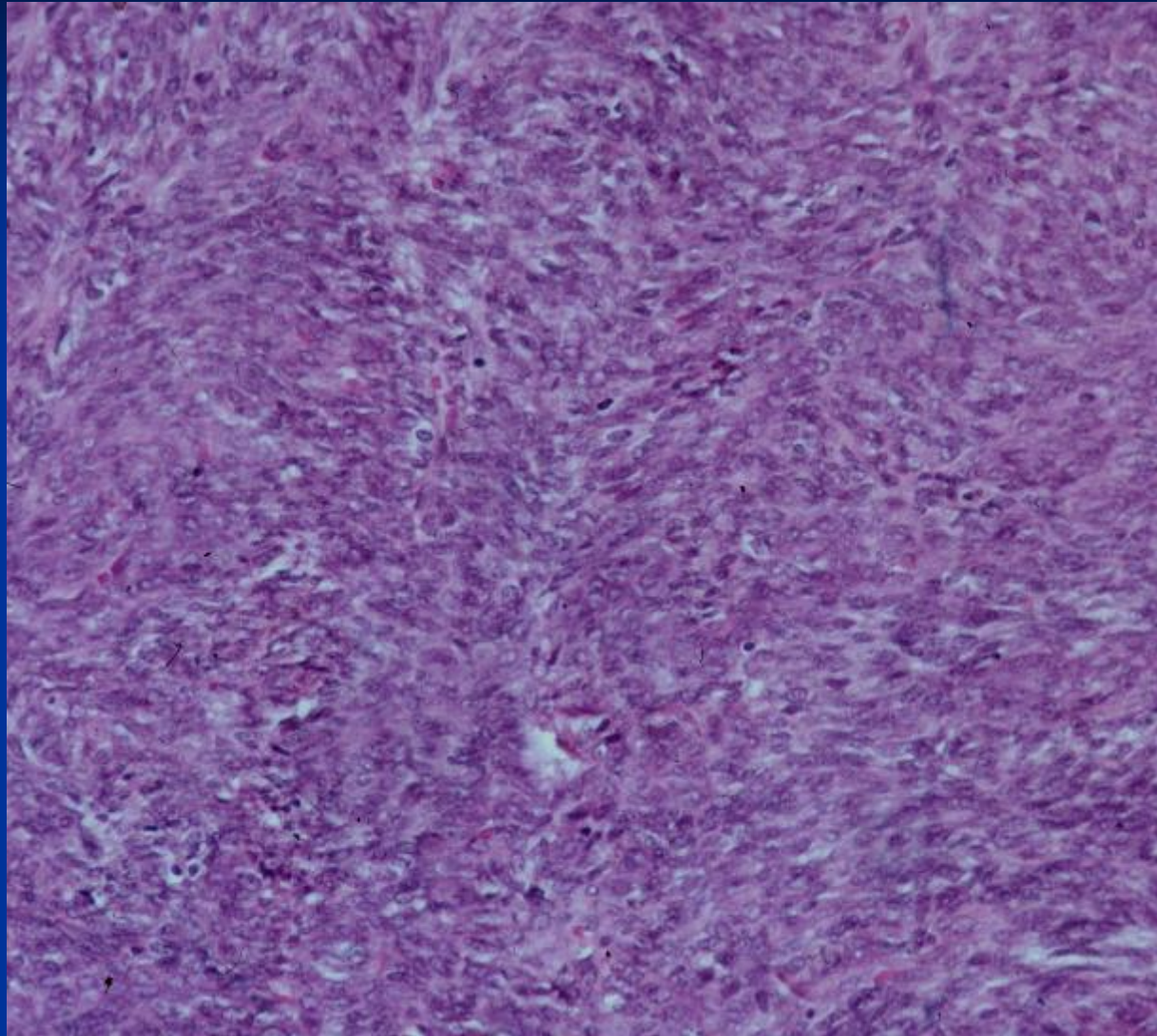
Synovial Sarcoma

- Microscopic: Monophasic Forms
 - Spindle cell component only
 - No epithelial components

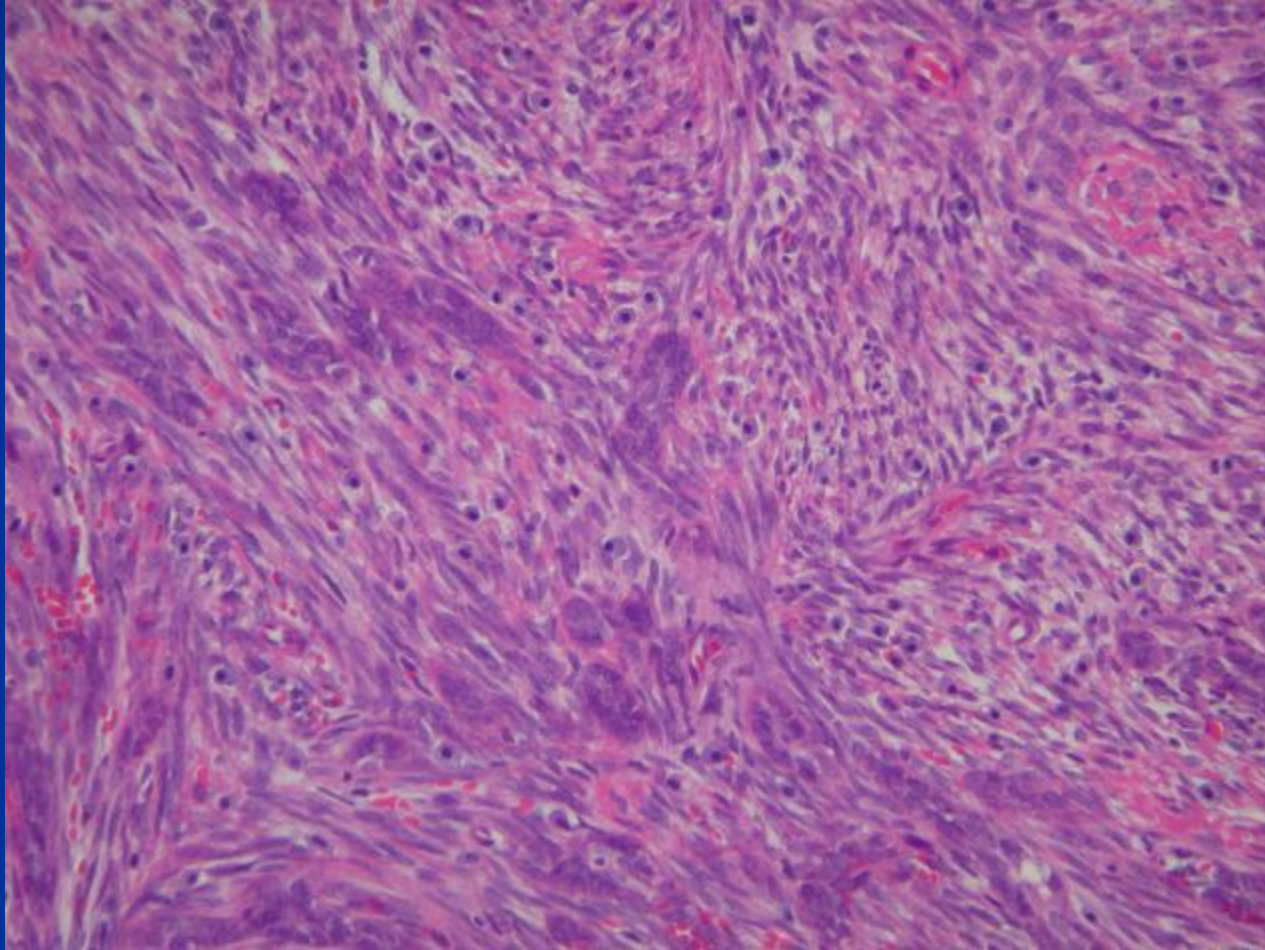
Pathology: Synovial Sarcoma



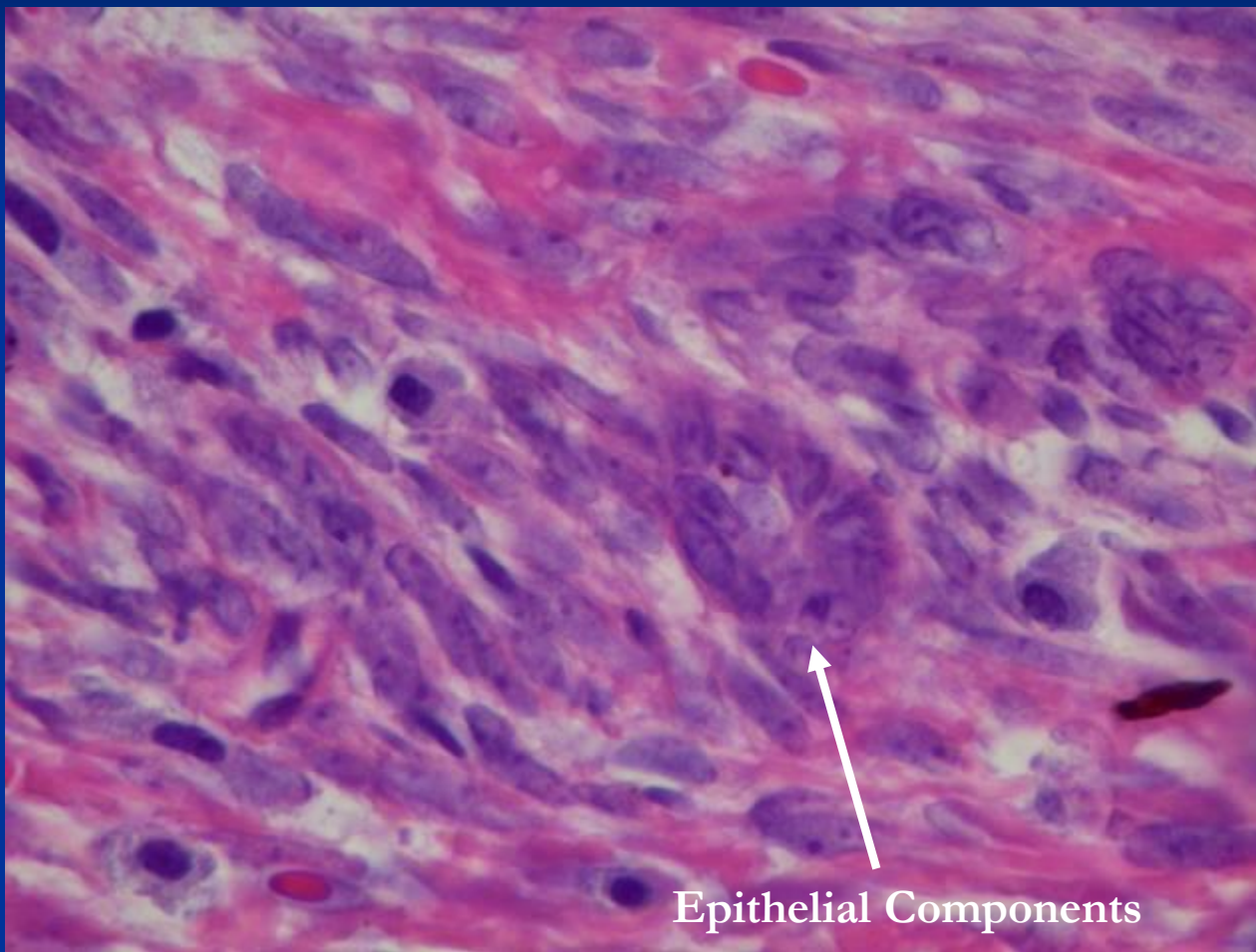
Synovial Sarcoma: Spindle Component



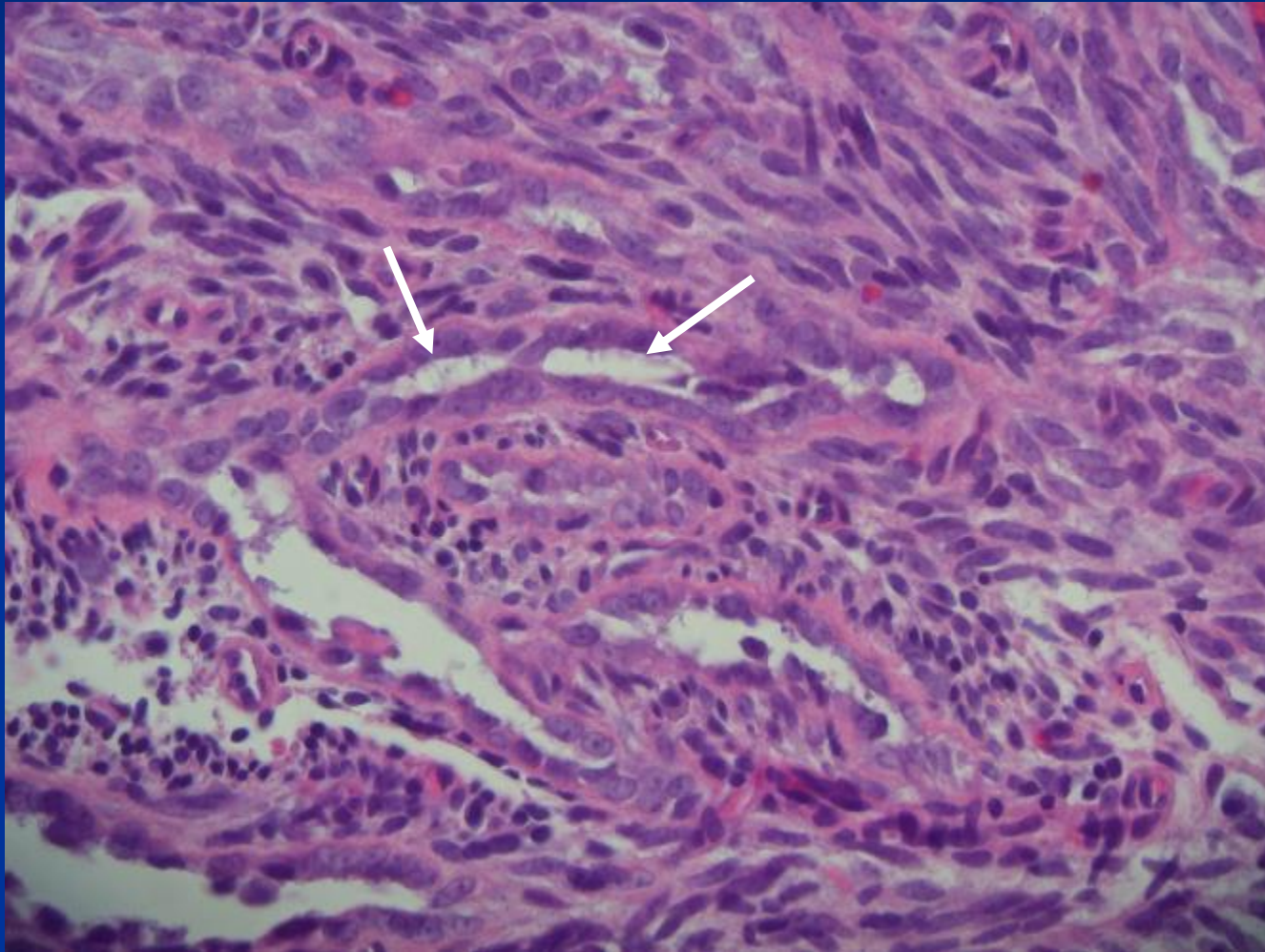
Synovial Sarcoma: Spindle Component Mixed with Epithelial Component



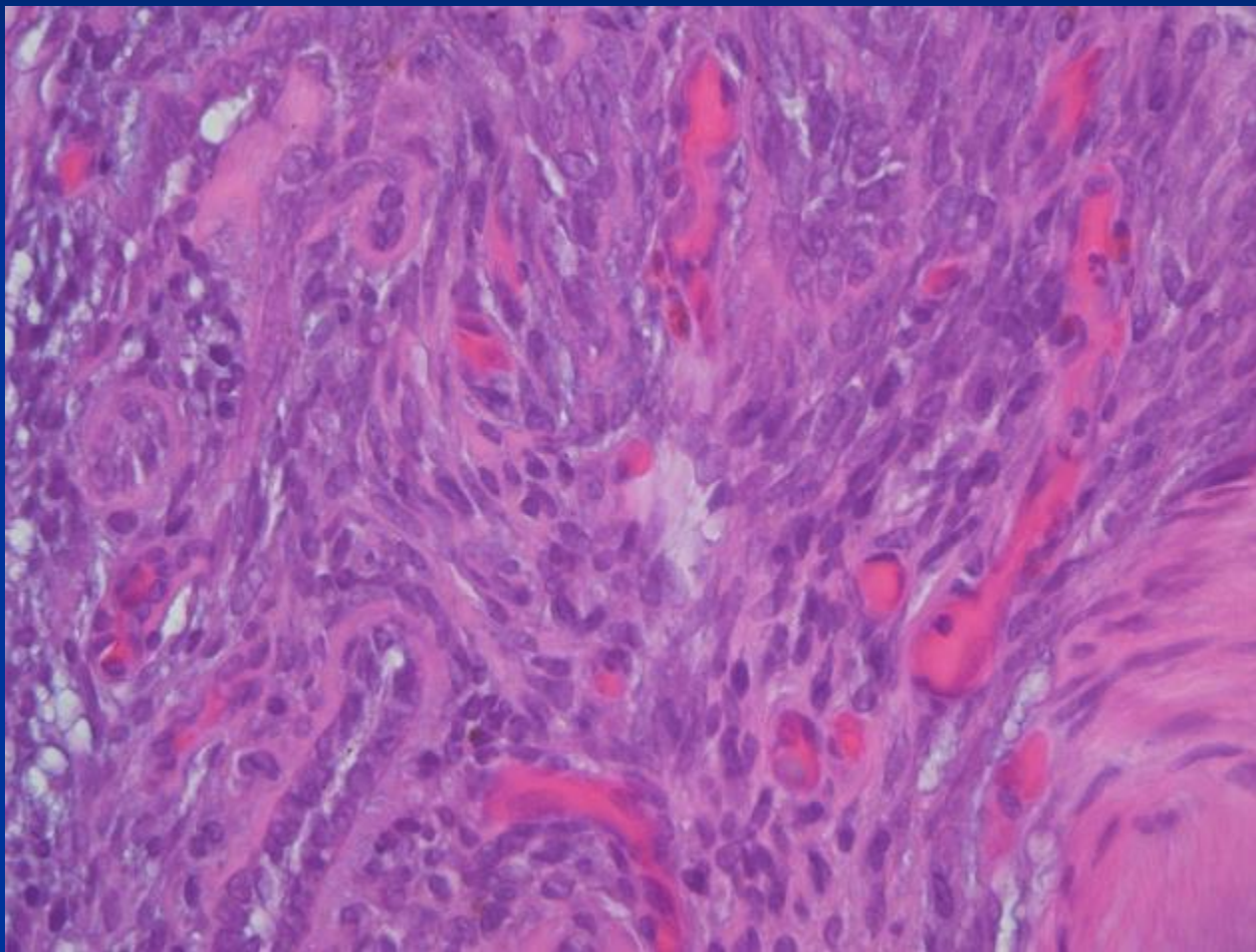
Synovial Sarcoma



Synovial Sarcoma: Epithelial Components Forming Glands



Synovial Sarcoma



Differential Diagnosis

- Malignant Peripheral Nerve Sheath Tumor (MPNST)
- Fibrosarcoma
- Hemangiopericytoma
- Monophasic Synovial Sarcoma

Treatment and Prognosis

- Surgery: Wide Resection and Postoperative Radiation whenever feasible
 - Amputation for unresectable tumors
- Metastases:
 - Lungs
 - Lymph Nodes
 - Bone Marrow
- Survival:
 - Overall 5 year survival: approximately 60-65%
 - 10 year survival approximately 35%
 - High incidence of late metastases

Rhabdomyosarcoma

- **Definition:** Malignant tumors composed of cells with light microscopic, electron microscopic or immunological evidence of skeletal muscle differentiation.
- Light microscopic features: cross striations within cells (**rhabdomyoblasts**)
- Ultrastructurally: sarcomeres
- Immunologically: Must express desmin, myoglobin, MyoD1 or myogenin
- Presence of fusion genes PAX3-FKHR and PAX7-FKHR are specific for alveolar rhabdomyosarcoma

Types of Rhabdomyosarcoma

- **Embryonal:** small round blue cell tumor
 - Most Common 70-75%
 - Occurs primarily in children
- **Alveolar:** solid and alveolar growth of cells
 - 20-25% of all rhabdomyosarcomas
 - Occurs primarily in children and adolescents
 - Worse prognosis compared to embryonal
- **Pleomorphic:** spindle and pleomorphic cells
 - Very rare <5% of rhabdomyosarcomas
 - Age usually > 40 years
 - High grade; Features similar to MFH but stains for skeletal muscle markers

Rhabdomyosarcoma

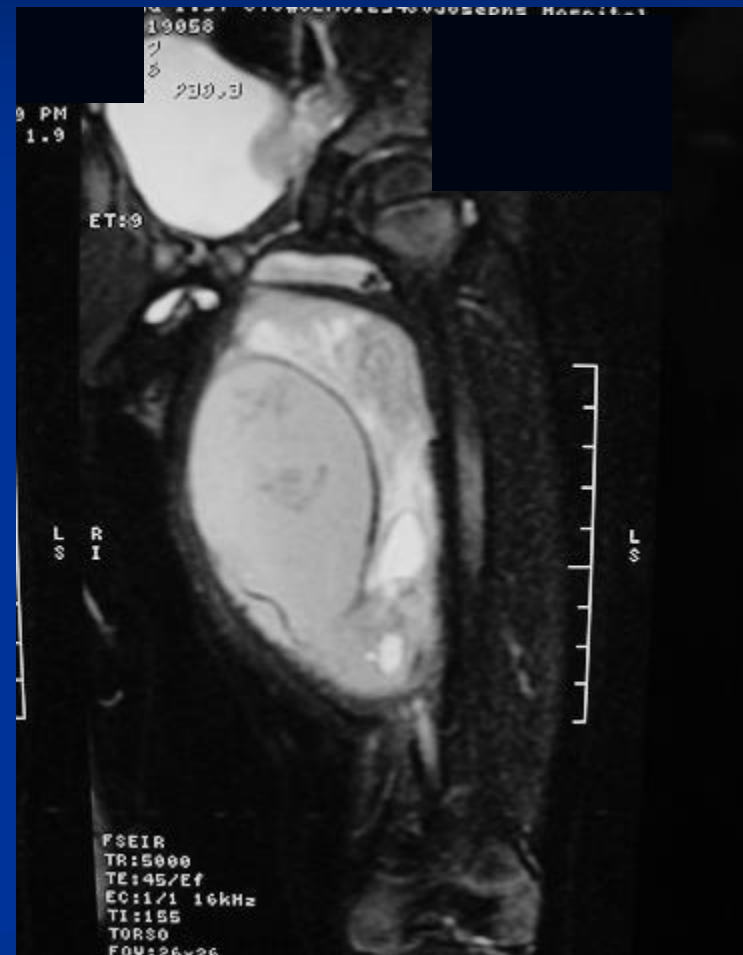
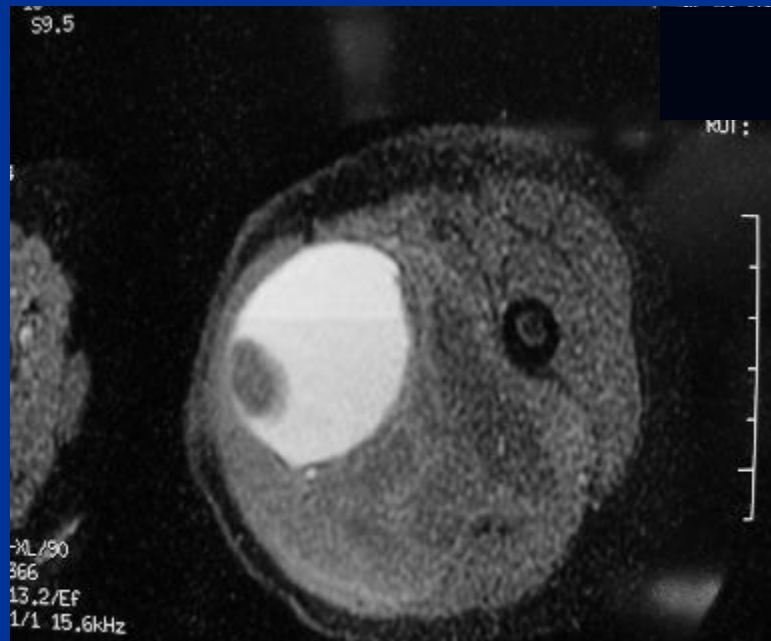
- Most common malignant soft tissue tumor in children
- 10% of all childhood neoplasms
- **Age:** 1st two decades most commonly
- **Sites:** Embryonal more common in head and neck;
Alveolar more common in extremities
 - Head and Neck (most common)
 - GU tract
 - Lower Extremity > Upper extremity
 - Retroperitoneum/Pelvis
 - Trunk
- **Clinical:** Painless or painful mass

Radiology

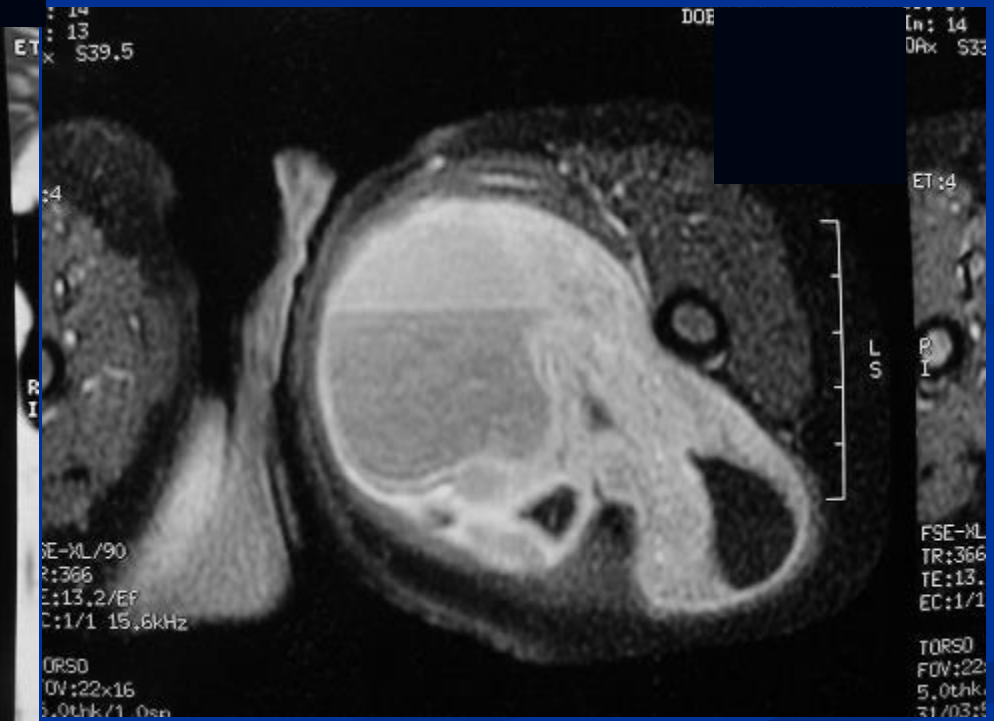
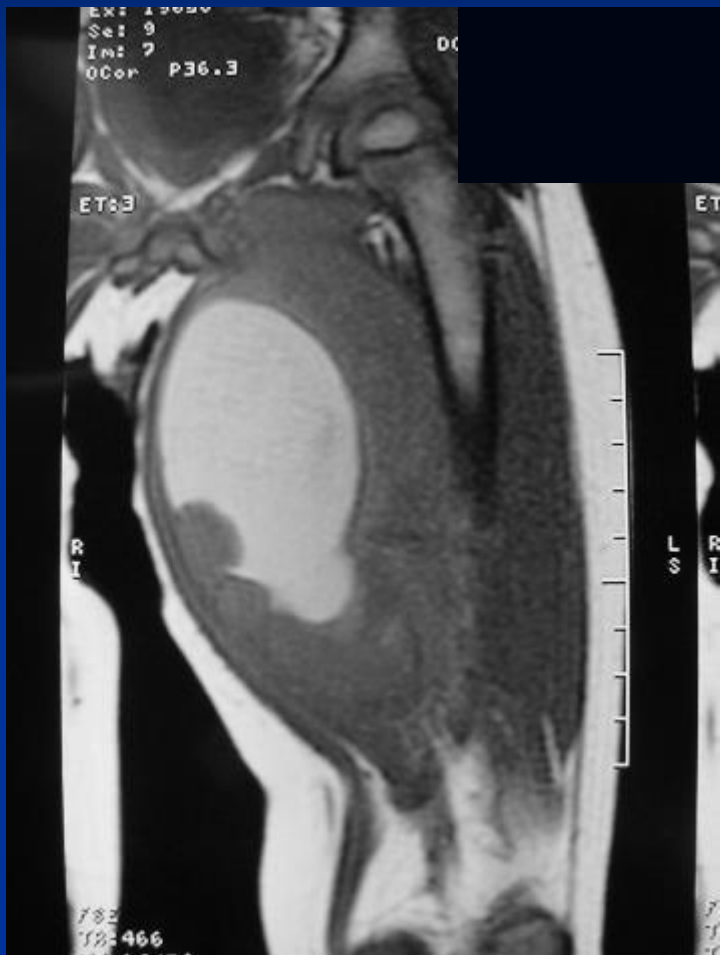
Rhabdomyosarcoma

- No specific radiological features
- 24% invade adjacent bone
- MRI: Heterogeneous mass (Does not follow signal of skeletal muscle)
 - T1: Isointense to skeletal muscle (intermediate signal)
 - T2: Hyperintense (high signal)
 - Often demonstrate prominent vascularity (large flow voids) with serpentine high flow vessels
 - Marked enhancement with gadolinium
 - May remain low to intermediate signal on T2 if there is extensive fibrous tissue within the tumor

MRI Rhabdomyosarcoma



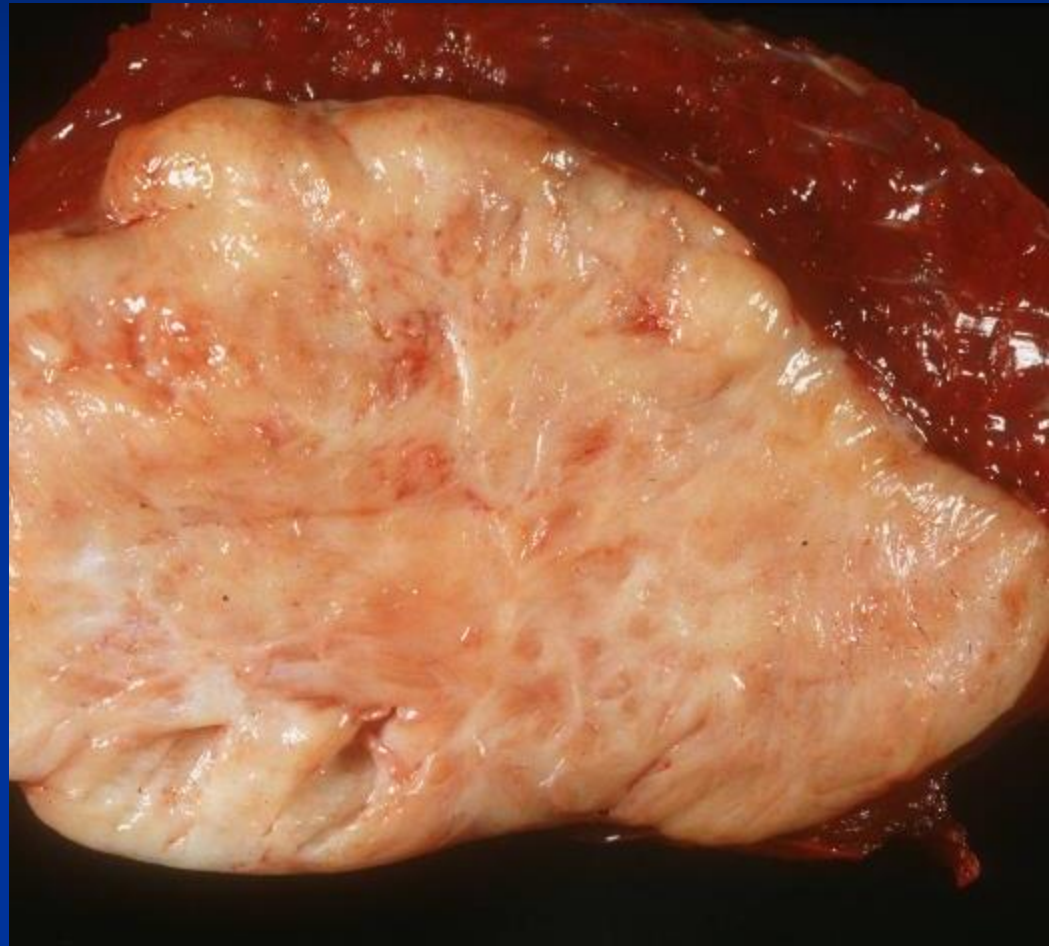
MRI Rhabdomyosarcoma



Pathology

Rhabdomyosarcoma

- Gross:
 - Fleshy, solid and well circumscribed
 - Hemorrhage and necrosis evident



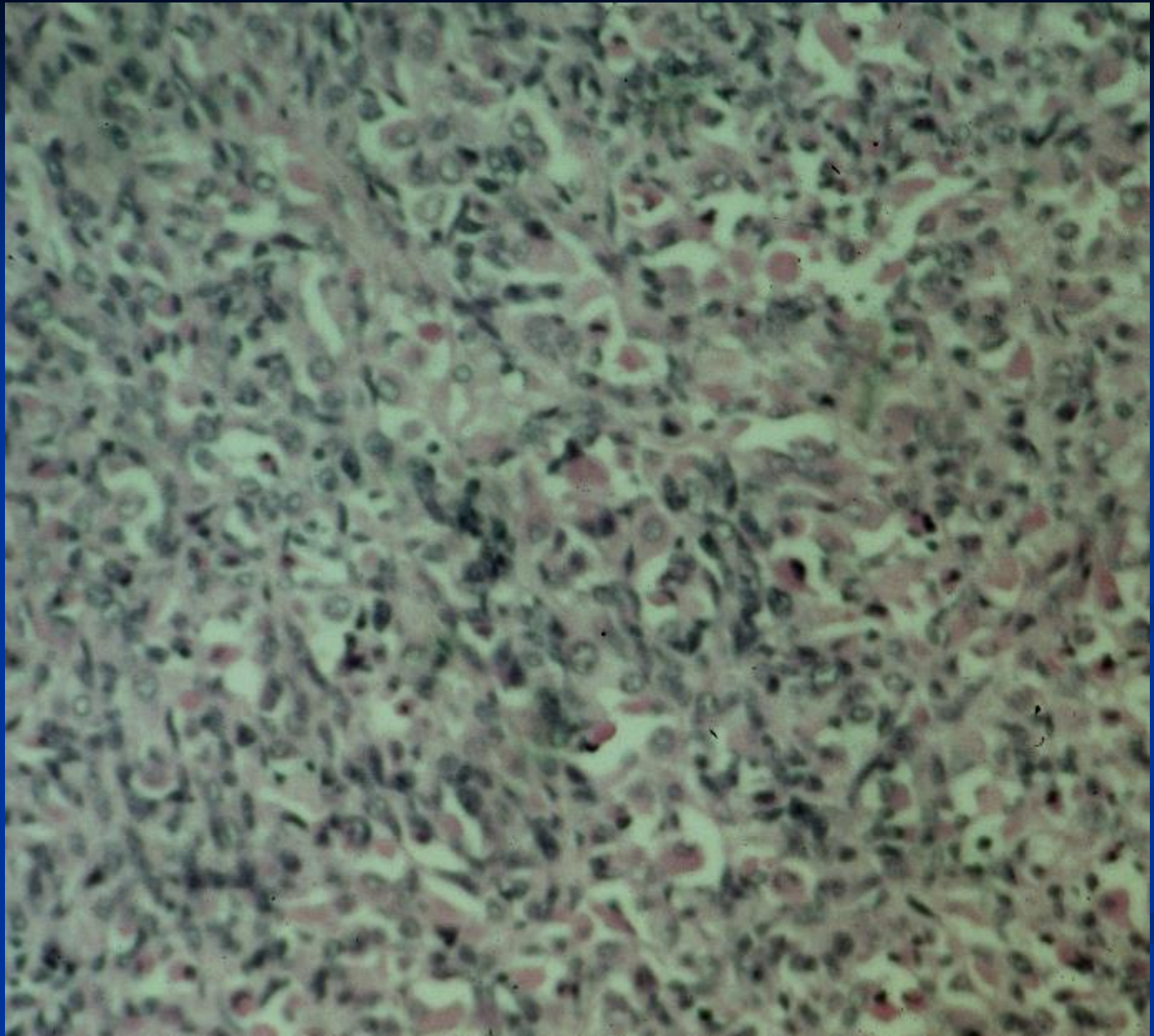
Pathology: Rhabdomyosarcoma

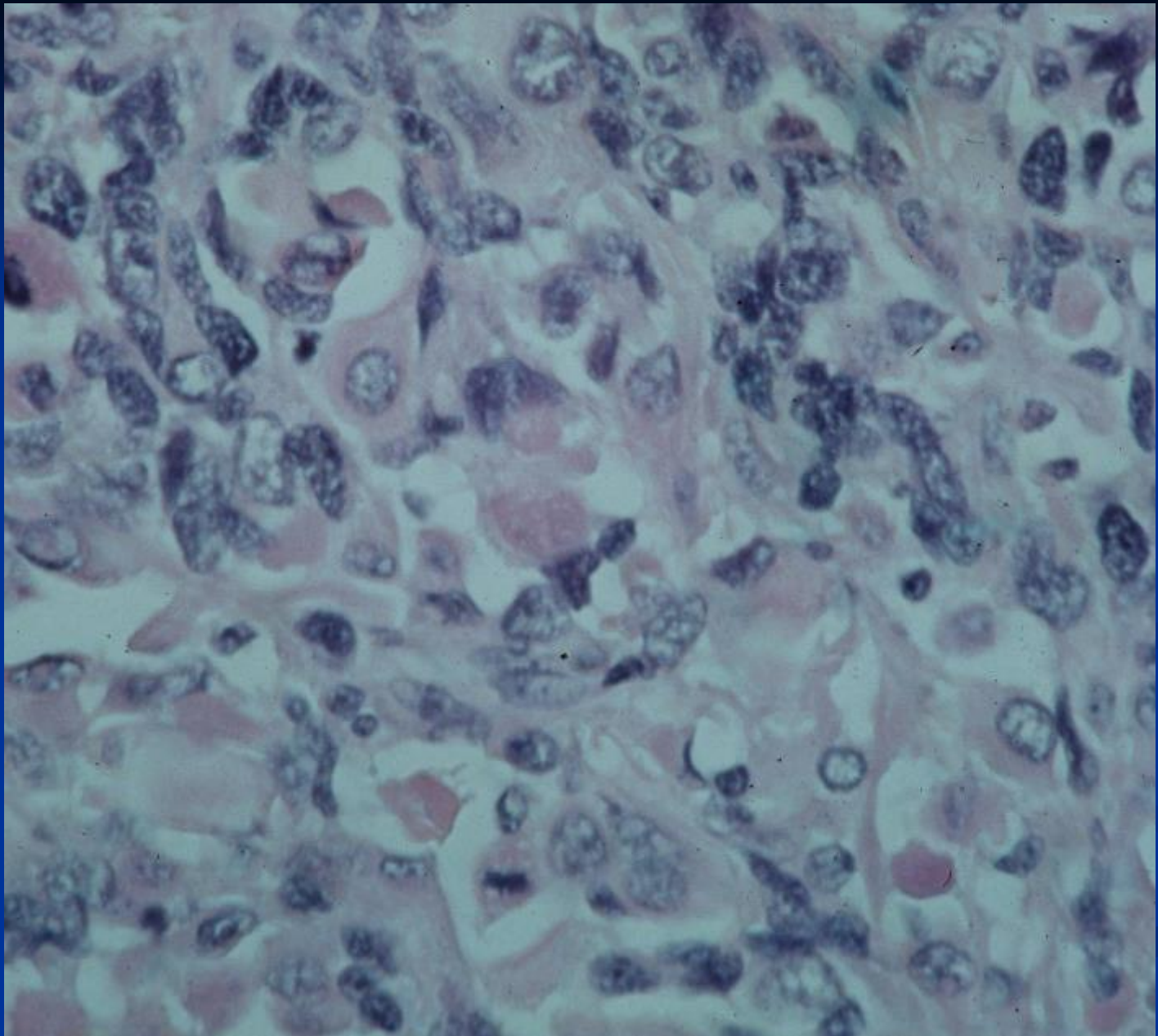
- Microscopic:
 - Embryonal
 - Small round blue cell tumor
 - **Rhabdomyoblast**: Well differentiated will have **Cross Striations**
 - Tadpole configuration (tapering bipolar configuration)
 - Alveolar: Tumor cells grow in nests or clusters at least focally
 - **Identify rhabdomyoblasts with cross striations**

Pathology

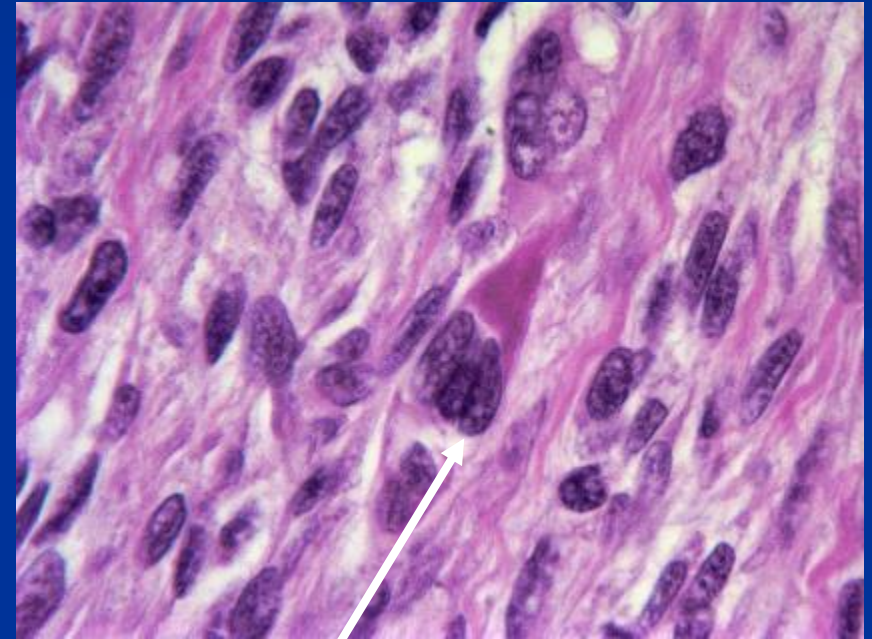
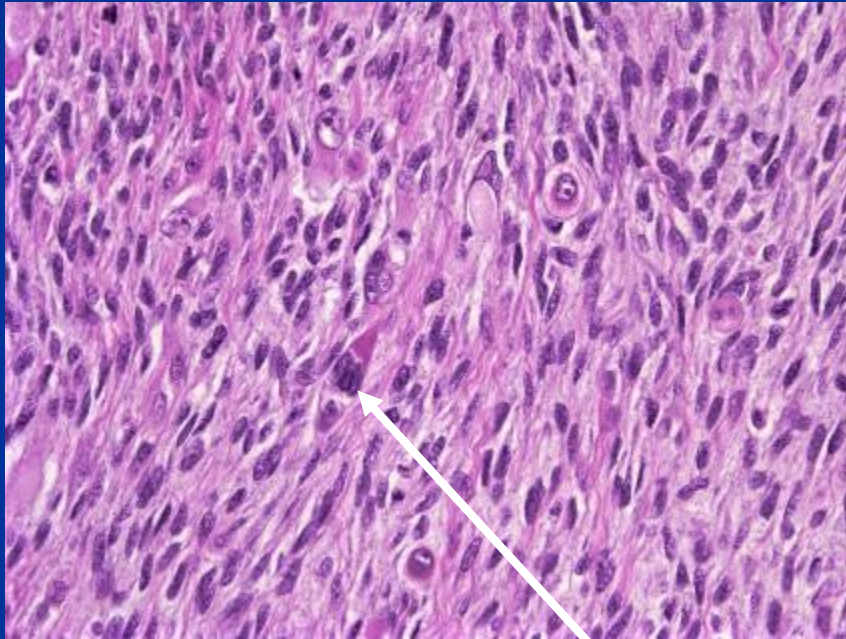
Rhabdomyosarcoma

- Immunohistochemistry
 - Desmin and Actin Positive (>90%)
 - MyoD1 and Myogenin positive: stain nuclei (>90%)
 - Myogenic regulatory proteins
 - Vimentin positive
- Genetic Studies
 - No reliable genetic study for Embryonal
 - Alveolar: Fusion Genes
 - t(2;13) PAX3/FKHR
 - t(1;13) PAX7/FKHR



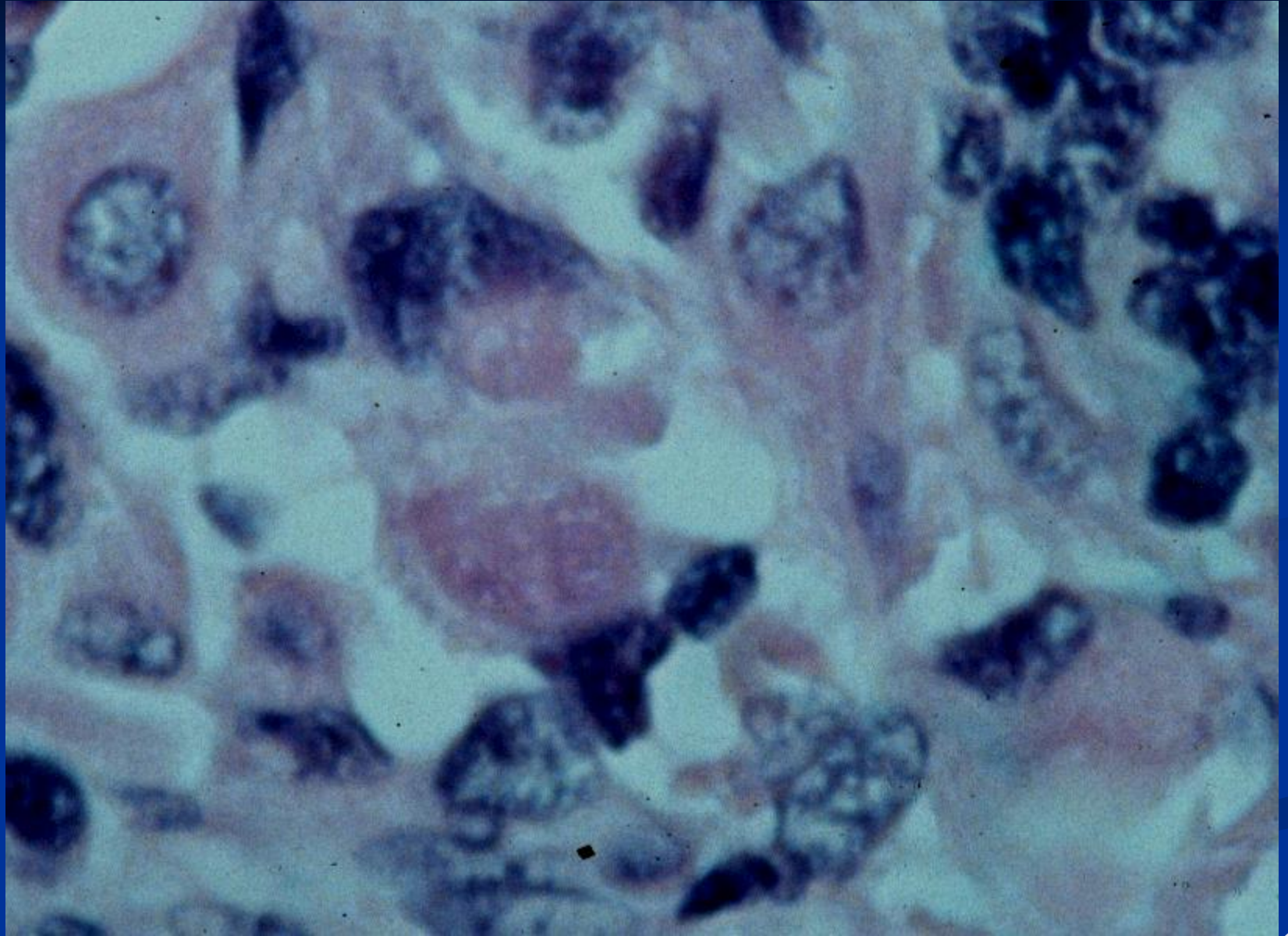


Rhabdomyosarcoma: Rhabdomyoblast

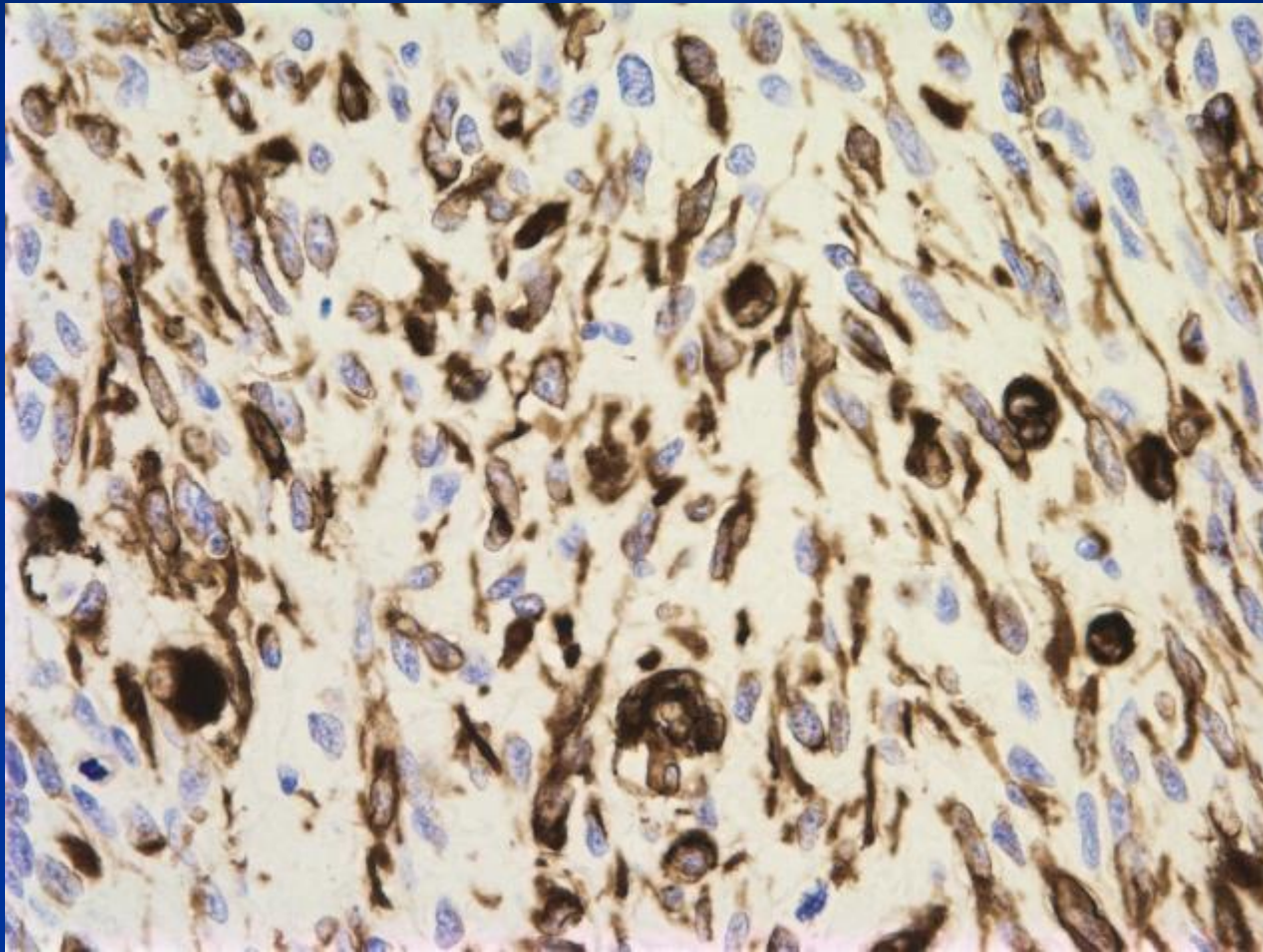


Rhabdomyoblast

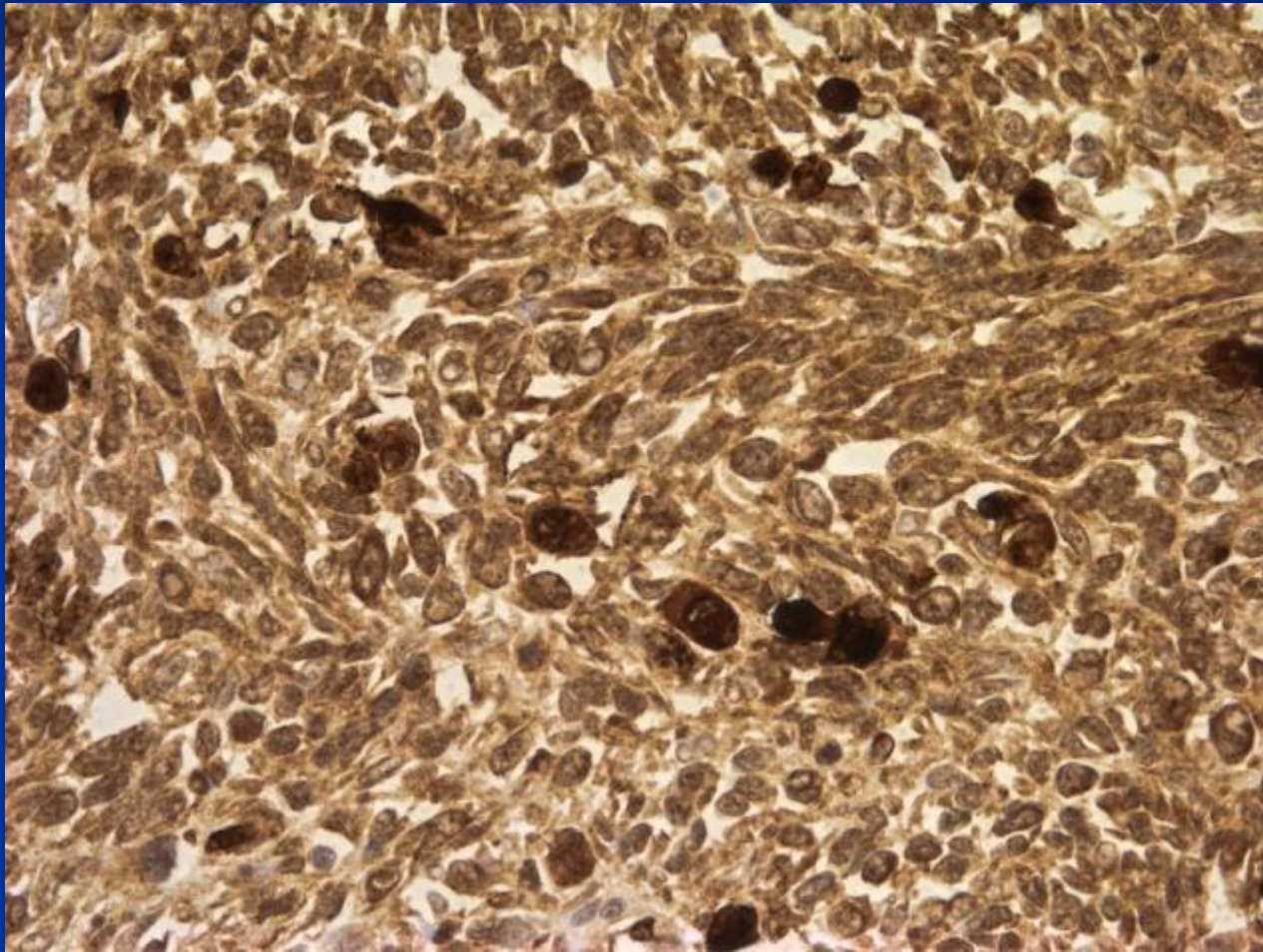




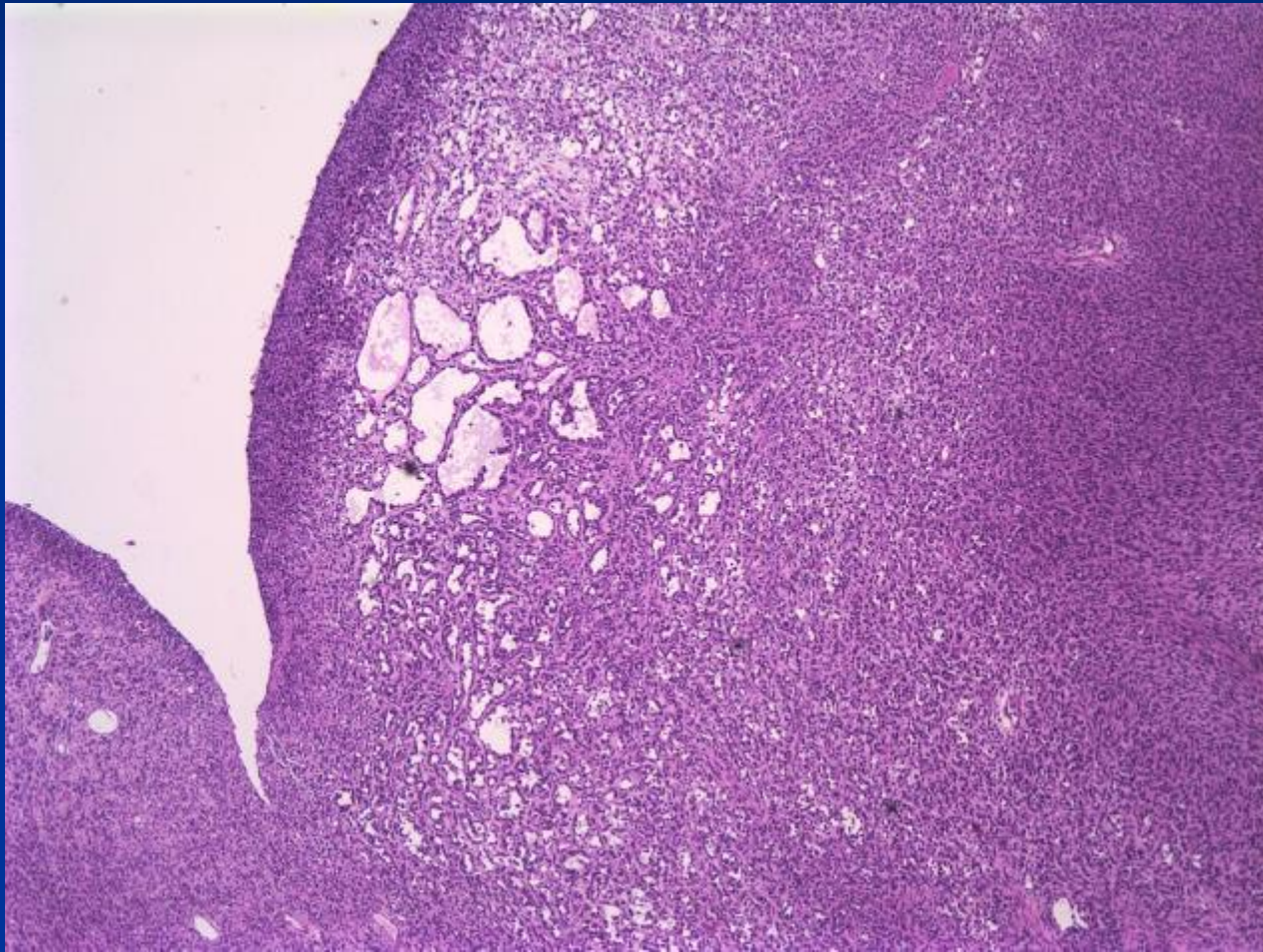
Rhabdomyosarcoma Desmin Stain



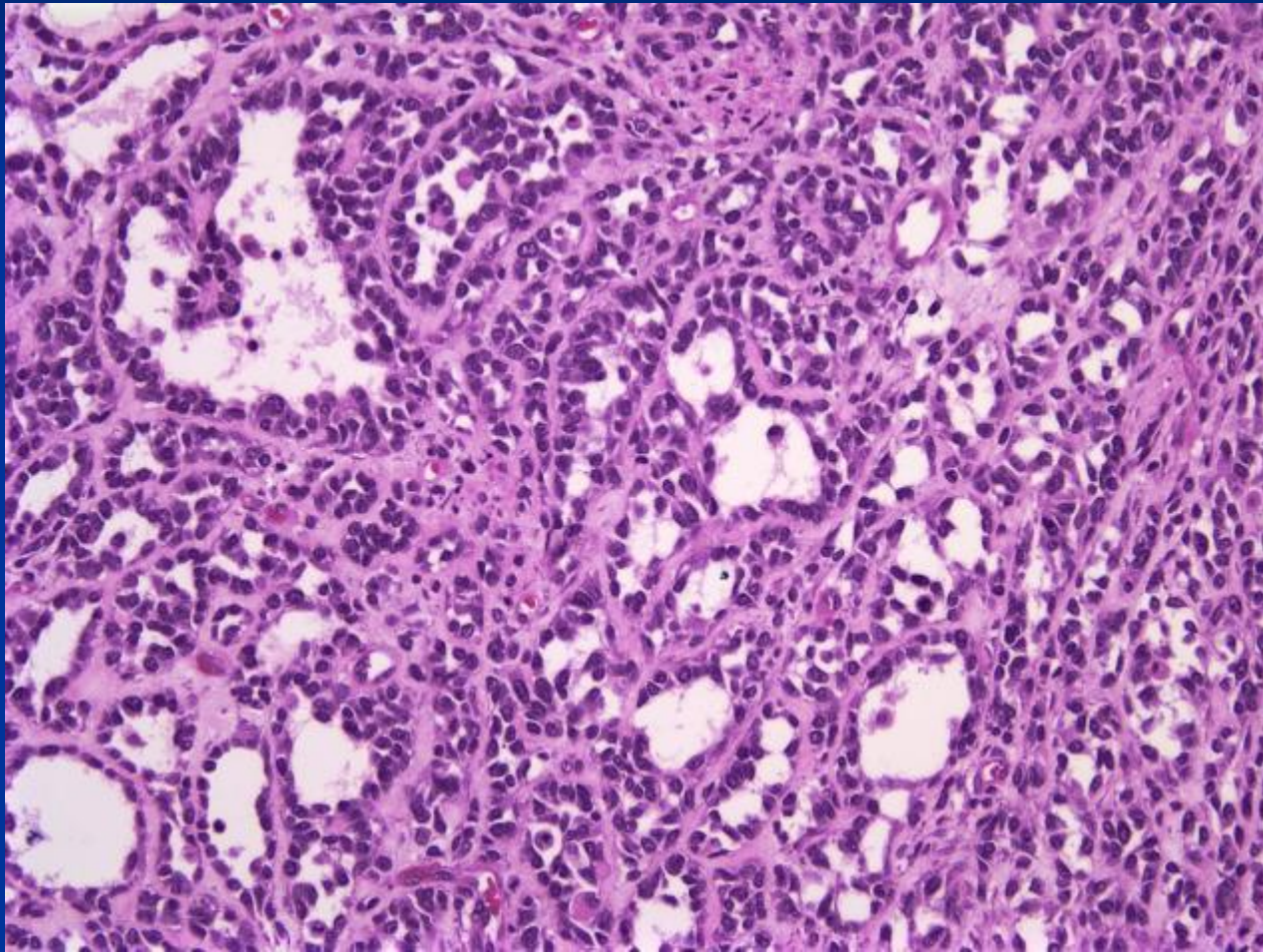
Rhabdomyosarcoma: Myoglobin Stain



Rhabdomyosarcoma: Alveolar Type



Rhabdomyosarcoma: Alveolar Type Glandular Appearance



Treatment and Prognosis

- Treatment:
 - Surgery: Wide Resection, Chemotherapy, possible Radiation
- Metastases:
 - Lung
 - Lymph Node
 - Bone
 - Brain
 - Liver
- Prognosis:
 - Embryonal: 70% DFS at 5 years
 - Alveolar: Worse prognosis than Embryonal 56% at 3 years
 - Pleomorphic: Worst prognosis—Majority die within 1 year

Leiomyosarcoma

- 9% of all soft tissue sarcomas
- Age: Median age 40 to 60 years
- Sites:
 - Retroperitoneum—Most common
 - Thigh—Second most common
 - 6% of subcutaneous sarcomas
 - May arise from wall of blood vessel
- Clinical: Painless mass
- Radiology: Non specific heterogeneous mass with necrosis and hemorrhage
- Pathology: Spindle cell tumor
 - Actin and Desmin positive

Leiomyosarcoma

- Treatment:
 - Wide excision and postop radiation
- Metastases:
 - Lungs
 - Liver
 - Bone
 - Other Soft Tissues
 - Lymph Nodes
- Prognosis:
 - Extremity Lesions: 50% 5 year survival
 - Retroperitoneal Lesions: 25-35% 5 year survival



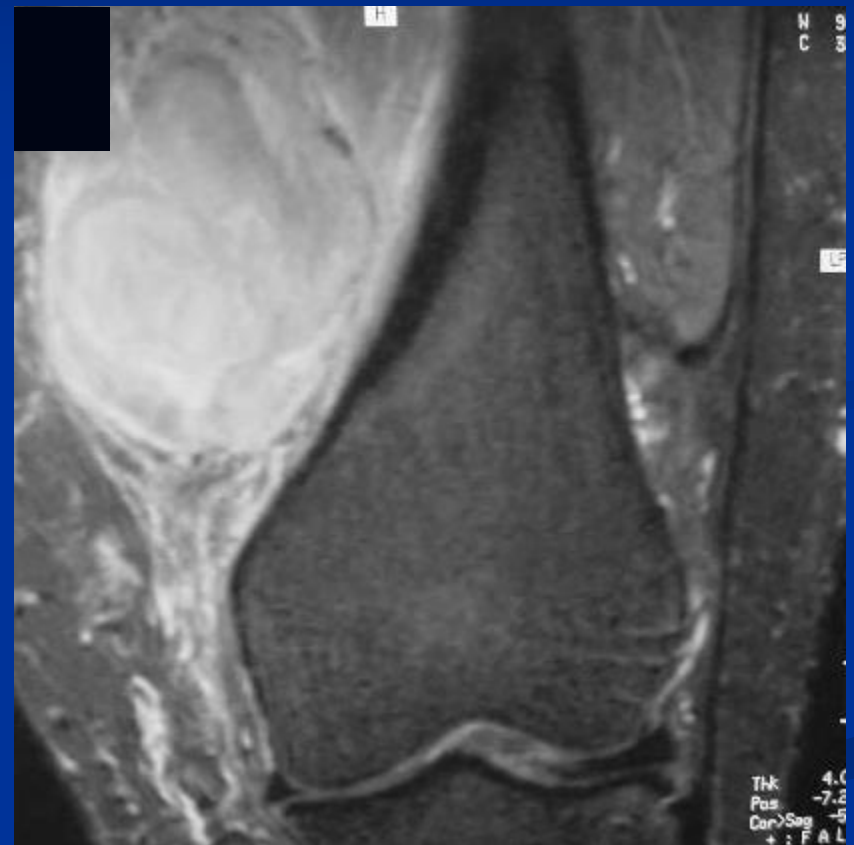
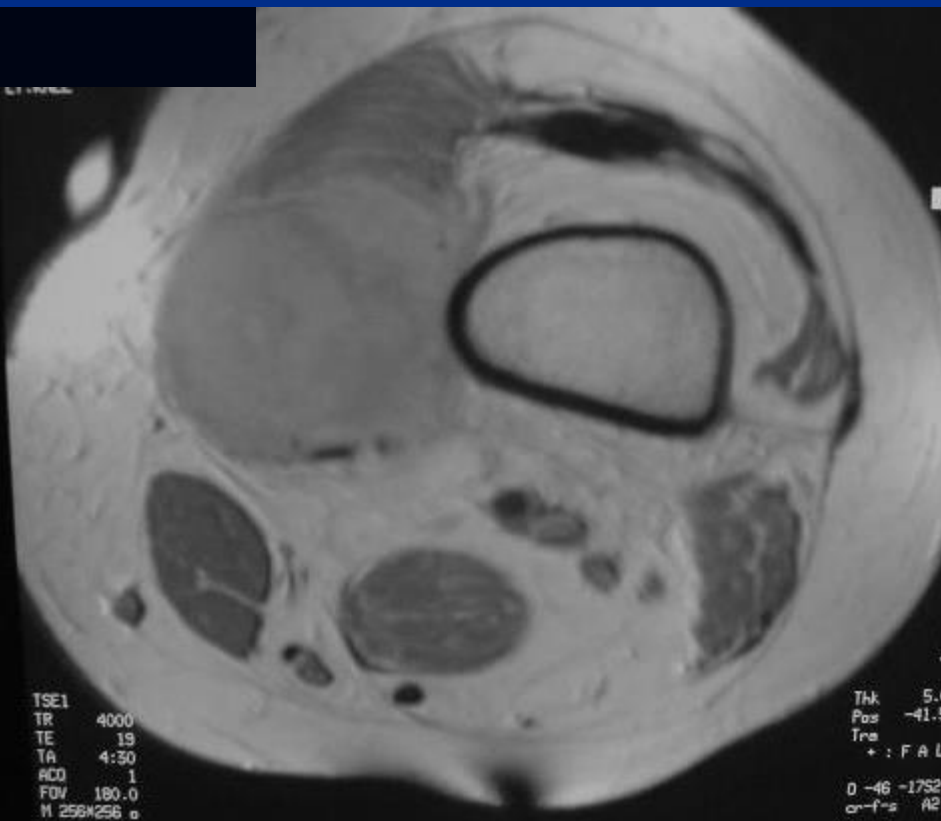
Leiomyosarcoma

- 9% of all ST sarcomas
- 3rd most common lesion after MFH and liposarcoma
- 20-67% occur in Retroperitoneum
- 12-41% occur in peripheral soft tissues (may arise in association with vessels)
- Thigh is most common peripheral location

Leiomyosarcoma

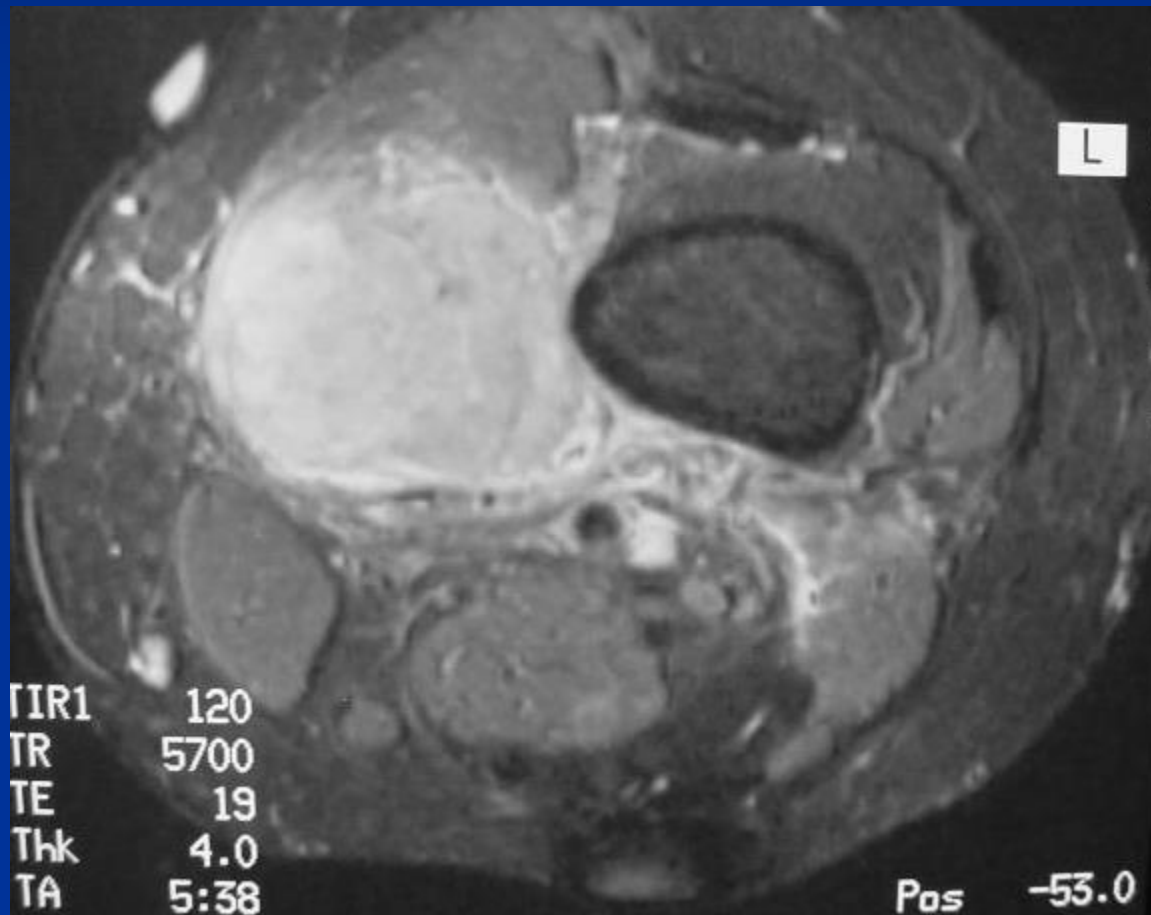
- Remainder of lesions in GU and GI tracts
- 5th and 6th decades
- Metastases common
- Imaging similar to MFH/fibrosarcoma
- Extremity lesions usually intramuscular
- Central necrosis/hemorrhage common
- Calcification/osseous invasion rare

MRI: Leiomyosarcoma of Vastus Medialis Muscle

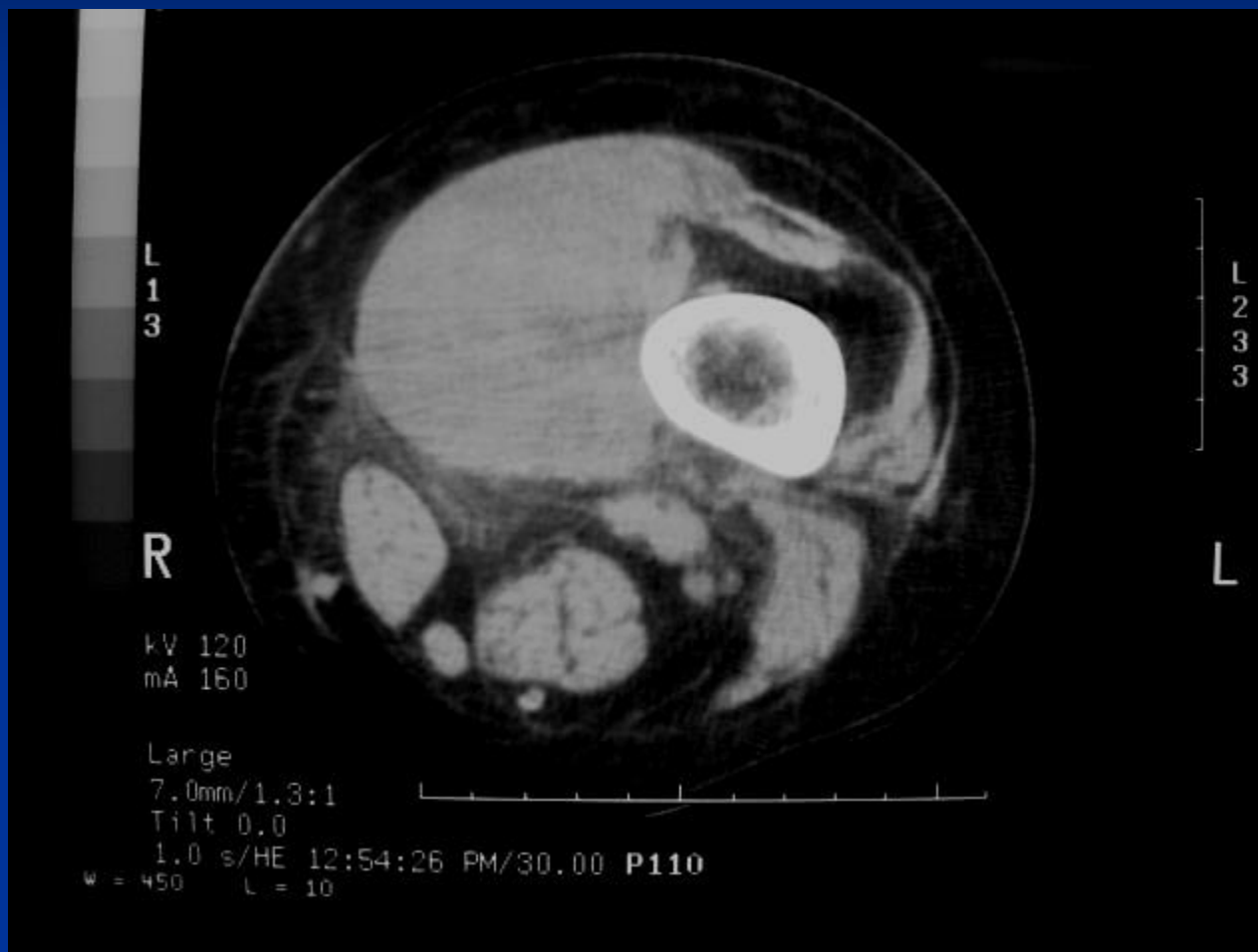

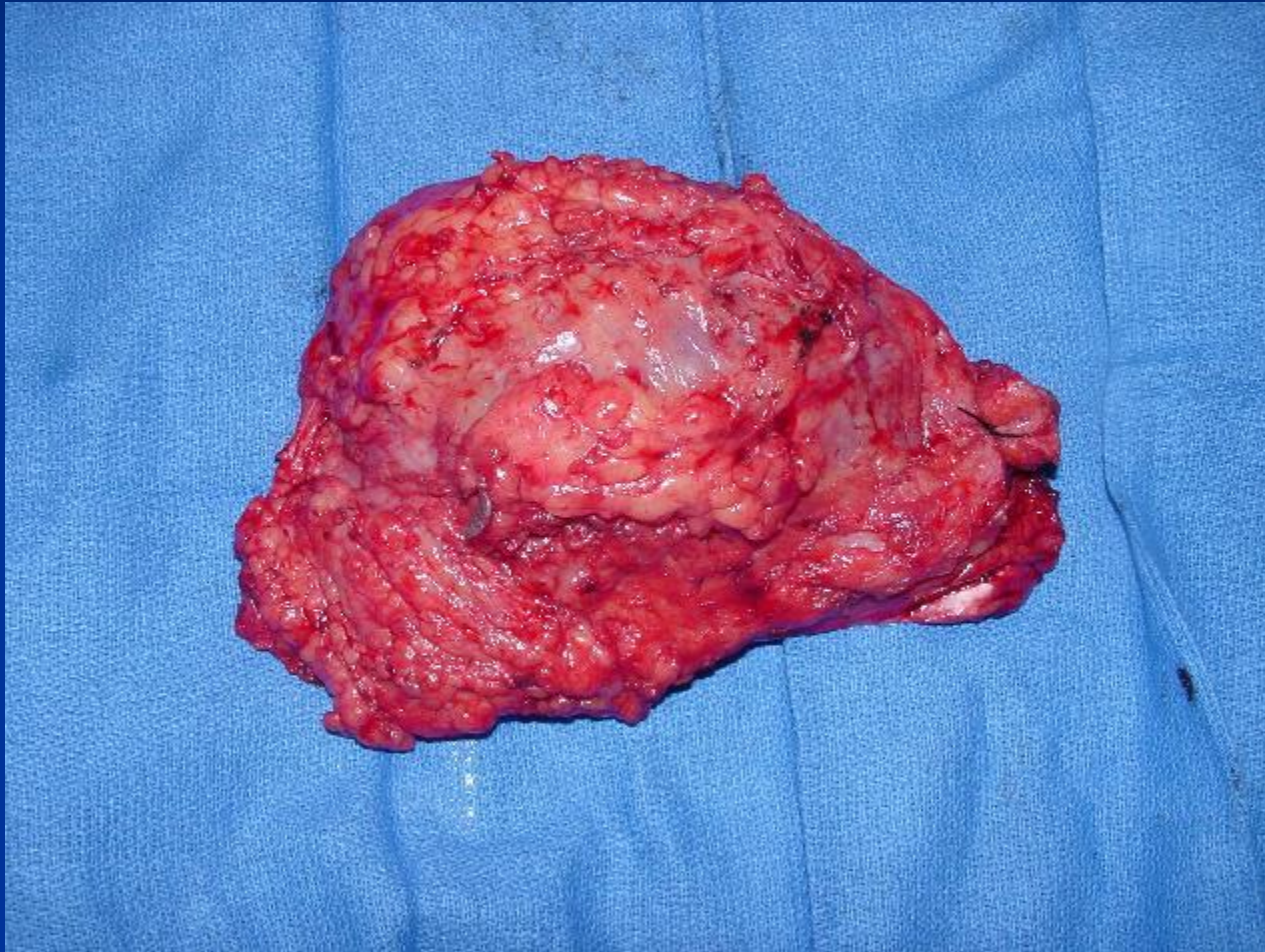MRI with Gadolinium

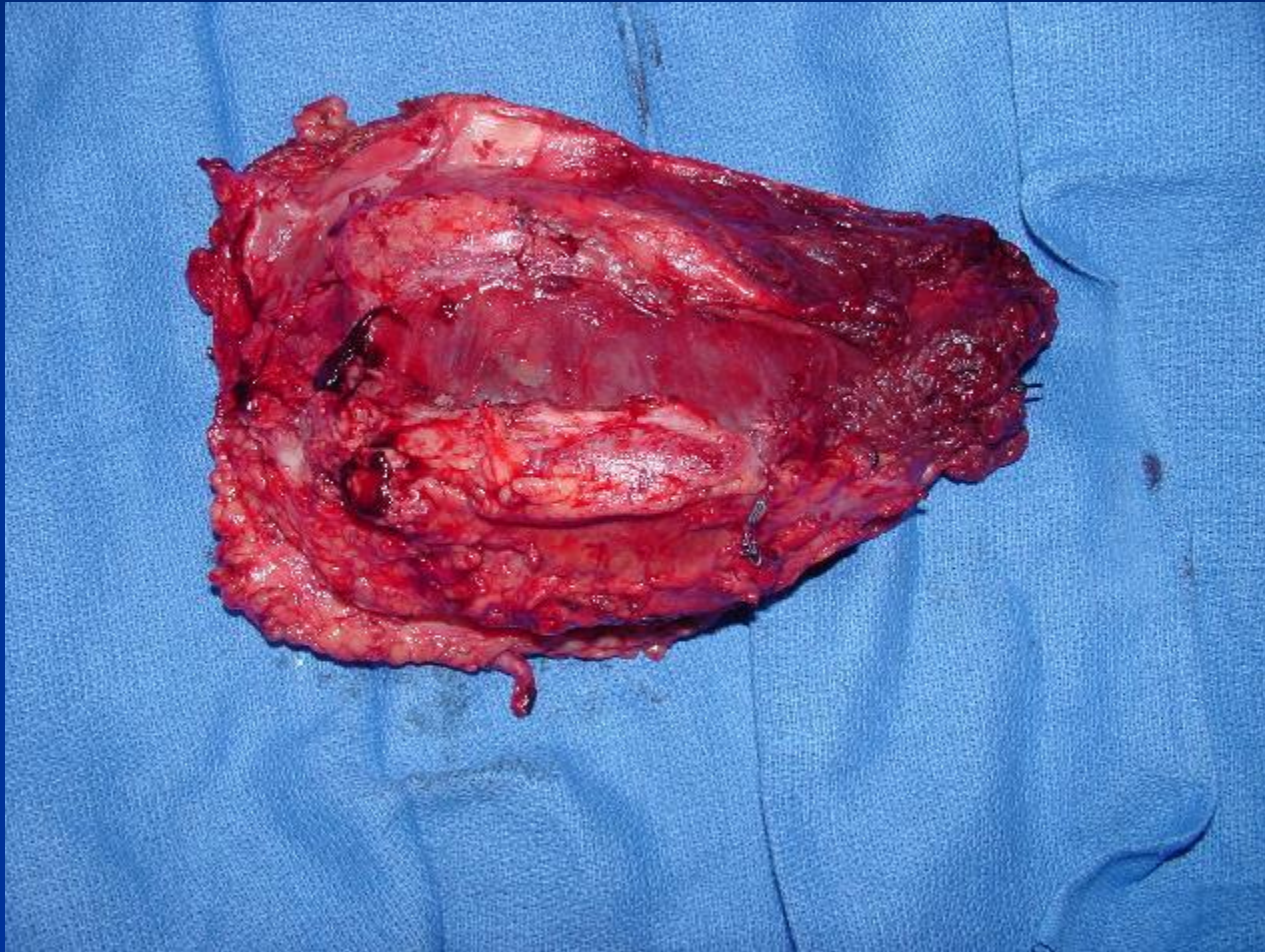
Leiomyosarcoma of Vastus Medialis Muscle

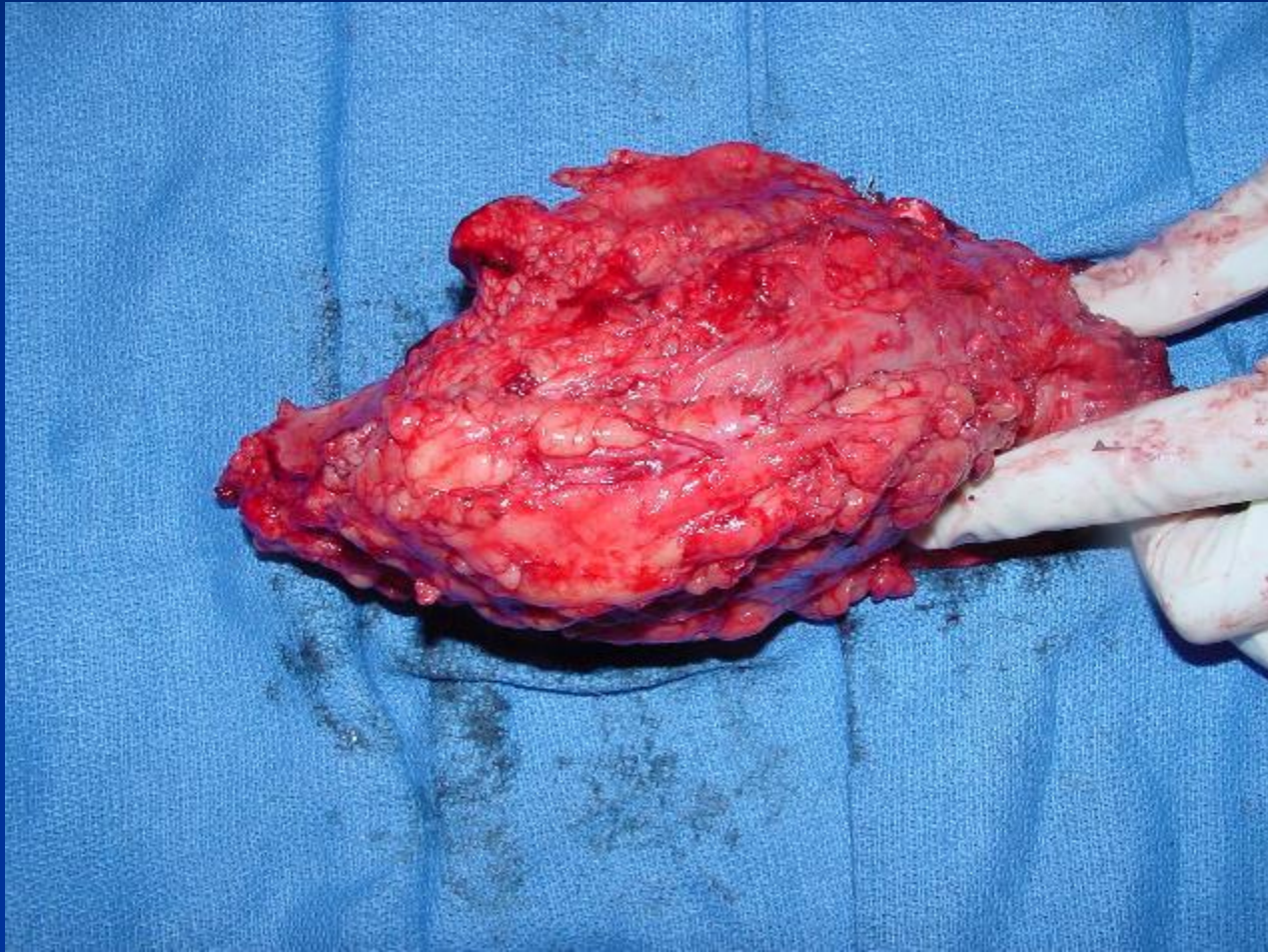


CT Scan Leiomyosarcoma Vastus Medialis Muscle

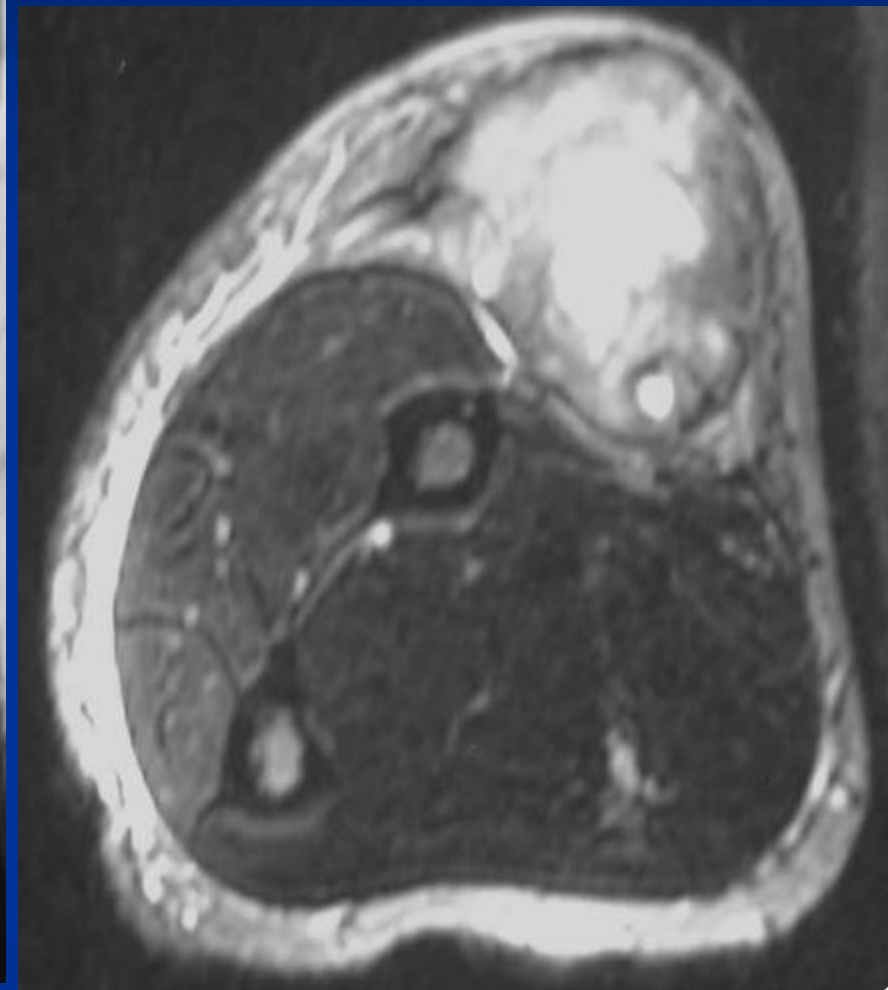
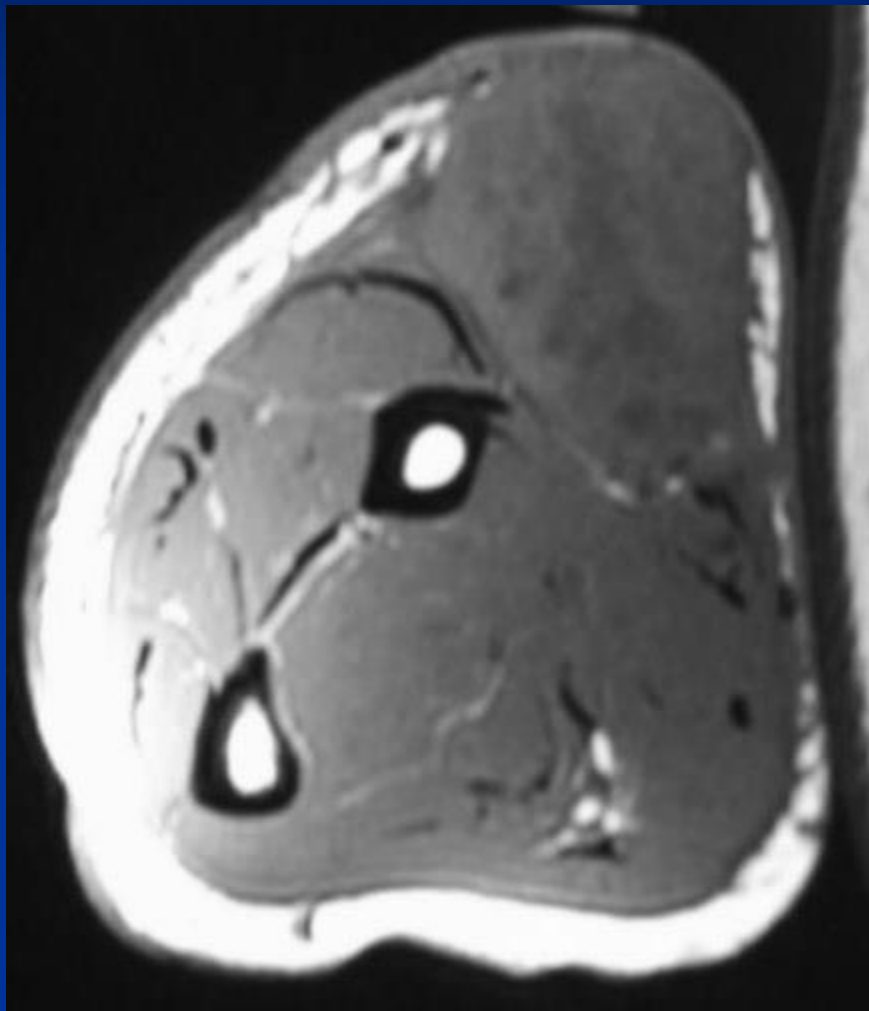




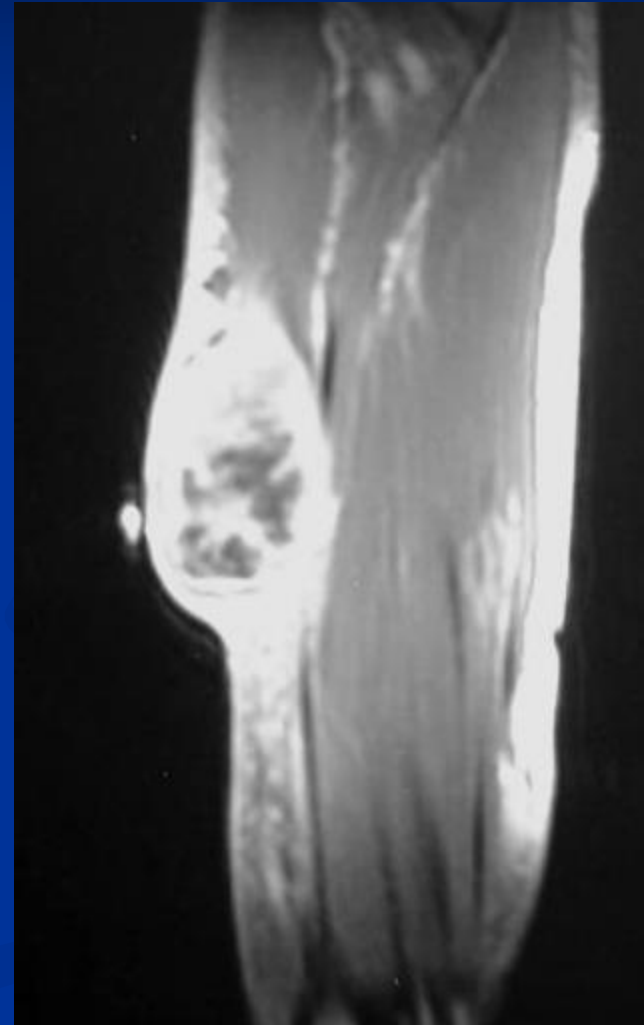
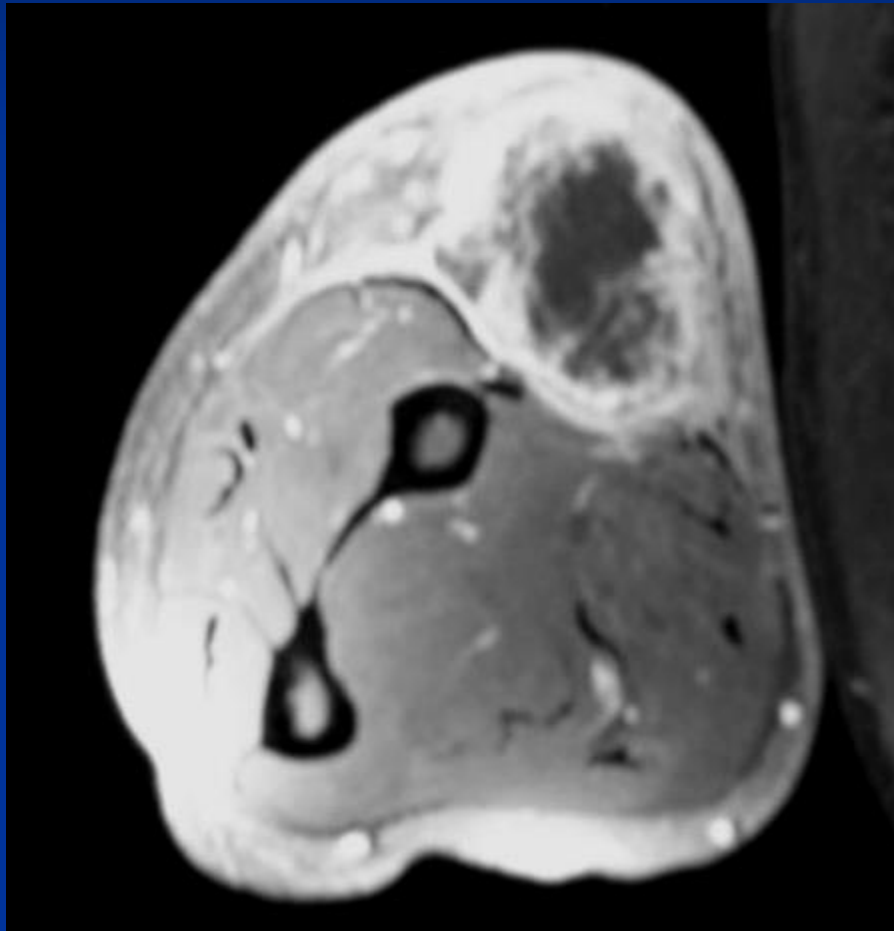




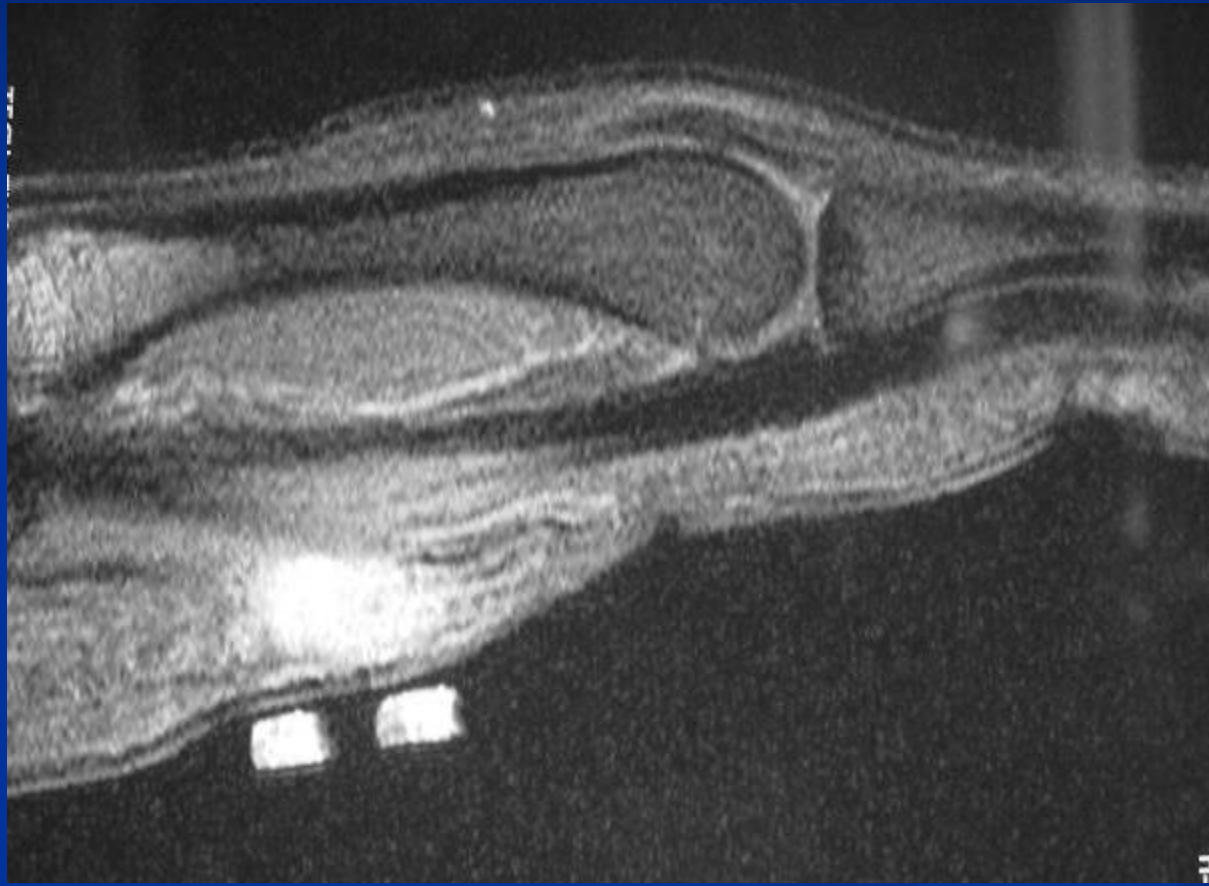
Leiomyosarcoma



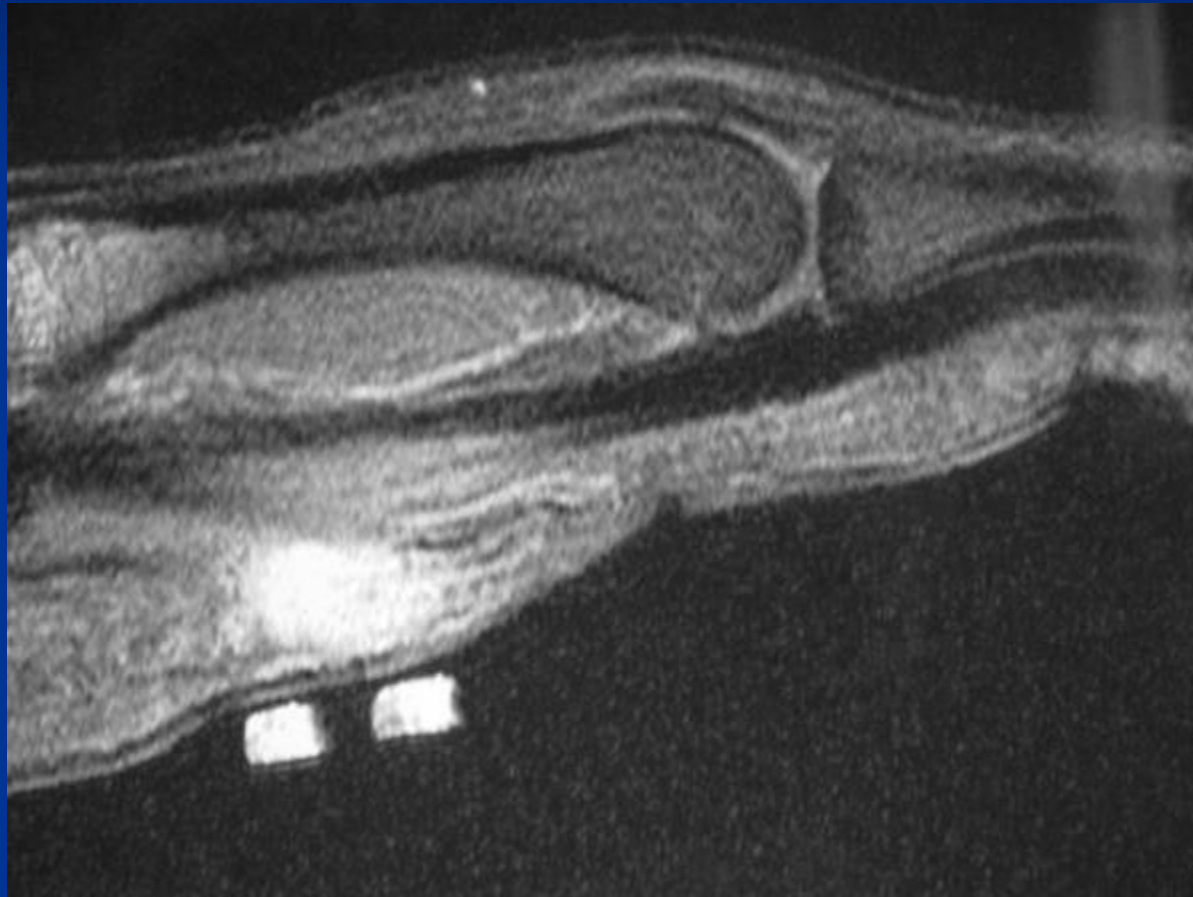
Leiomyosarcoma

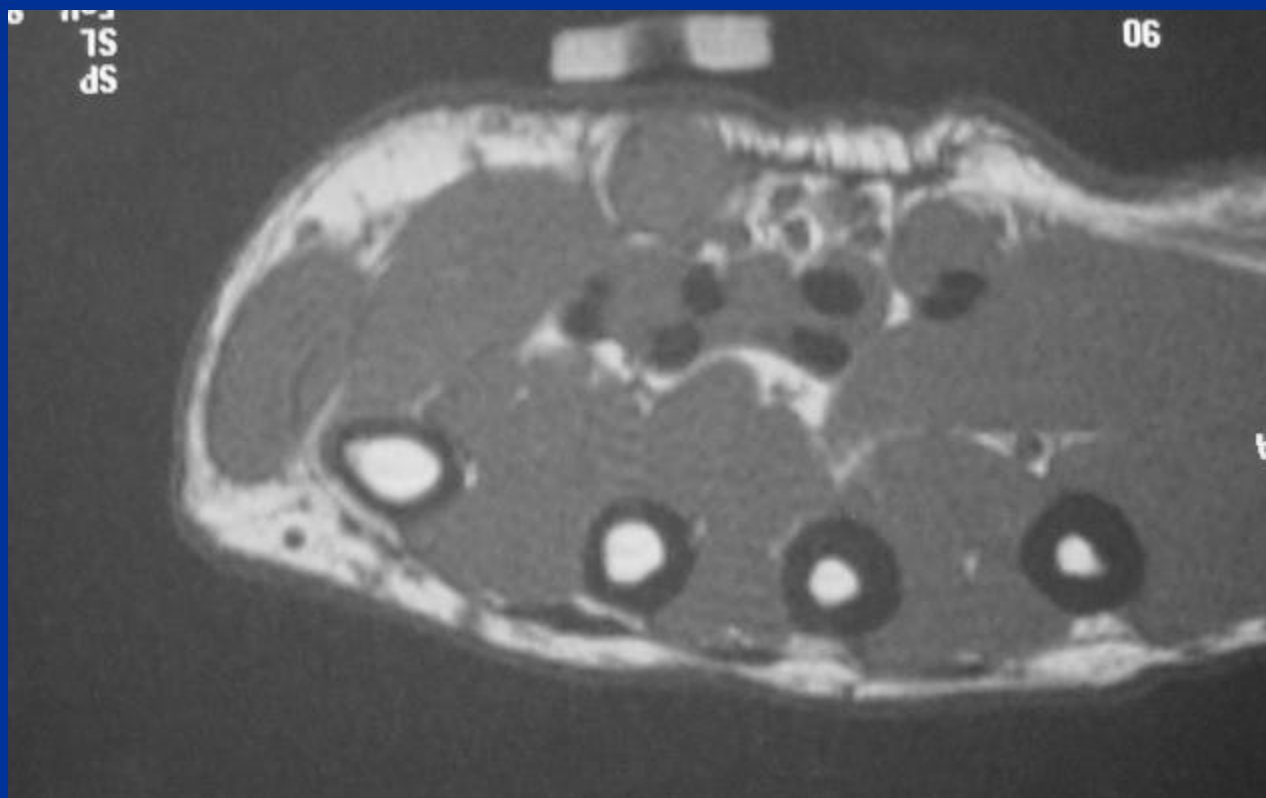


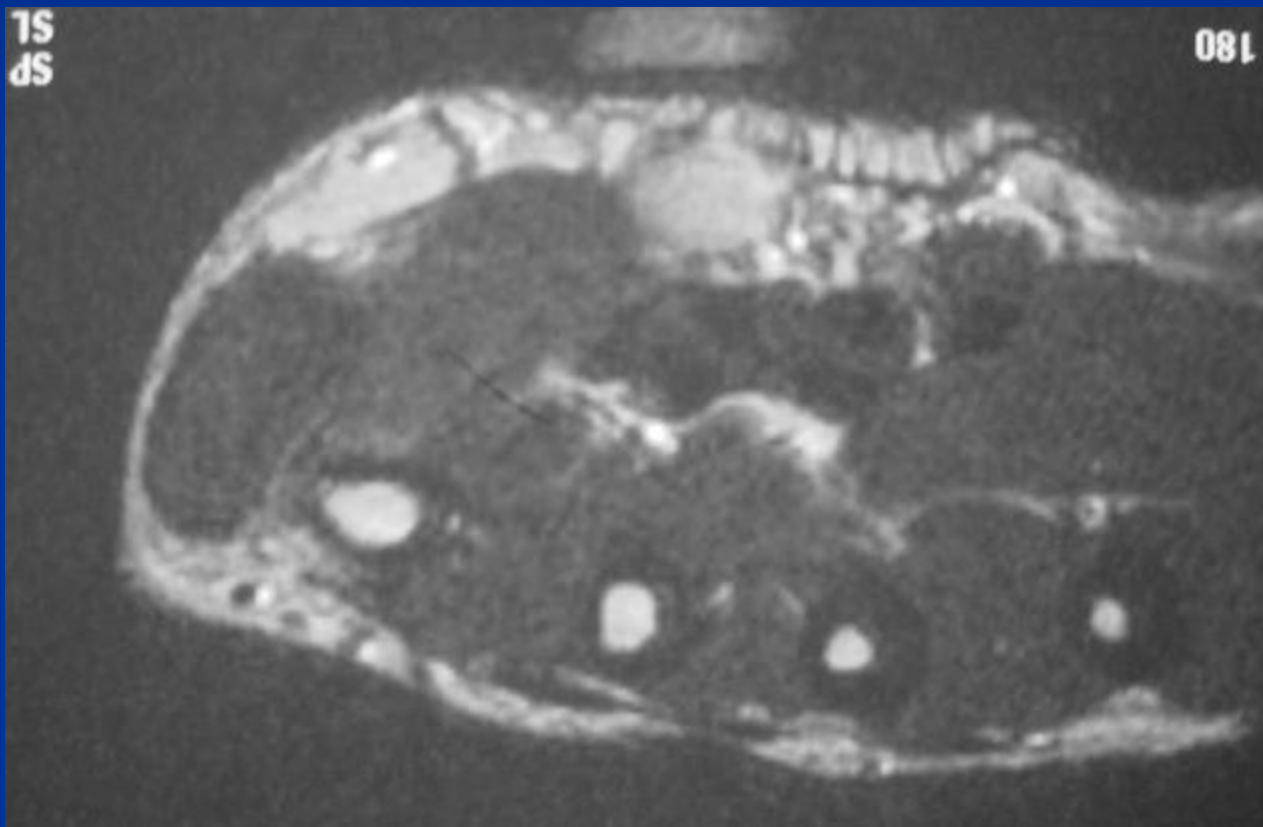
Leiomyosarcoma Low Grade of Palm of Hand

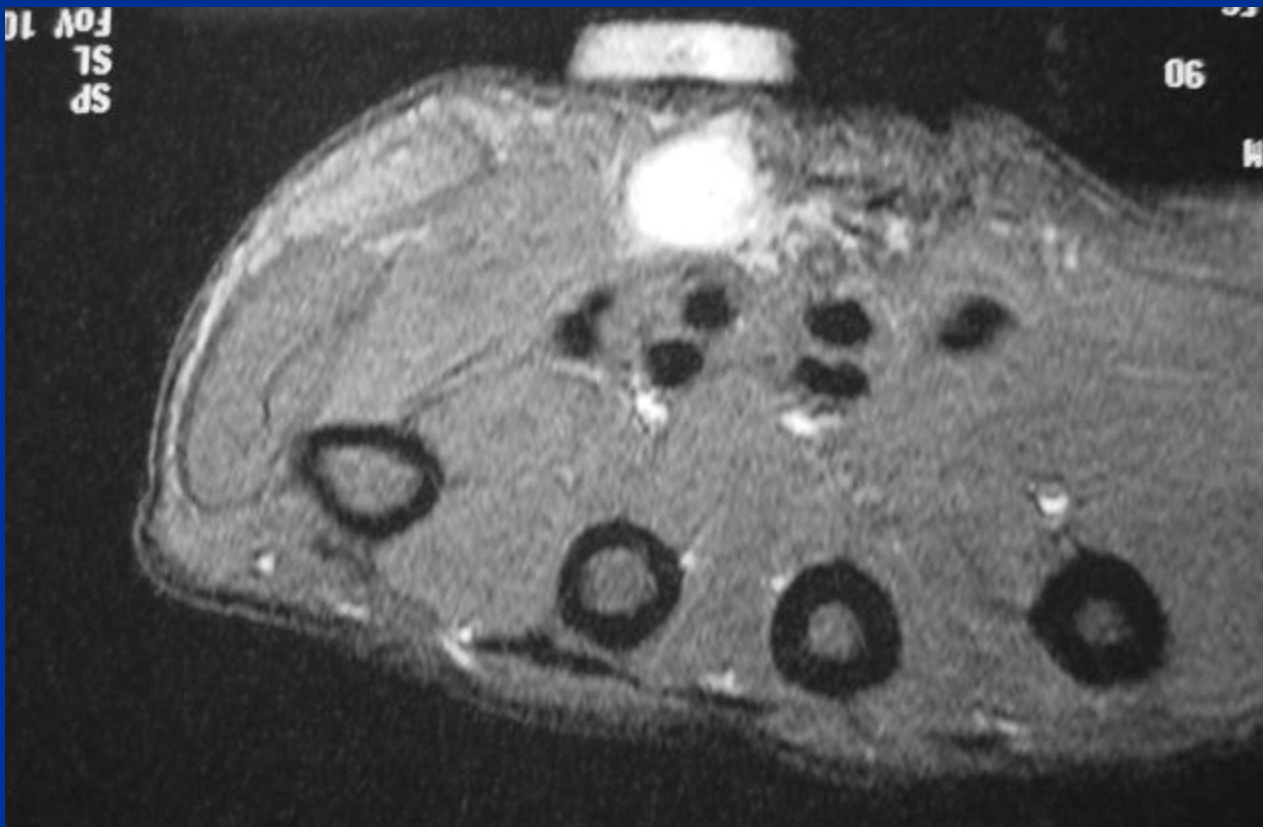


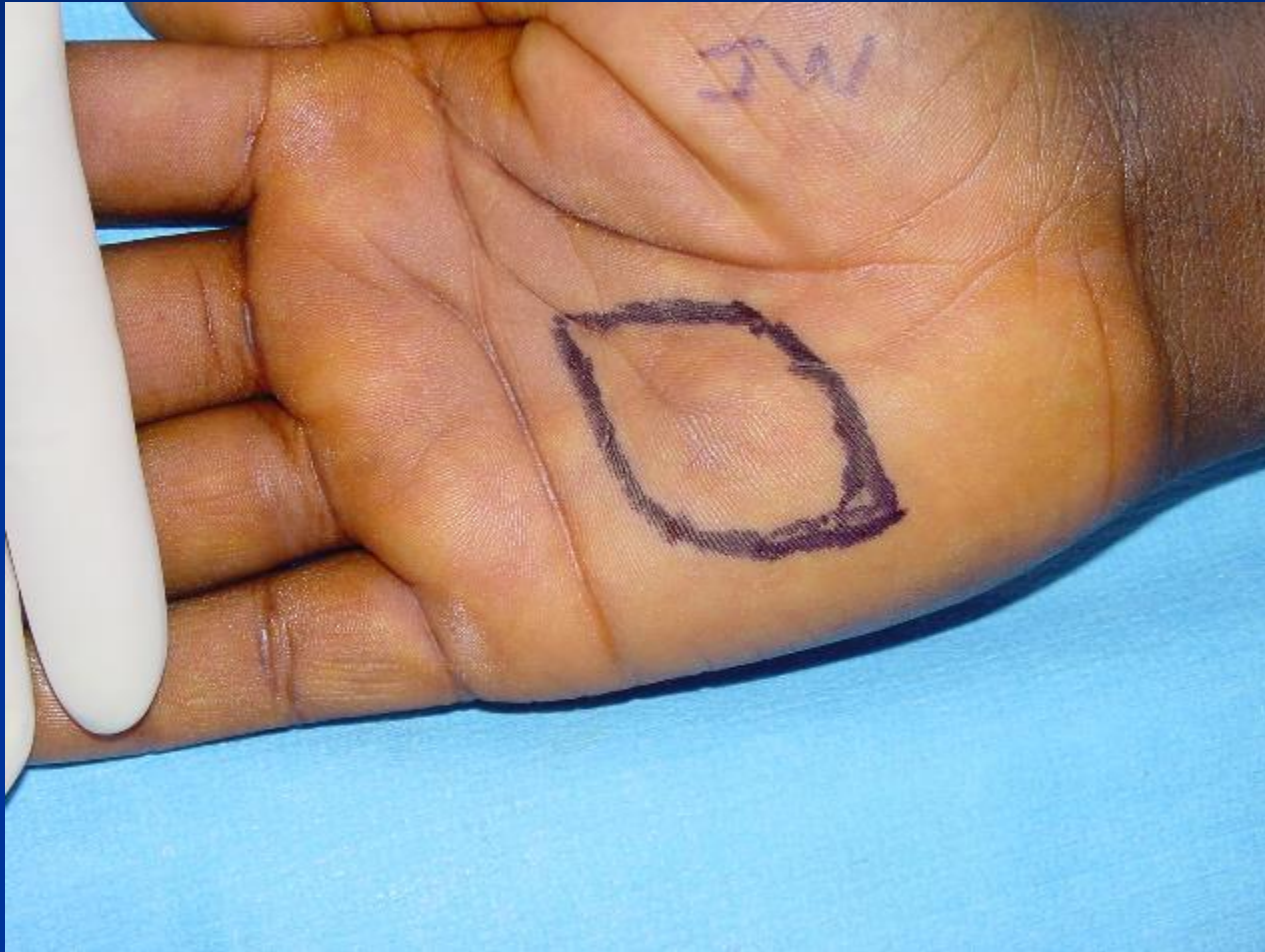Leiomyosarcoma of Subcutaneous Tissue of Hand

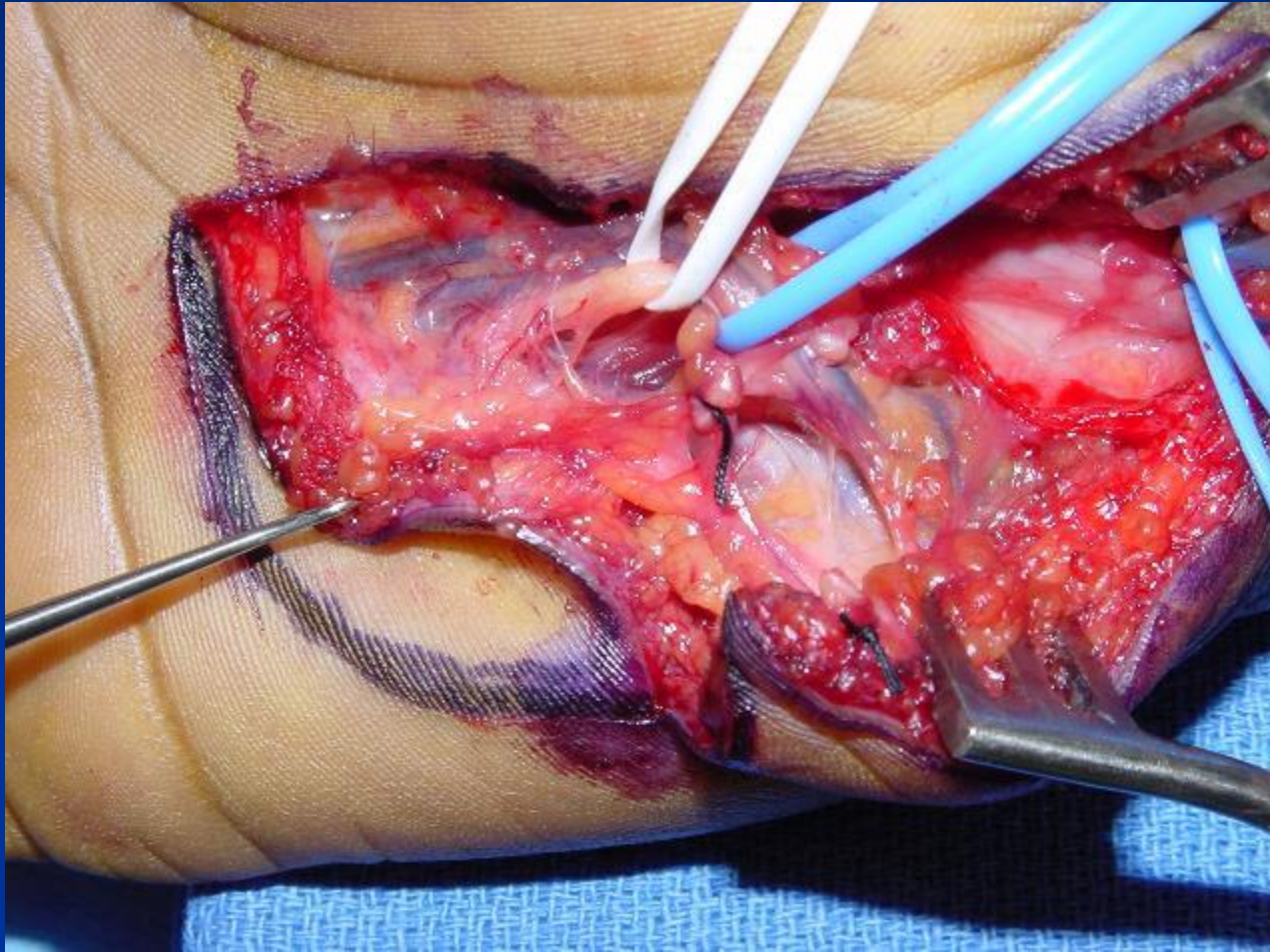


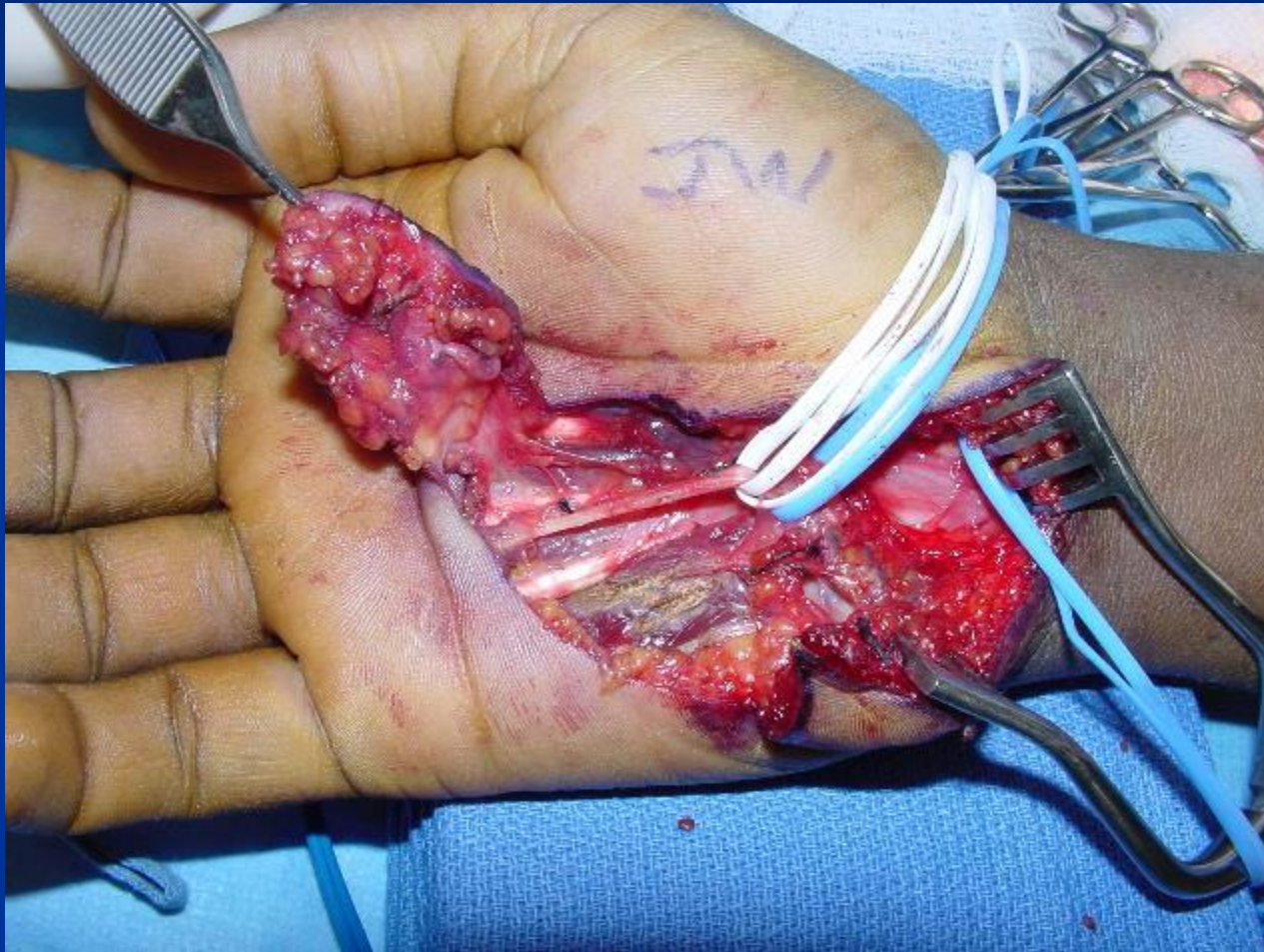


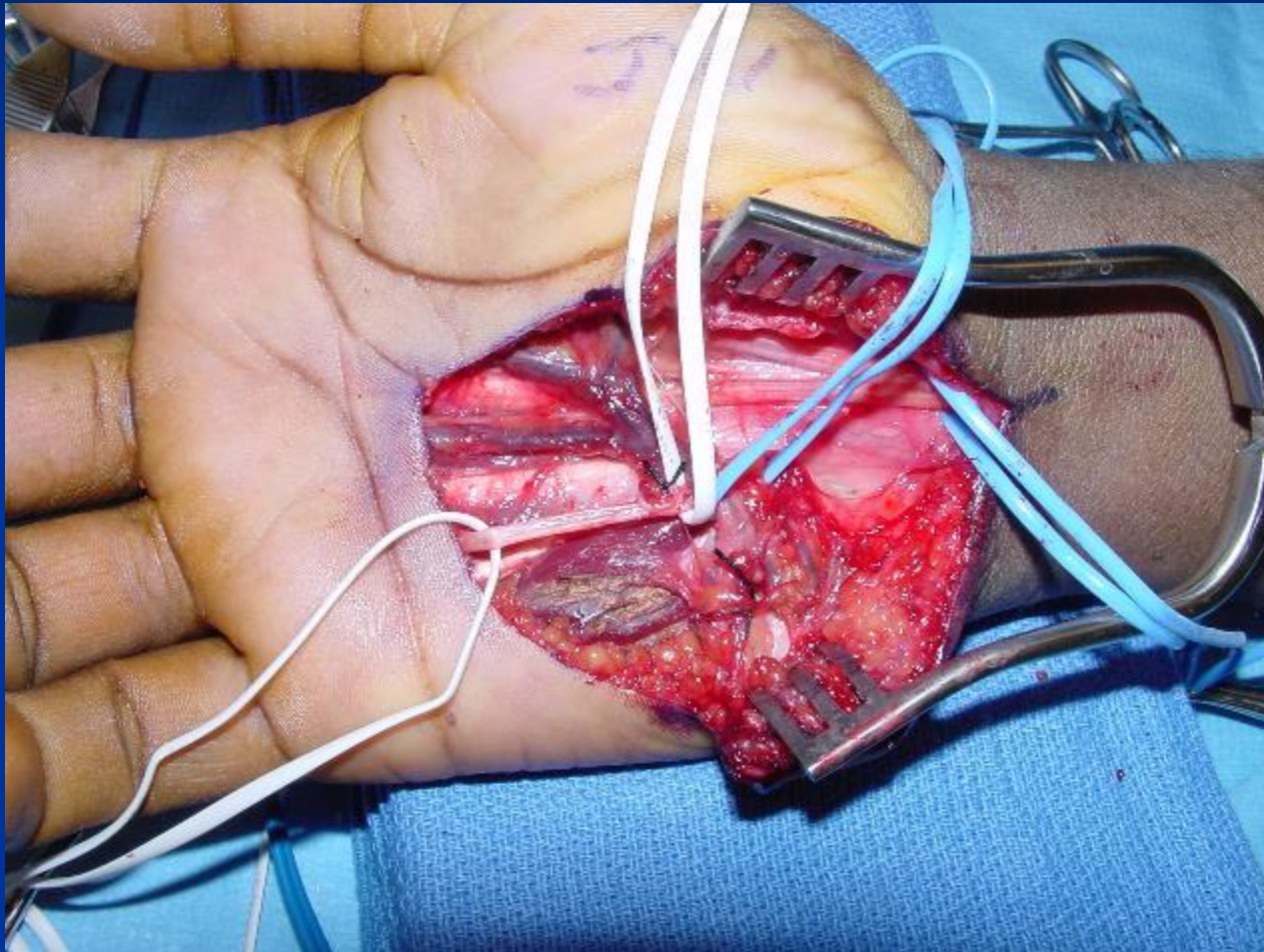


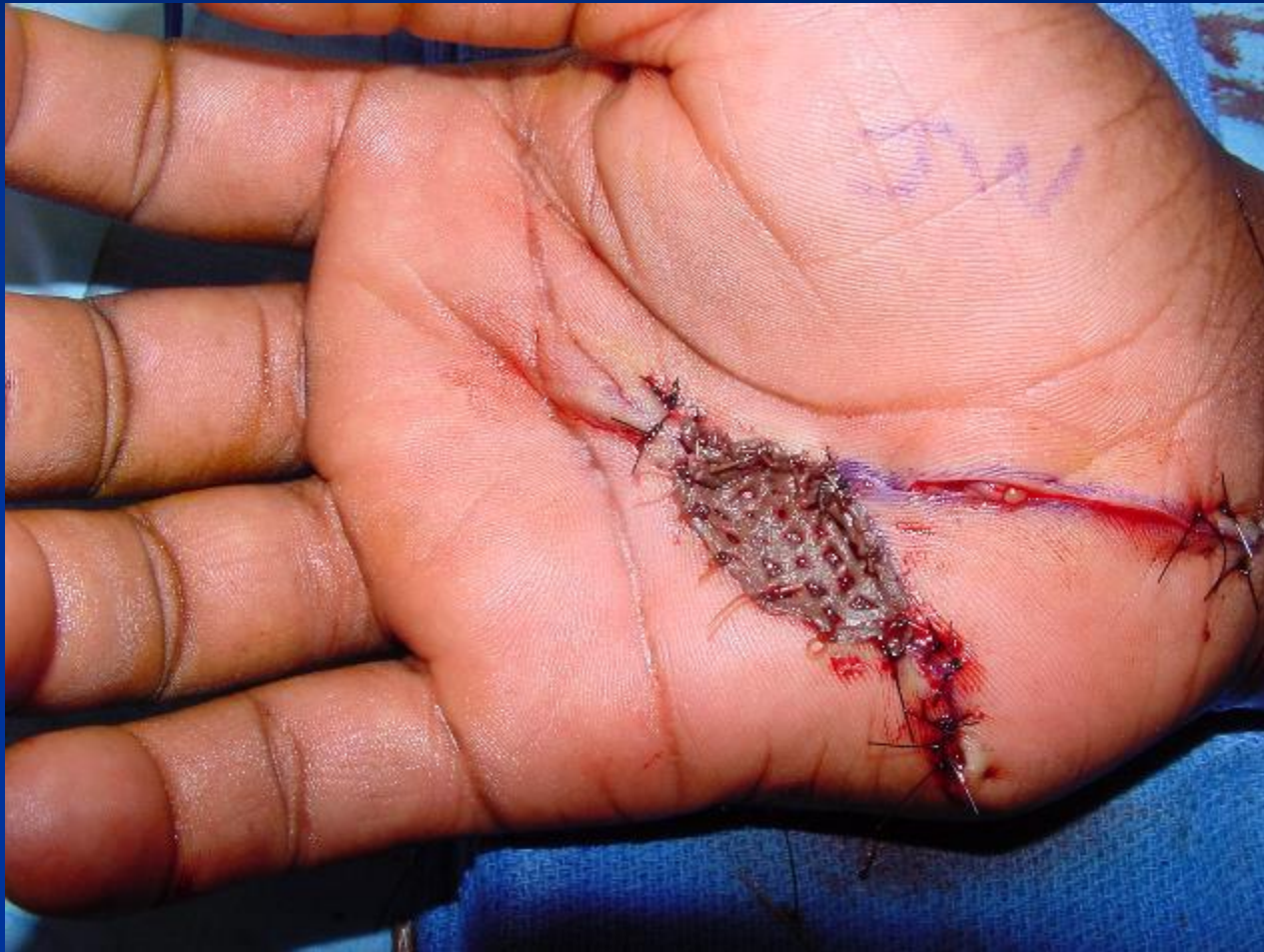

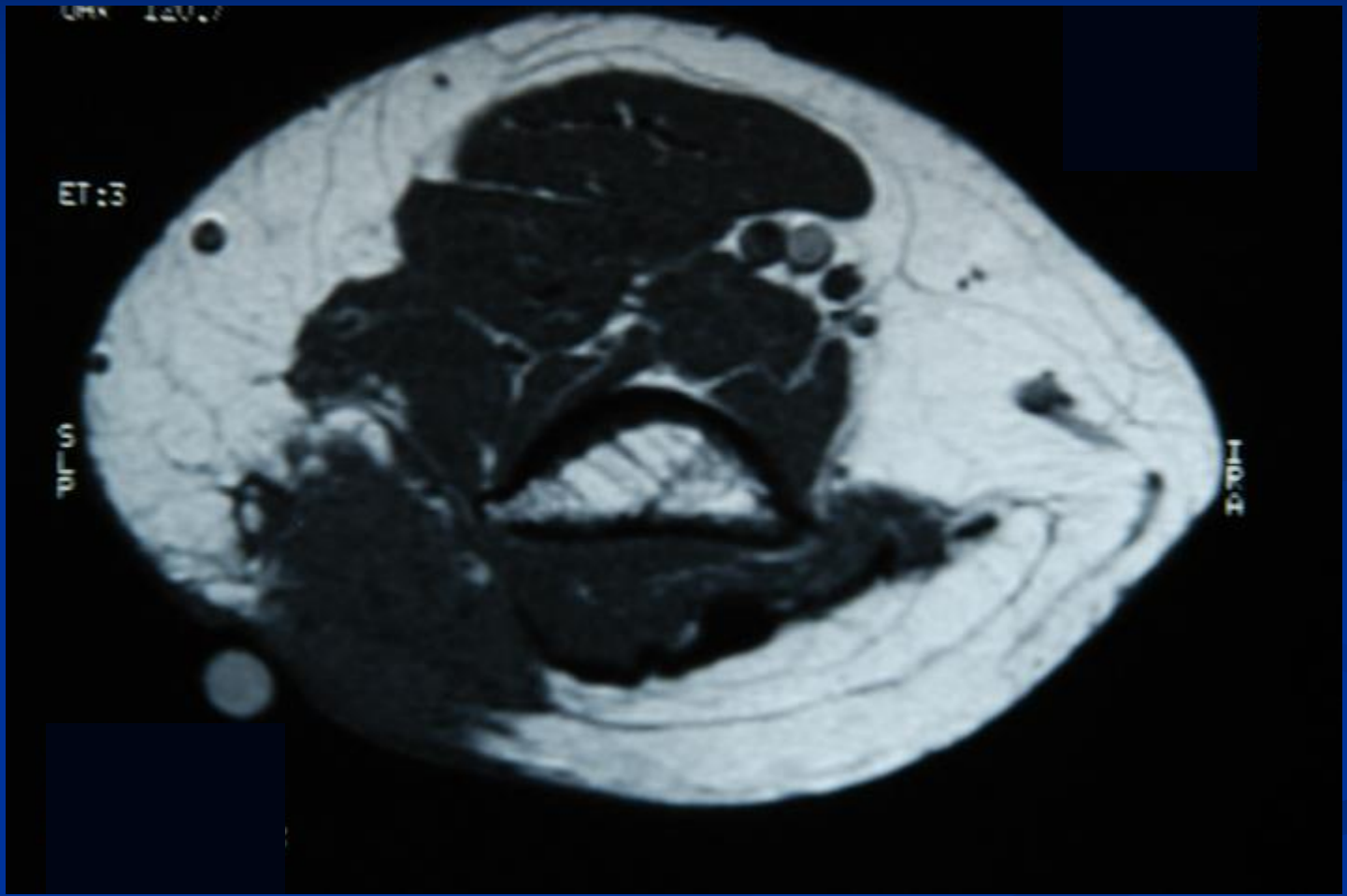


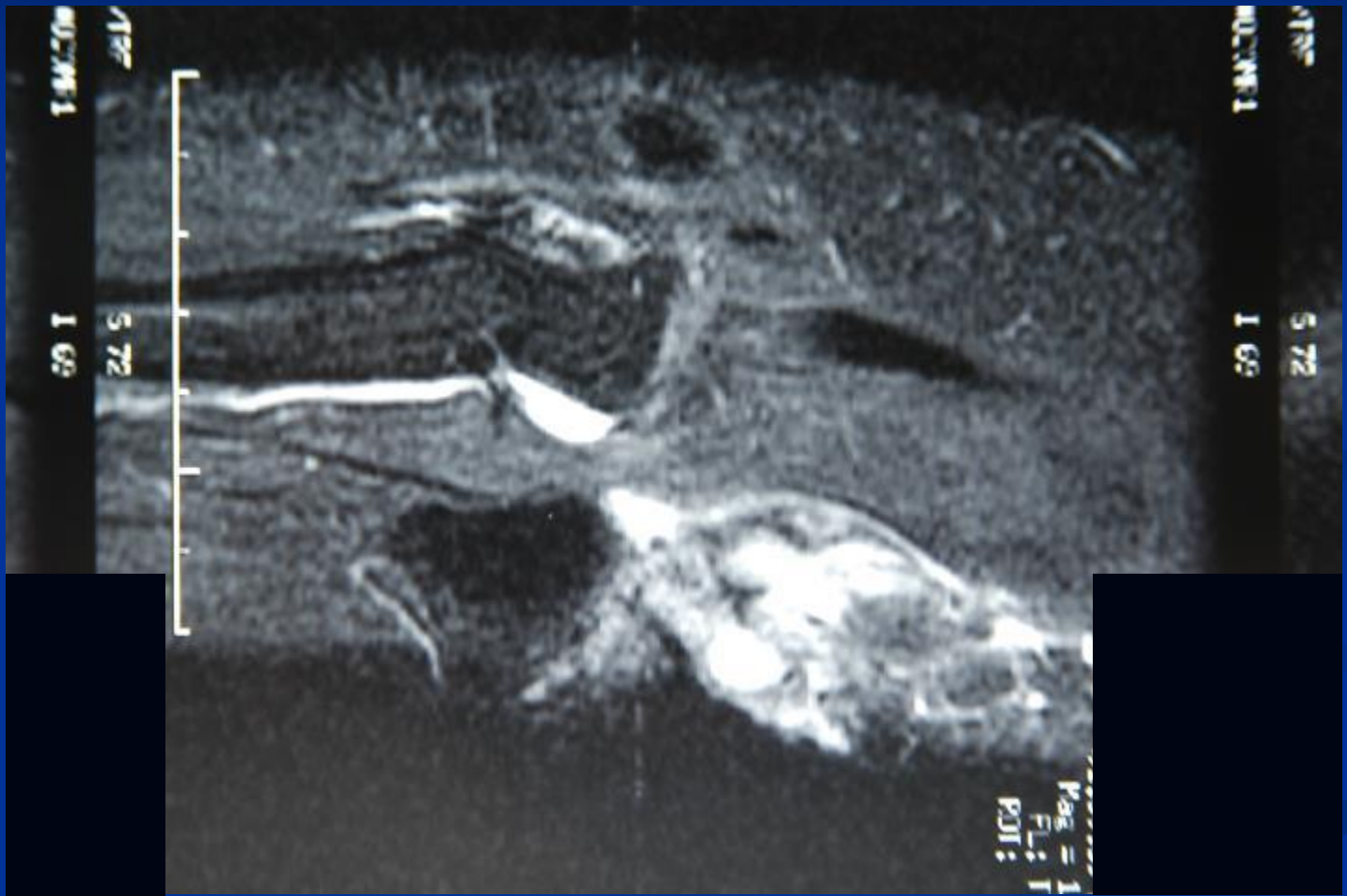



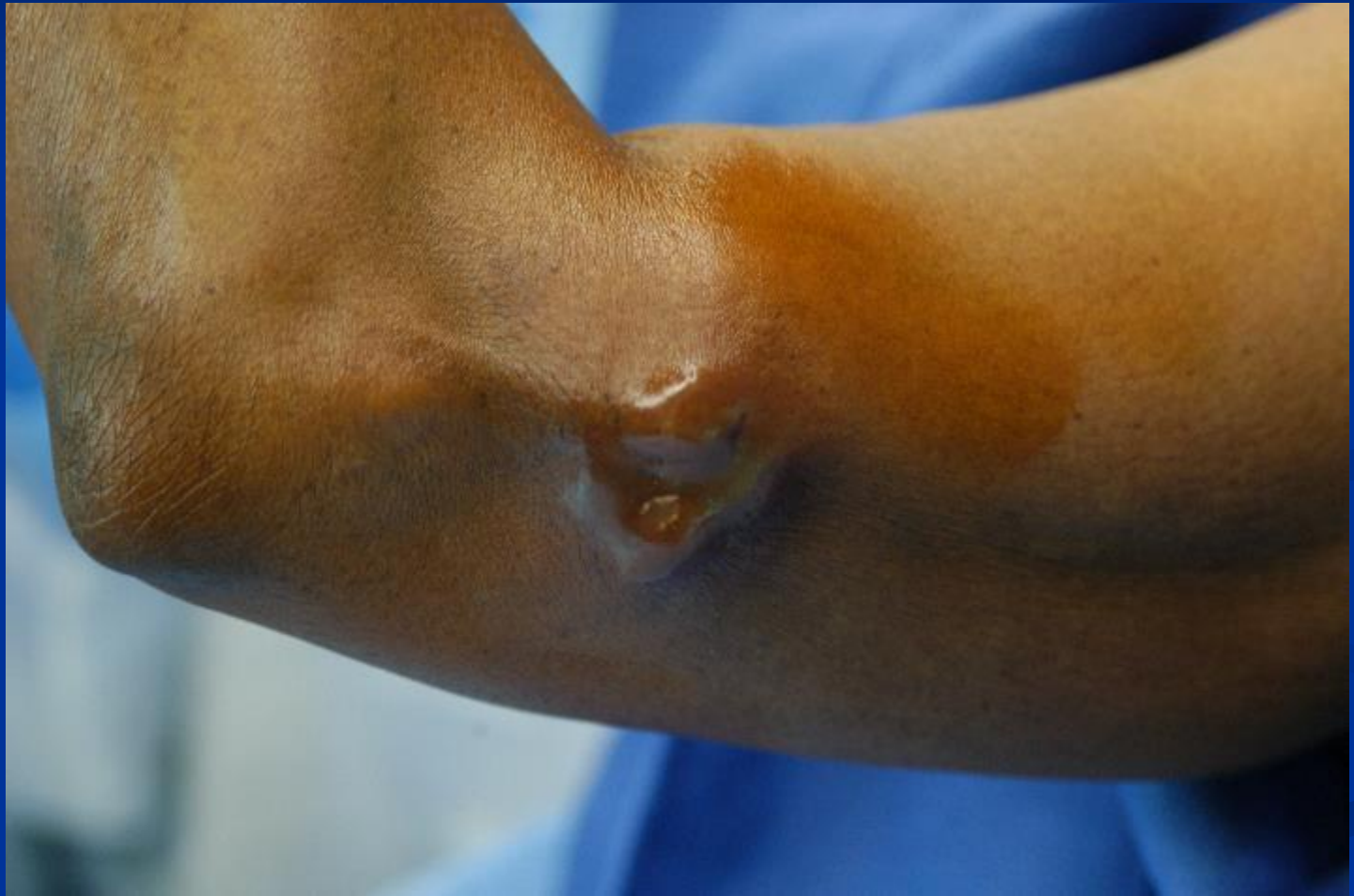
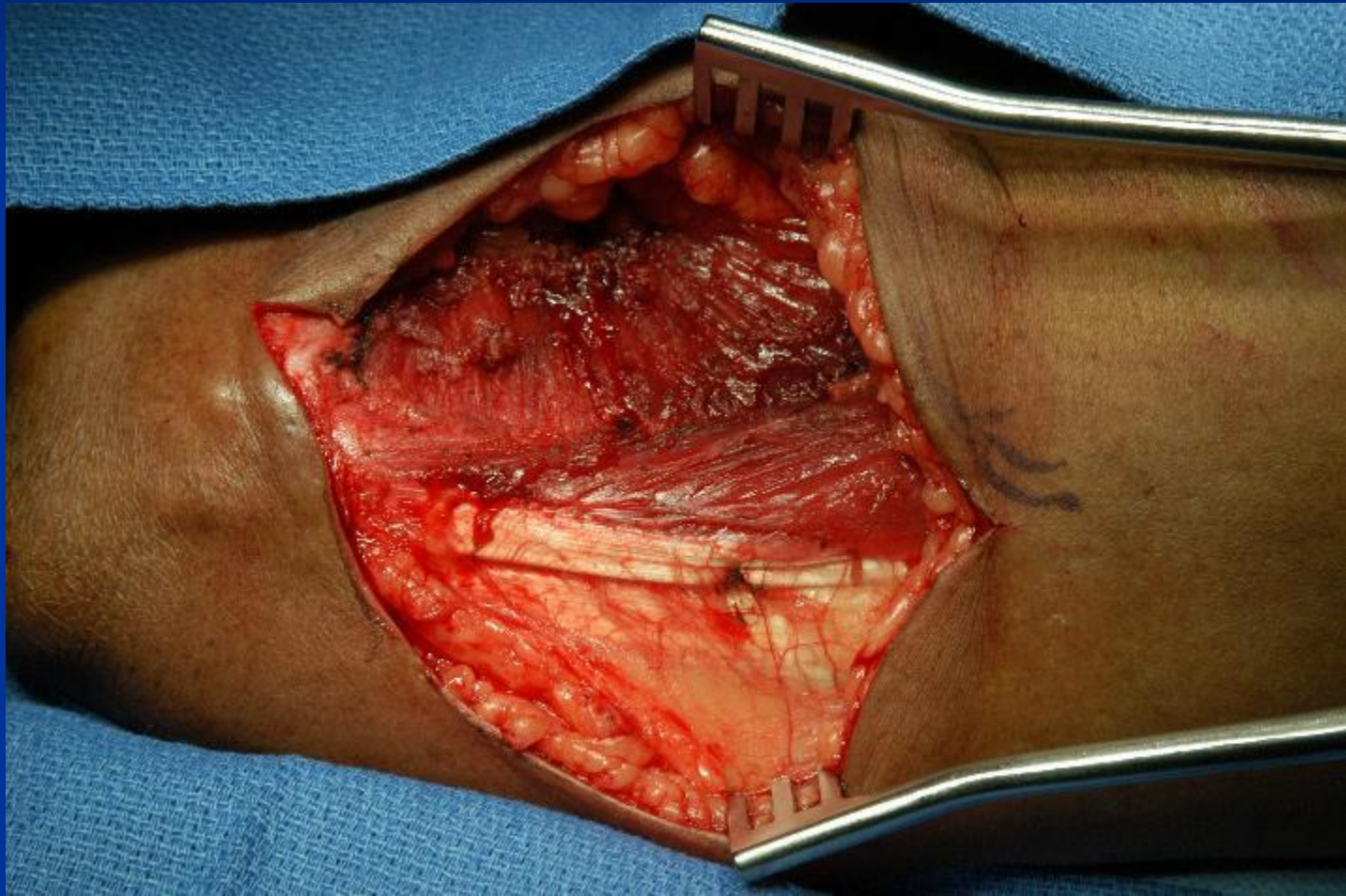




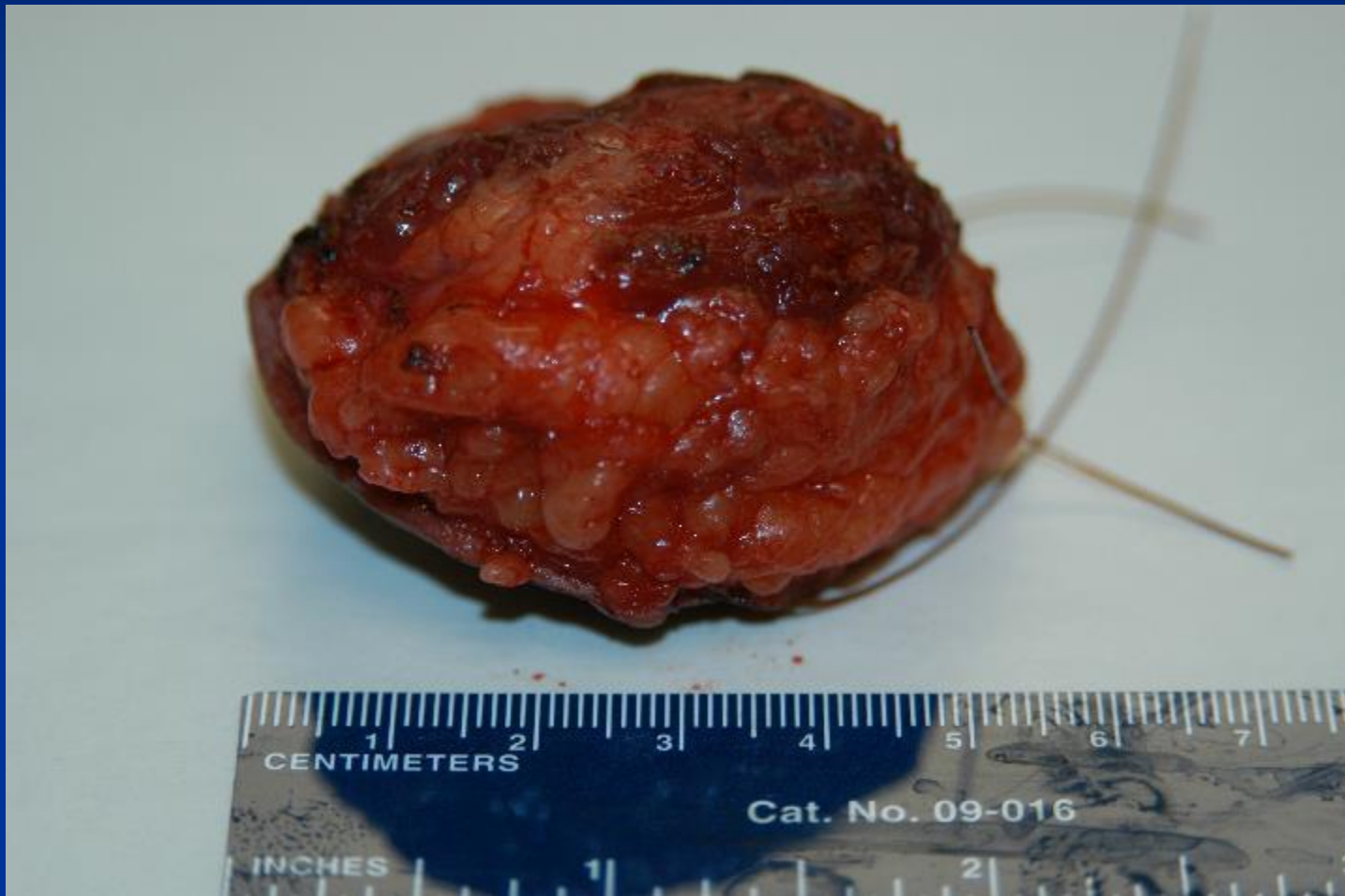


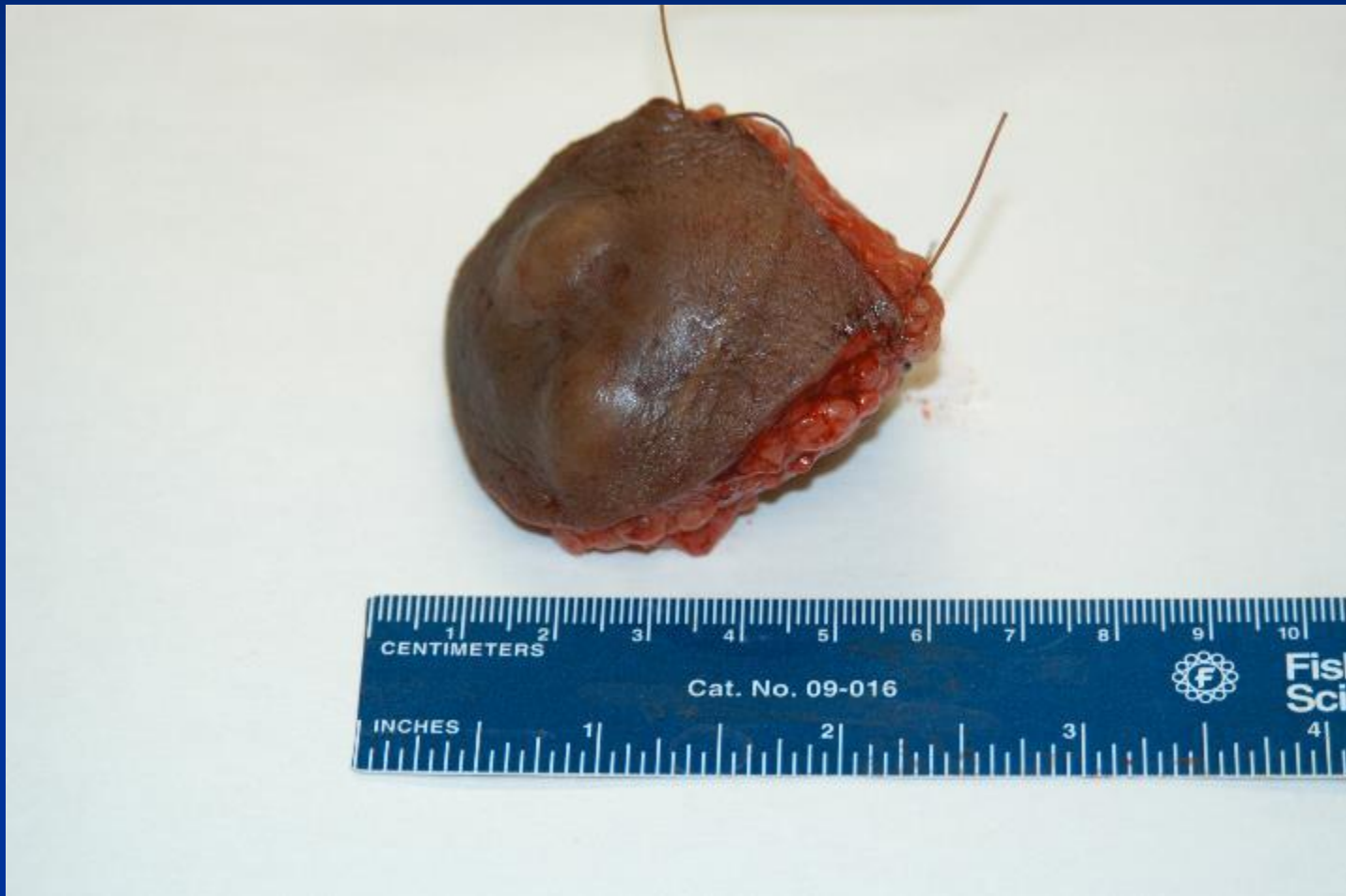


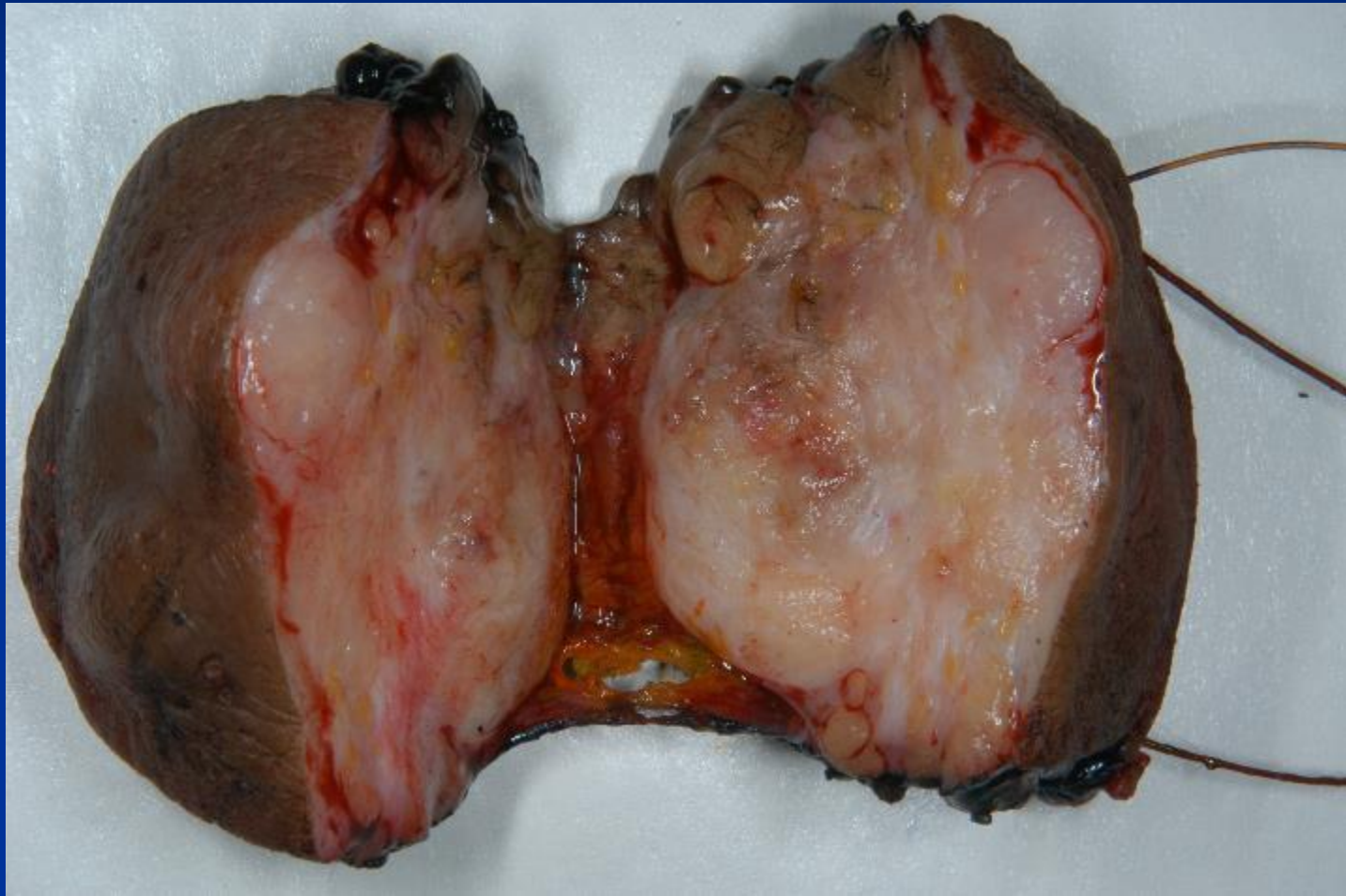


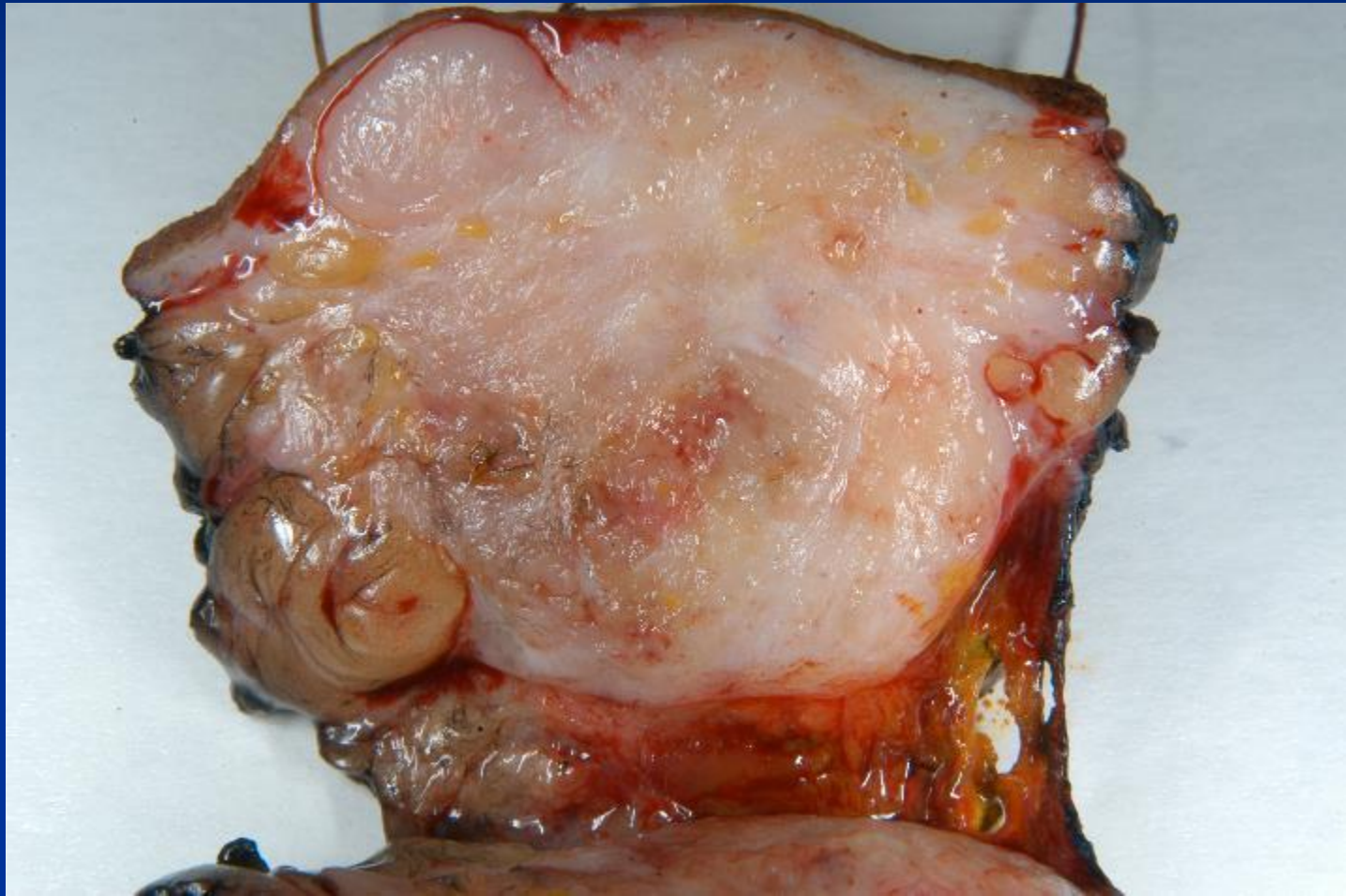


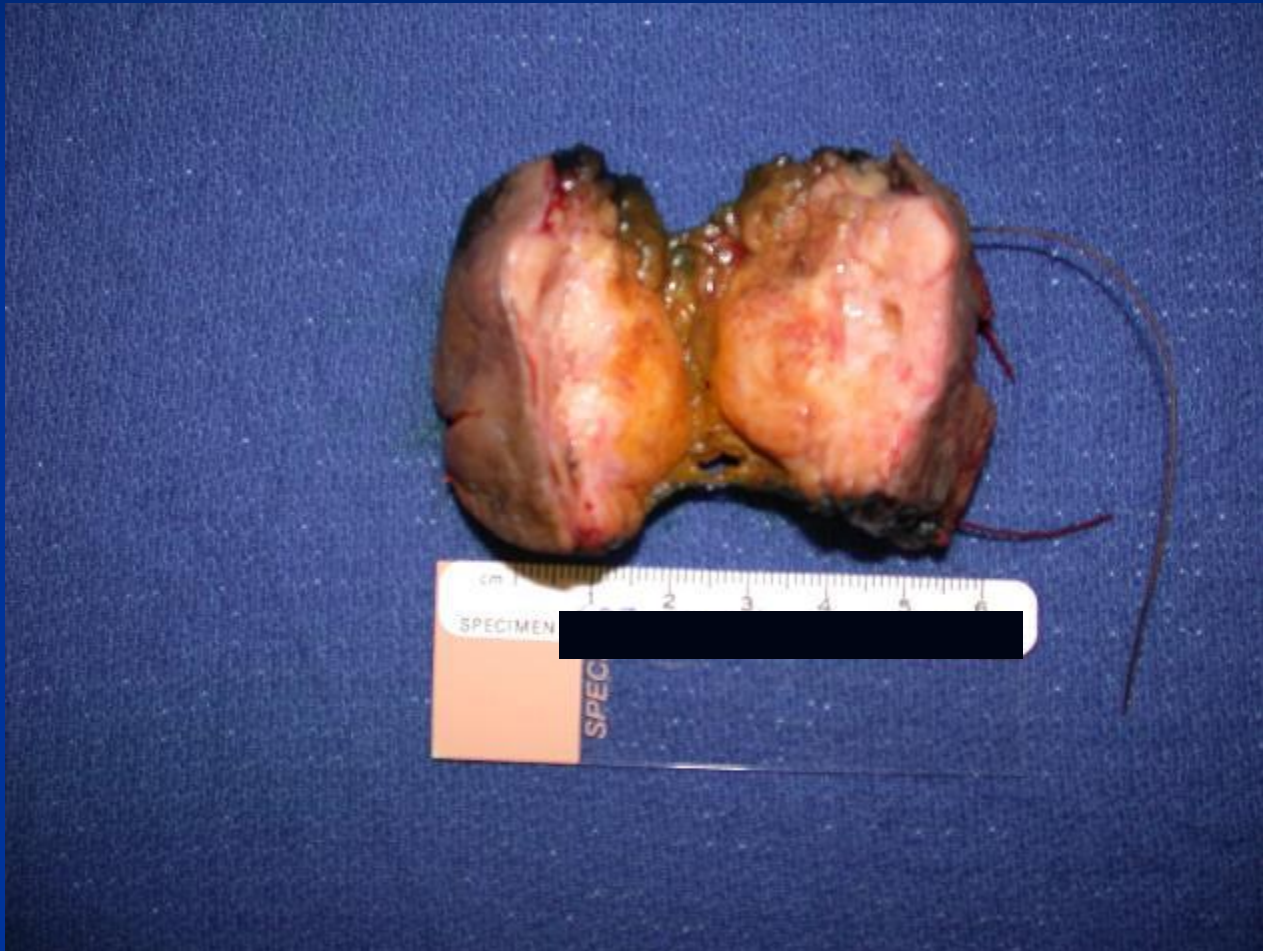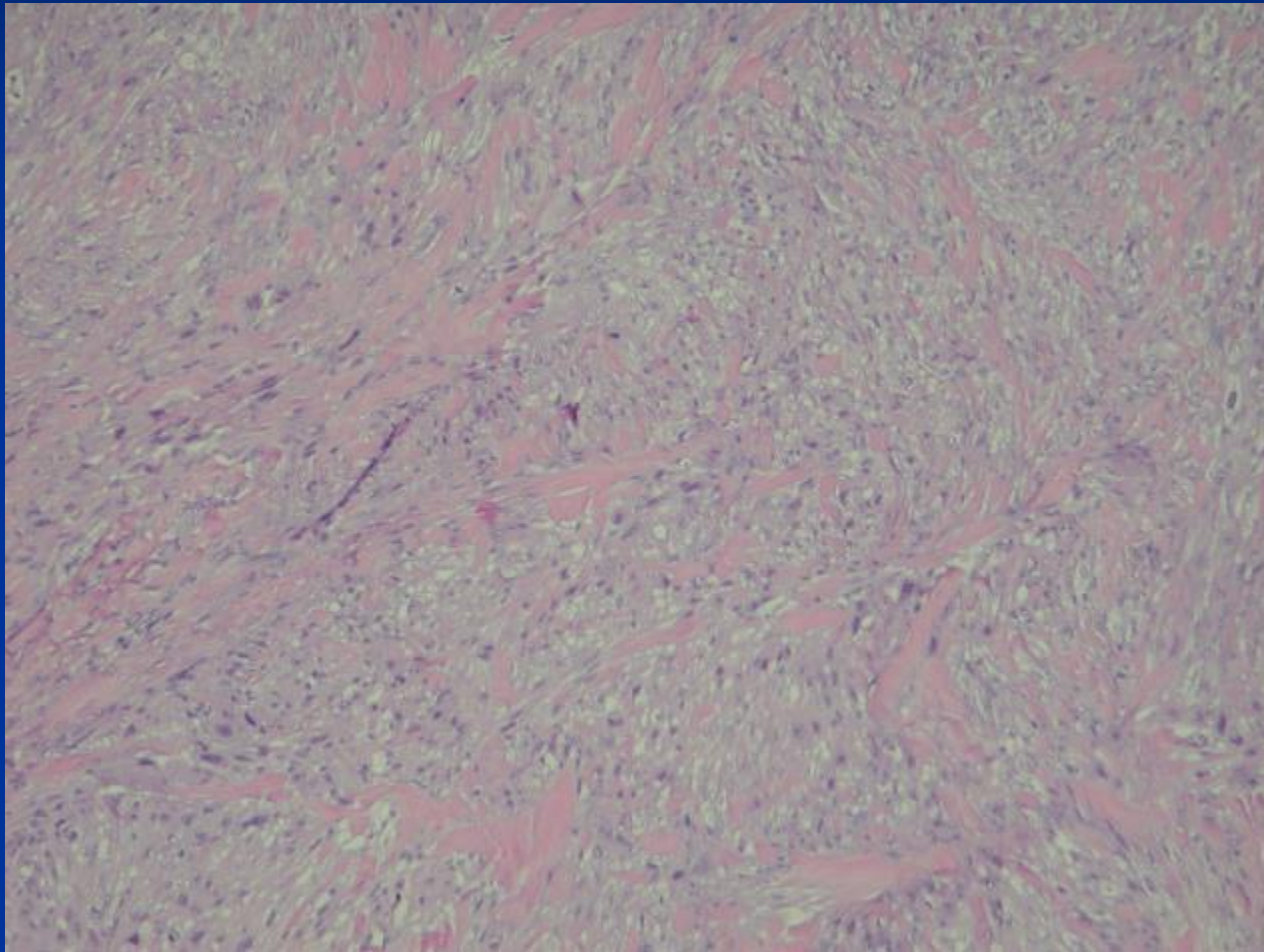






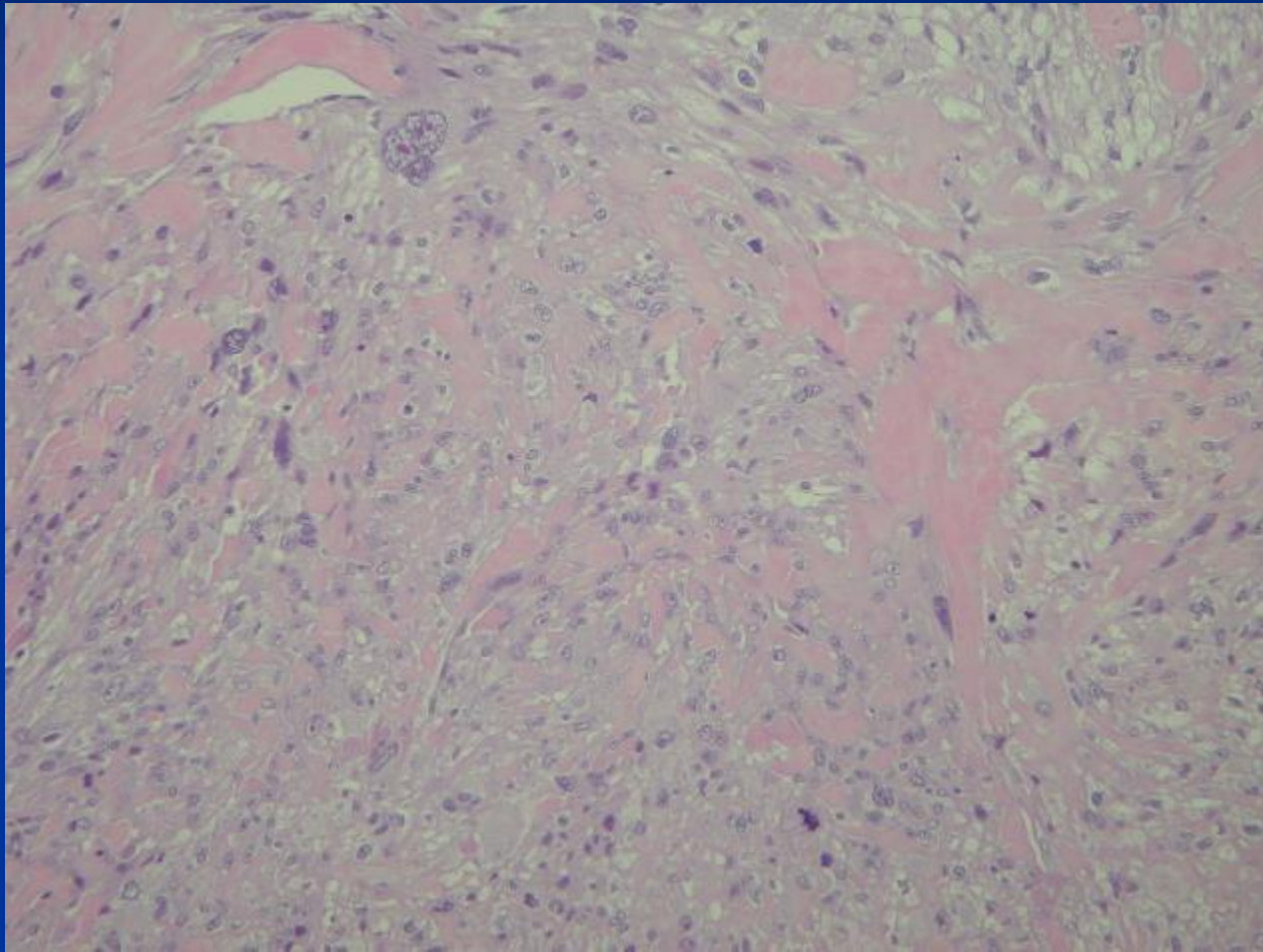
Leiomyosarcoma

Low Power

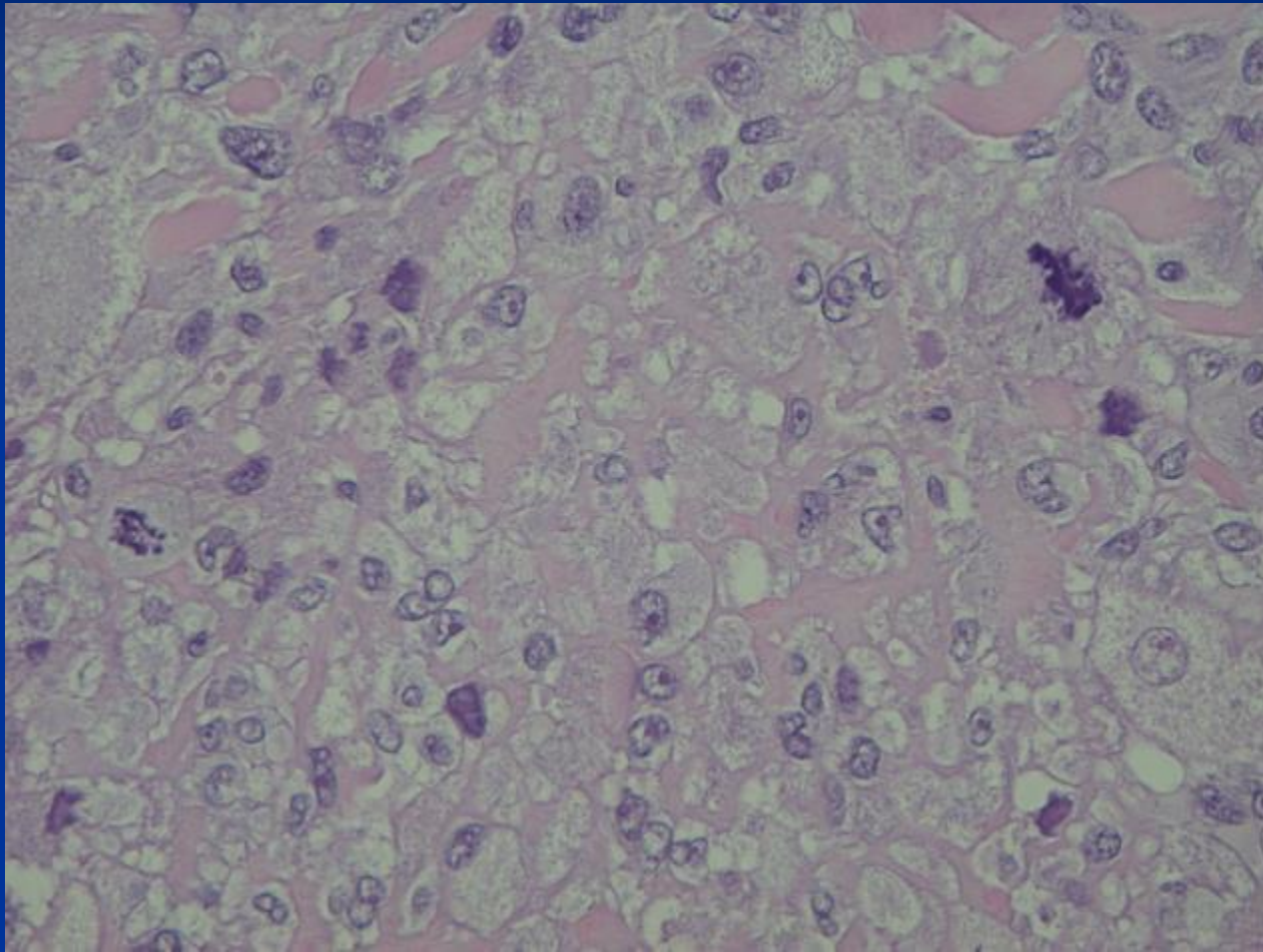


Leiomyosarcoma

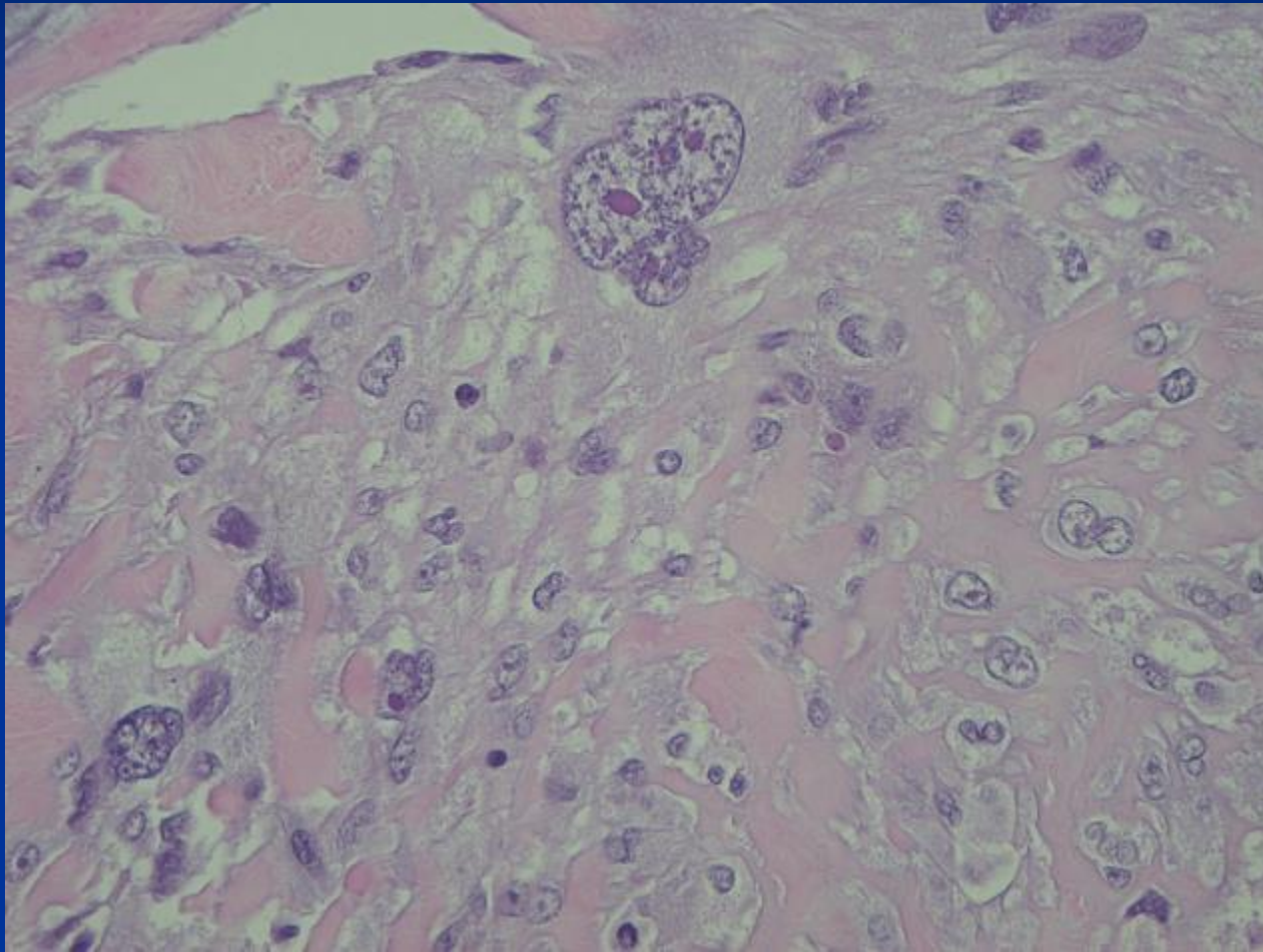
Intermediate Power



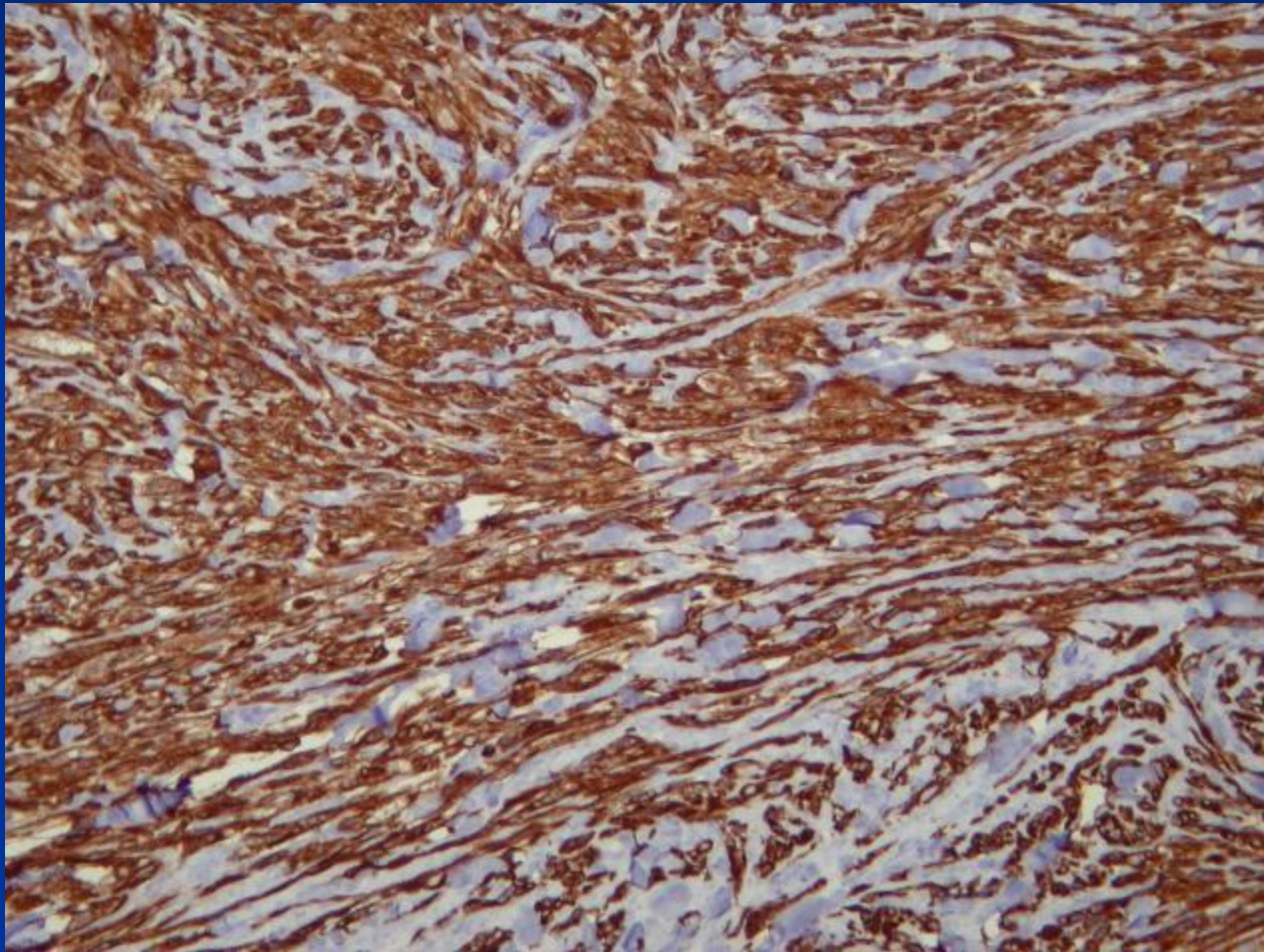
Leiomyosarcoma High Power



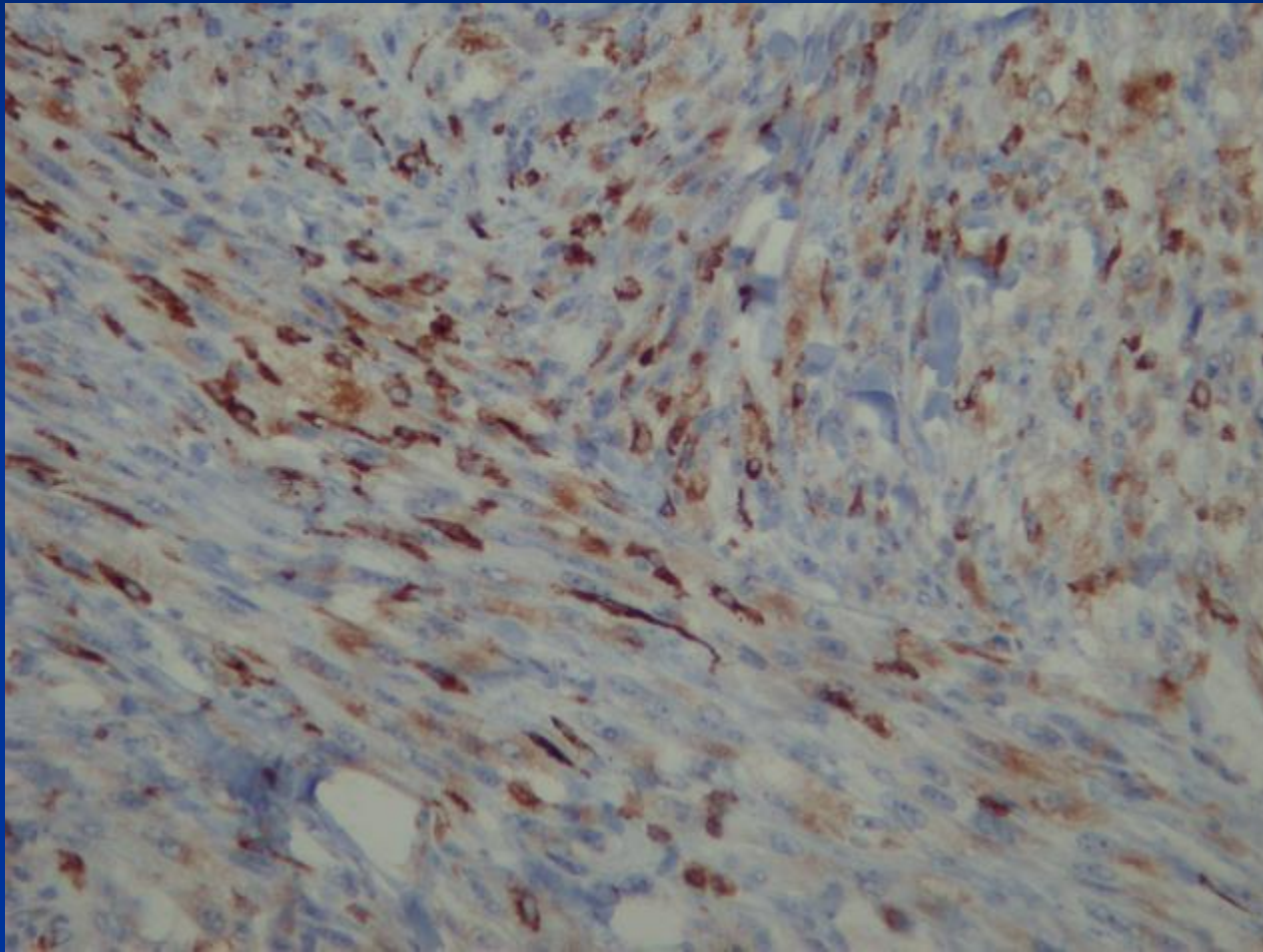
Leiomyosarcoma High Power



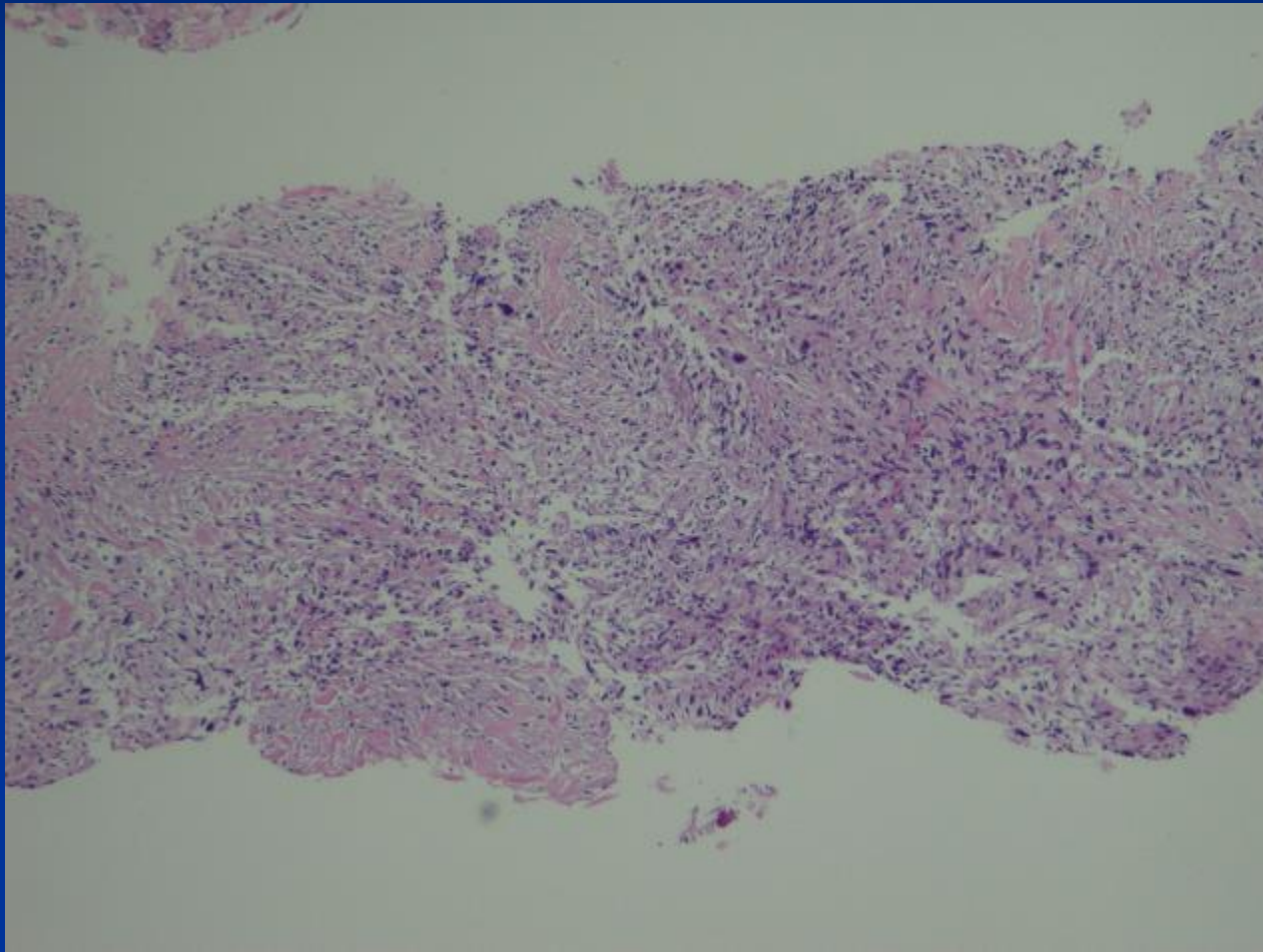
Leiomyosarcoma Actin Stain



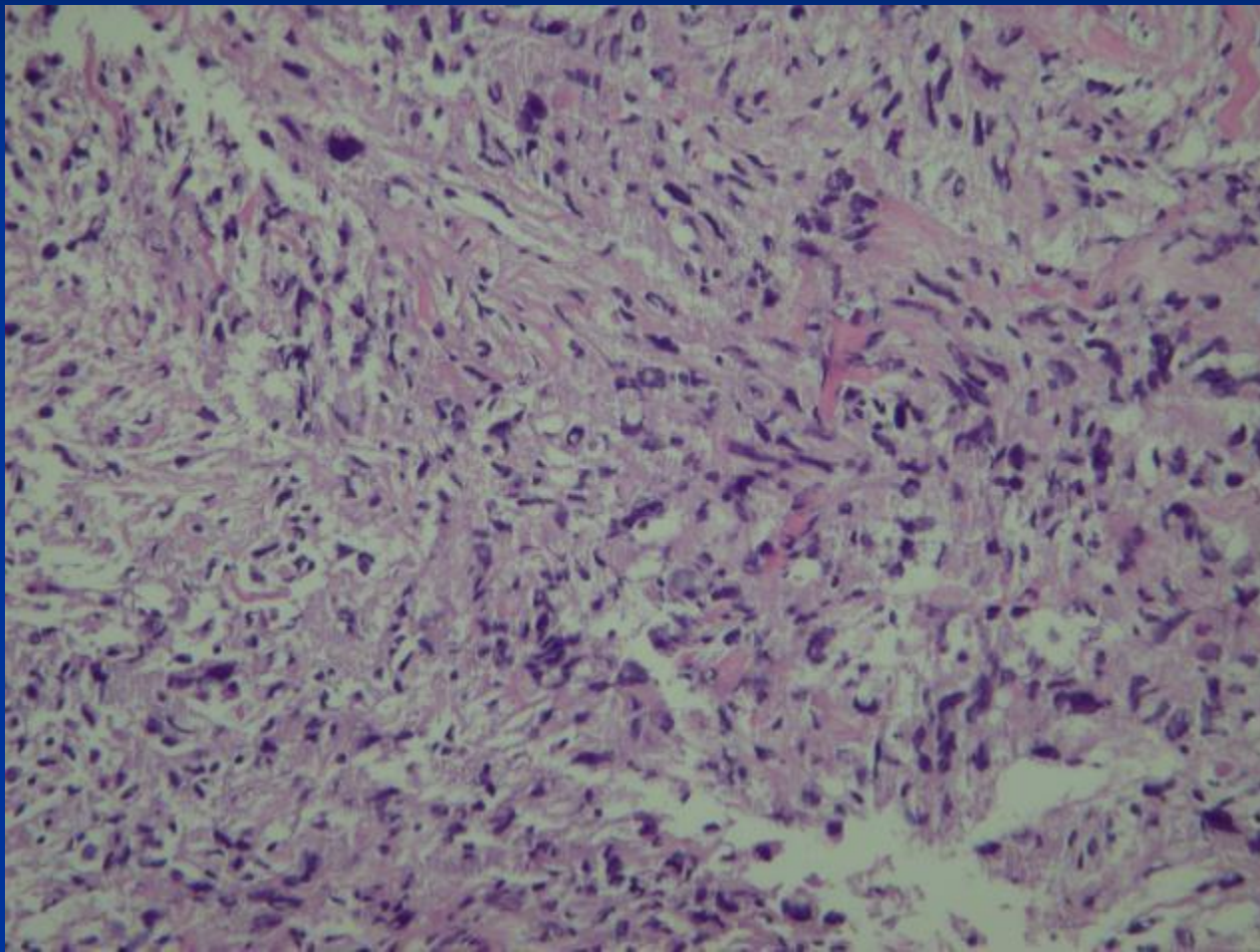
Leiomyosarcoma Desmin Positivity



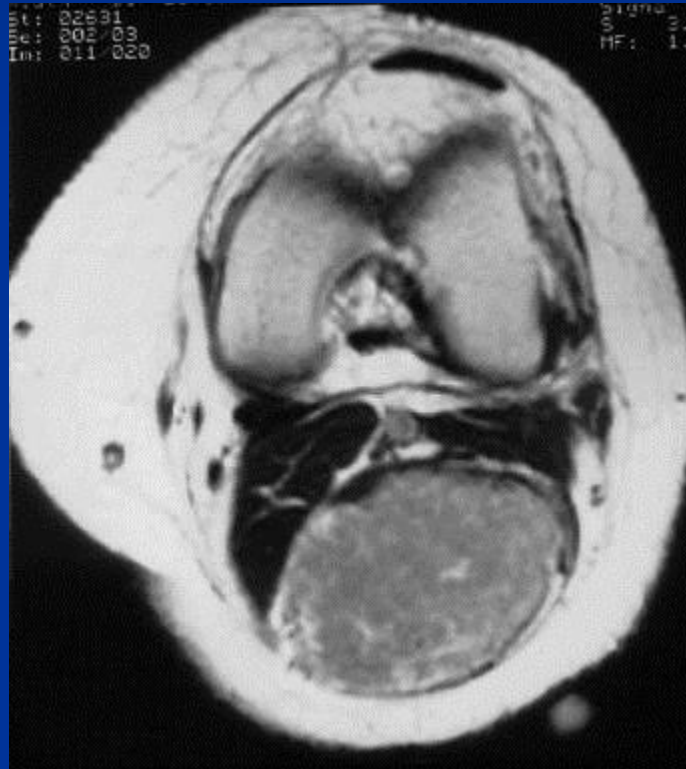
Leiomyosarcoma



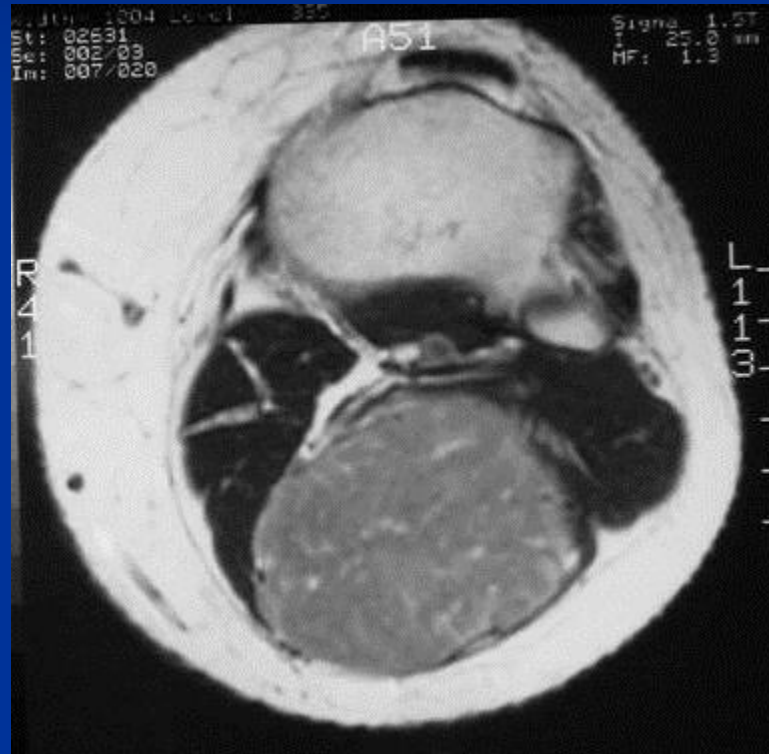
Leiomyosarcoma



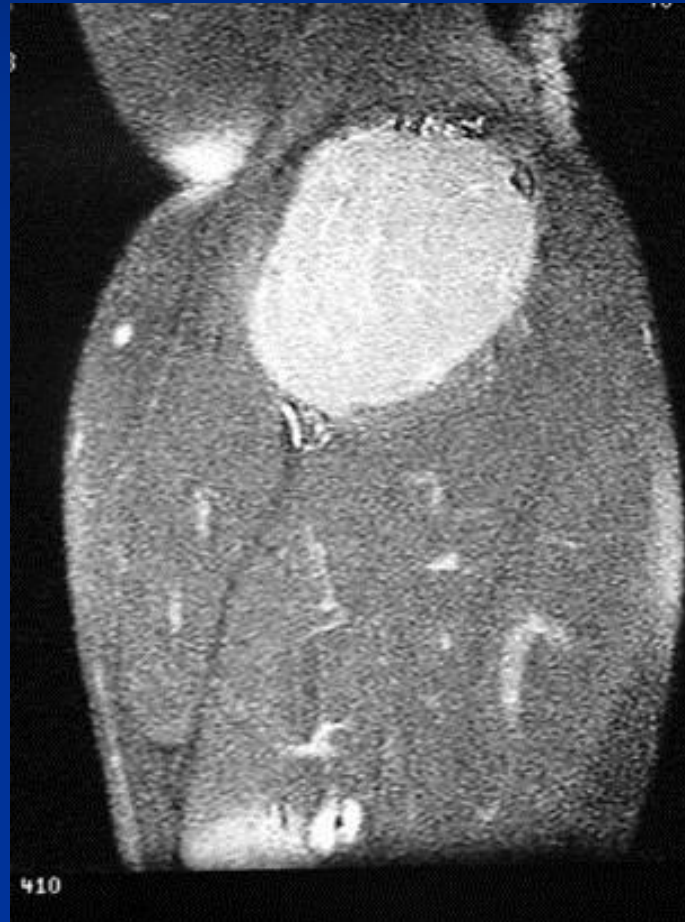Leiomyosarcoma



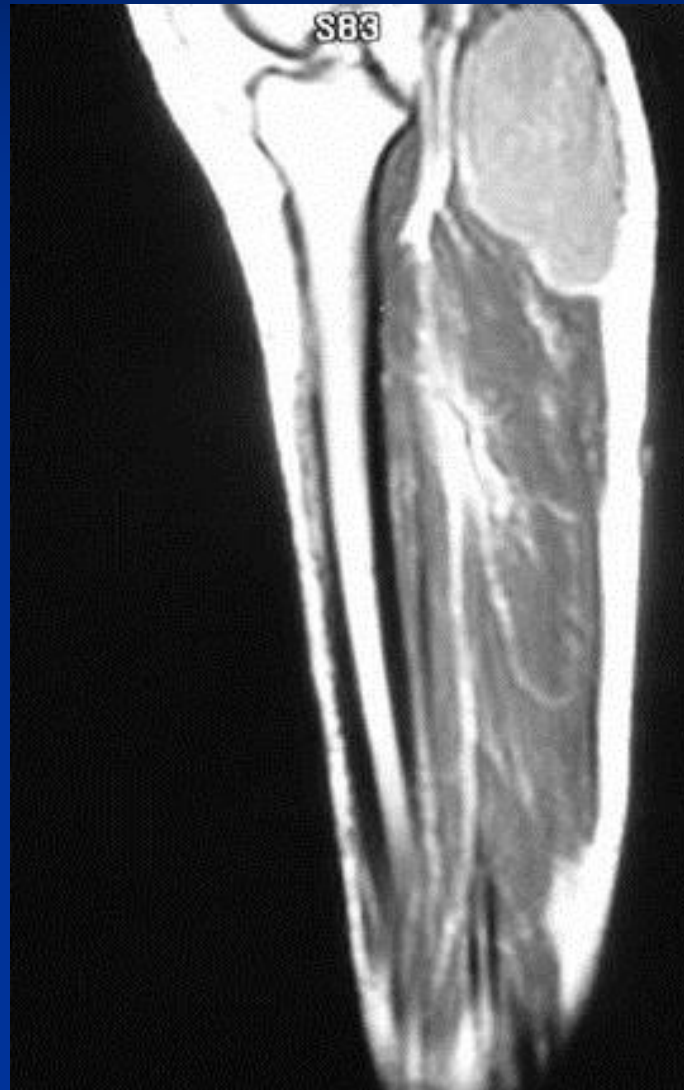Leiomyosarcoma



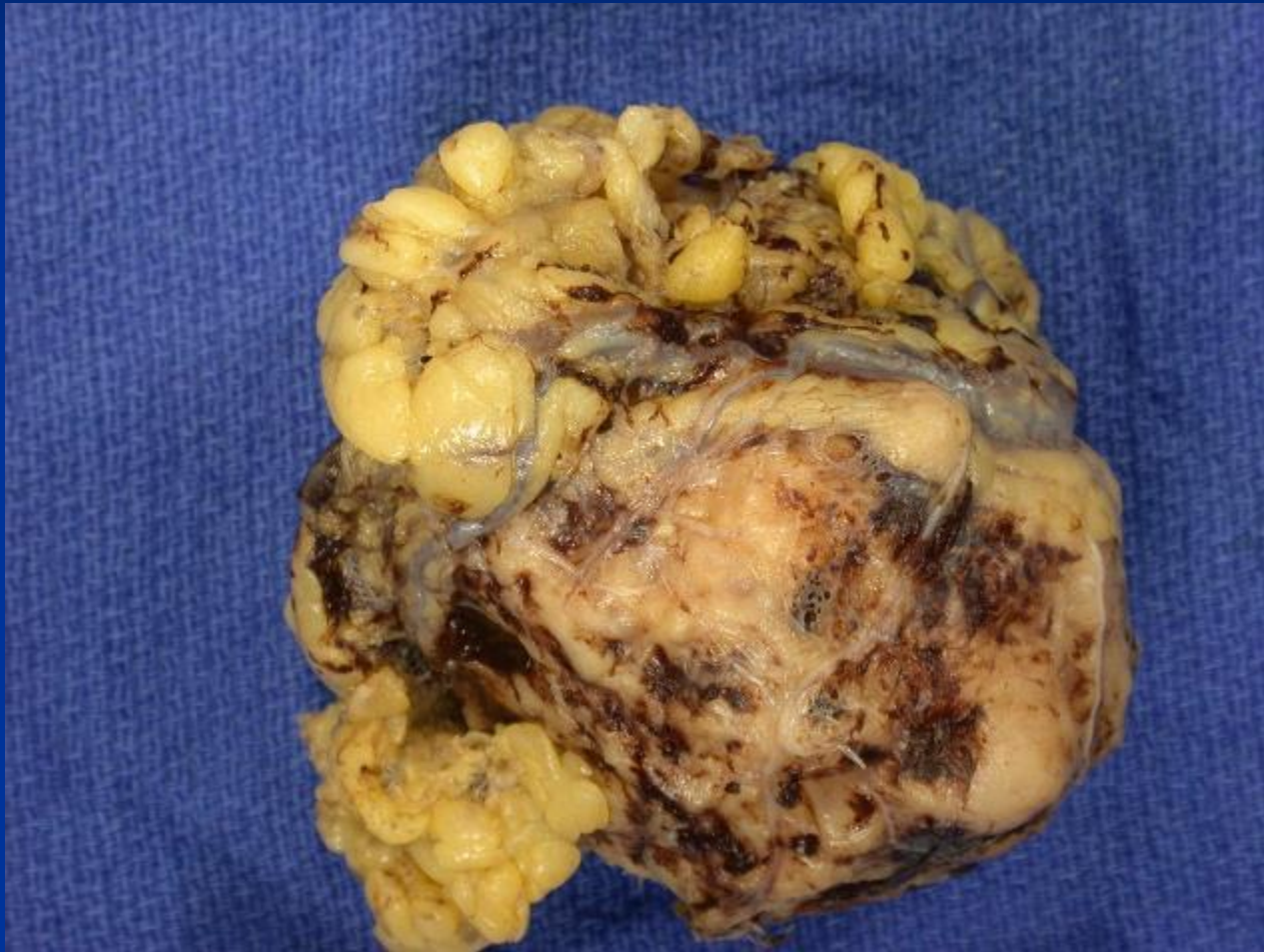Leiomyosarcoma



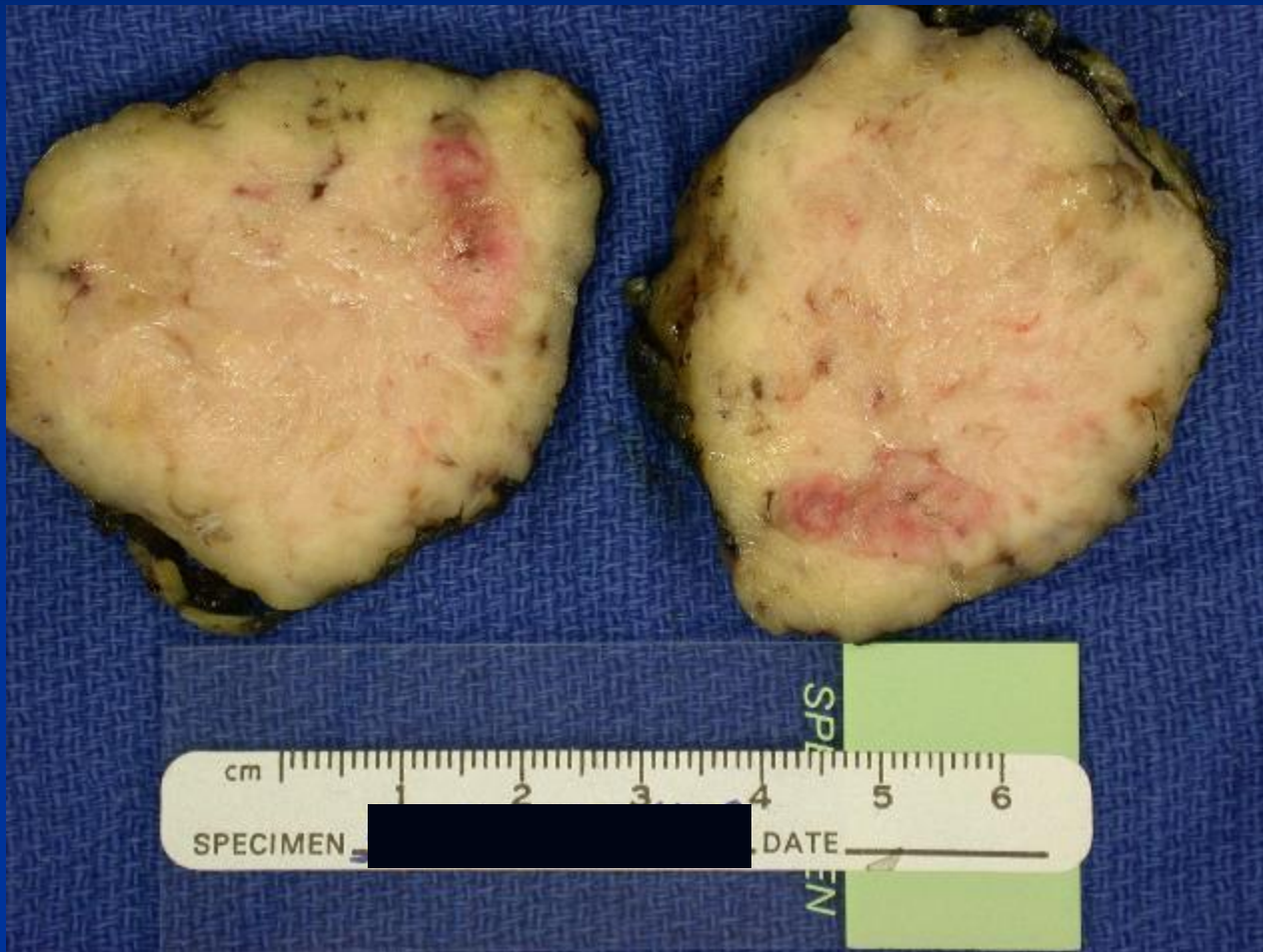Leiomyosarcoma



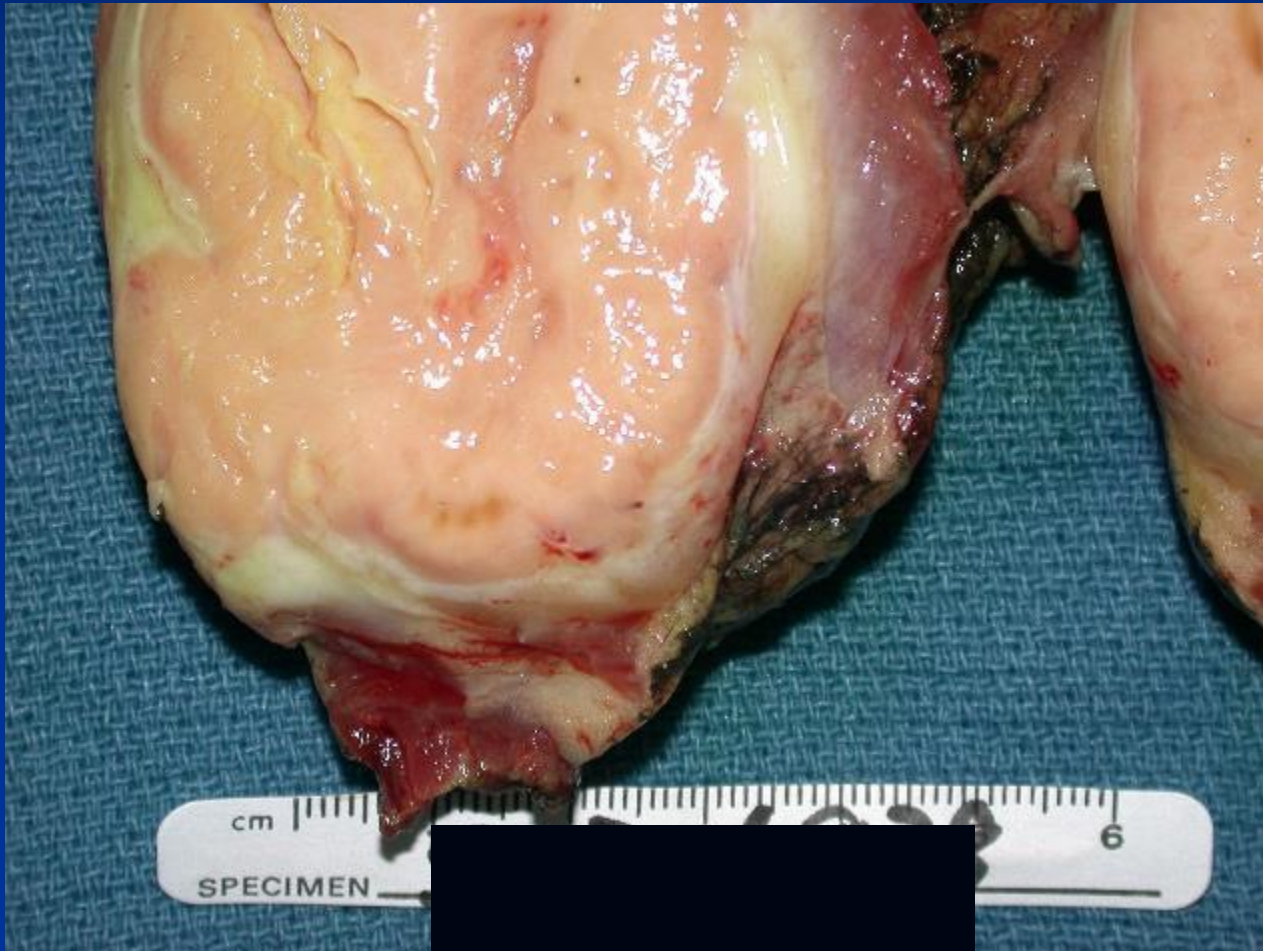Leiomyosarcoma



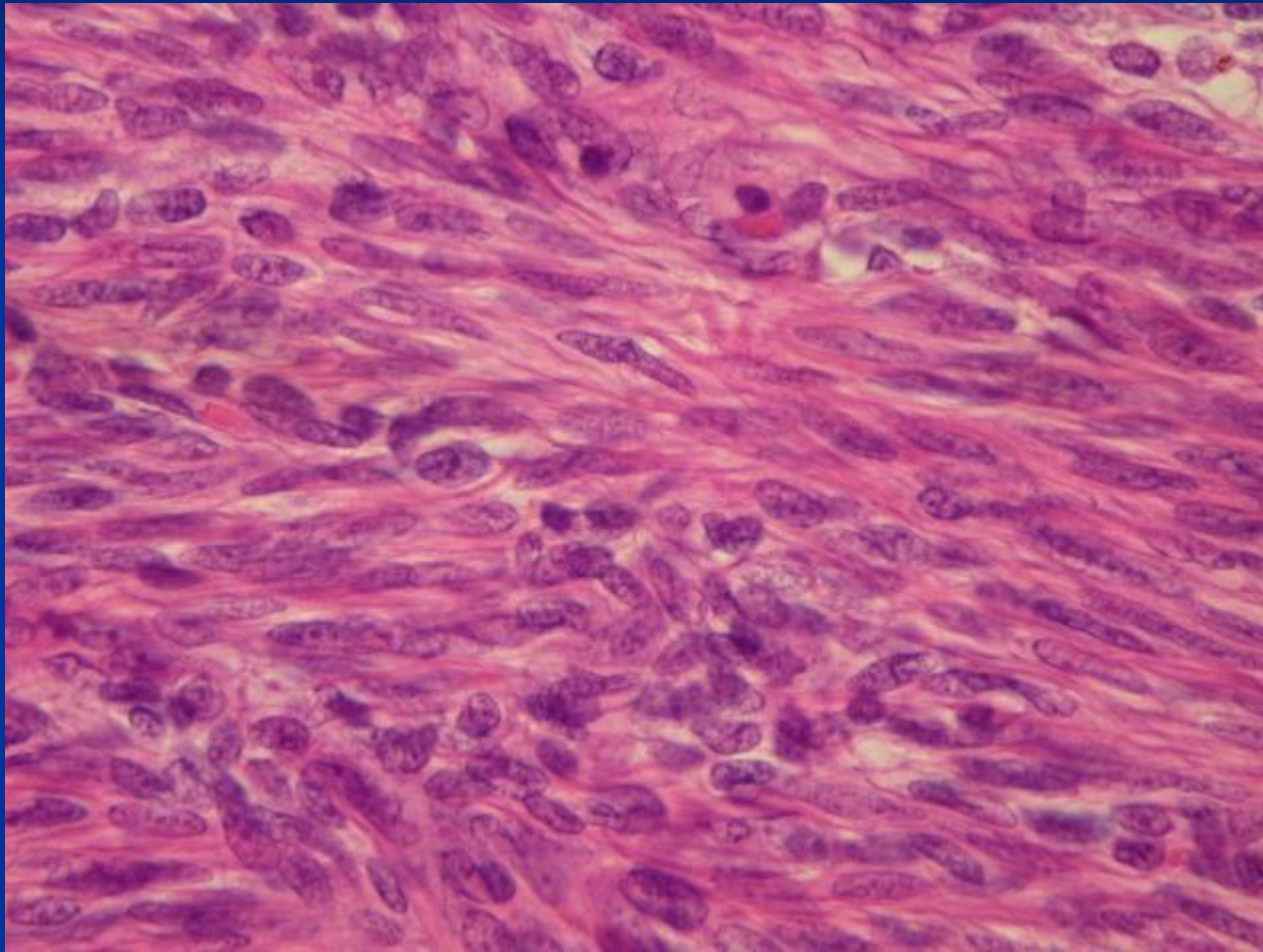
Leiomyosarcoma



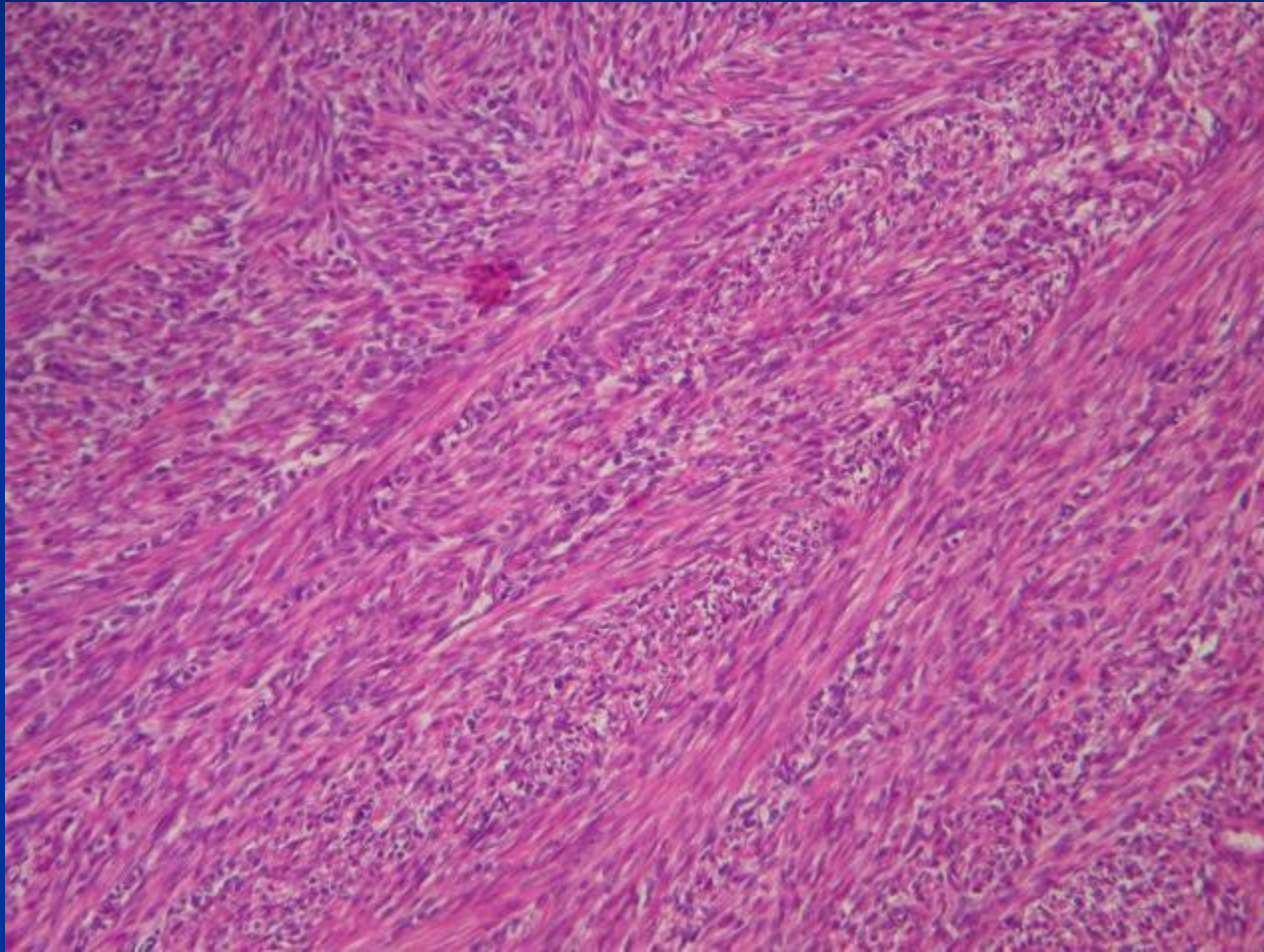
Leiomyosarcoma



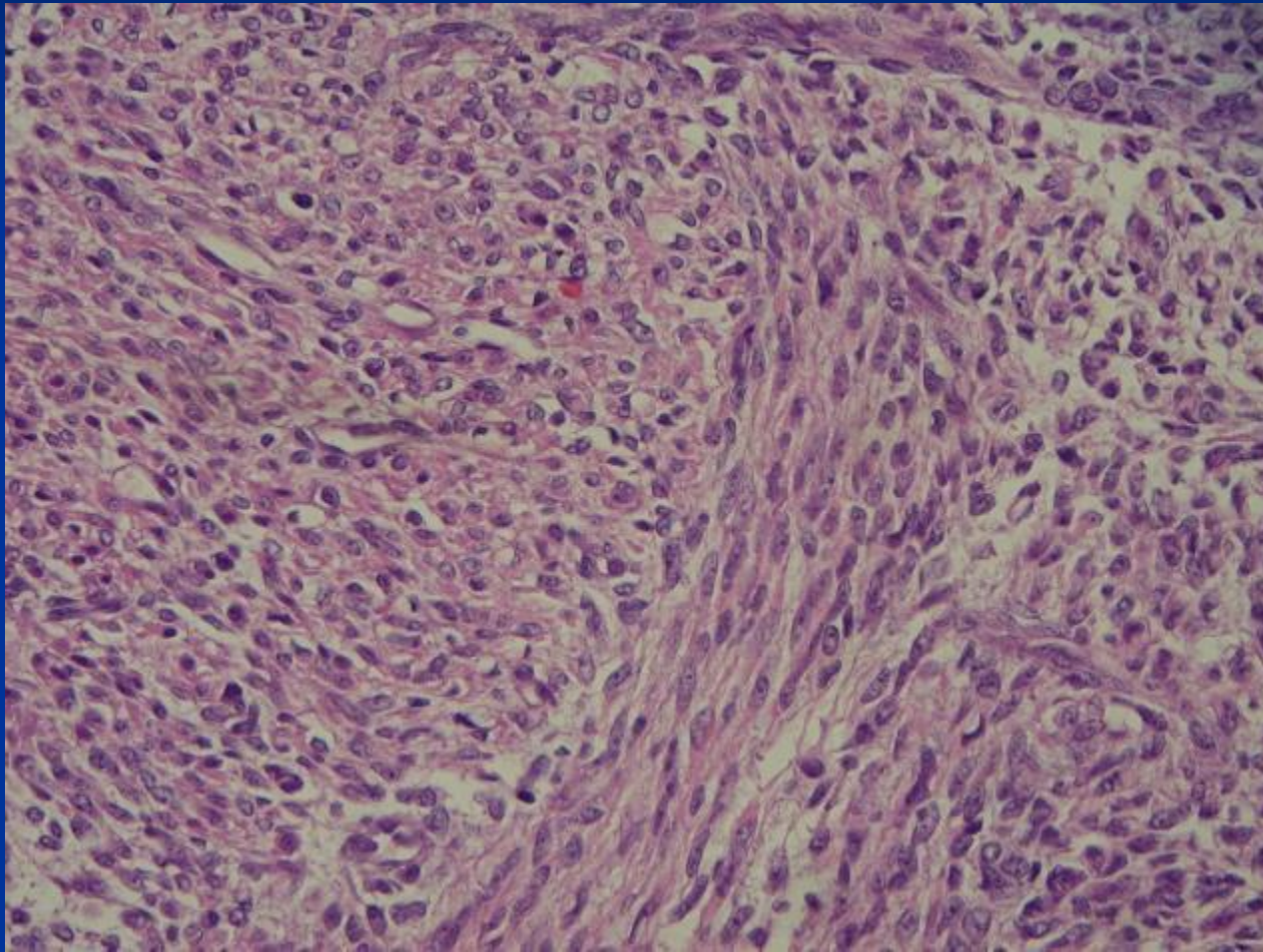
Leiomyosarcoma



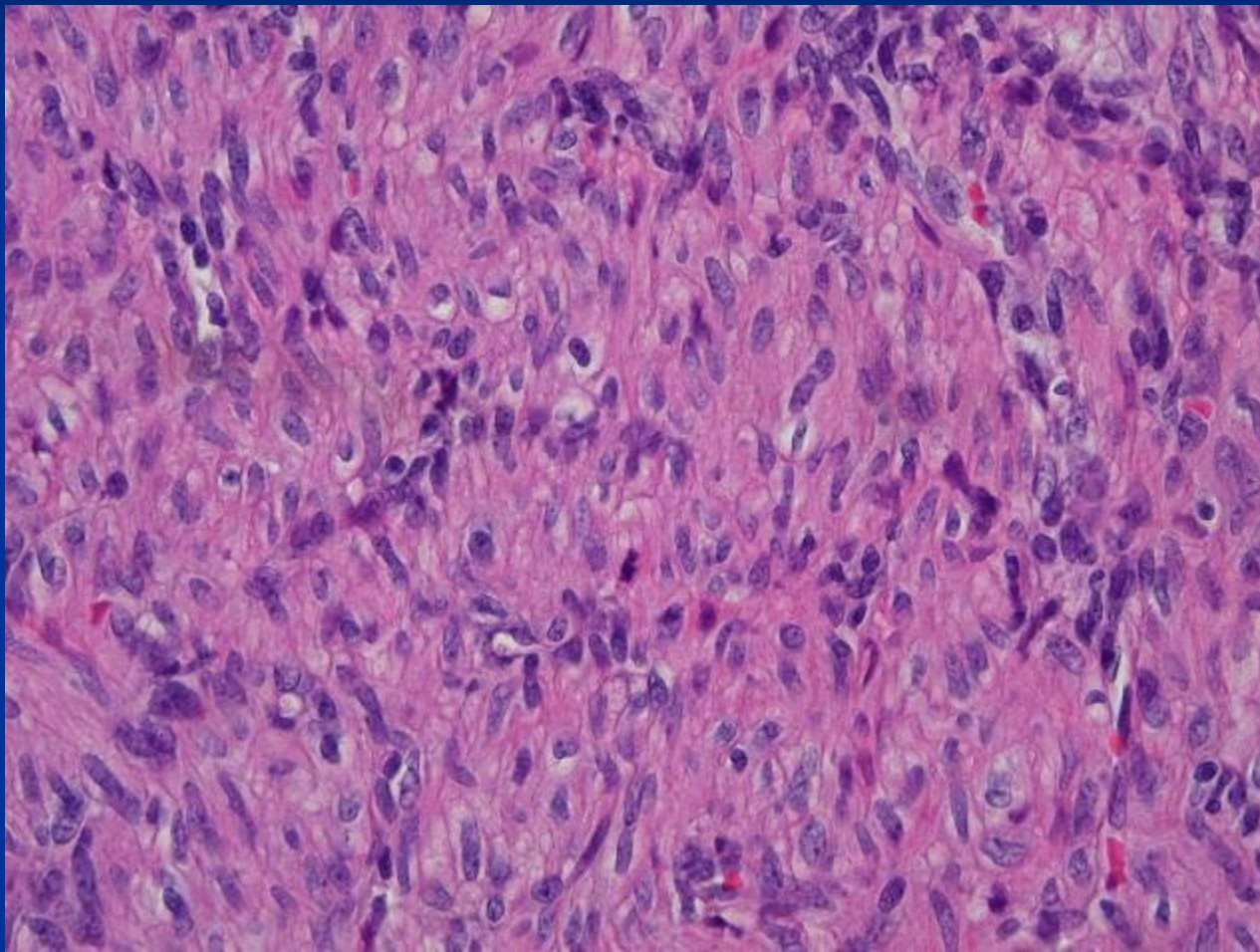
Leiomyosarcoma



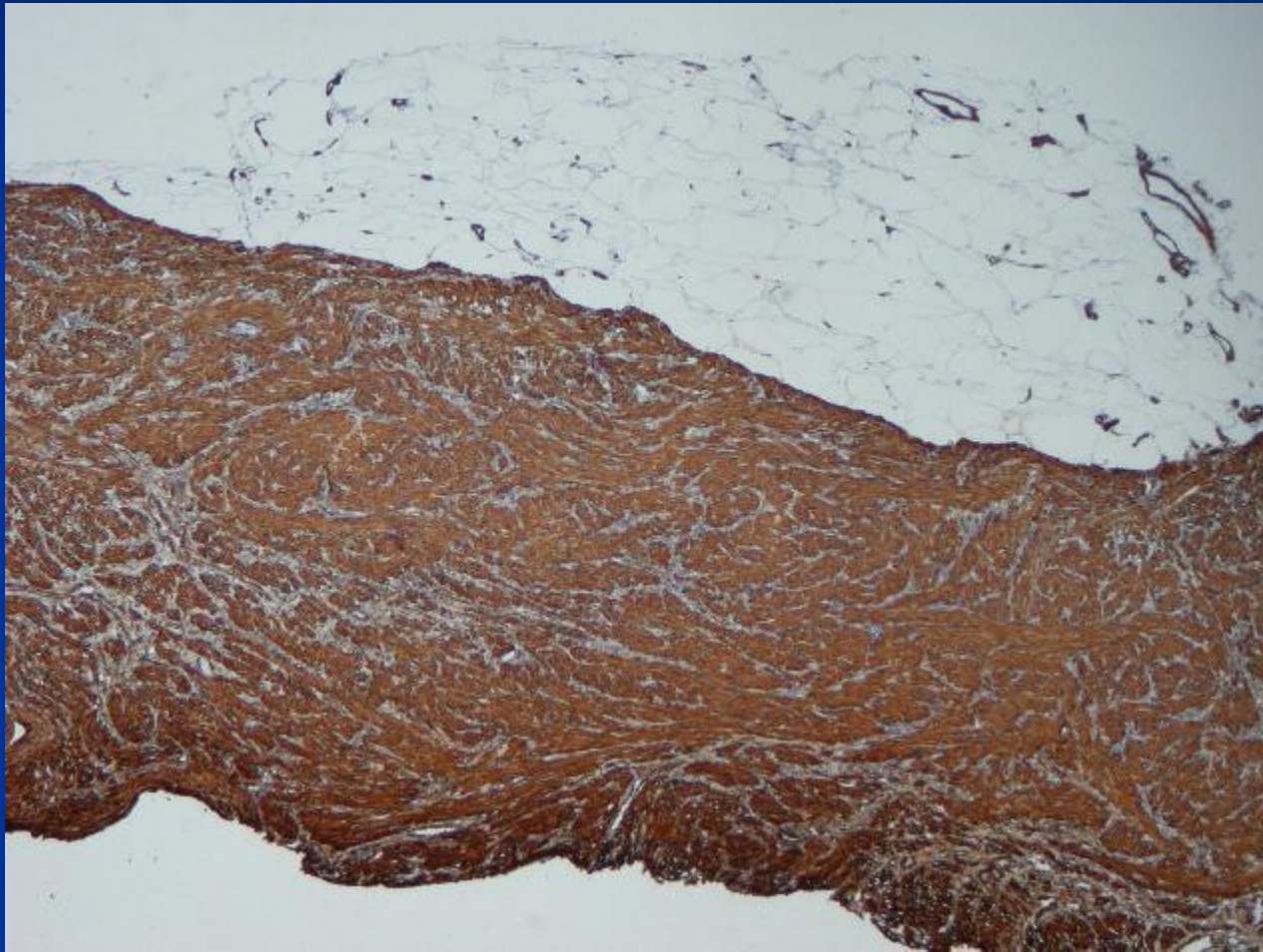
Leiomyosarcoma



Leiomyosarcoma



Leiomyosarcoma Actin Stain



Thank You!