

# **Benign Osseous Tumors**

**James C. Wittig, MD**

**Associate Professor of Orthopedic Surgery**

**Chief, Orthopedic Oncology**

**Mount Sinai Medical Center**

# Osseous Lesions of Bone

## ■ Benign

- Enostosis and related conditions
- Osteoma
- Osteoid Osteoma
- Osteoblastoma

## ■ Malignant

### ■ Osteosarcoma

#### ■ Intramedullary

##### ■ Conventional

- Osteoblastic
- Fibroblastic
- Chondroblastic

##### ■ Telangiectatic

##### ■ Small Cell

##### ■ Low Grade Intraosseous

#### ■ Juxtacortical

- Parosteal
- Periosteal
- High grade surface

#### ■ Intracortical

# Osseous Lesions of Bone

- **Definition:** Characterized by the presence or production of bone and/or osteoid
- **Radiographically:** Mineralization

# Benign Osseous Lesions of Bone

## ■ Enostosis (Bone Island)

- Solitary foci, spot or island of dense compact bone within the medullary cavity (within cancellous bone)
- Considered a hamartoma or developmental abnormality
- Usually found incidentally
- Patient is usually asymptomatic
- Rare in children

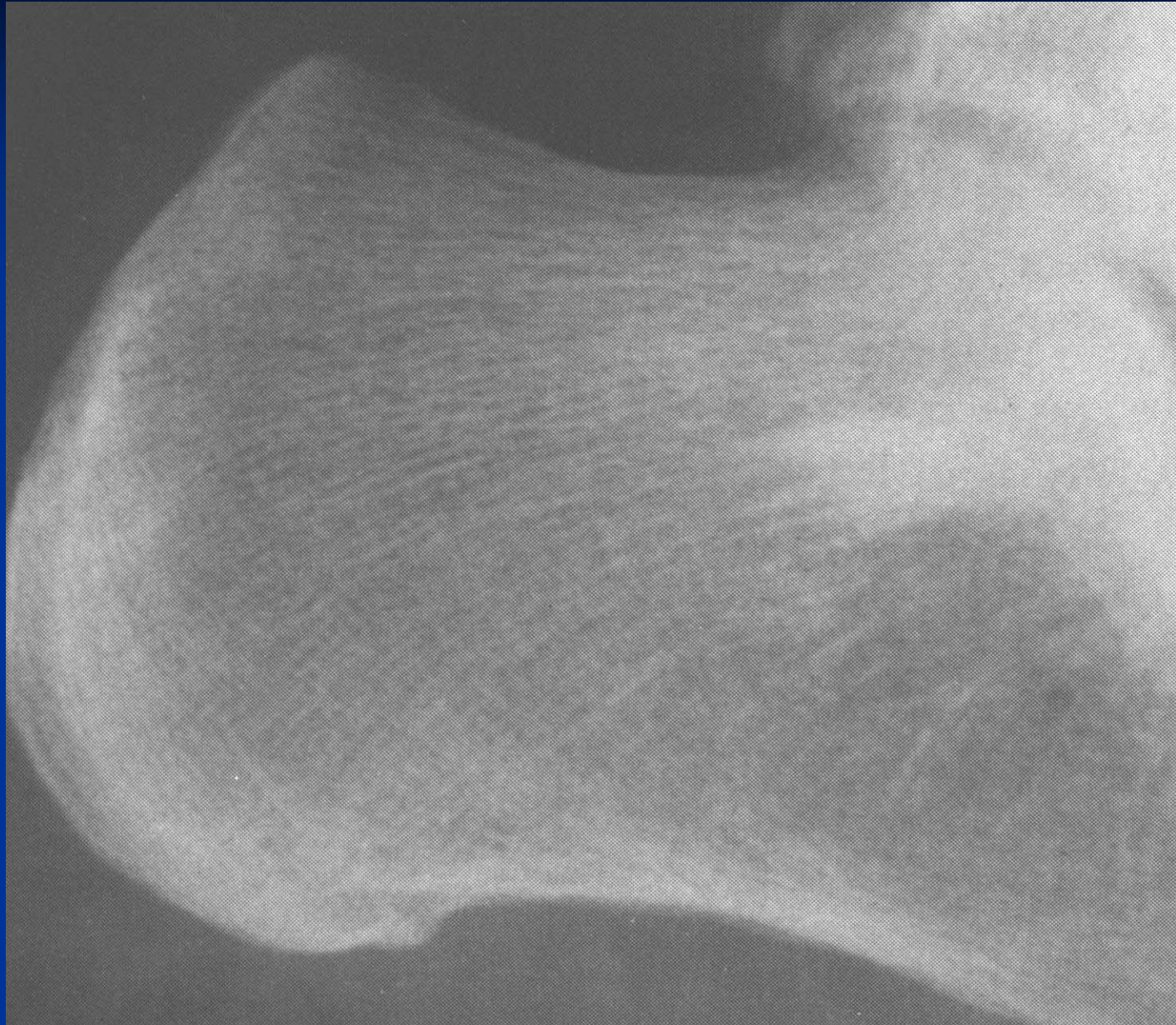# Enostosis

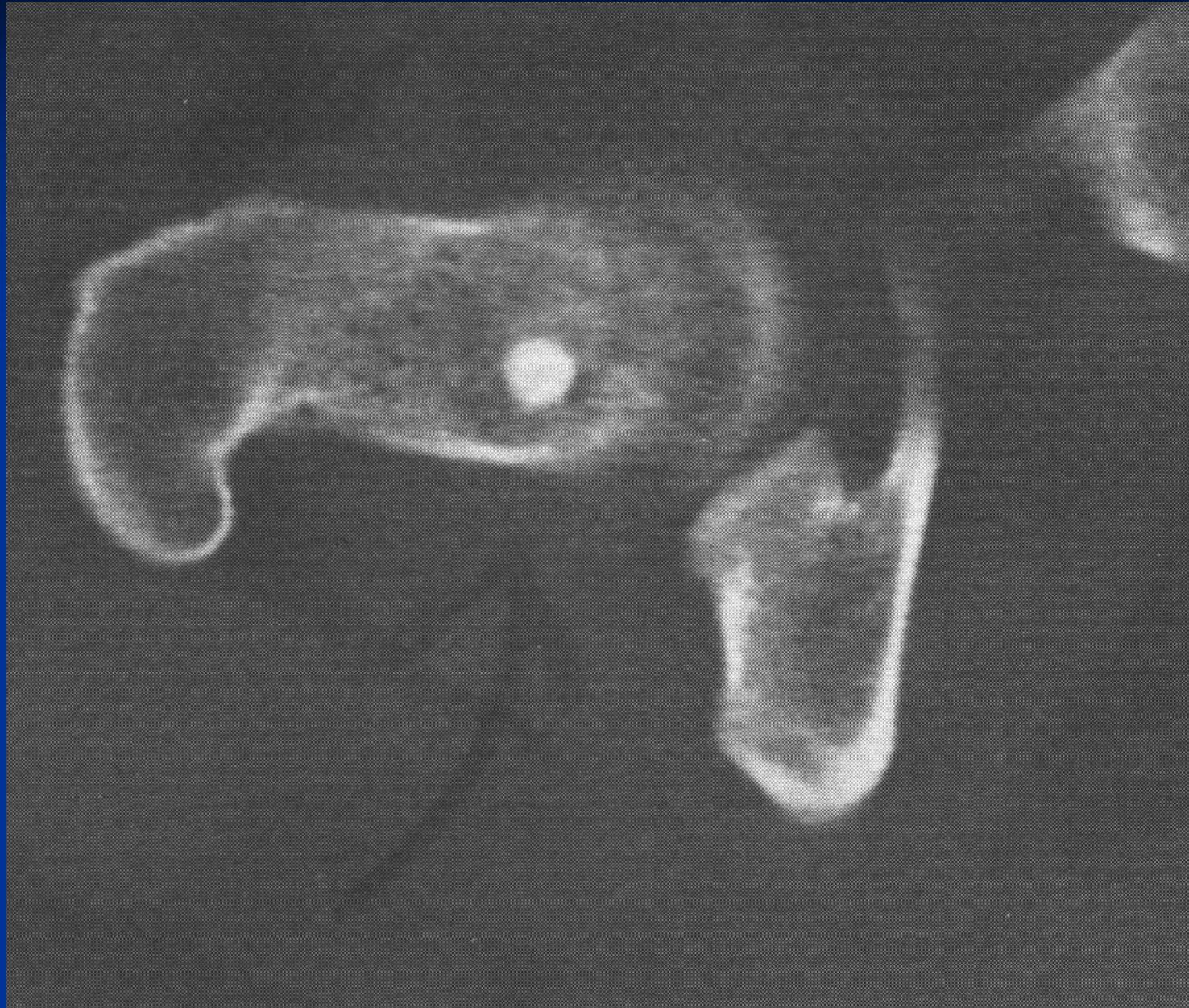- **Anatomic Sites:**
  - Any site
  - Most Common
    - Ribs
    - Spine
    - Pelvis

# Enostosis

## ■ Radiology

- Round to oval dense osteoblastic area within the intramedullary canal
- May be attached to inner cortex
- .2 to 2 cm
- Often epiphyseal or metaphyseal
- Thorny, radiating spicules at margin but are well defined
- Bone scan: Normal to mild increase in activity







# Enostosis

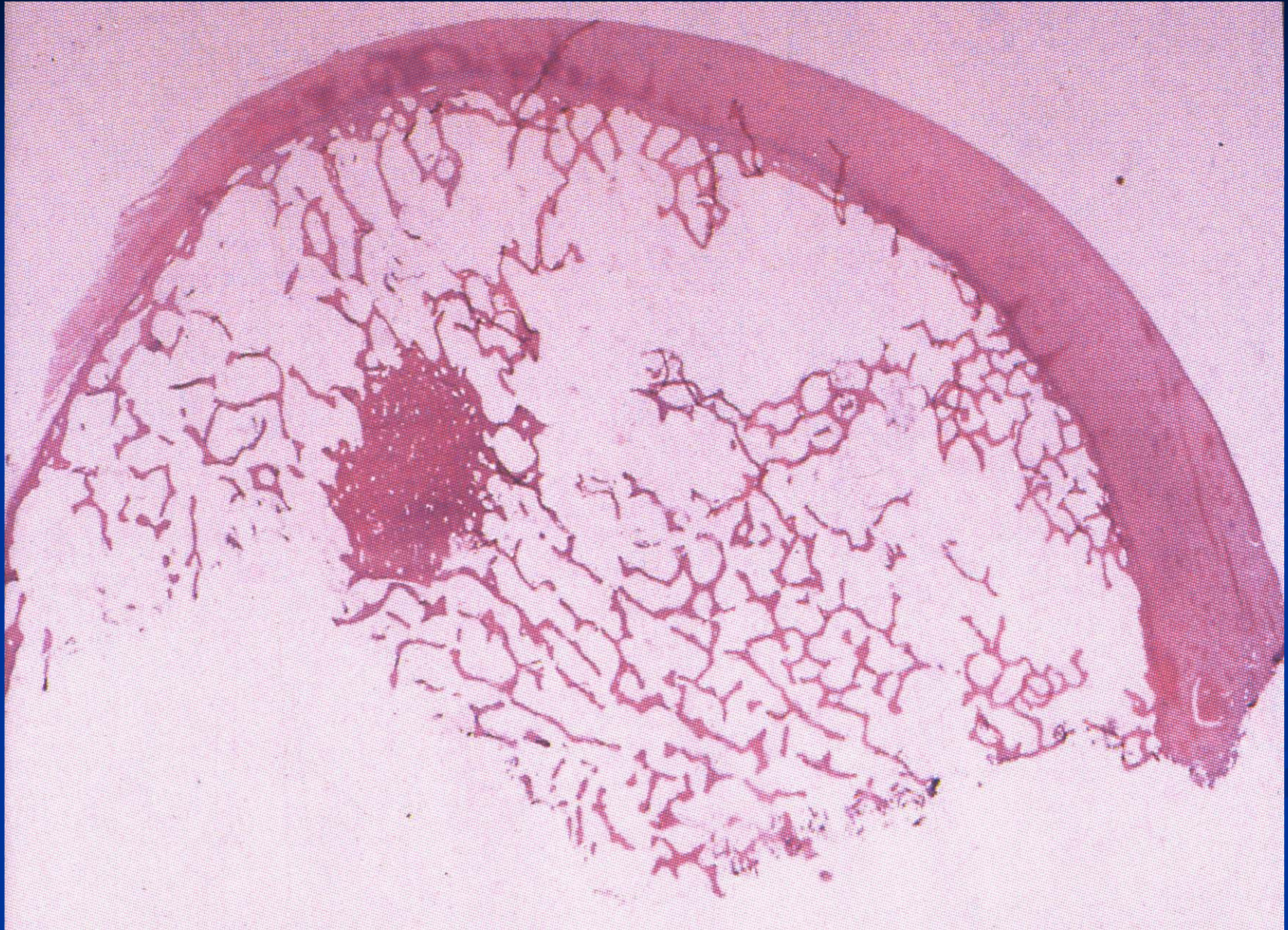
## ■ Radiology:

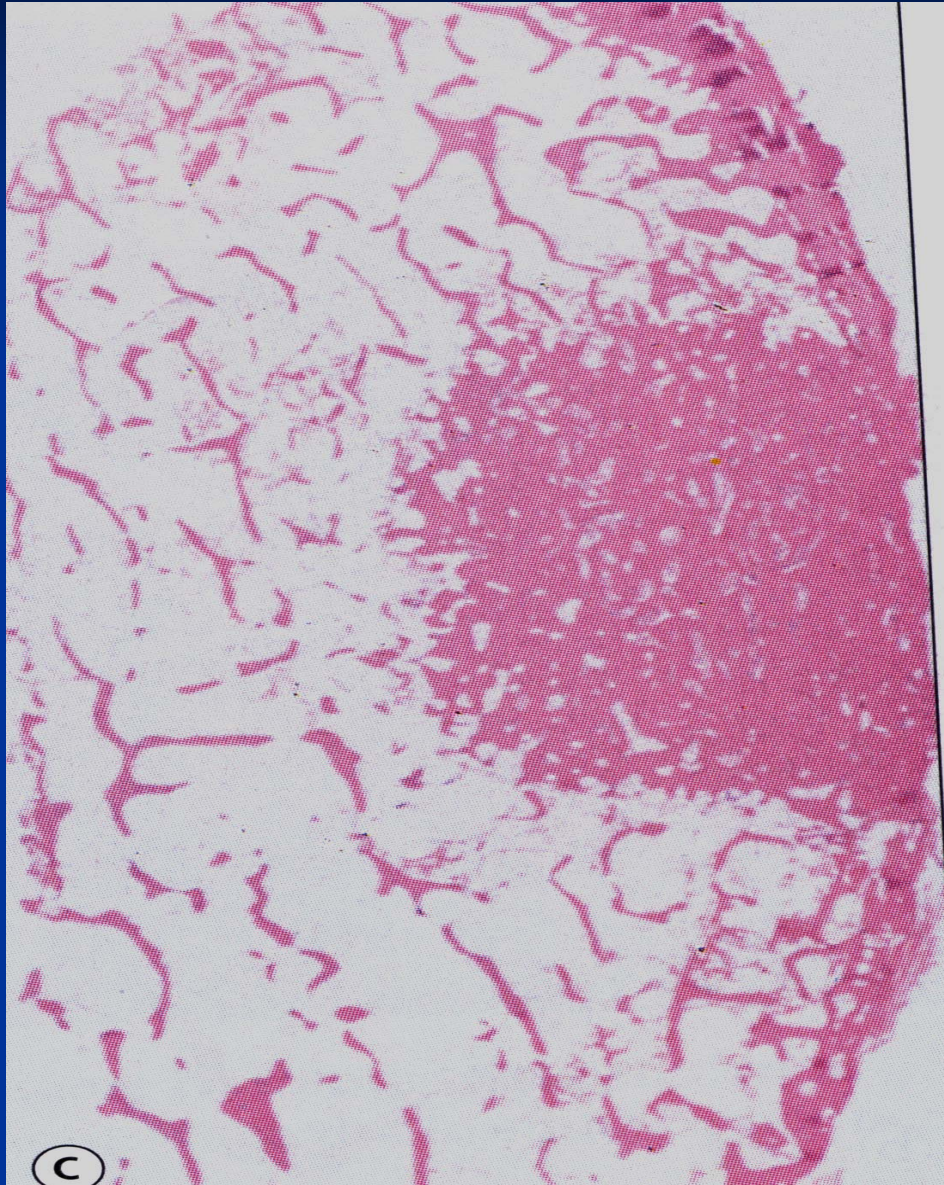
- May slowly increase or decrease in size
- Up to 25% increase in diameter over 6 months
- Differential Dx:
  - Osteoblastic Metastasis
  - Osteoma
  - Osteoid Osteoma
  - Low Grade Osteosarcoma
- Bone scan is best test to differentiate
- Follow up: 1, 3, 6, 12 mos; Biopsy if grows too rapidly

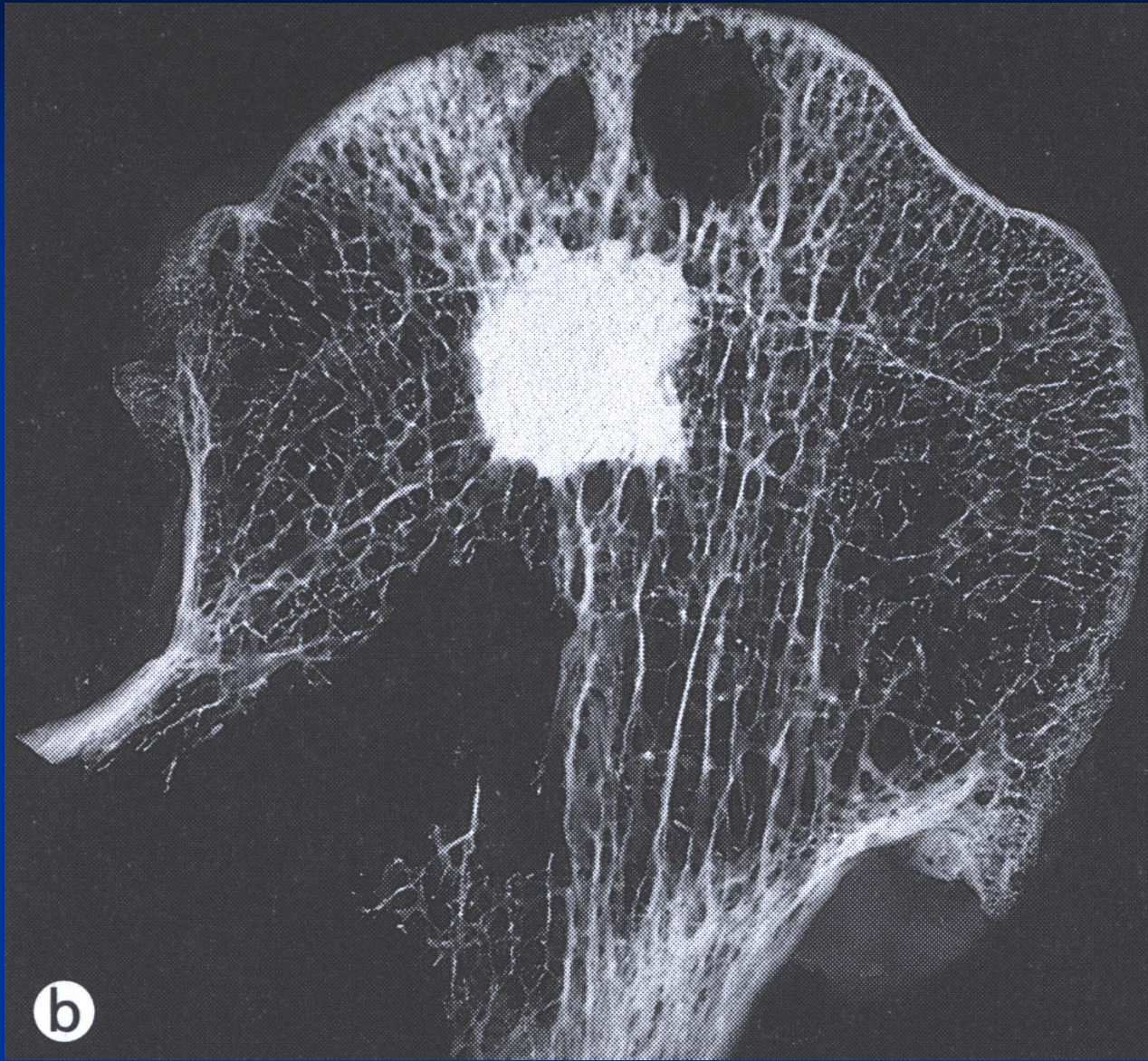
# Enostosis

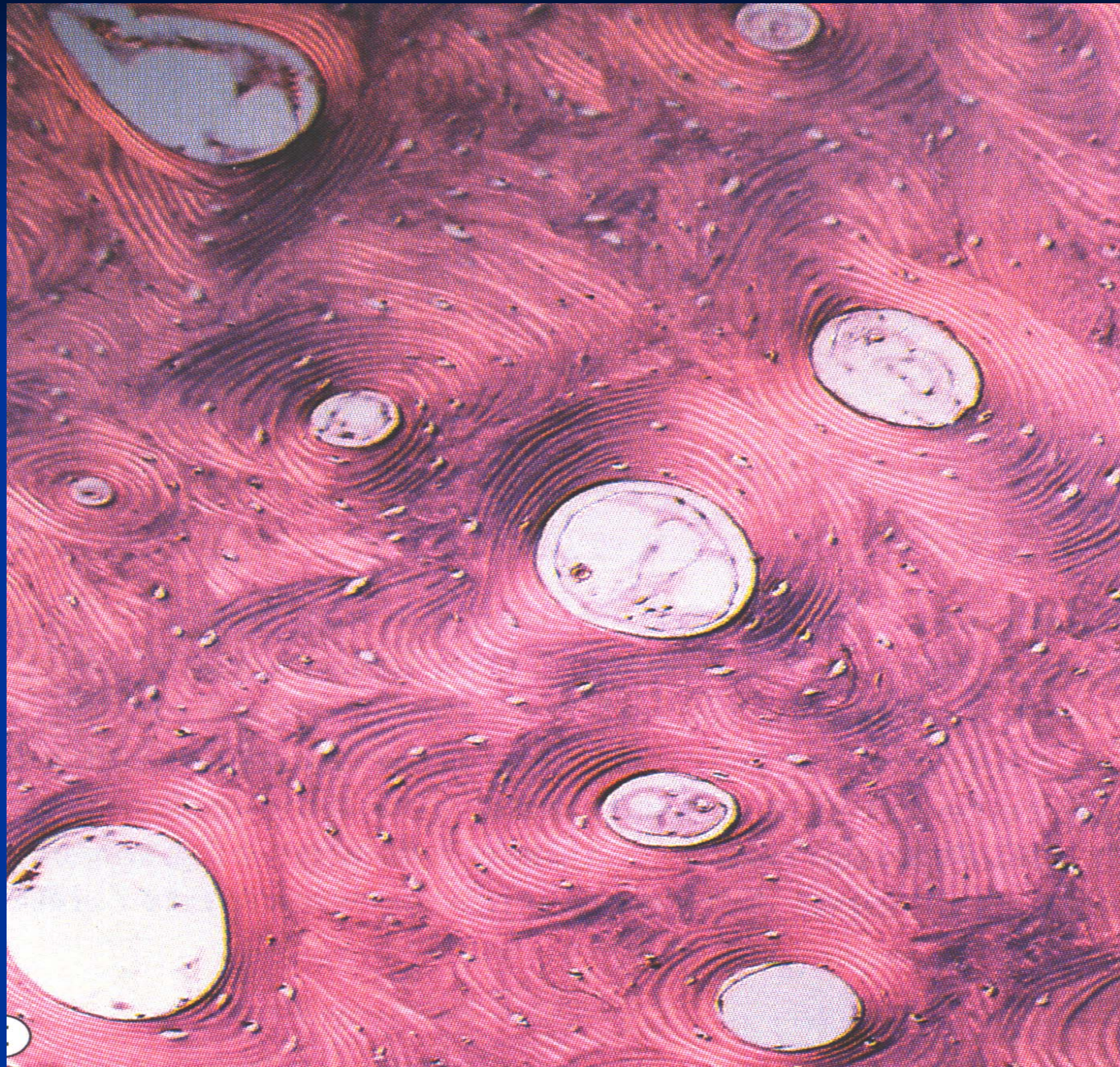
## ■ Pathology:

- Intramedullary
- Normal appearing compact, lamellar (cortical) bone with haversian canals within medullary bone
- Thornlike projections at margins blend with surrounding trabeculae creating an irregular margin
- Haversian canals with osteoblasts and osteoclasts (Howship's lacunae)—Features of active bone deposition and remodeling
- Increased activity on bone scan (Increased bone turnover)









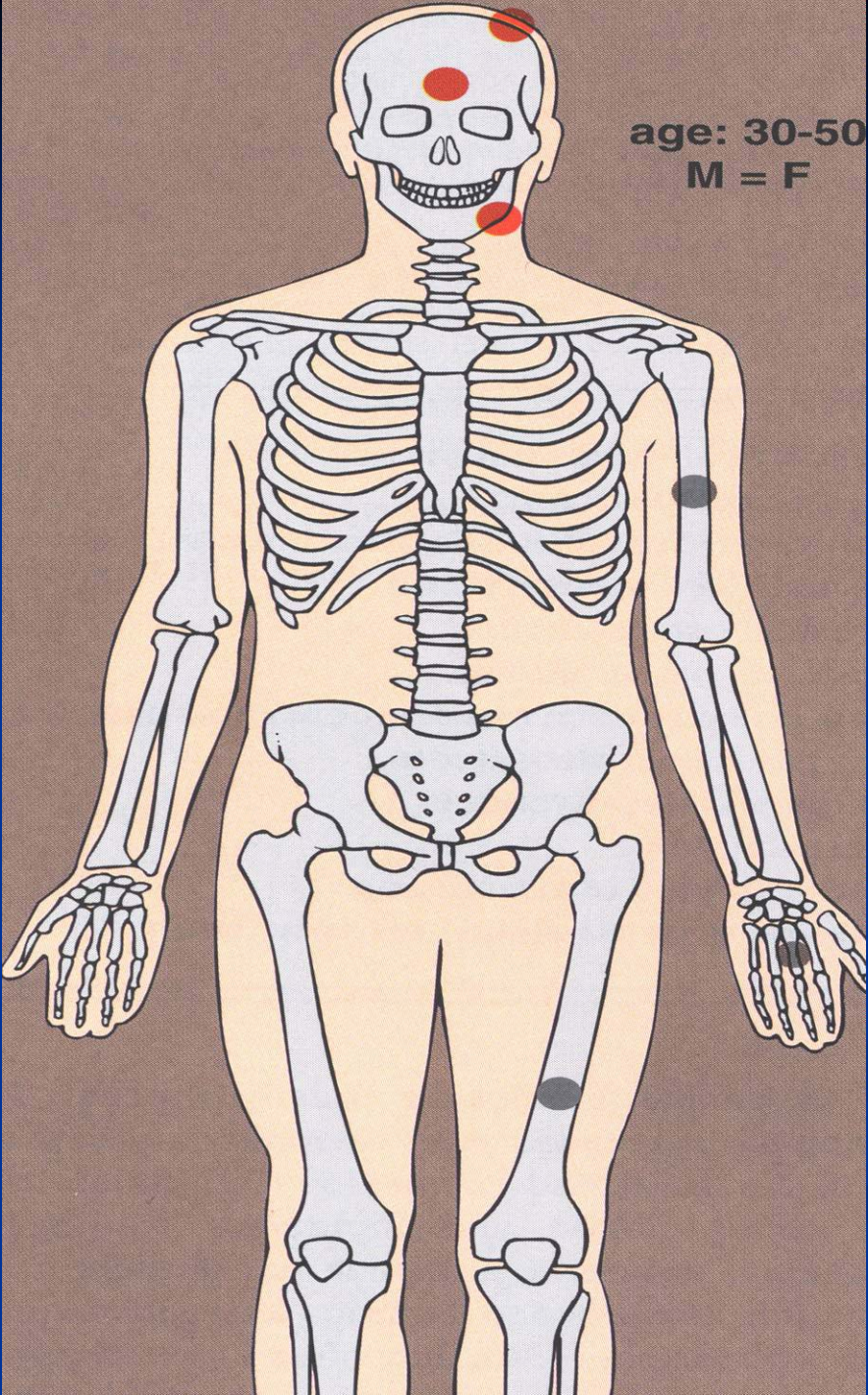
# Giant Enostosis (Giant Bone Island)

- Greater than 2-3cm in size
- Pelvis is most common site
- Most likely to demonstrate increased activity on bone scan (25-30% show mild increased uptake vs osteoblastic metastasis or sclerosing osteosarcoma that show intense uptake)
- On pathology—osteoblastic met and sclerosing osteosarcoma show entrapped host lamellar bone

# Osteoma

- Rare, slow growing benign tumor or hamartoma composed of mature osseous tissue (compact lamellar bone)
- Protruding mass of dense periosteal intramembranous bone on surface of host bone
- Abnormally dense but normal bone formed in the periosteum
- **Distribution:**
  - Cranium, sinuses and mandible are most common
  - Long bones—rare





age: 30-50  
M = F

# Osteoma

## ■ Clinical:

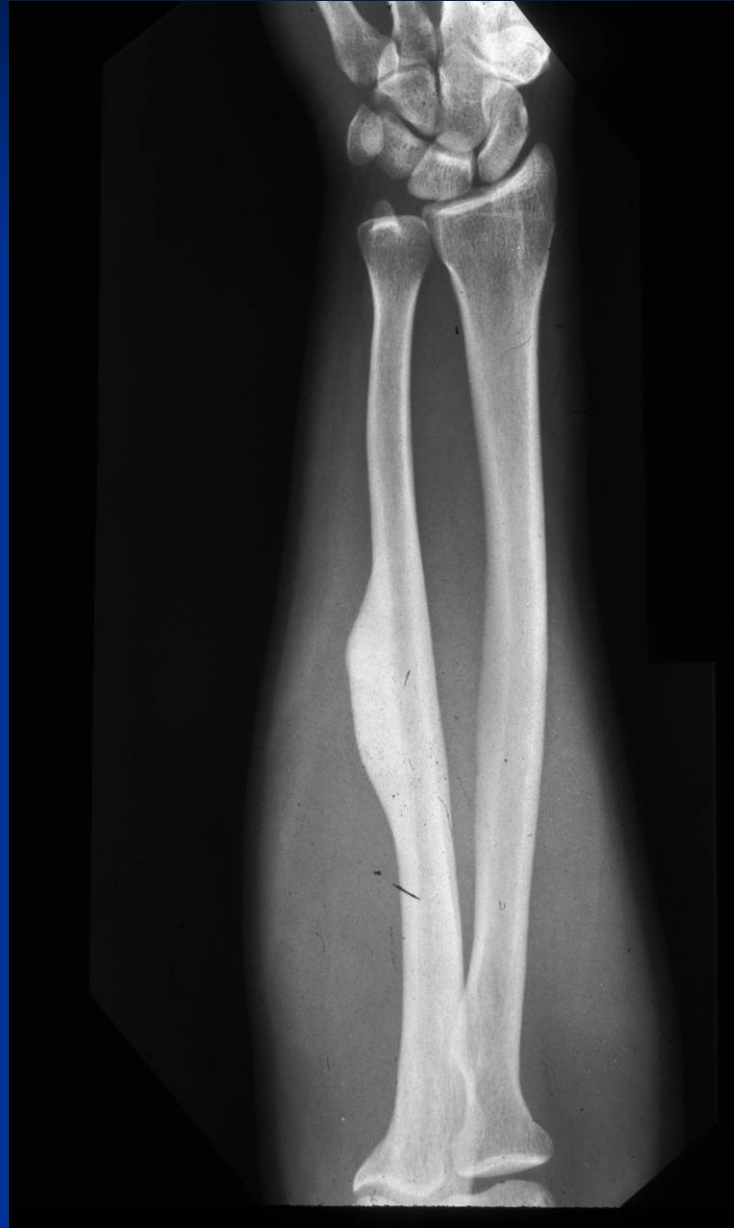- 4<sup>th</sup> to 5<sup>th</sup> decades
- Usually asymptomatic
- Sinus lesions may lead to sinusitis or can grow into cranial vault (found in .42% of sinus radiographs)
- Orbital lesions—exophthalmos, diplopia, displacement of globe

# Osteoma

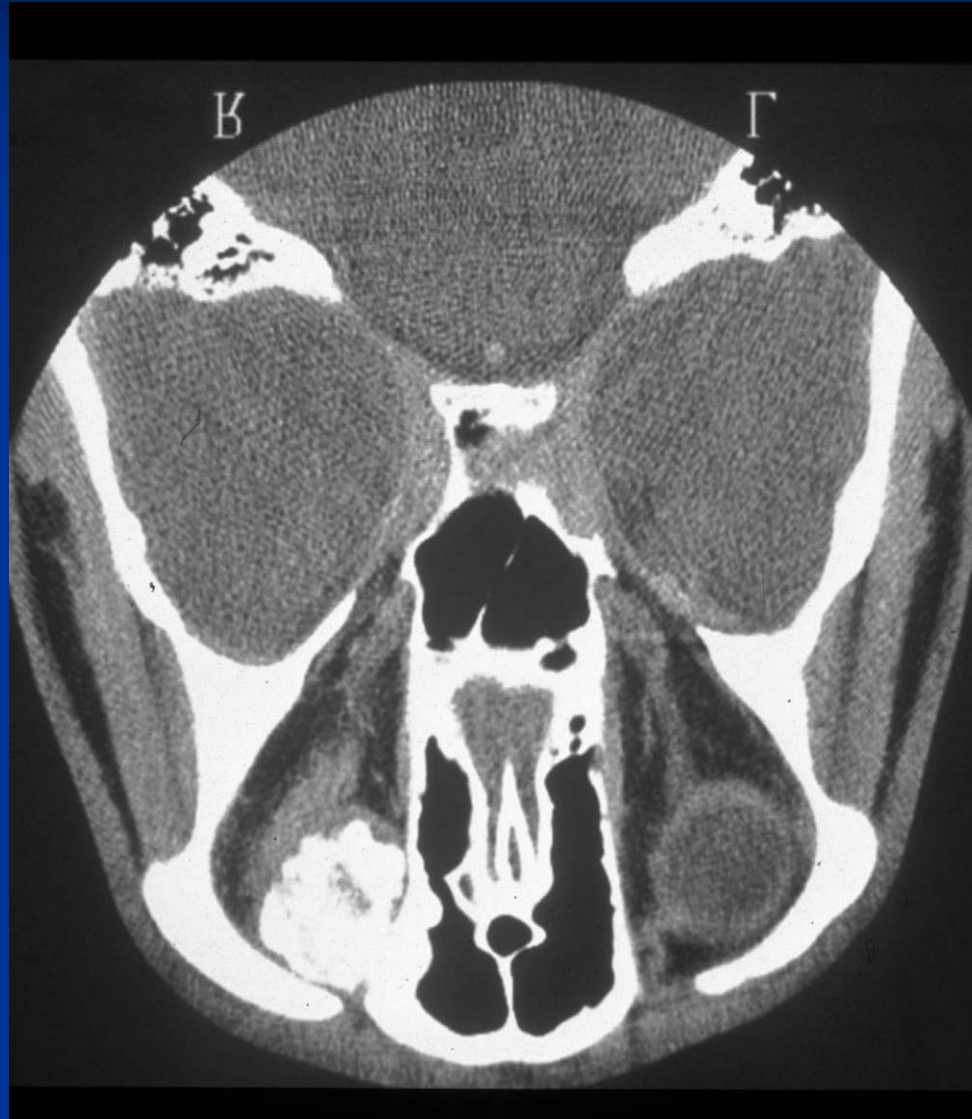## ■ Radiology:

- XR: Sharply defined, smooth, homogeneous bone protruding from the surface of a bone
- Usually remain unchanged on serial studies
- Usually diagnosed incidentally on radiographs
- Most common sites: Frontoethmoid sinus region (75%); Sphenoid: 1-4%

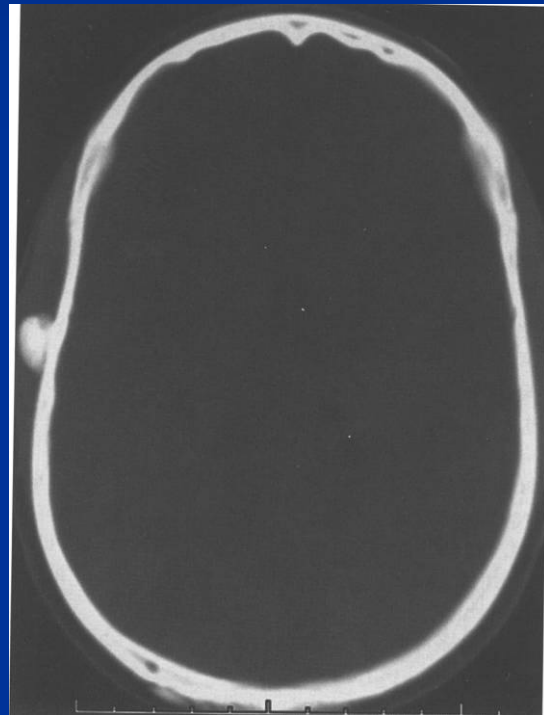
# Osteoma

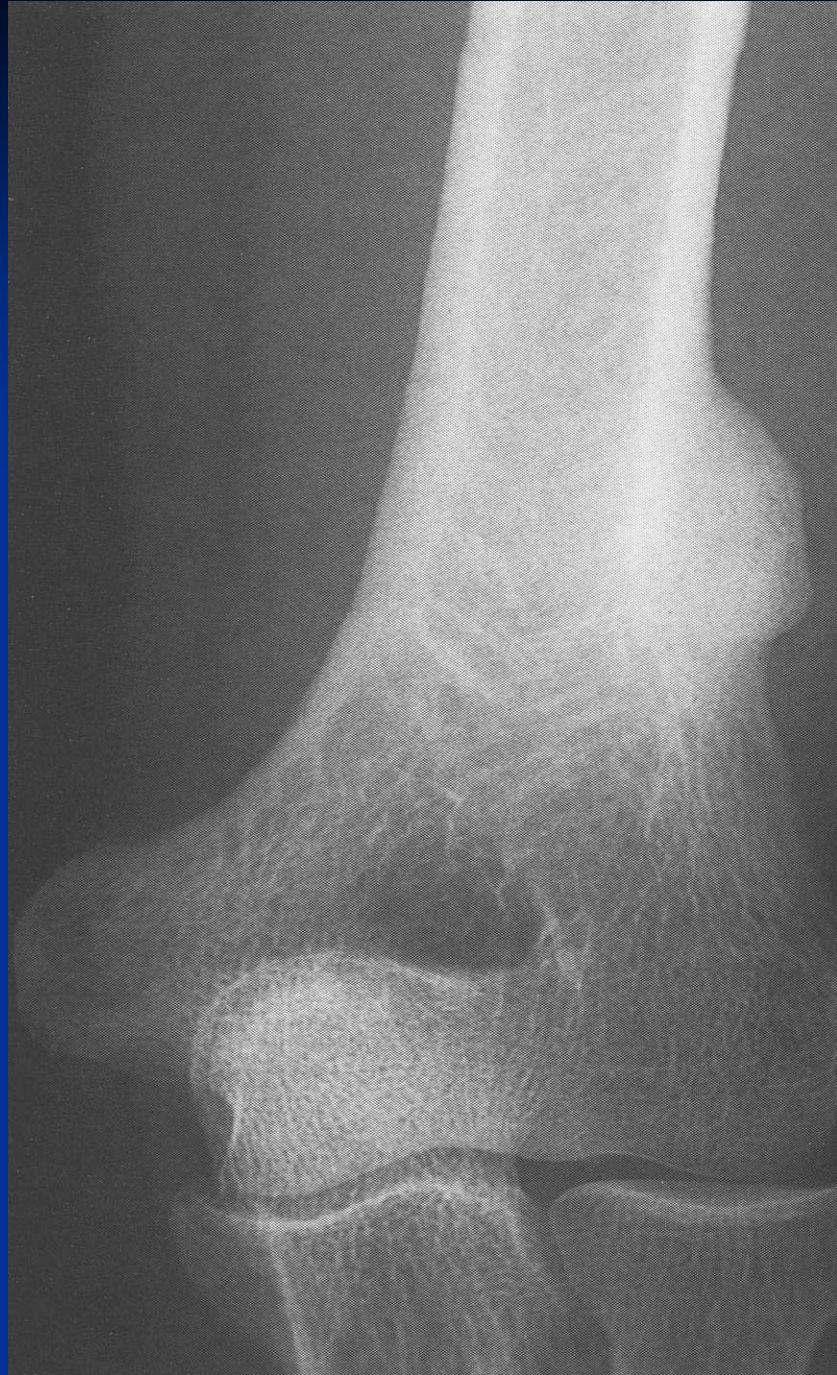

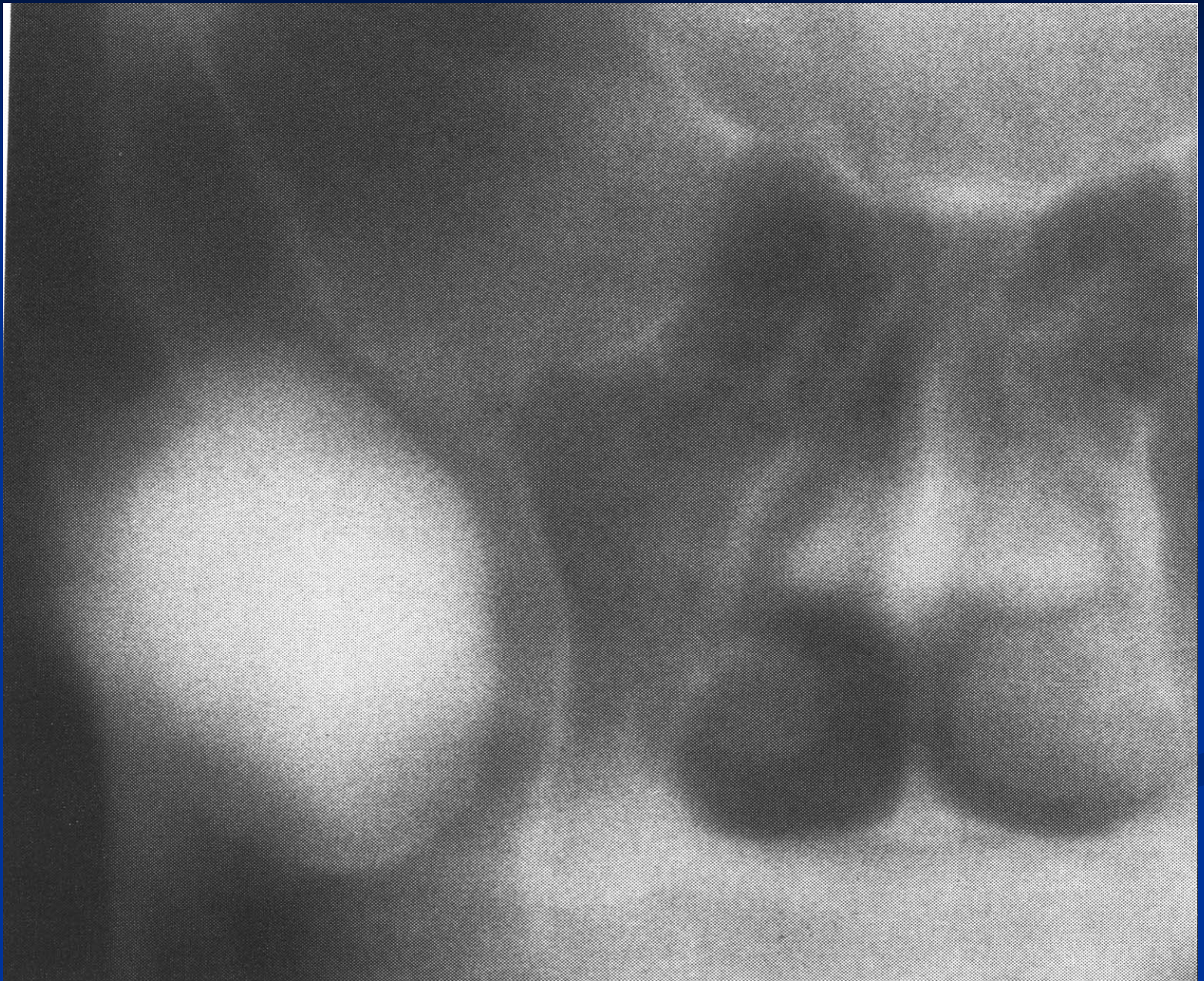
# Osteoma



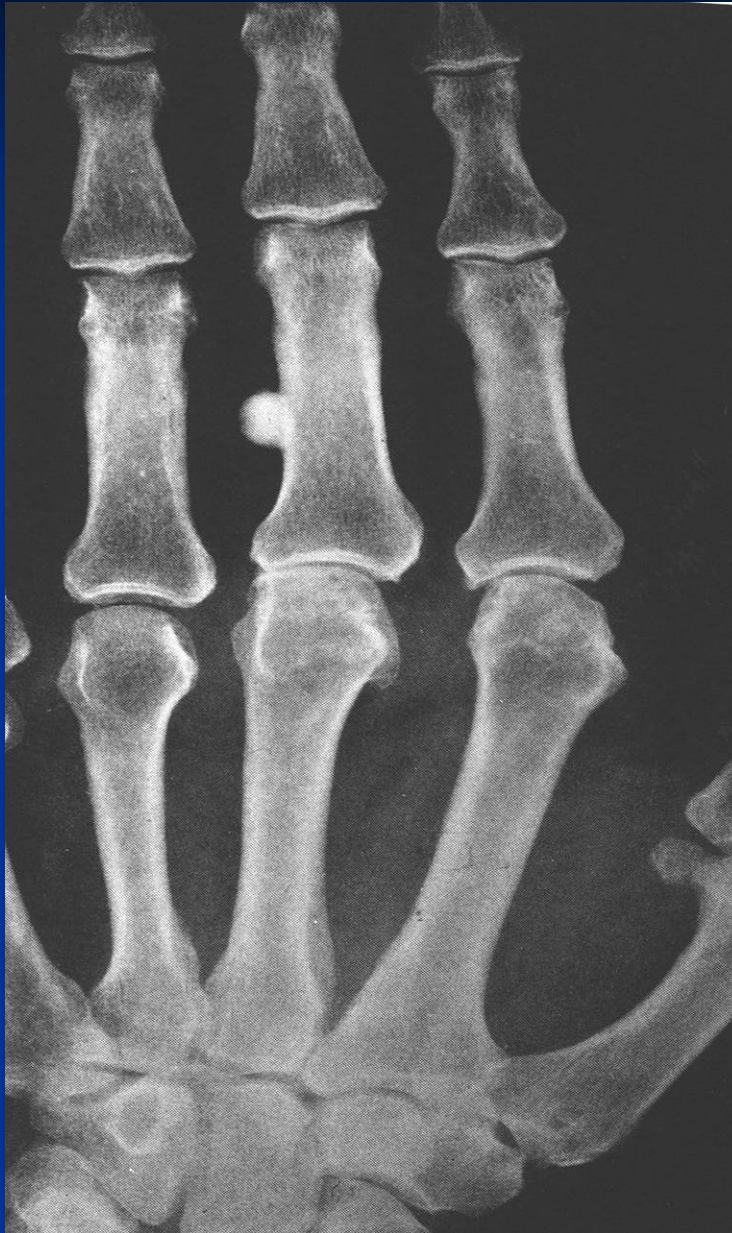# Osteoma of Calvarium









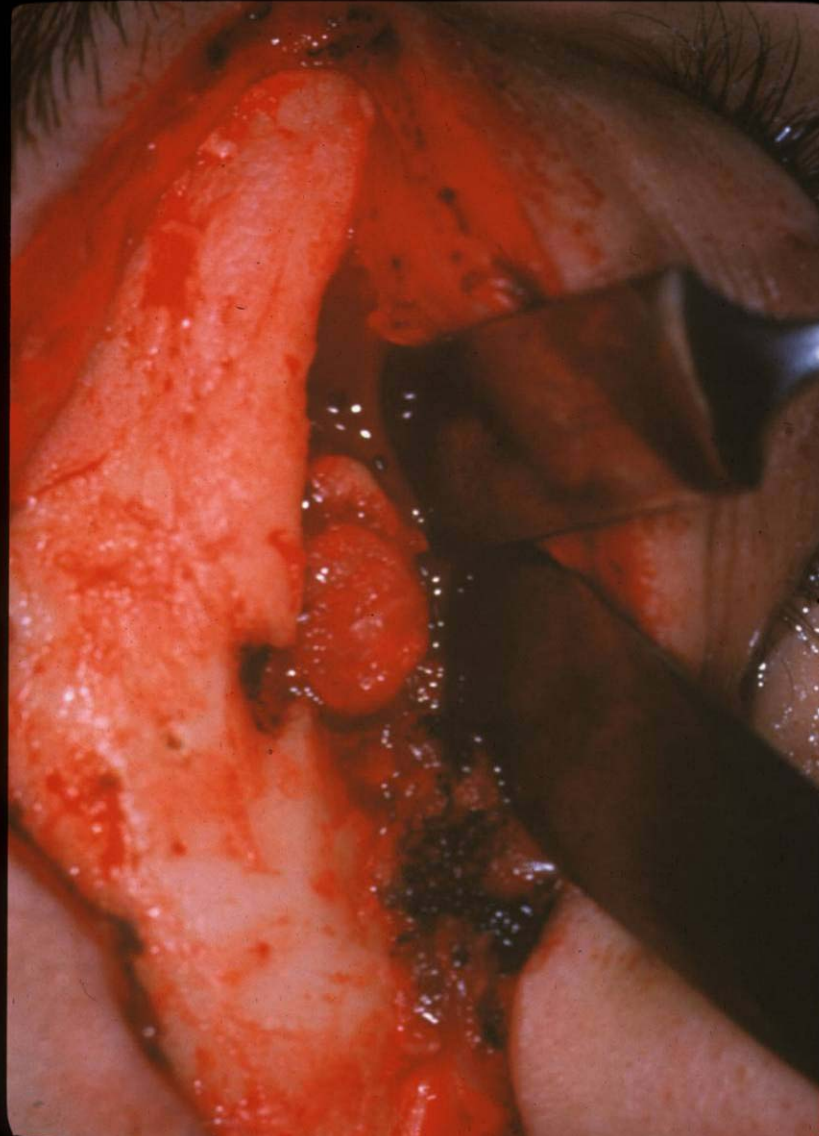


# Osteoma

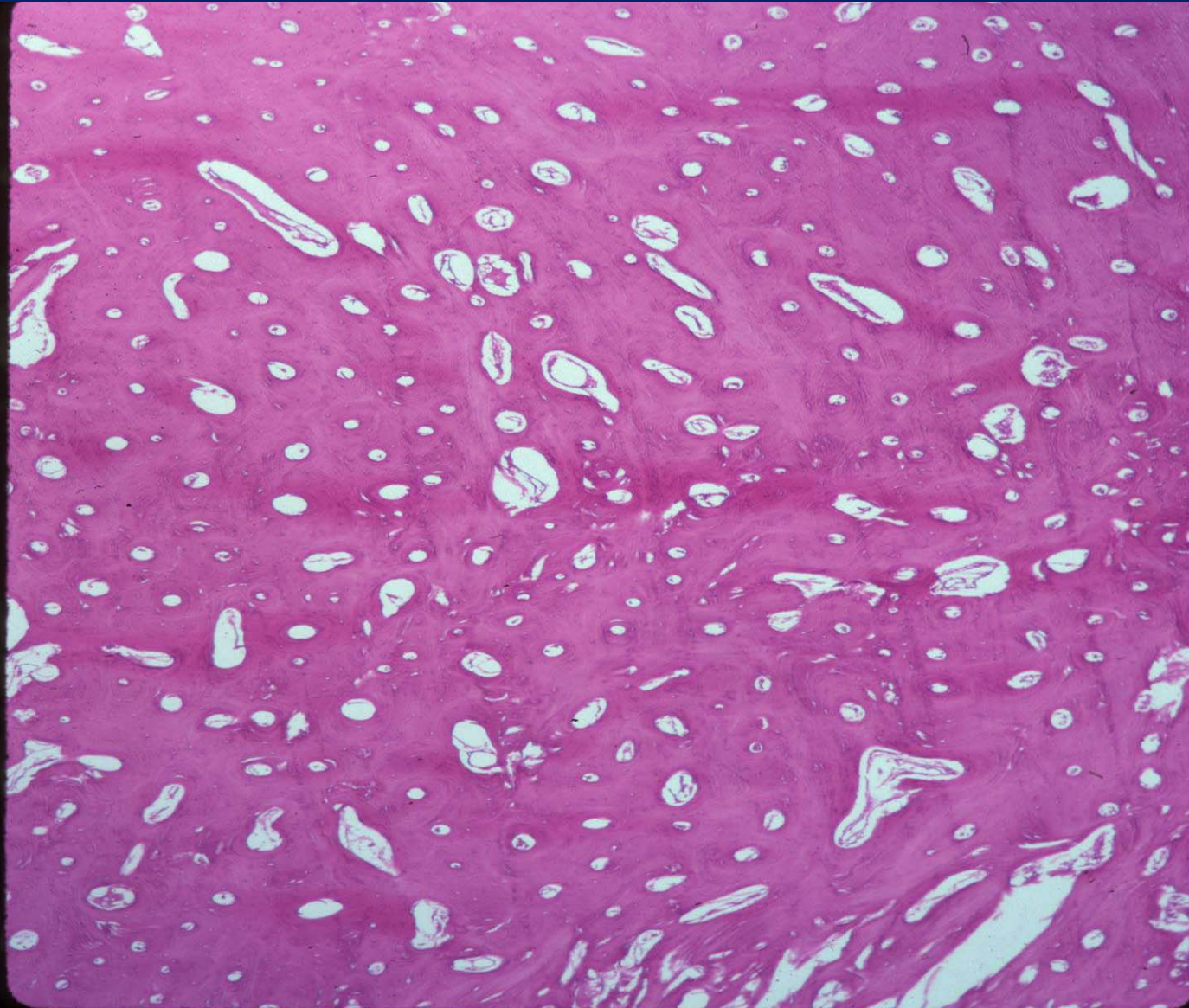
## ■ Pathology:

- Nodules of dense, mature, lamellar (cortical) bone surrounding Haversian Canals
- The bone is very orderly and mature
- The bone is organized into lamellae
- The cells are uniform and have small nuclei
- No nuclear pleomorphism
- No Mitoses

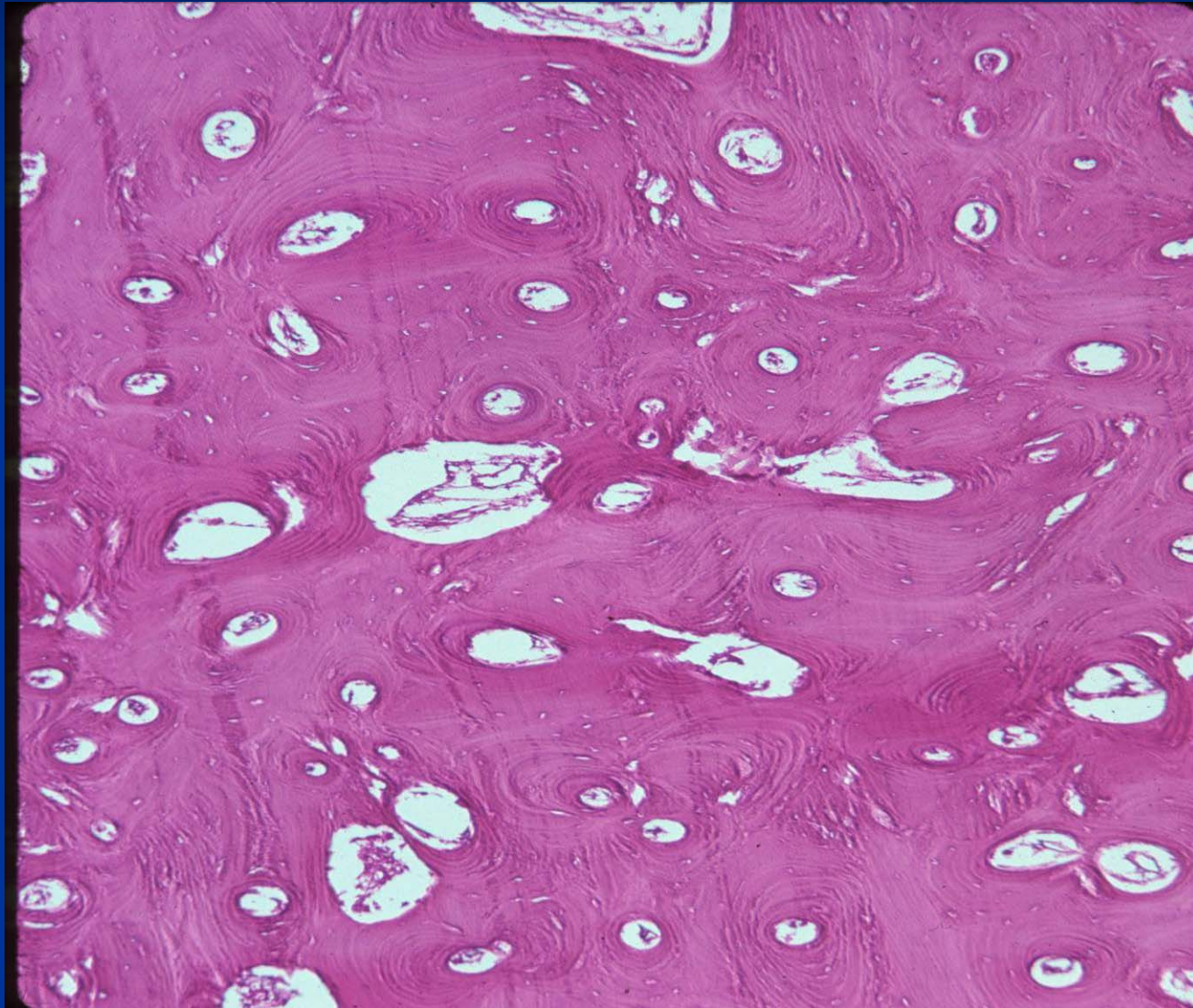
# Osteoma

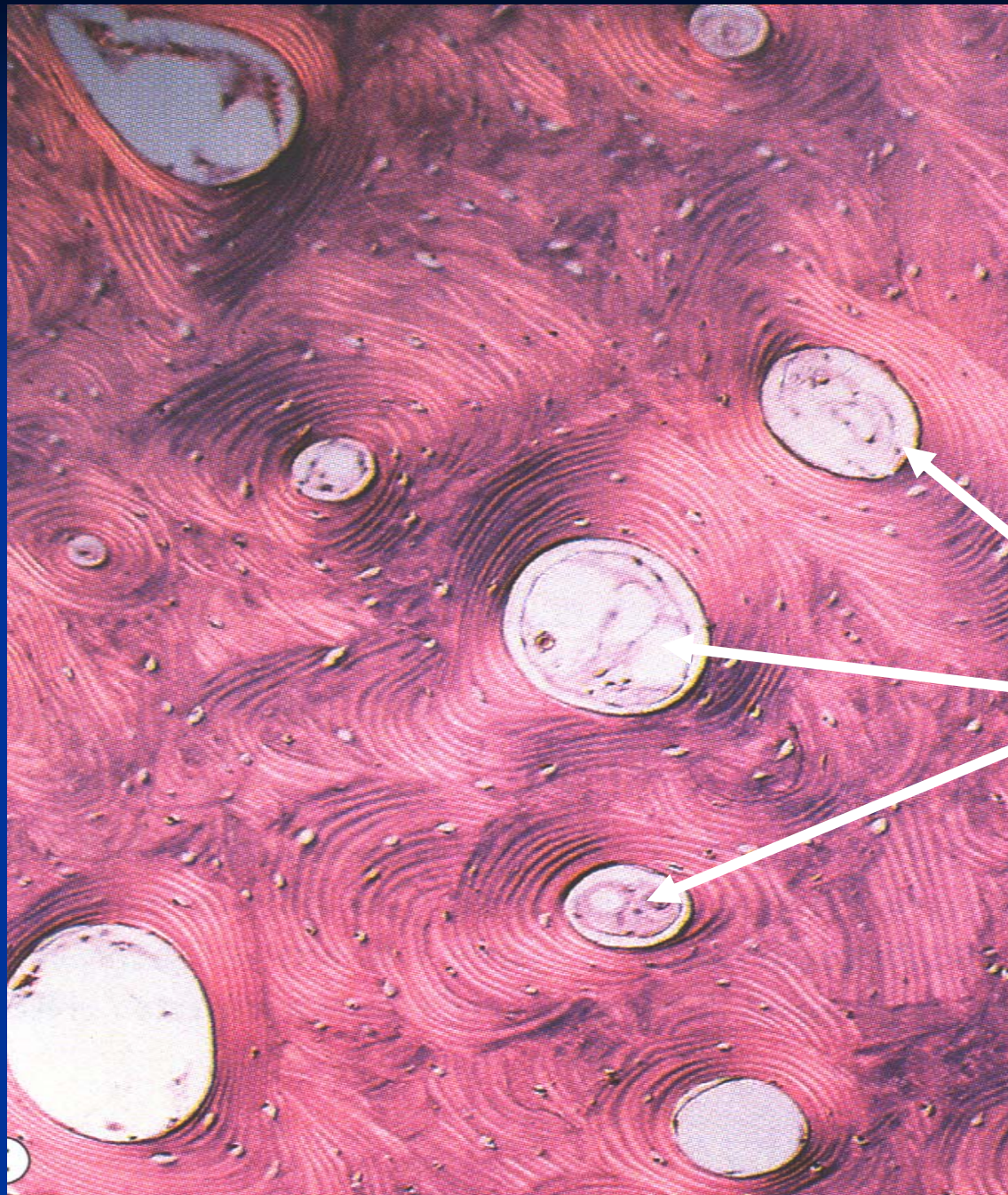


# Osteoma




# Osteoma



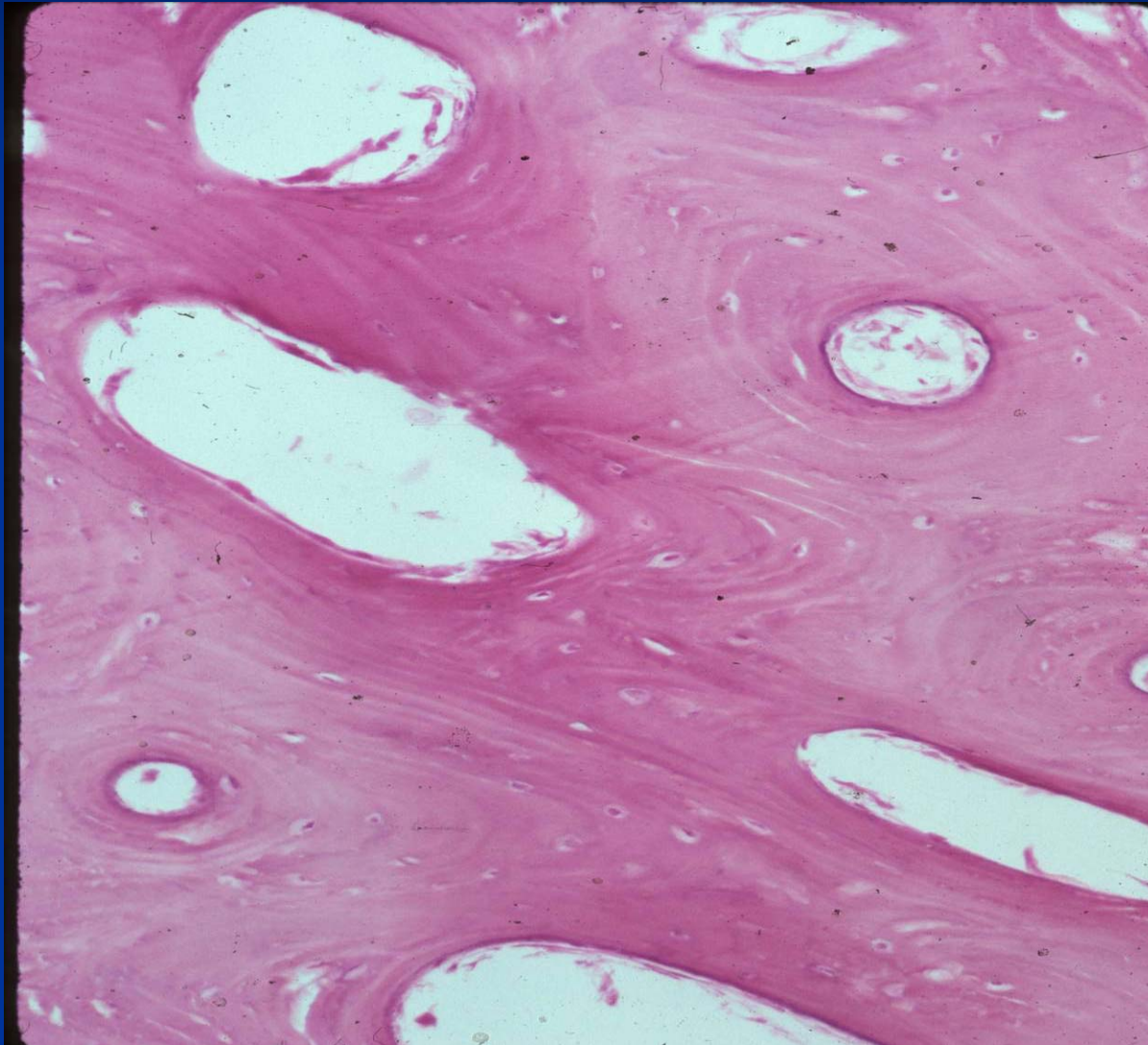


**Haversian  
Canals**

# Polarized Light Demonstrating Lamellar Arrangement



# Osteoma





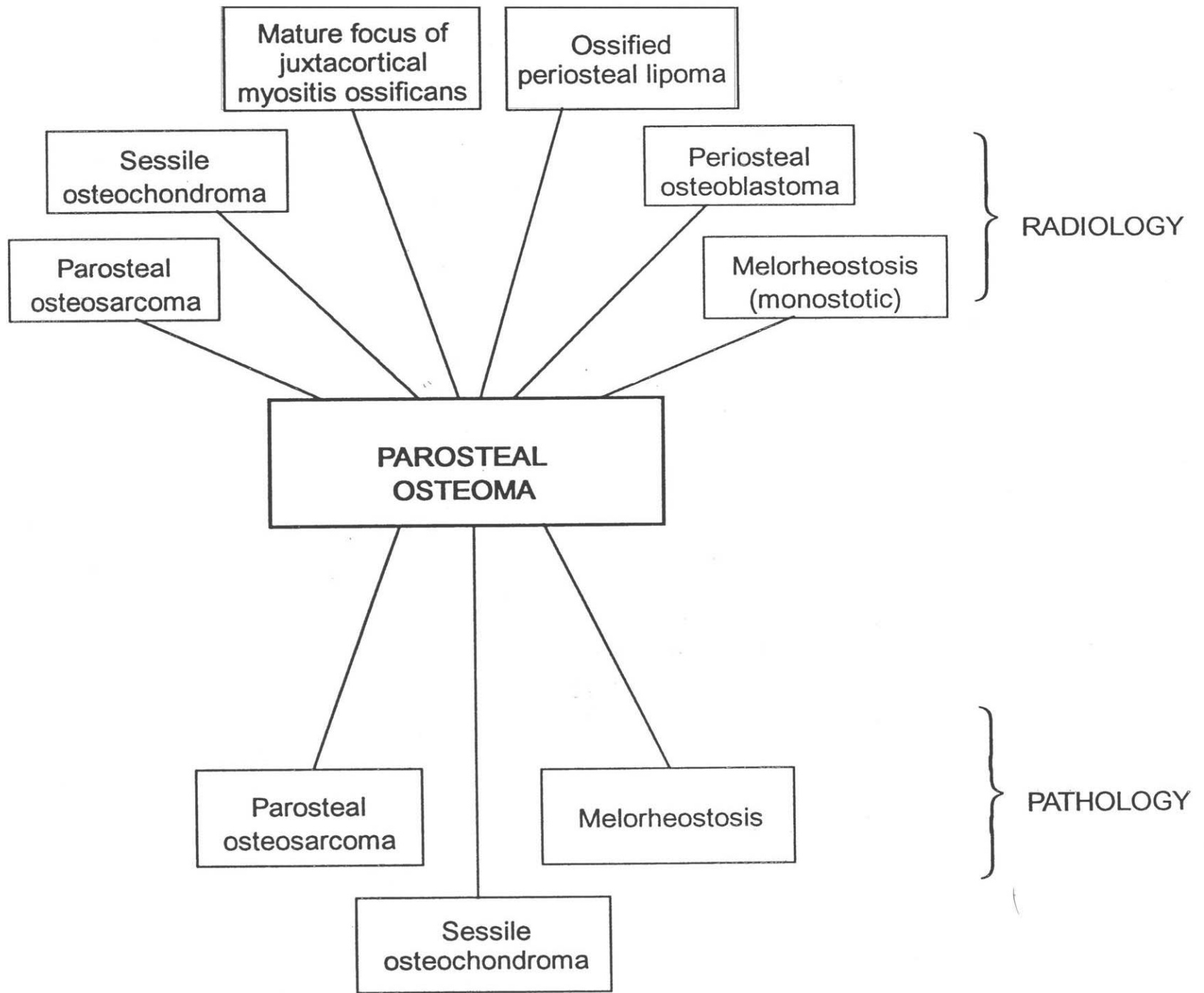
# Osteoma

## ■ Association:

- May be associated with Gardner's Syndrome (especially when multiple)
  - Autosomal Dominant Disease
  - Colonic Polyposis
  - Osteomatosis
  - Soft Tissue Tumors (especially desmoids)
  - Osseous tumors frequently precede the clinical and radiographic appearance of intestinal polyposis
  - Recommend colonoscopy because of risk of malignant transformation of polyps

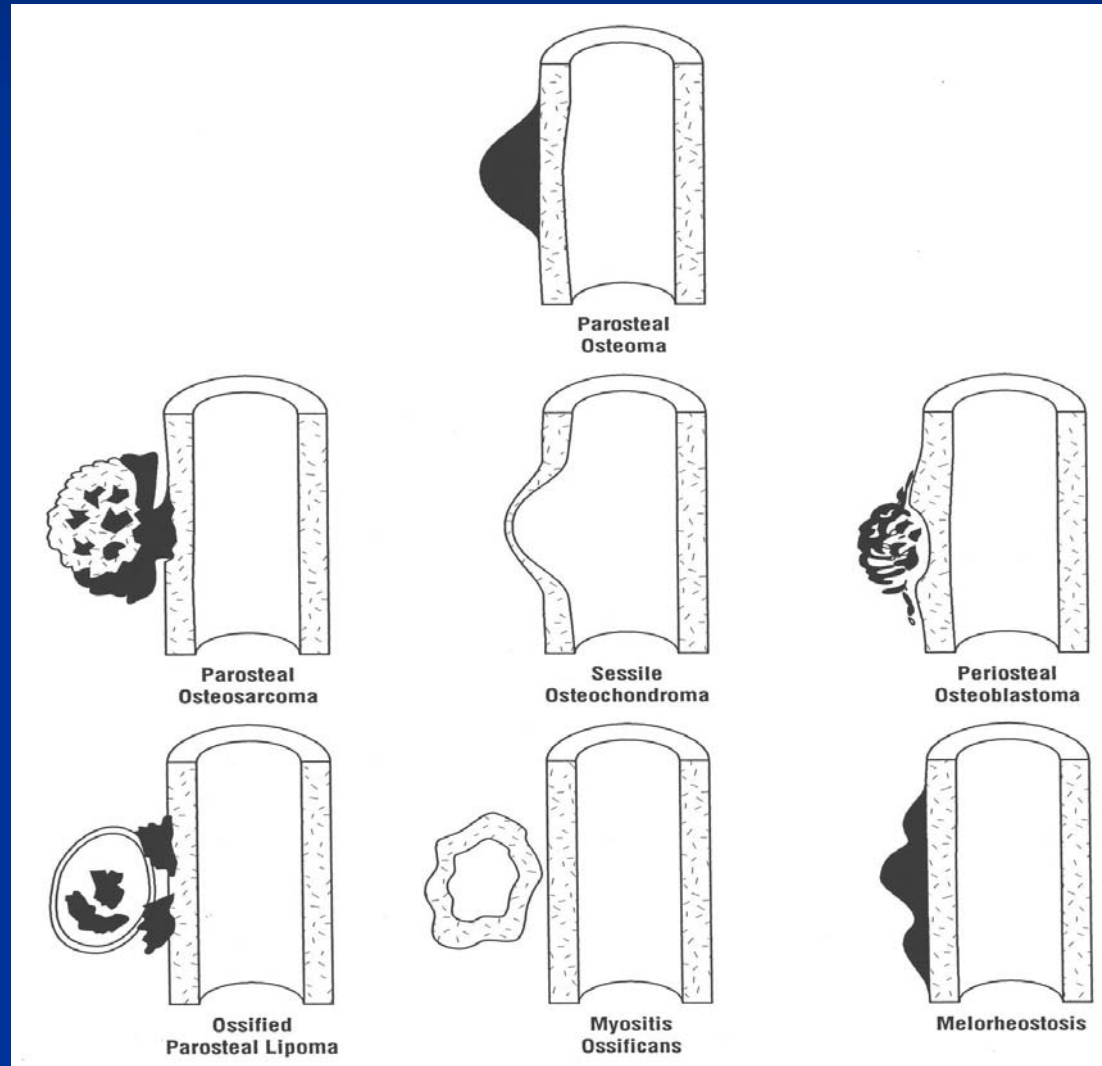
# Differential Diagnosis of Osteoma

- The following chart demonstrates the radiological and pathological differential diagnosis of an osteoma



# Differential of an Osteoma

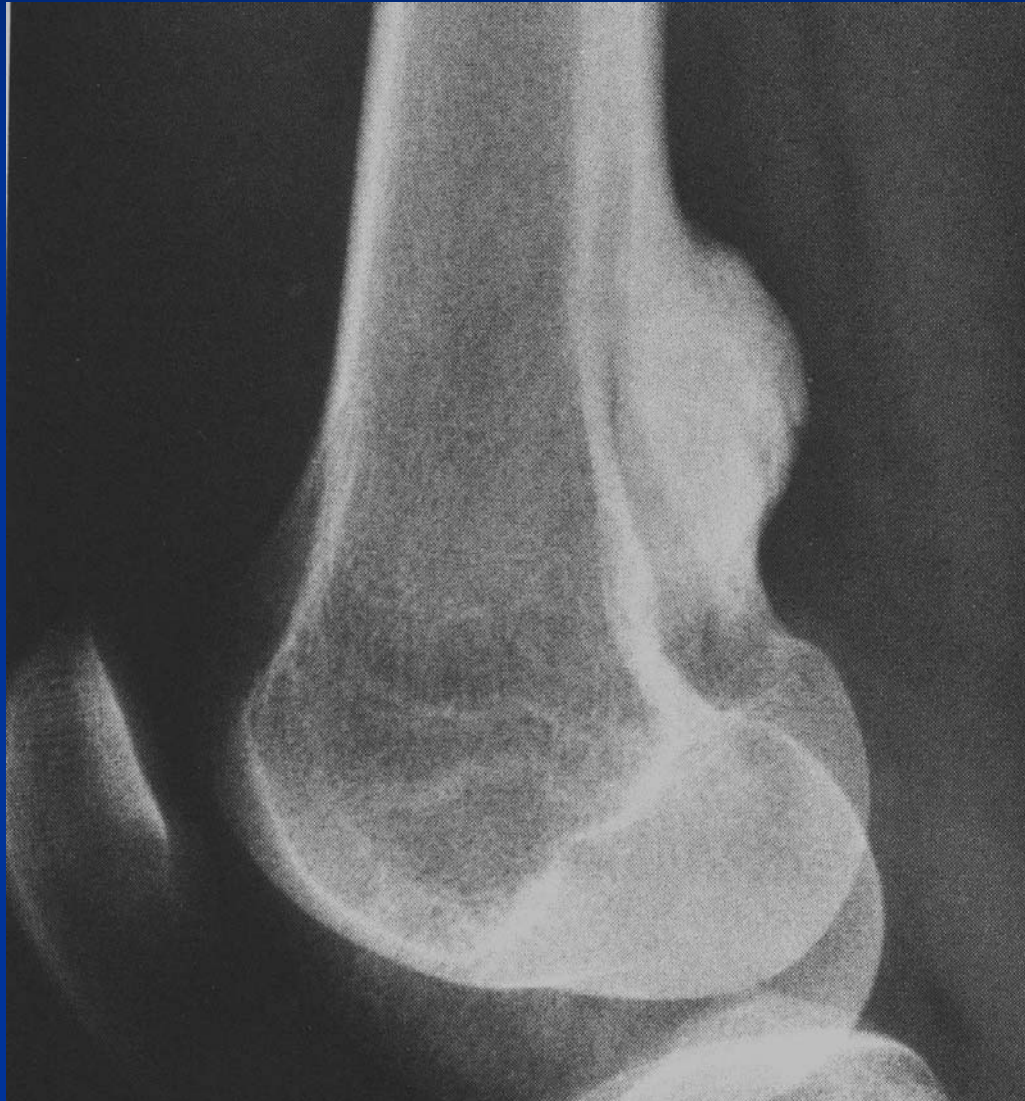## Relationship of Lesions to Cortex of Bone: How to Differentiate



**TABLE 1.** *Differential diagnosis of parosteal osteoma*

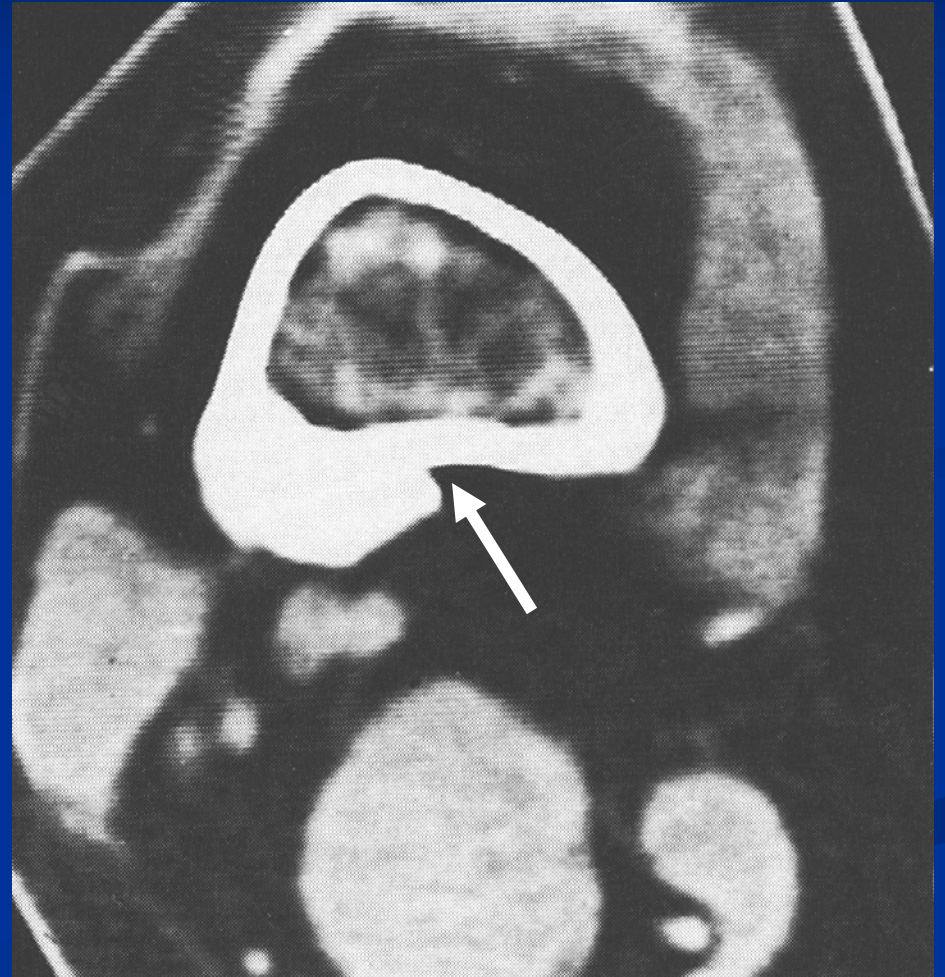
Condition (lesions)	Radiologic features	Pathologic features
Parosteal osteoma	Ivory-like, homogeneously dense sclerotic mass, with sharply demarcated borders, intimately attached to cortex. No cleft between lesion and adjacent cortex.	Mature lamellar bone (either consisting of concentric rings of compact bone, or parallel plates of cancellous bone), lack of active fibrous stroma.
Parosteal osteosarcoma	Ivory-like, frequently lobulated sclerotic mass, homo- or heterogeneous in density with more radiolucent areas at periphery. Incomplete cleft between lesion and adjacent cortex occasionally present.	Streamers of woven to woven-lamellar bone with heavily collagenized stroma. Moderately cellular foci with nuclei exhibiting slight pleomorphism.
Sessile osteochondroma	Cortex of host bone merges without interruption with cortex of lesion and respective cancellous portions of adjacent bone and osteochondroma communicate.	Cartilaginous cap composed of hyaline cartilage arranged similarly to growth plate. Beneath zone of endochondral ossification with vascular invasion and replacement of calcified cartilage by newly formed bone. Intertrabecular spaces may contain fatty or hematopoietic marrow.
Juxtacortical myositis ossificans	Zonal phenomenon: radiolucent area in center of lesion and dense zone of mature ossification at periphery. Frequently thin radiolucent cleft separates ossific mass from adjacent cortex.	Trabecular bone and fibrous marrow. Histologic zonal phenomenon: immature bone in the center with proliferating osteoblasts, fibroblasts, and areas of hemorrhage and necrosis; mature bone at the periphery.
Periosteal osteoblastoma	Round or ovoid heterogeneous in density mass attached to cortex.	Trabeculae of woven bone, numerous dilated capillaries, exuberant in number osteoblasts, osteoclasts, and fibroblasts.
Ossified parosteal (periosteal) lipoma	Lobulated mass containing irregular ossifications and radiolucent area of fat. Hyperostosis of adjacent cortex occasionally present.	Formation of mature bone within adipose tissue. Occasionally foci of necrosis and calcifications.
Melorheostosis (monostotic)	Cortical thickening resembling wax dripping down one side of a candle. Commonly extends to the joint.	Thickened cortical bone containing irregularly arranged Haversian canals surrounded by cellular fibrous tissue. Osteoblastic activity usually present.

# Parosteal Osteosarcoma

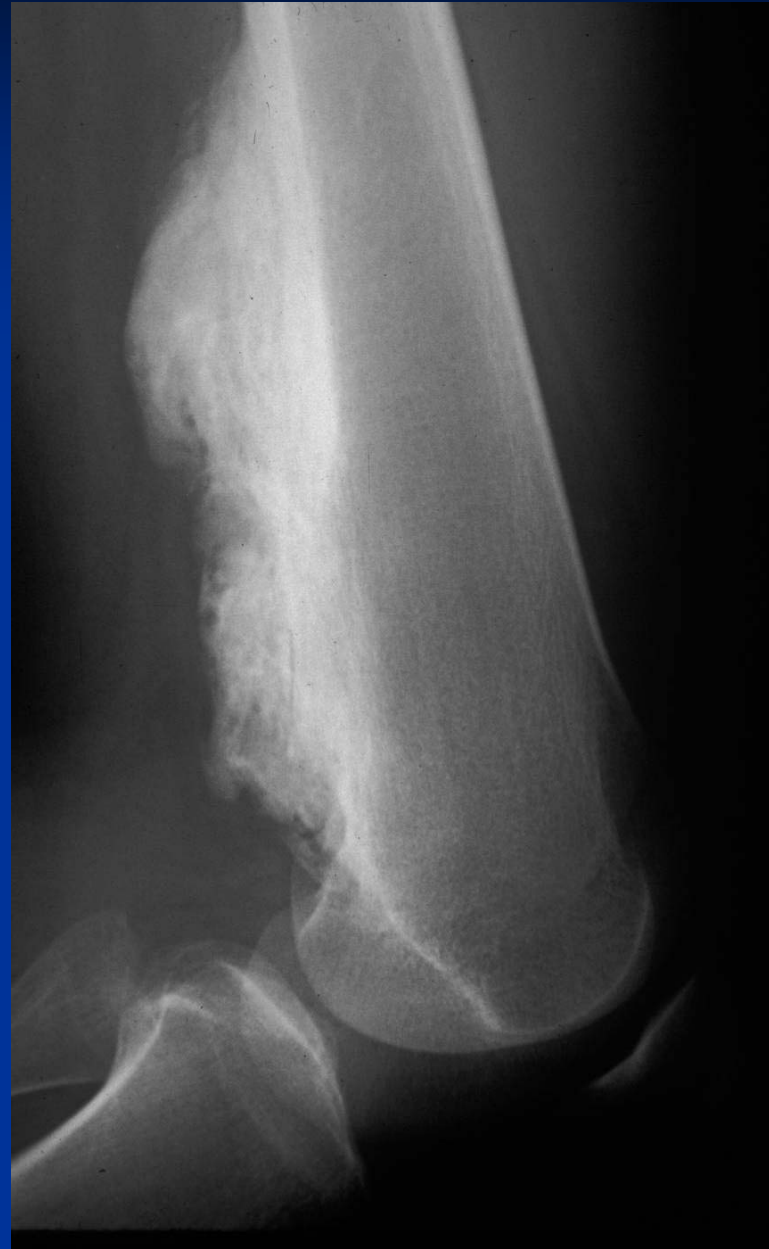

# CT Scan of Parosteal Osteosarcoma

- A cleft (arrow) can often be identified at the periphery of the tumor between the tumor and underlying cortex
- There is no cleft associated with an osteoma

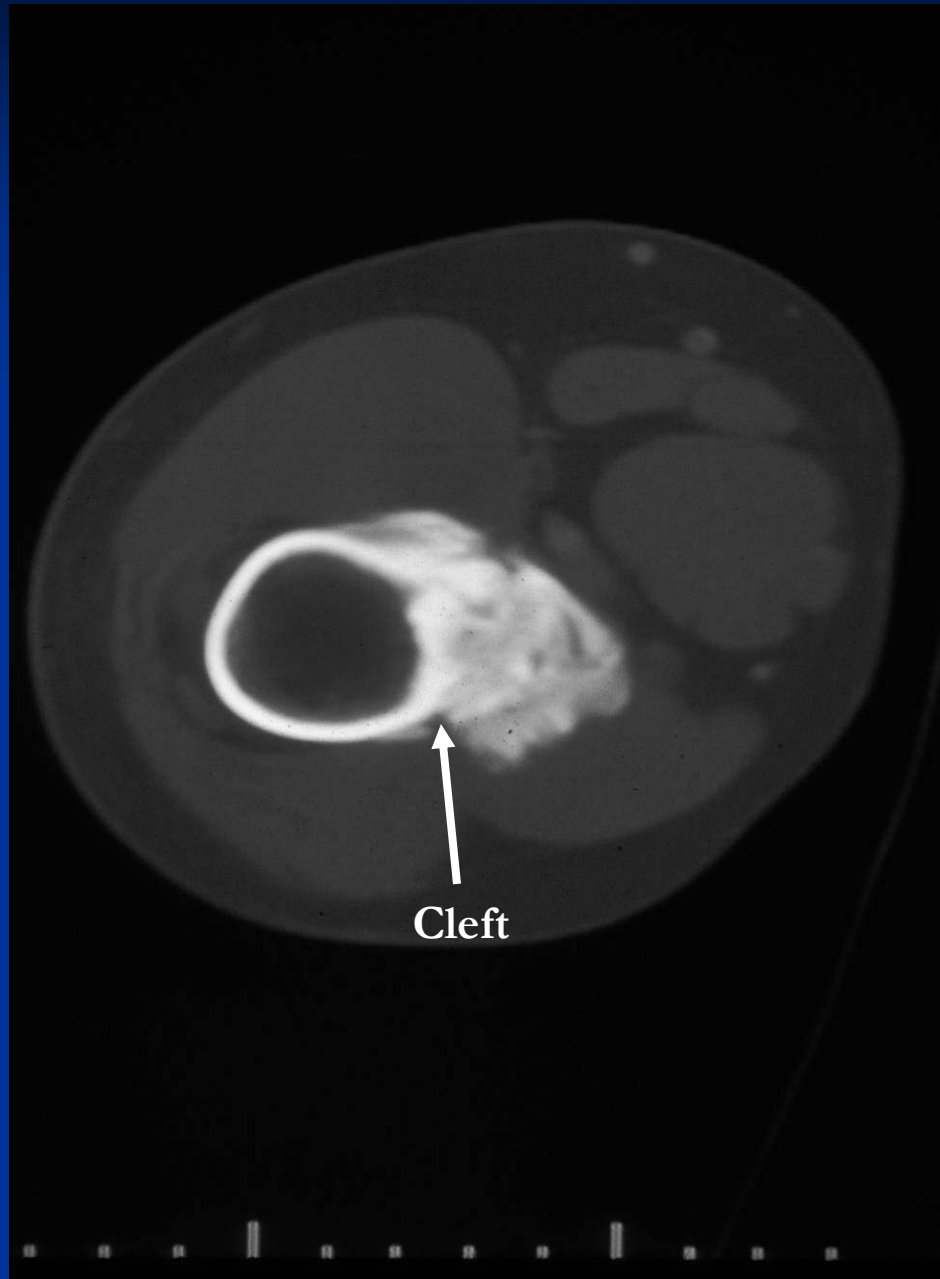


# Parosteal Osteosarcoma



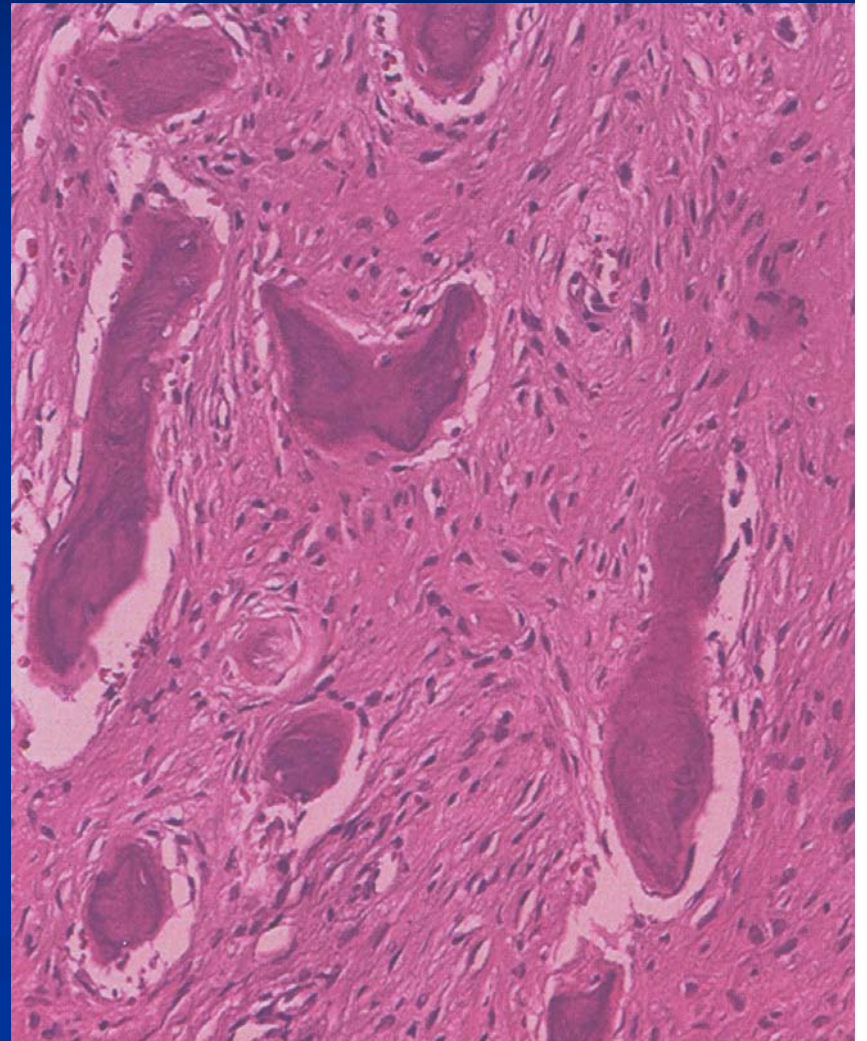


# CT Scan Parosteal Osteosarcoma



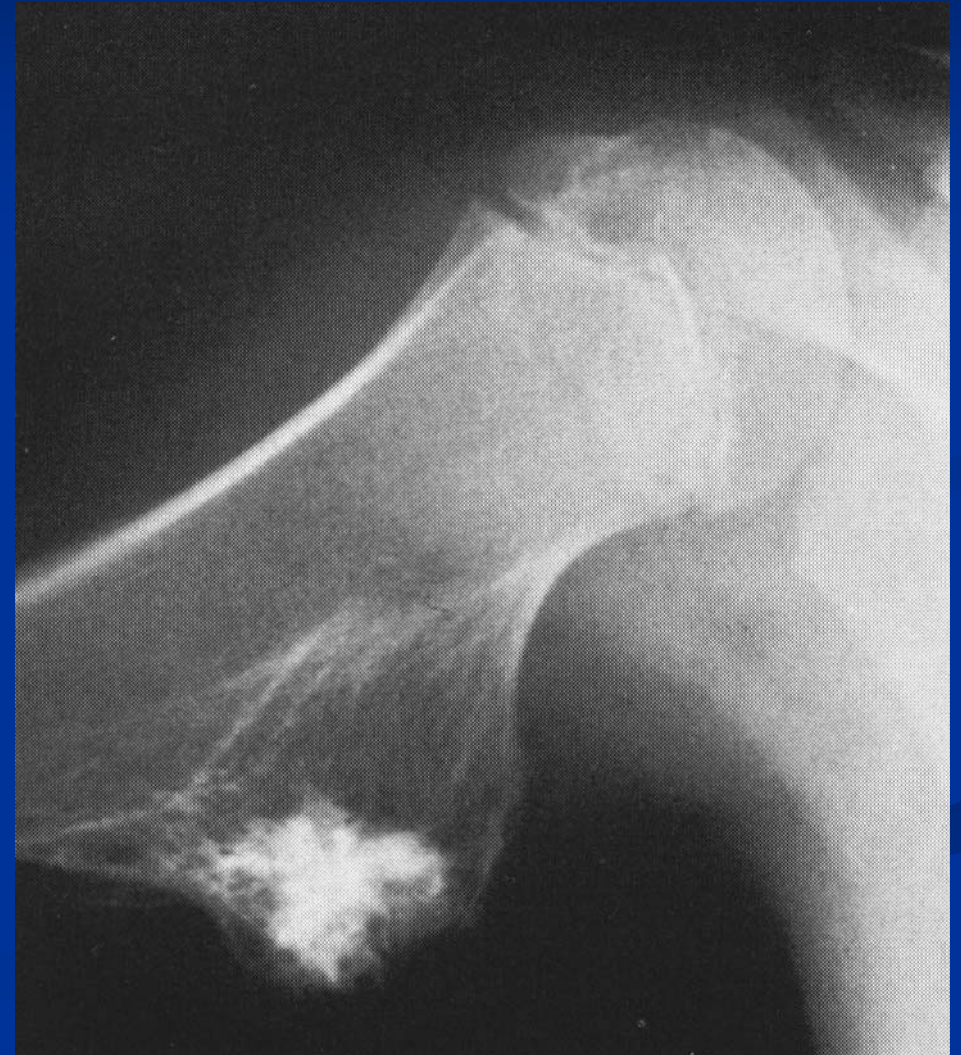# Pathology of Parosteal Osteosarcoma

- Low grade malignant fibroblastic stroma admixed with islands of immature woven bone
- Minimal nuclear atypia
- Minimal cellular pleomorphism
- Few mitotic figures



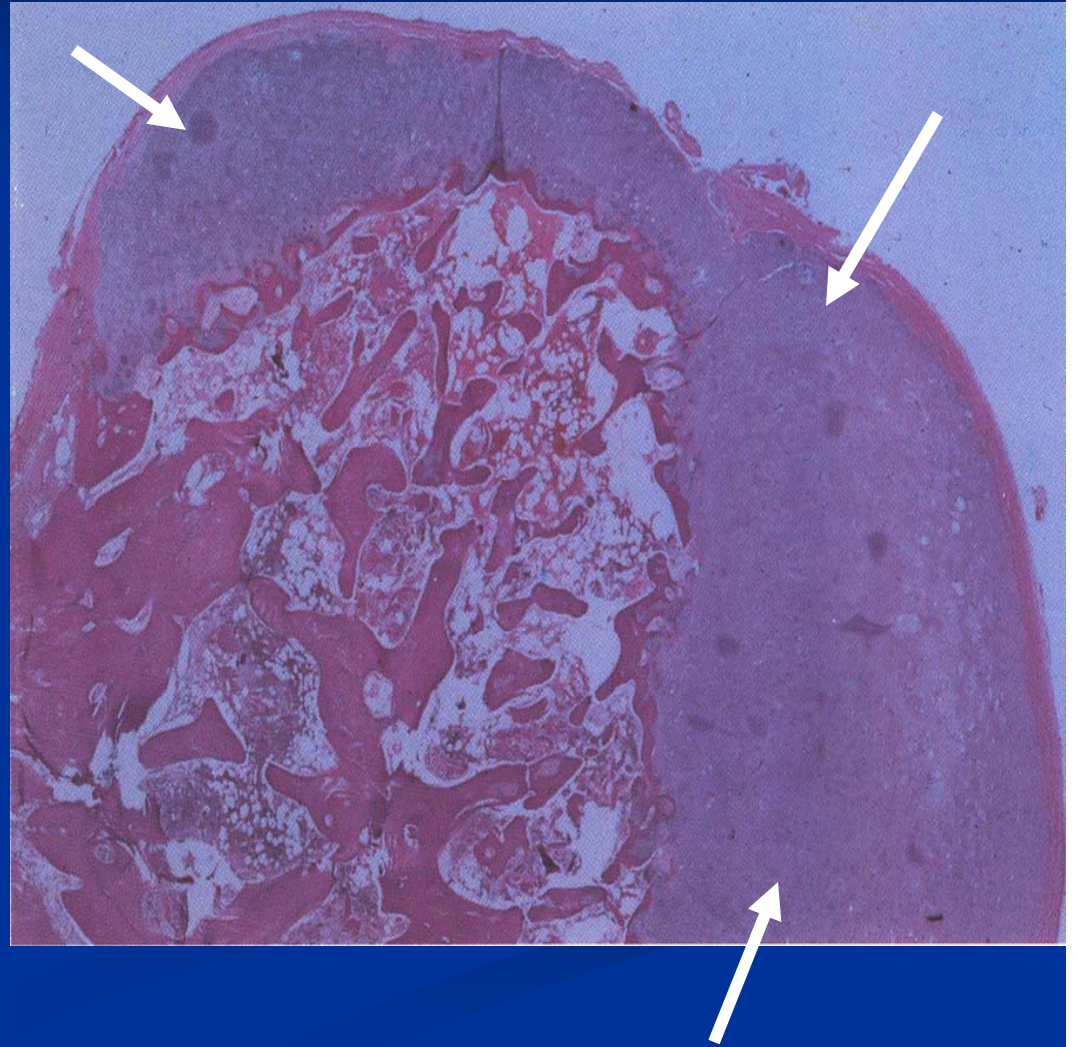
# Osteochondroma

- An osteochondroma is a cartilaginous tumor
- The cap has calcifications in a ring and arc manner
- It grows from a piece of the growth plate that branches off and grows outward instead of longitudinally
- Radiographically there is corticomedullary continuity: the cortex and medullary cavity of the osteochondroma is continuous with that of the underlying bone
- Notice that there is no cortex between the osteochondroma and underlying bone; the medullary cavities are continuous
- The cortex is usually intact with a parosteal osteosarcoma unless it has grown through the cortex and invaded the medullary canal (this would indicate a more aggressive parosteal osteosarcoma). The cortex is also intact with an osteoma.



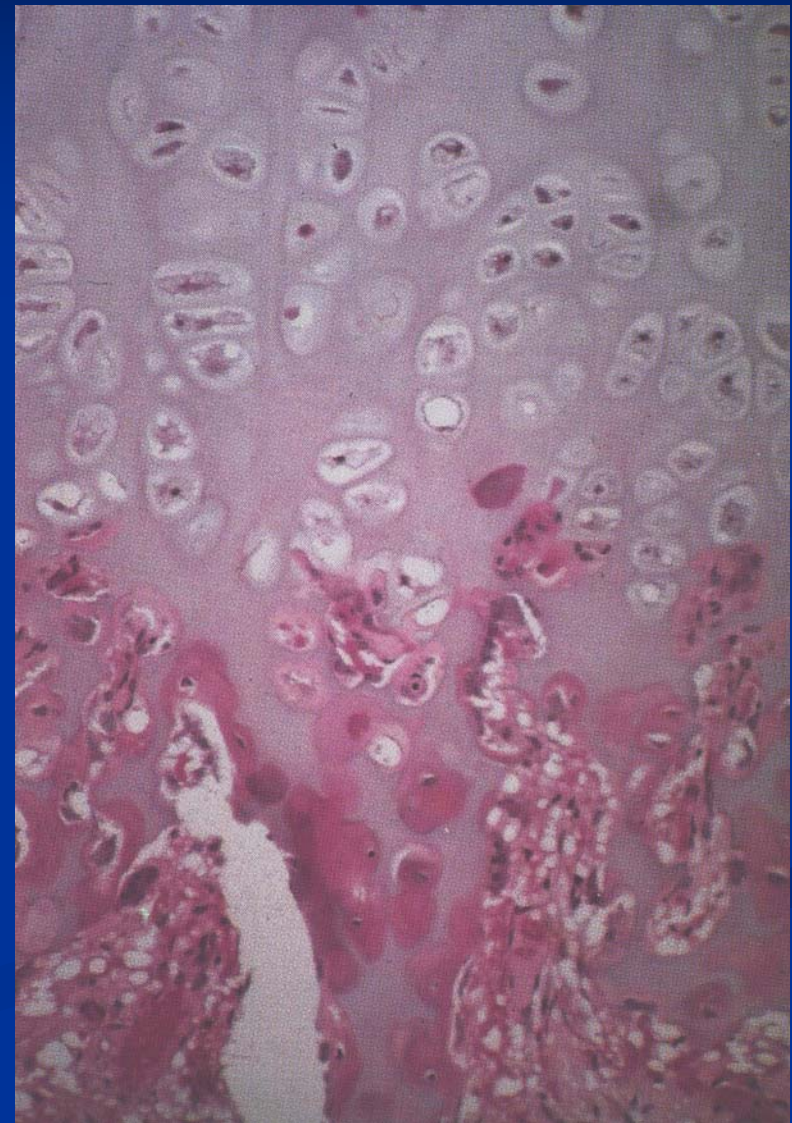# Pathology of an Osteochondroma

- There is a **Cartilaginous Cap** (arrow) with underlying trabecular bone (medullary cavity)

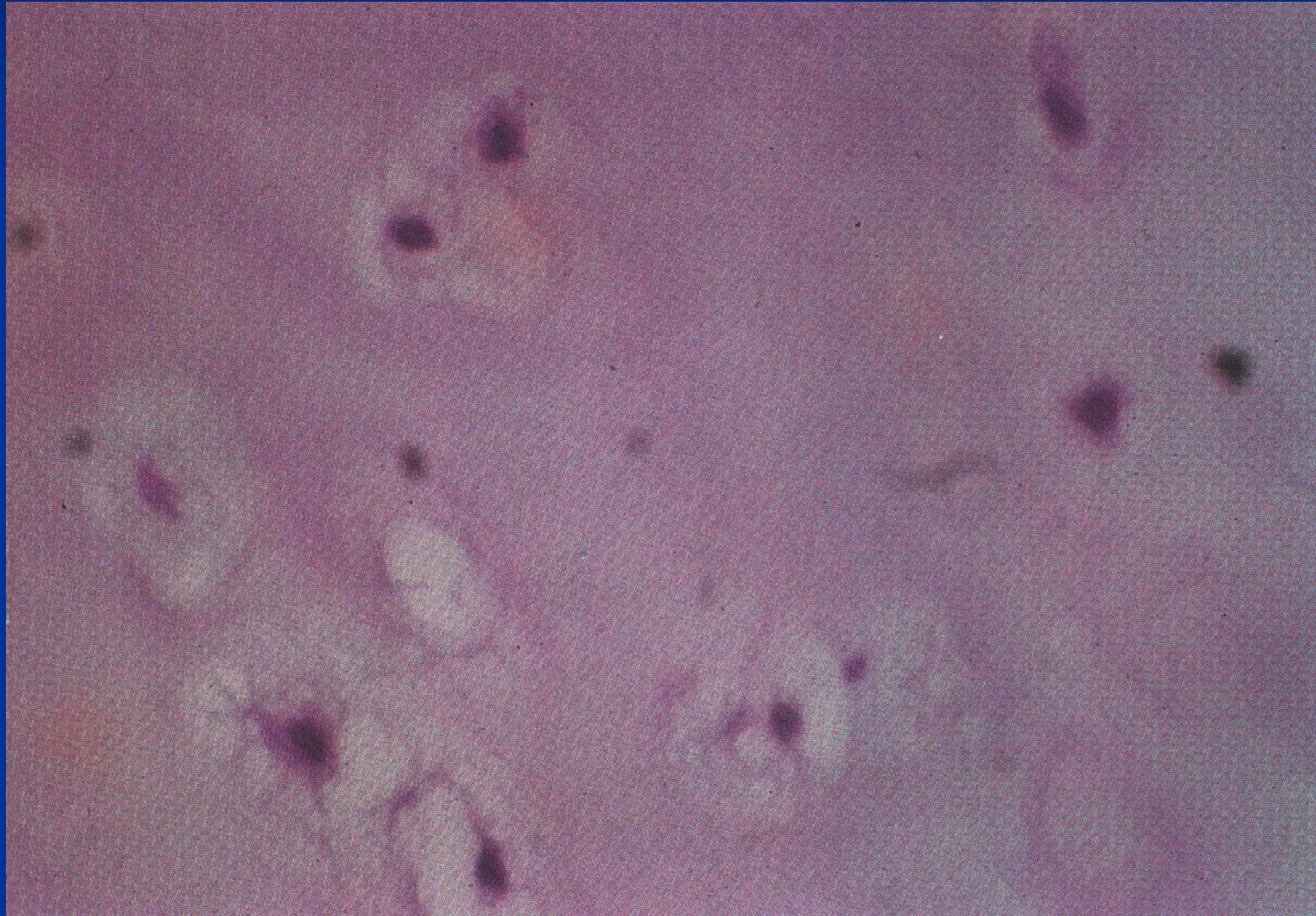


# Pathology of Osteochondroma

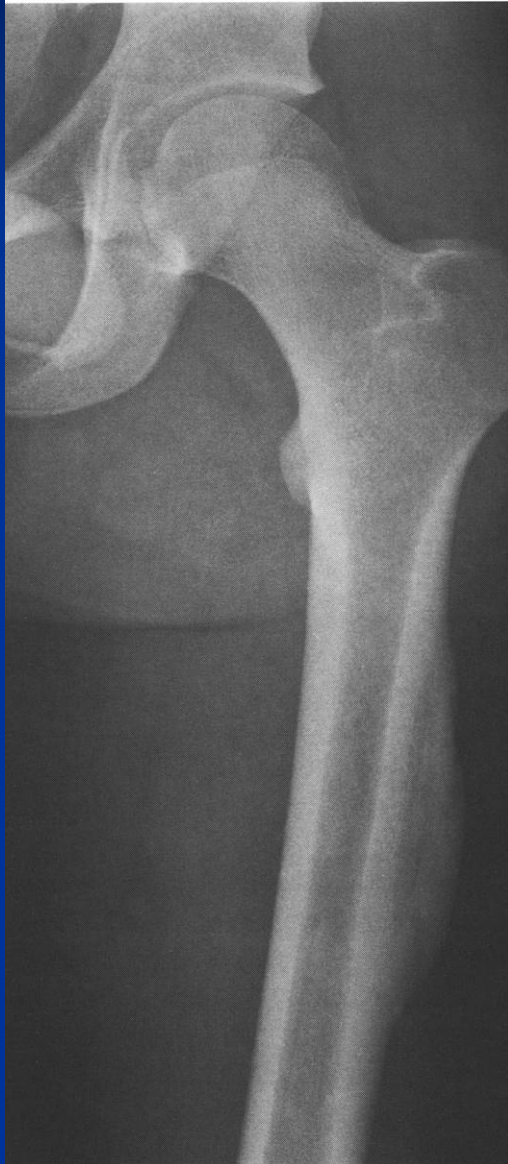- The cartilaginous cap of an osteochondroma is arranged similar to a normal growth plate.
- It is arranged into various zones
- As the growth plate grows longitudinally the cartilaginous cells become calcified and turn into bone
- This pathology slide shows the zones of hypertrophy and provisional calcification
- This is an example of endochondral ossification (formation of bone from a cartilaginous precursor)



# Pathology of Benign Cartilage



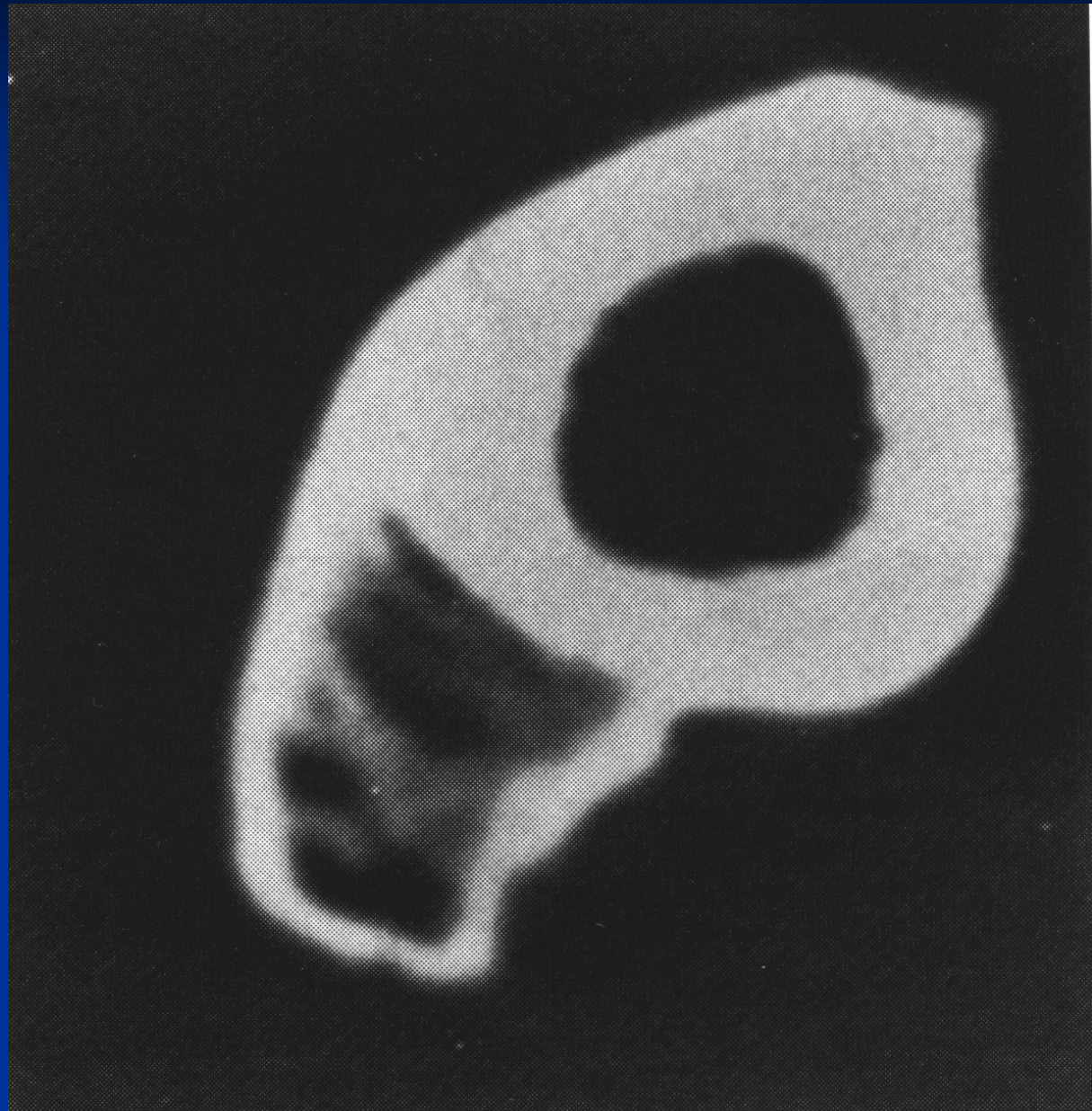
# Myositis Ossificans



# Myositis Ossificans

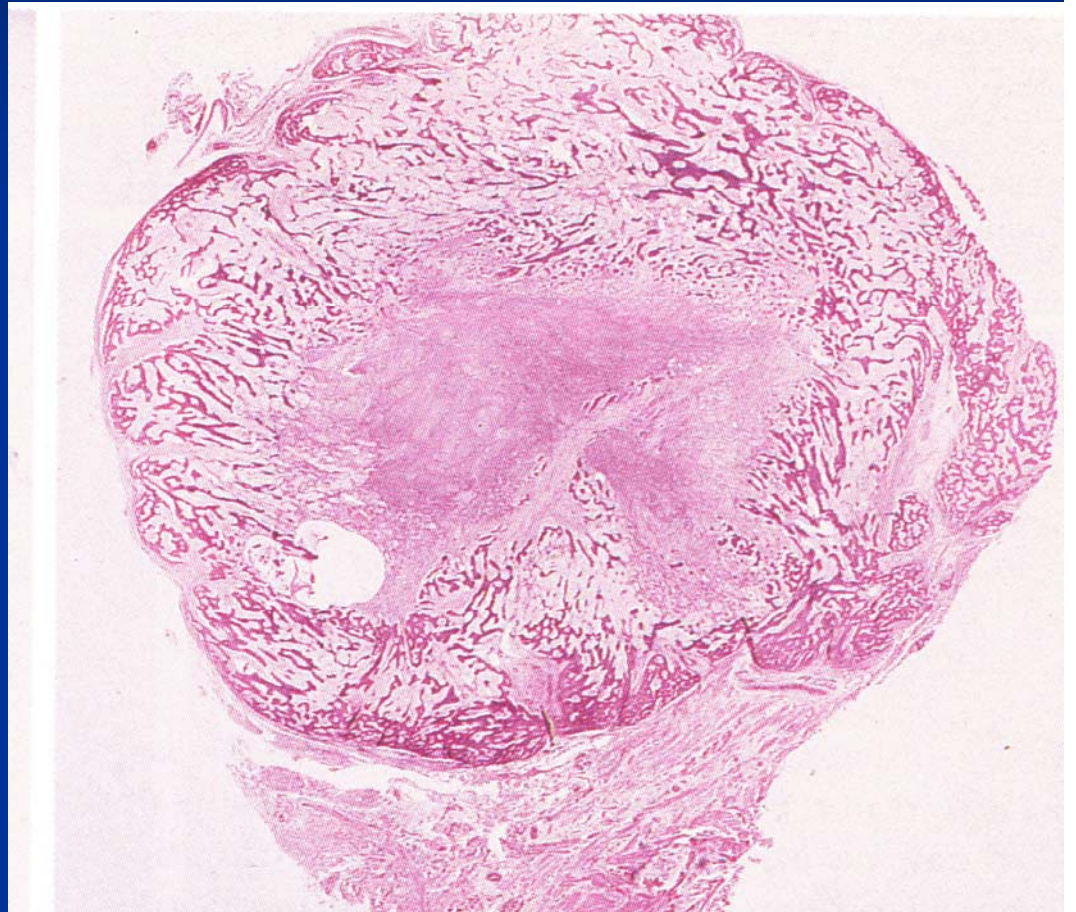
- Myositis ossificans occurs from an injury
- It can form directly in a muscle or form closely applied to the surface of a bone
- Myositis ossificans goes through a maturation phase. Initially it may show minimal ossification and mineralization. Usually after 6-12 weeks, the amount of mineralization increases. As the process matures, a zonal phenomenon occurs. The periphery of the lesion matures and the central portion of the lesion appears to form a medullary canal that contains fat and marrow.



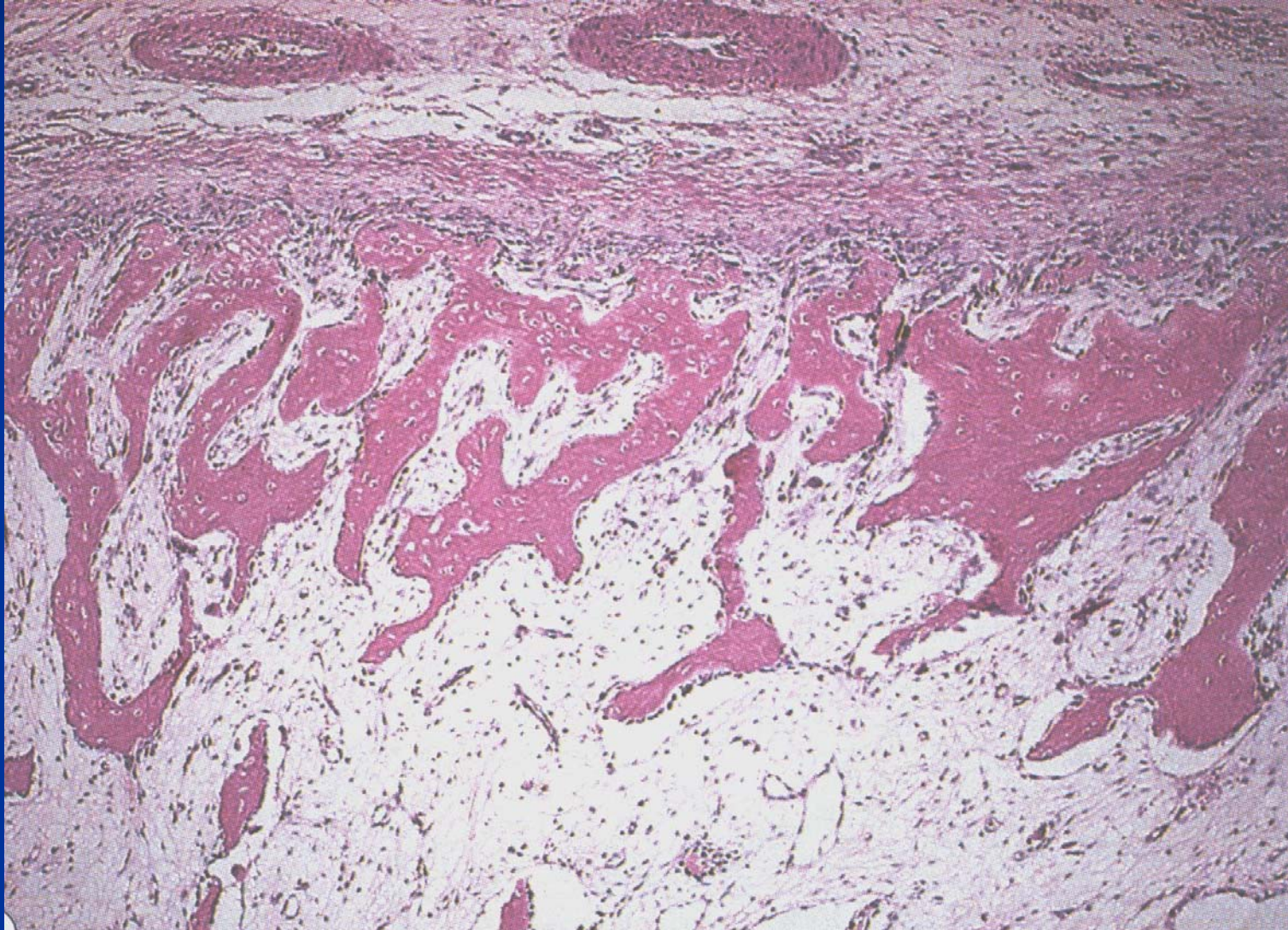


# Myositis Ossificans

- Mature bone at periphery
- Central canal forming

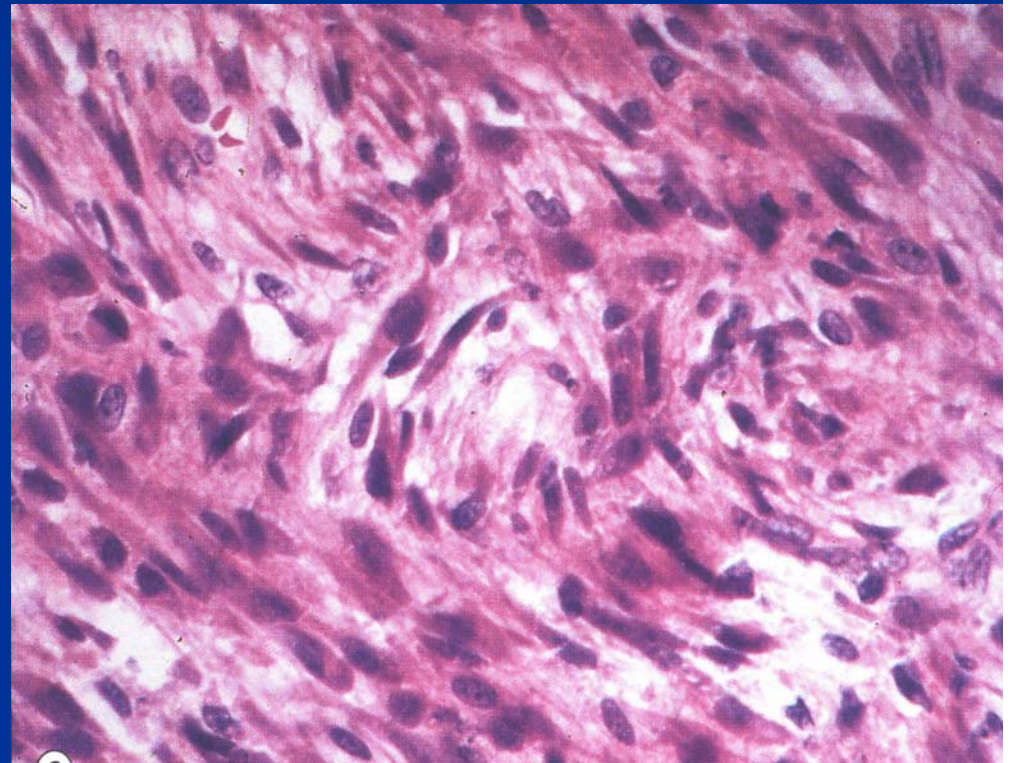


# Myositis Ossificans



# Myositis Ossificans

- This slide demonstrates a very immature area of the myositis ossificans
- It can mimic a high grade sarcoma
- The surgeon must be careful when performing a biopsy
- The pathology must be interpreted in conjunction with the clinical history and radiological studies



# Melorheostosis

- **Definition:** Rare sclerosing bone disorder that is symptomatic and usually becomes manifest after early childhood; “Candle Wax Drippings”
- Localized, diffuse thickening of cortical bone; wax dripping down the side of a candle
- Sometimes initial signs appear in adult patients
- Equal sex distribution
- No inheritance pattern

# Melorheostosis

## ■ Clinical Manifestations:

- Asymmetric; Usually a single limb involved
- Lower extremity > Upper extremity
- Signs/Symptoms
  - Pain and swelling of joints
  - Decreased ROM
  - Joint contractures; tendon and ligament shortening
  - Soft tissue involvement and juxtaarticular masses
  - Growth disturbances that can lead to scoliosis, joint contracture and foot deformity
  - Scleroderma like skin lesions over affected bones

# Melorheostosis

## ■ Radiology:

### ■ Distribution:

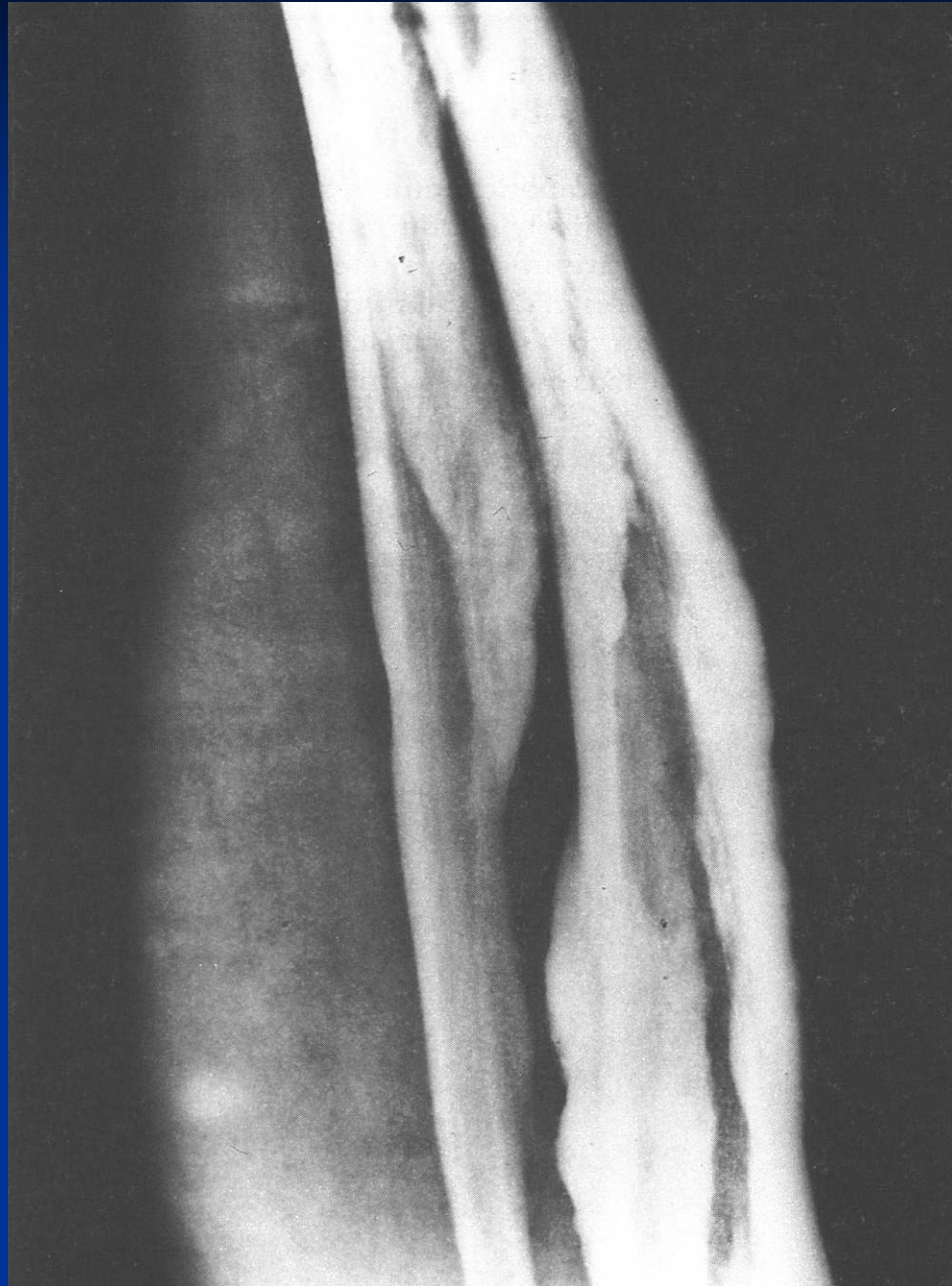- Asymmetric
- Usually a single limb; one or more bones
- Lower extremity > upper extremity
- Sclerotomal distribution
- Rarely see abnormalities in skull, facial bones, ribs, vertebrae

# Melorheostosis

## ■ Radiology:

- Osseous excrescences often exuberant and lobulated along bone surface (Peripherally located cortical hyperostosis)
- Wavy, sclerotic bone contour
- Endosteal involvement (rare) may encroach on marrow space
- Soft tissue masses: Soft tissue ossification and calcification---ankylosis
- Bone scan: Intense activity
- MR: Bone and soft tissue lesions low signal on all pulse sequences



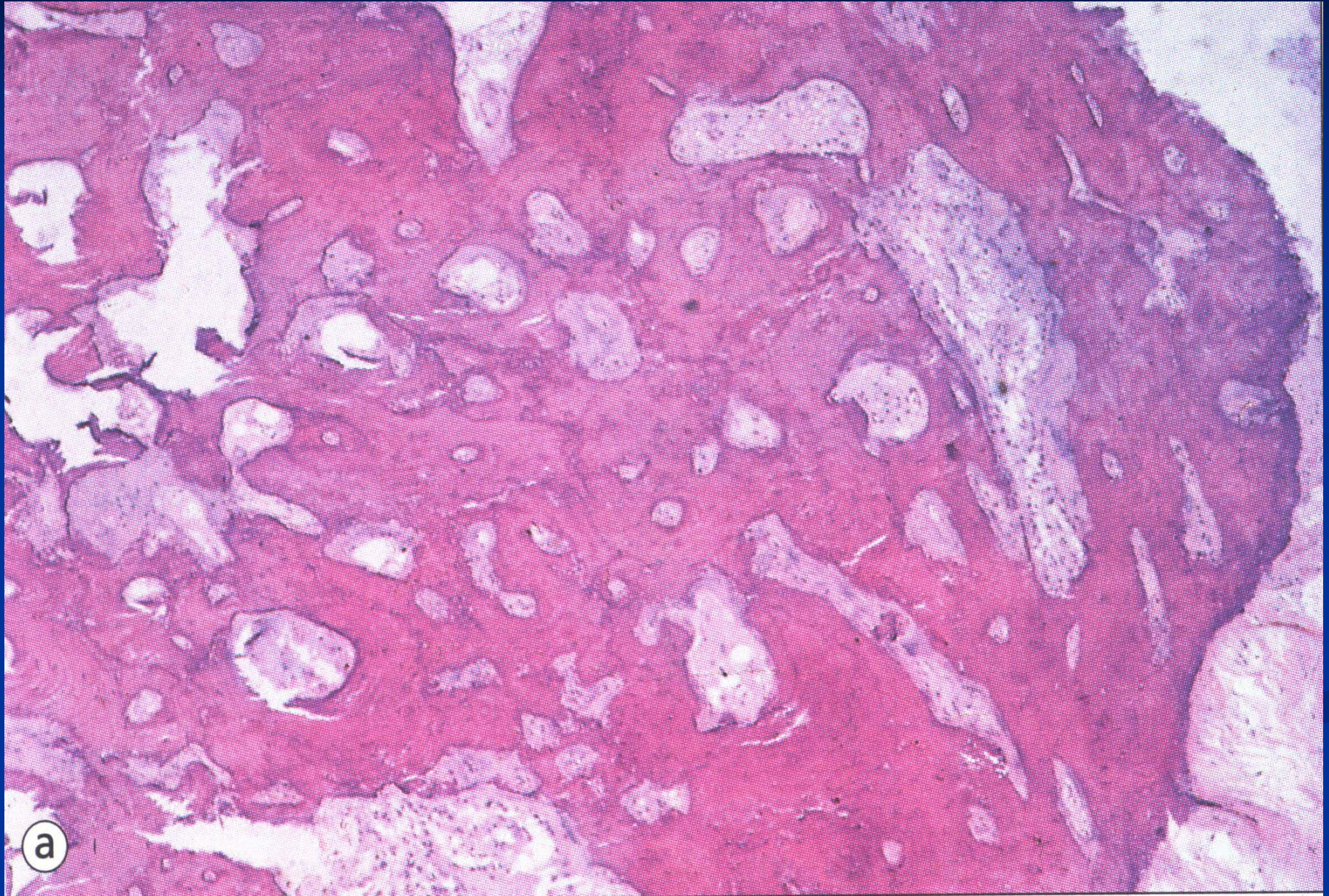


# Melorheostosis

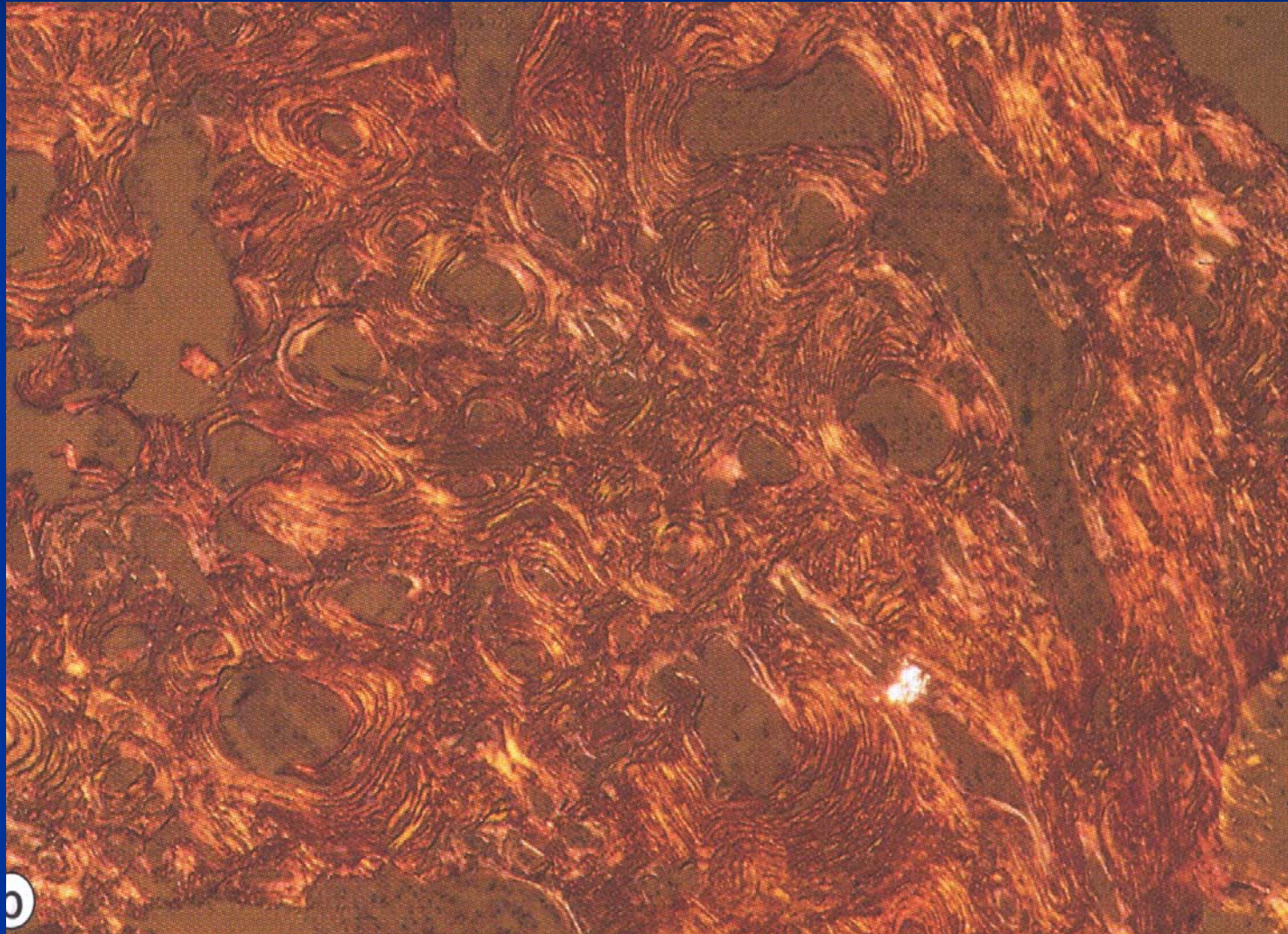
## ■ Pathology:

- Thickened and enlarged cortical bone with prominent haversian canals
- Haversian canals are normal but with irregular arrangement
- Marrow space may show increased cellularity
- Features of immaturity may be present (absence of well organized osteons and a woven bone appearance)
- Soft tissues may contain fibrous tissue with or without ossification

# Pathology Melorrrheostosis



# Polarized Light Melorrrheostosis



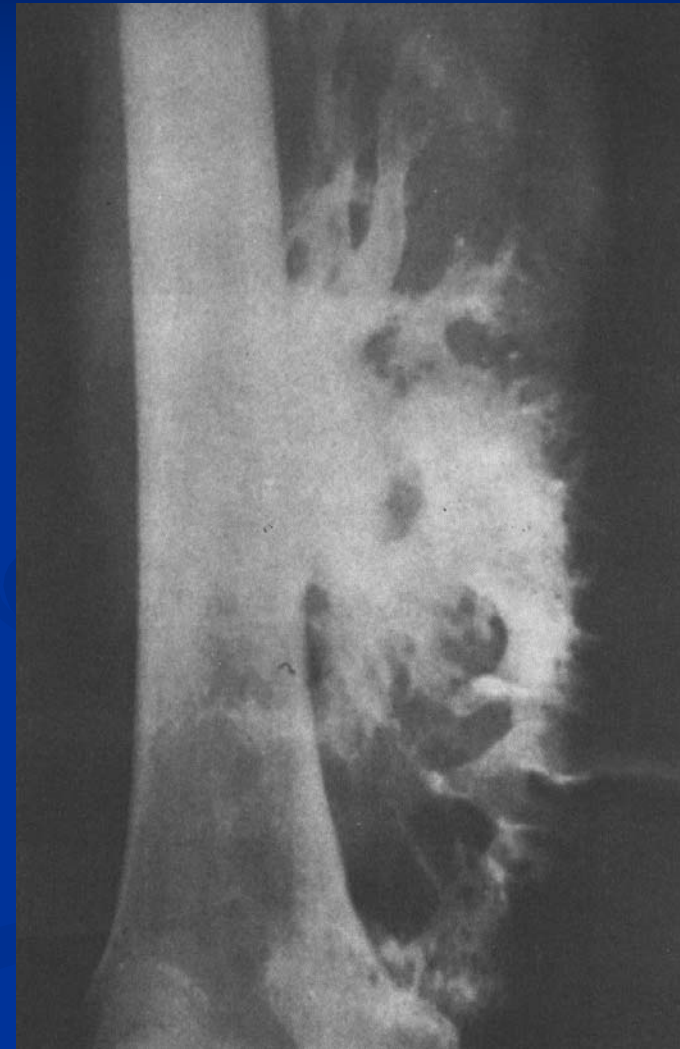# Melorheostosis

## ■ Associations:

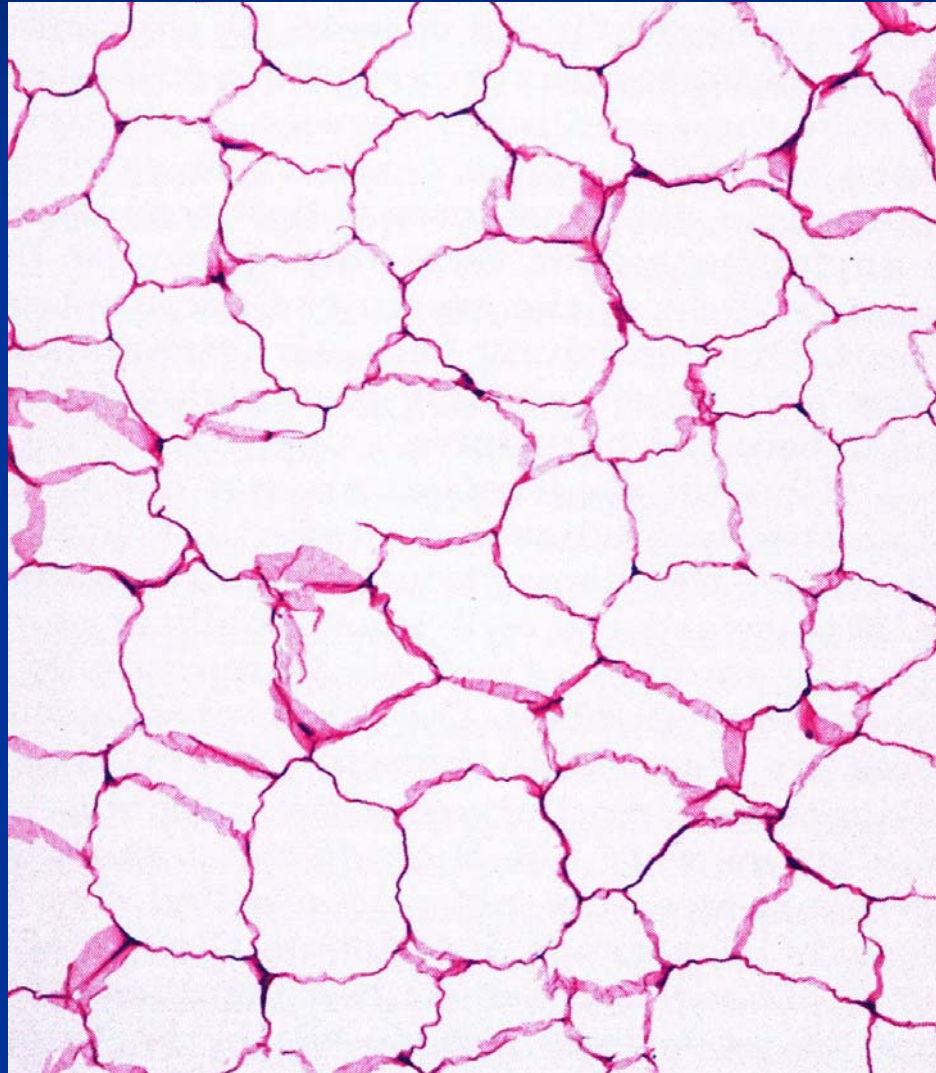
- Linear scleroderma
- Osteopoikilosis
- Osteopathia striata
- Neurofibromatosis
- Tuberous sclerosis
- Hemangiomas
- In the axial skeleton, can be accompanied by overlying fibrolipomas in adjacent areas including the spinal canal and retroperitoneum

# Parosteal Lipoma

- A parosteal lipoma consists of an exostosis protruding from the surface of a bone that is surrounded by a benign fatty tumor
- There is no corticomedullary continuity between the exostosis and underlying bone



# Pathology of Parosteal Lipoma



# Osteoid Osteoma

- **Definition:** A benign osteoblastic tumor consisting of a central core of vascular osteoid tissue (nidus) and a peripheral zone of sclerotic bone
- **History:**
  - Described in 1935 by Jaffe as an osteoblastic tumor composed of osteoid and atypical bone
  - Controversy exists as to its true nature: neoplastic, inflammatory, traumatic, vascular, viral
  - May be related to osteoblastoma
  - 3% of primary bone tumors (11% of all bone tumors that come to biopsy)



# Osteoid Osteoma

## ■ Clinical:

- Young: 7-25 years old
- Male: Female 2-3:1
- Rare in afroamerican
- Pain is the hallmark of the lesion (1.6% are painless and 50% of these are in the hand)
- Night pain common and more dramatic
- Pain is characteristically relieved with aspirin, NSAIDS, salicylates; inhibit PGE-2

# Osteoid Osteoma

## ■ Clinical:

- Soft tissue swelling and tenderness
- Spine: Torticollis, spinal stiffness, scoliosis (No neurologic dysfunction)
- Intraarticular tumors: joint tenderness, swelling, synovitis, decreased ROM

# Osteoid Osteoma

## ■ Skeletal Distribution:

- Femur—most common

- Tibia—2<sup>nd</sup> most common

(Femur and Tibia constitute 50%-60% of lesions;

Usually located in diaphysis and may extend into metaphysis)

- Spine: 10% (Posterior elements: 90%; Vertebral body 10%)

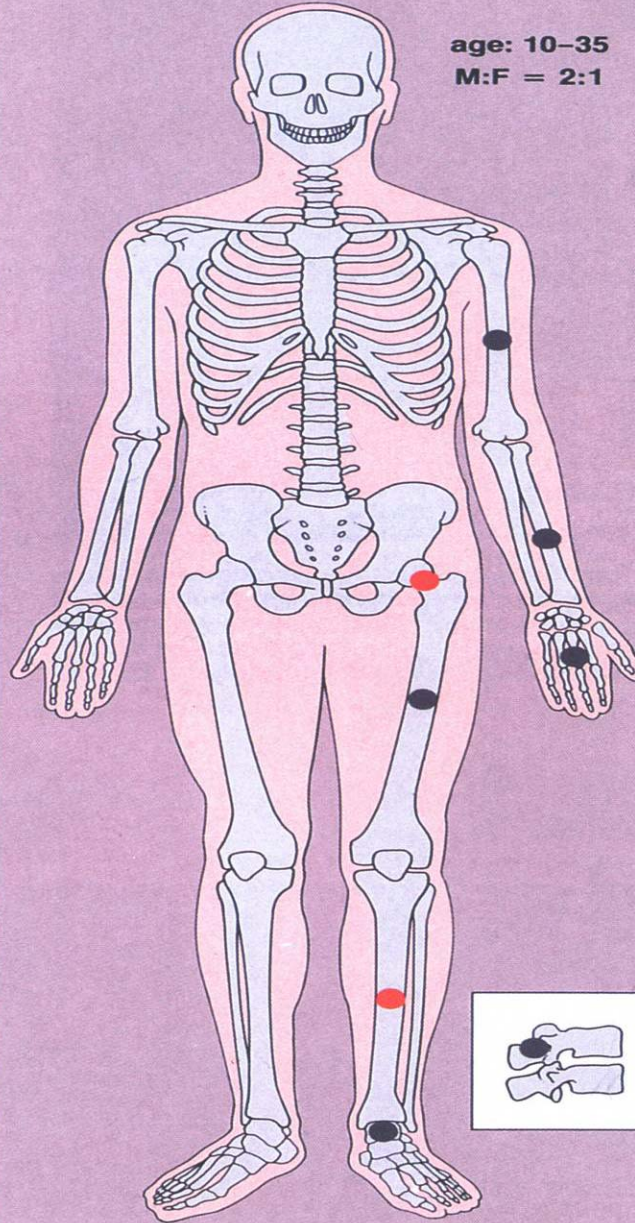
- Hand and Foot: 10-20%: proximal phalanx, metacarpal, scaphoid, navicular, calcaneus

- Epiphyseal and Intraarticular lesions are rare

# Osteoid Osteoma

age: 10-35

M:F = 2:1



■ common sites

■ less common sites

# Osteoid Osteoma

## ■ Classification:

- **Cortical (70-75%):** Long bone shaft; intense fusiform sclerosis; central nidus
- **Subperiosteal:** Rare; arises adjacent to bone; Usually femoral neck; hand/foot; Bone may show a pressure erosion on surface/lucent lesion on surface/scalloped excavation; adjacent periosteal reaction
- **Intramedullary/Cancellous (25%):** usually femoral neck, hand/foot; little sclerosis and sclerosis may be at a distance from the nidus

# Osteoid Osteoma

## ■ Radiology:

### ■ Cortical Lesions

- Radiolucent lesion (nidus) surrounded by bone sclerosis with cortical thickening (endosteal and subperiosteal new bone formation)
- Dense fusiform sclerosis; Sometimes obscures the nidus
- Periosteal bone is solid, rarely lamellated
- Nidus is usually central, rarely >1.5 cm
- Nidus may be radiolucent or contain variable amounts of calcification
- Nidus is usually in the center of the sclerotic reaction

# Osteoid Osteoma

- **Radiology:**
- **Cortical Lesions:** rarely there may be more than one nidus or there may be more than one osteoid osteoma, each with its own nidus (in same bone or neighboring bones—multicentricity)
- **Bone Scan:** Double Density Sign: Hot within the nidus and less intense accumulation peripherally within the sclerotic bone
- **CT:** Well defined nidus with a smooth peripheral margin; +/- mineralization (CT more sensitive than XR and MRI for detecting mineralization); CT is better for detecting nidus in presence of exuberant sclerosis

# Osteoid Osteoma

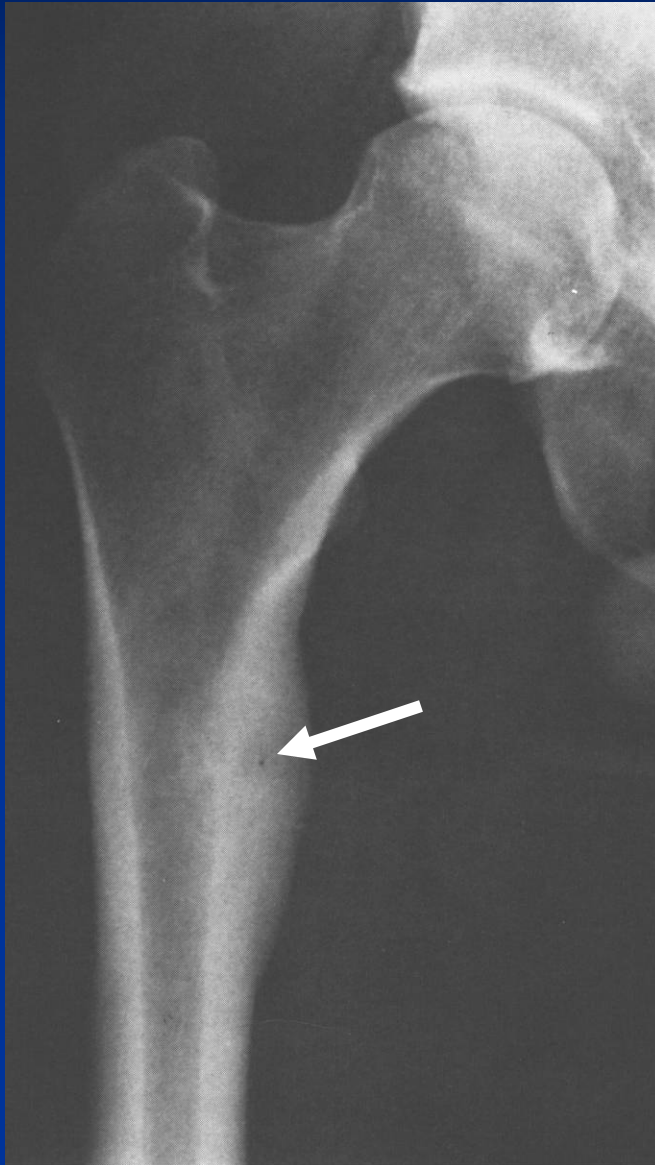
## ■ Radiology:

## ■ MRI:

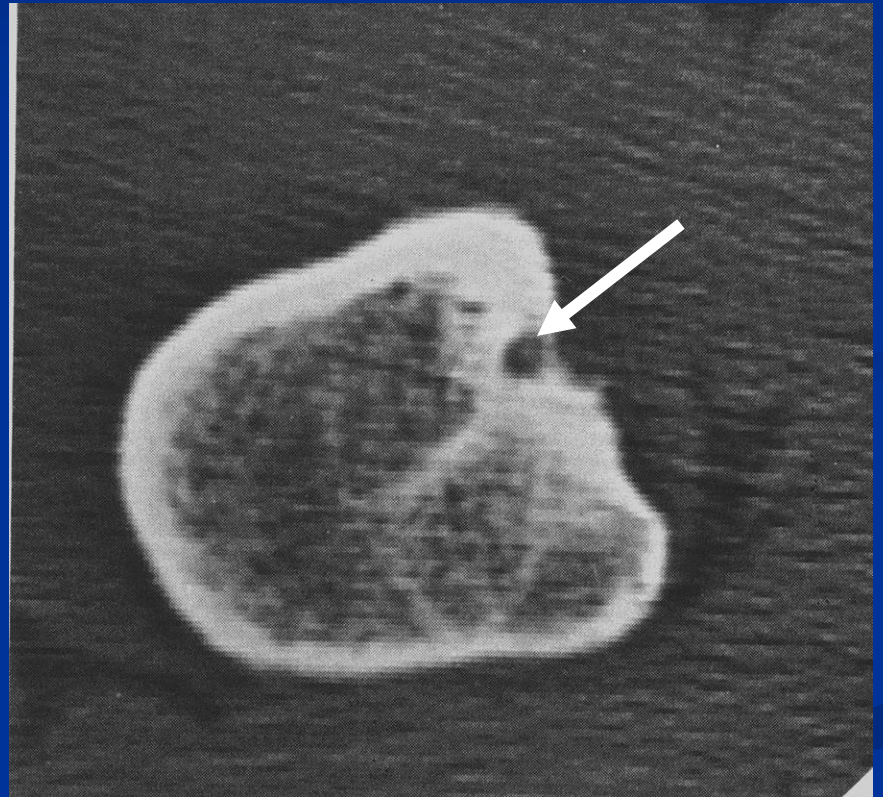
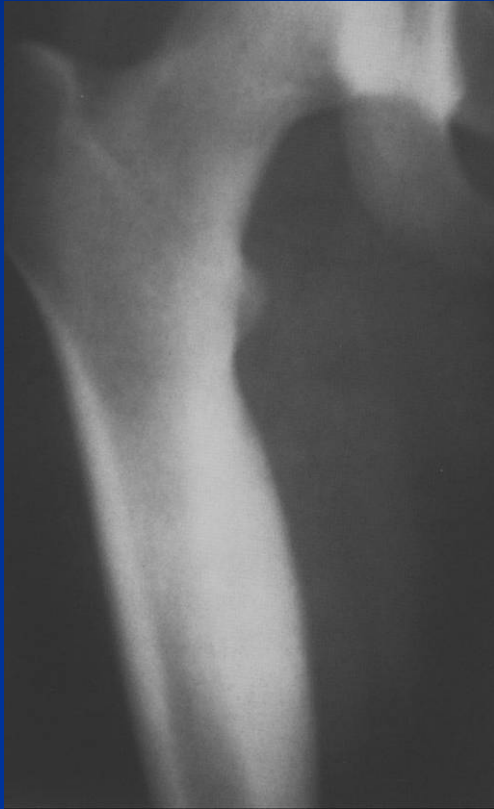
- May mimic findings of a malignant tumor such as Ewing's sarcoma or osteomyelitis because of the presence of marrow and soft tissue edema
- CT is more useful for detecting the nidus if there is extensive edema
- Intermediate intensity on T1
- High intensity on T2 in areas of nidus and surrounding edema
- Reactive marrow edema may obscure the lesion on T2
- Good for detecting synovitis and joint effusion with Intraarticular osteoid osteomas



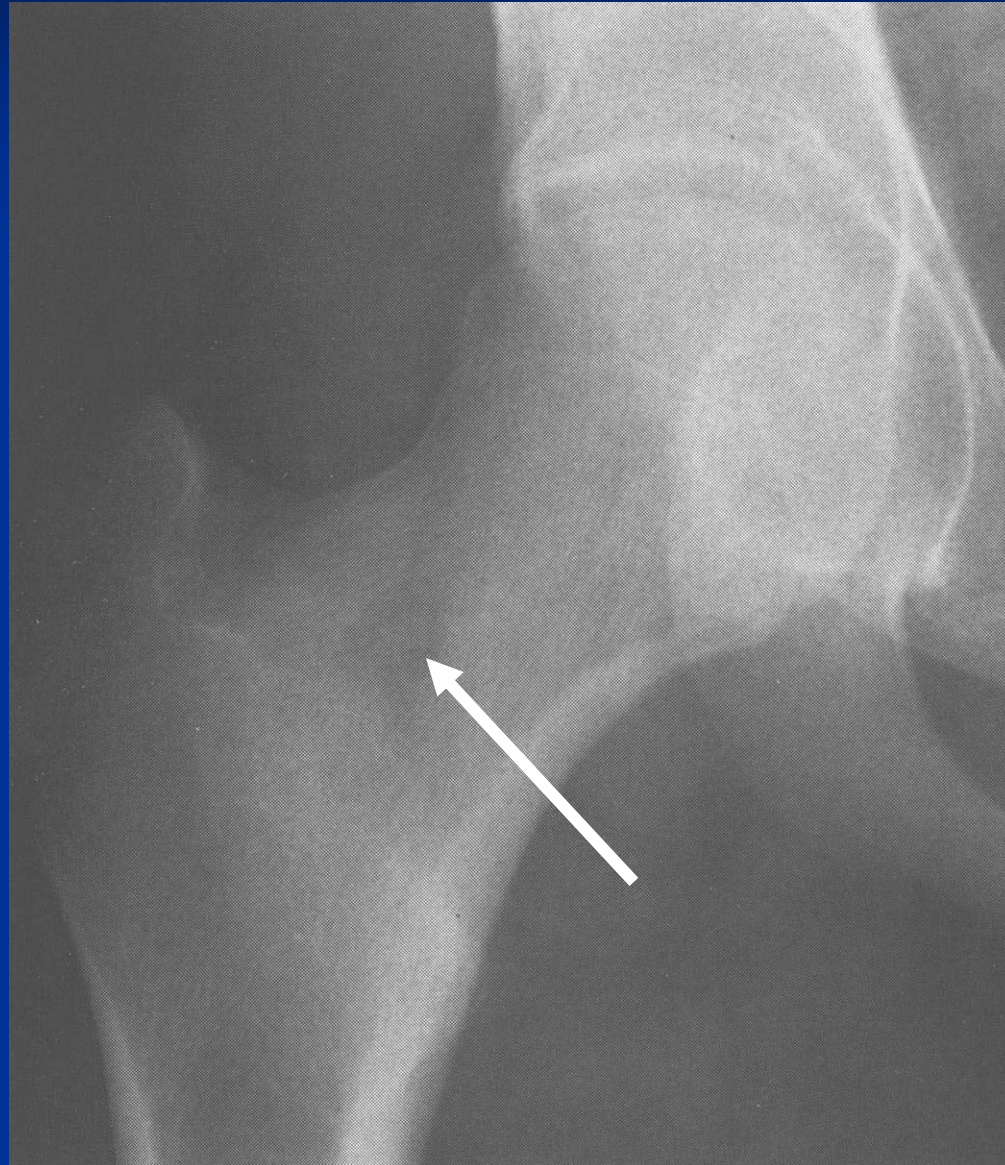
# Intracortical Osteoid Osteoma



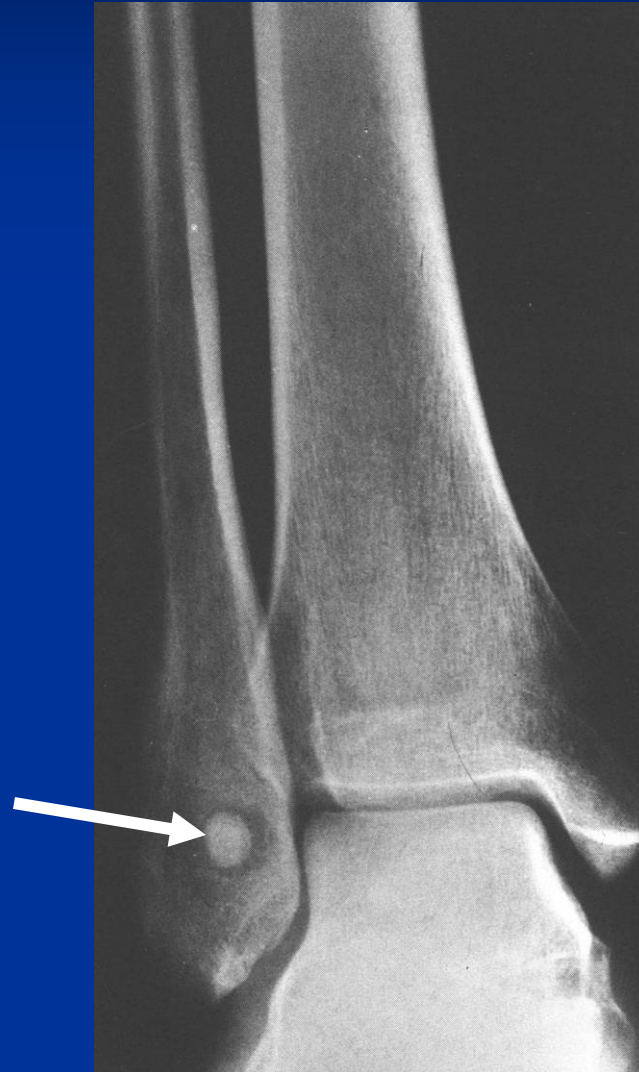
# Intracortical



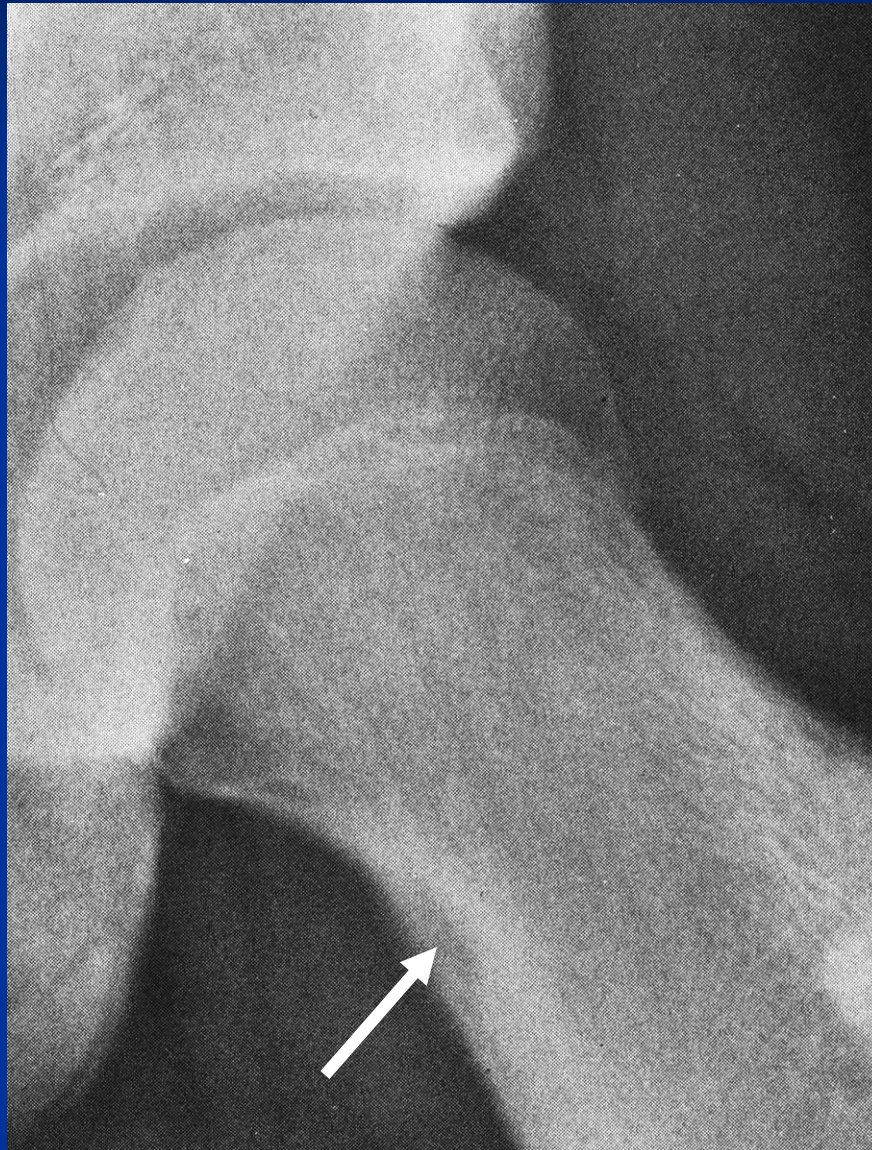# Intramedullary



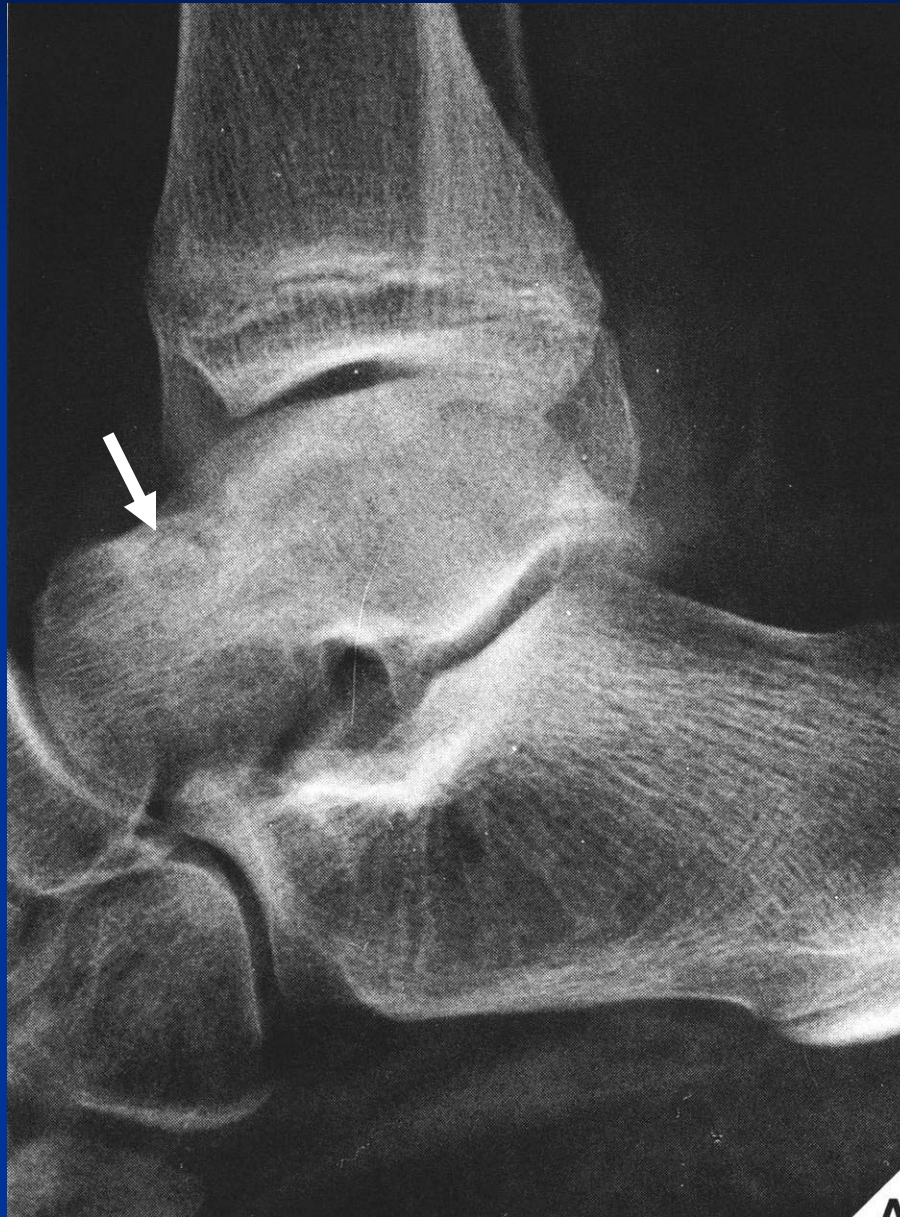# Intramedullary



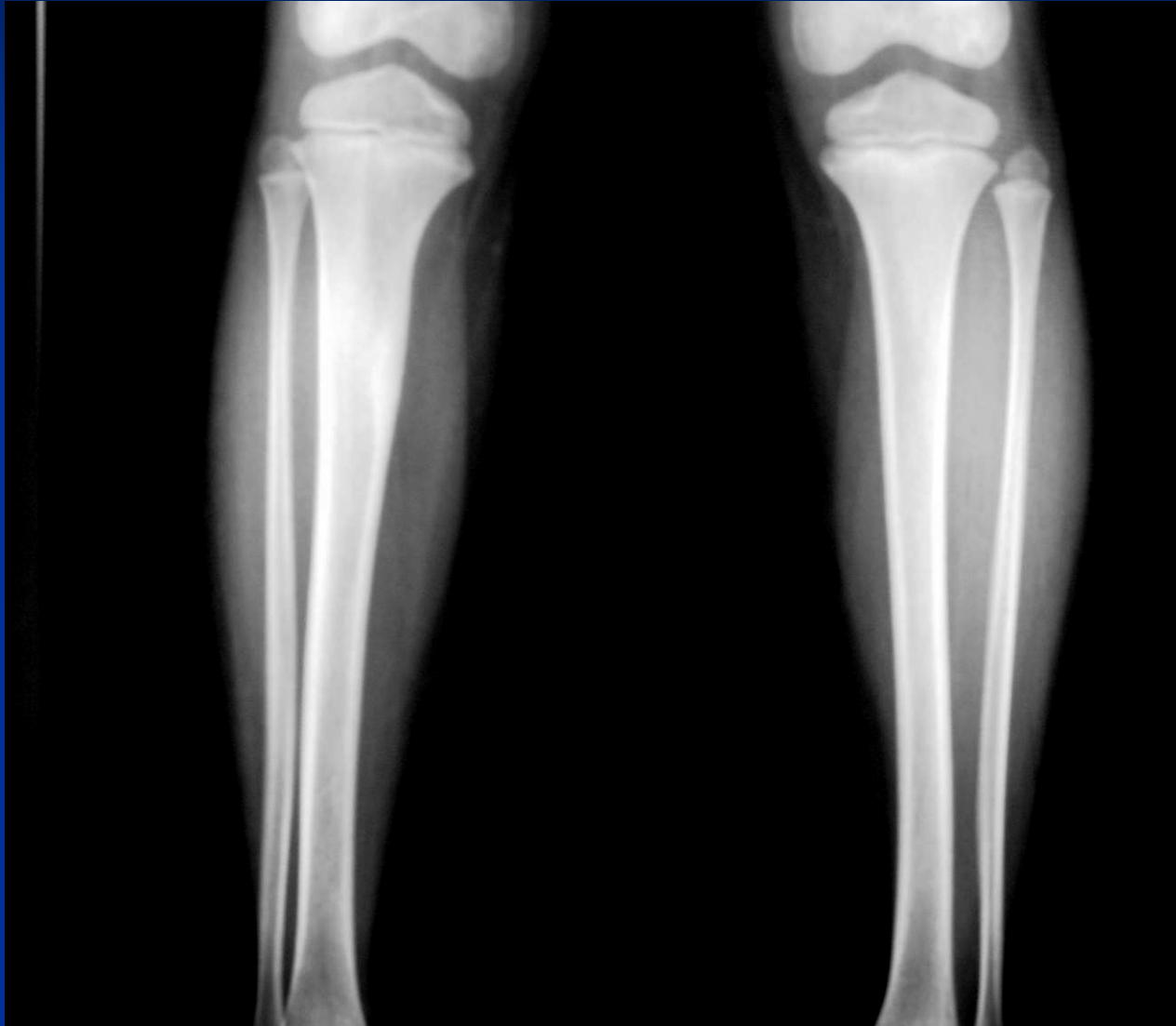# Intracapsular



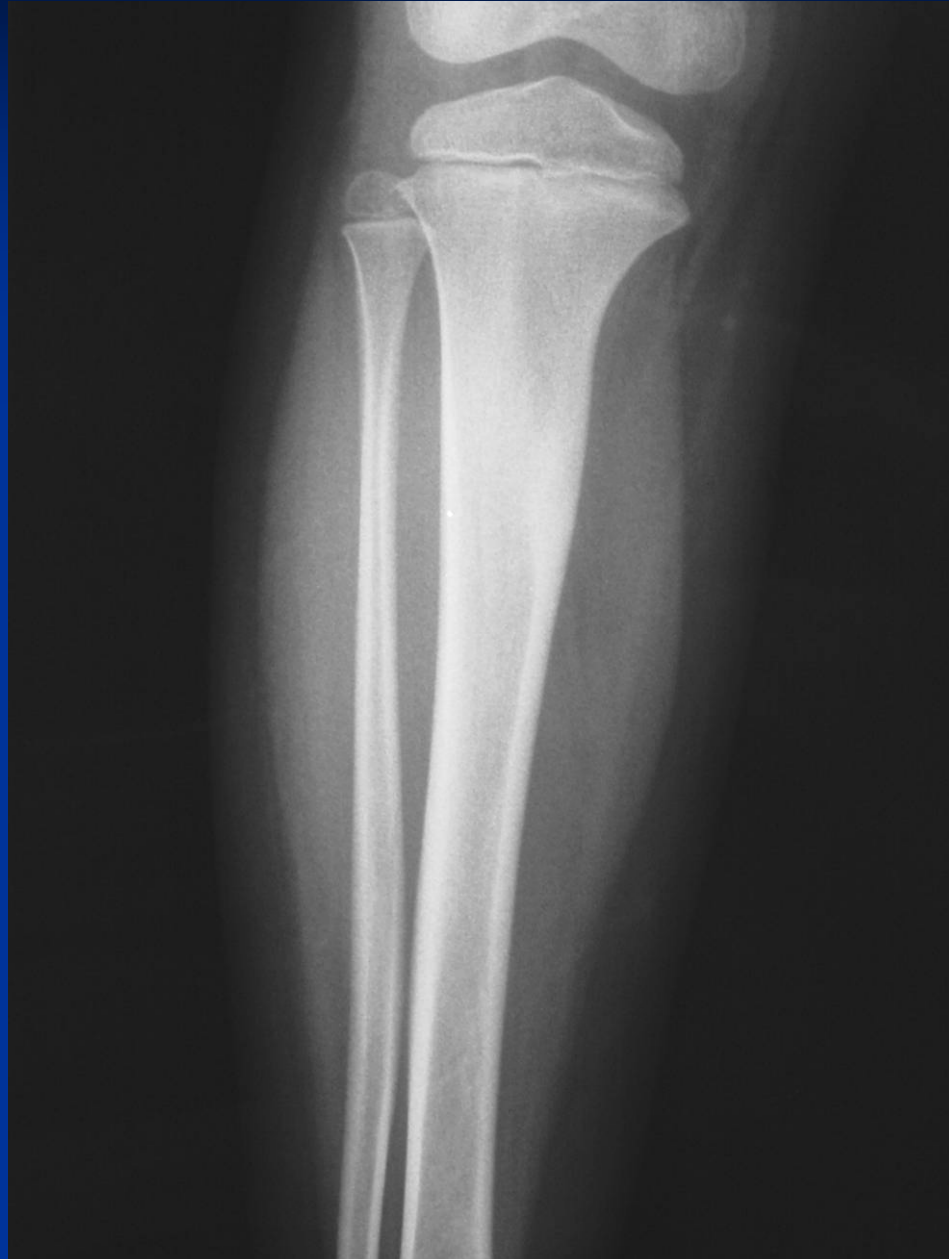# Talus



# Osteoid Osteoma

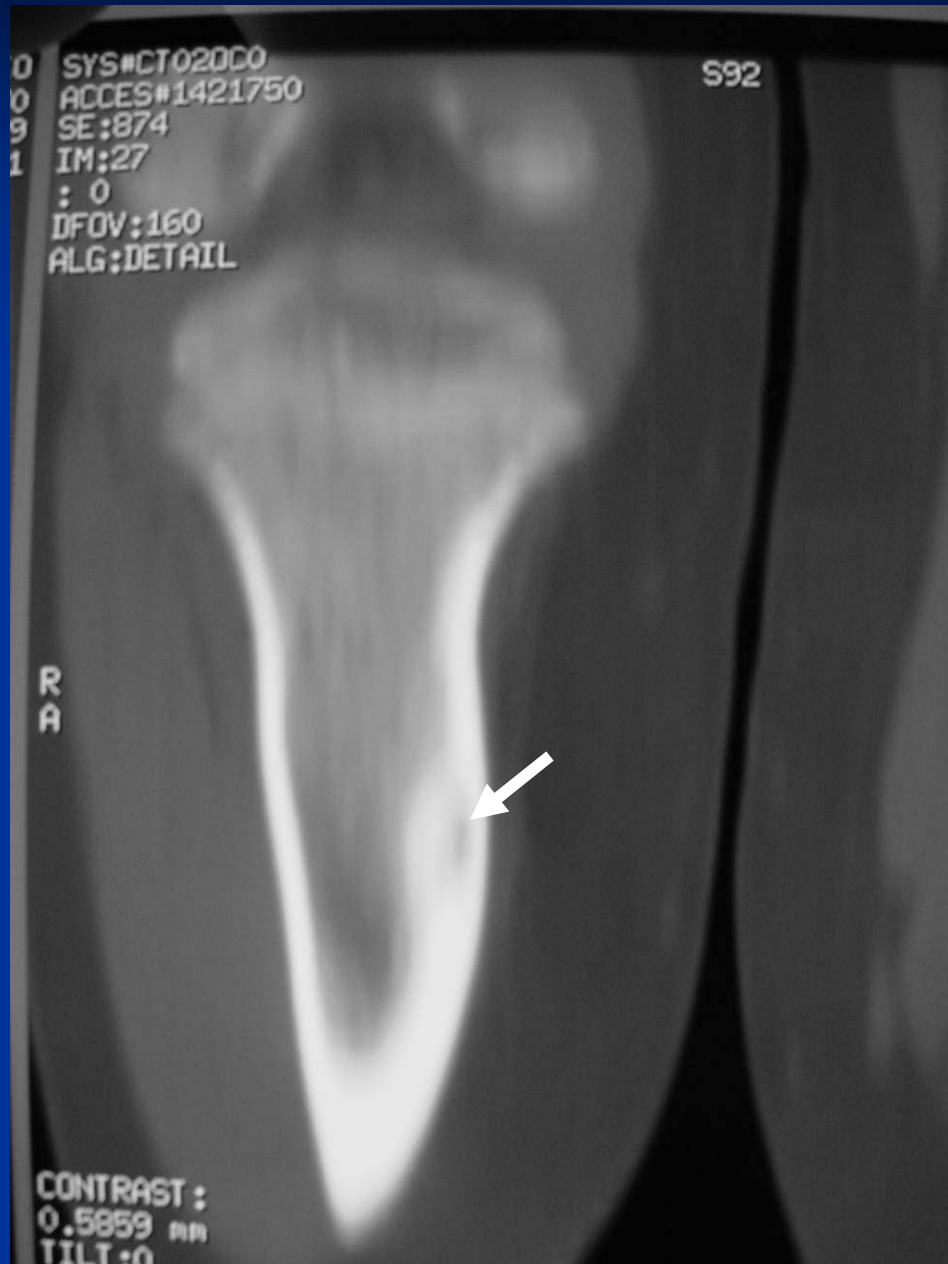

# Osteoid Osteoma



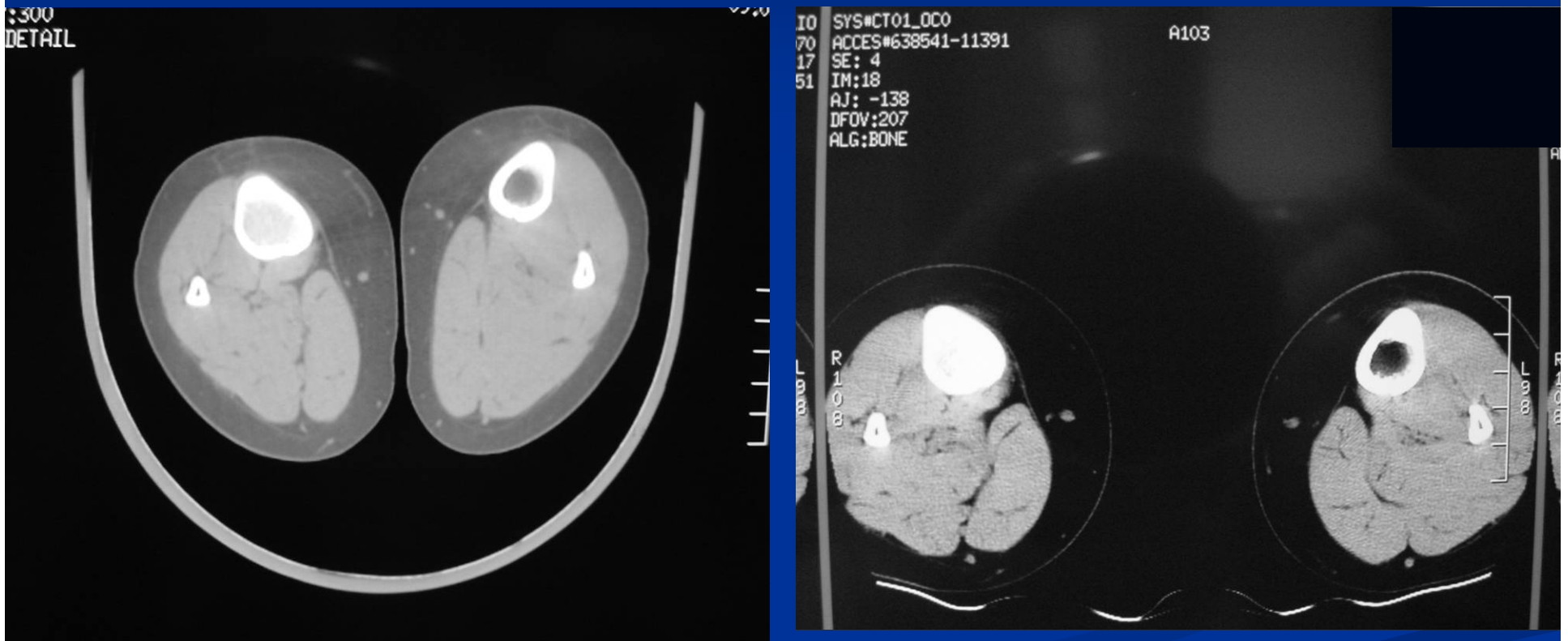


# Osteoid Osteoma

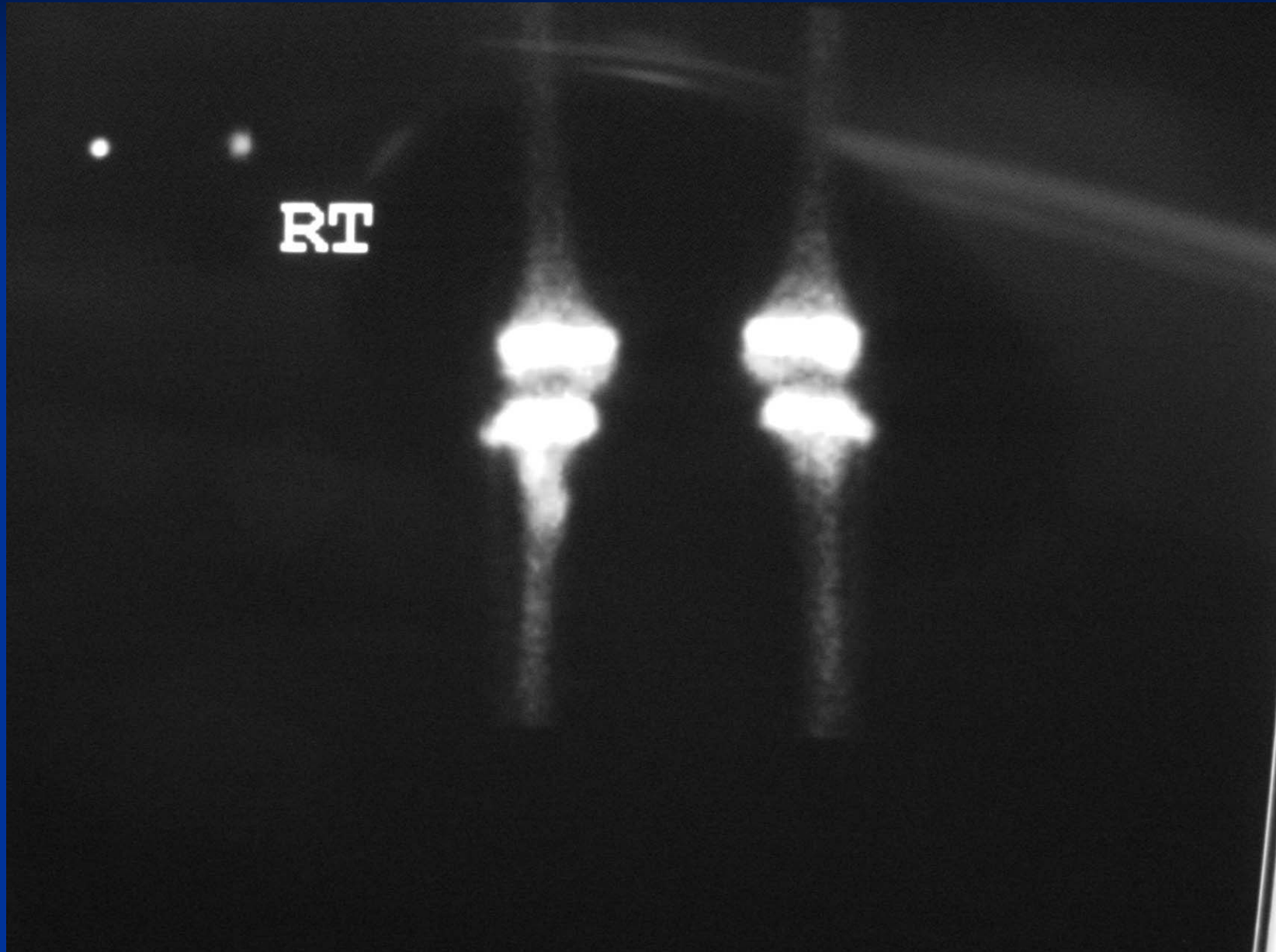


# Osteoid Osteoma

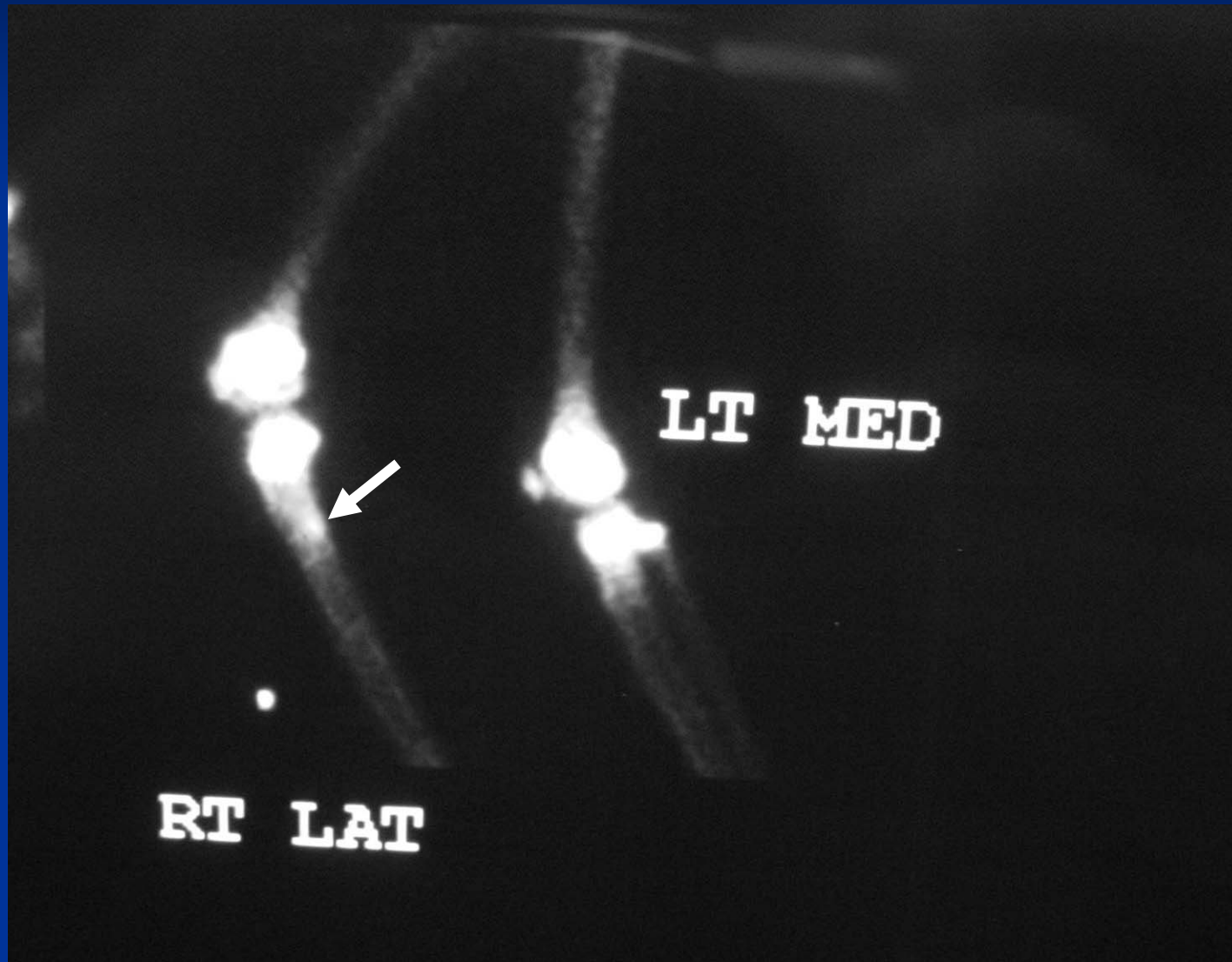## Extensive Sclerosis Obliterated the Canal of the Right Tibia



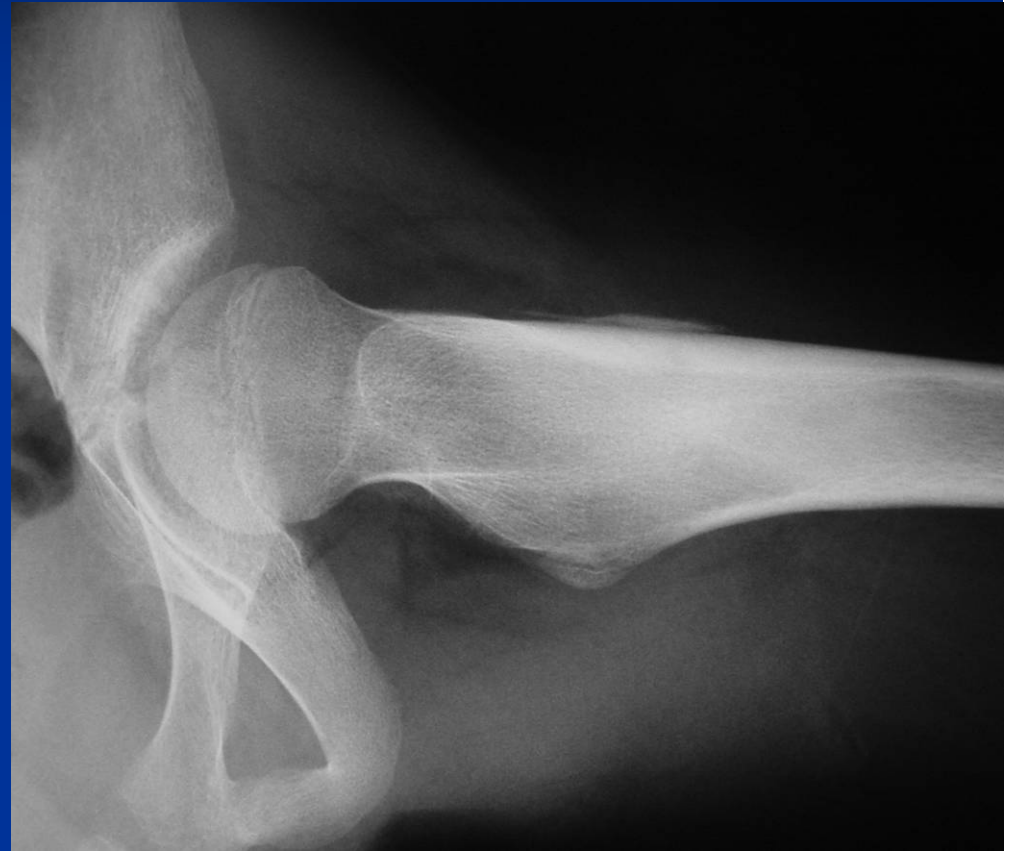
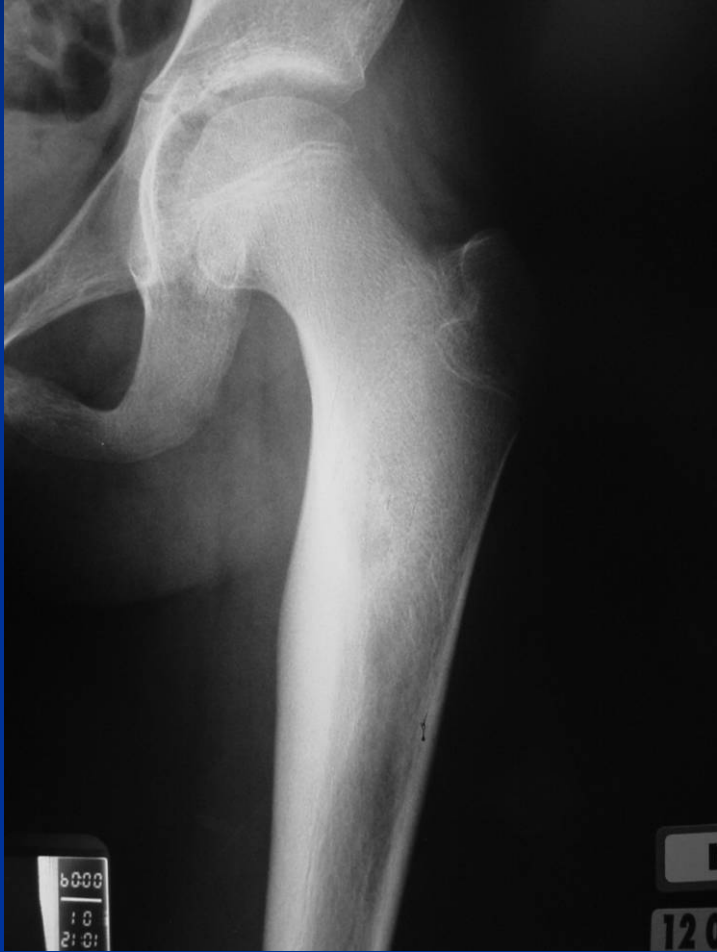
# Osteoid Osteoma Bone Scan



# Osteoid Osteoma

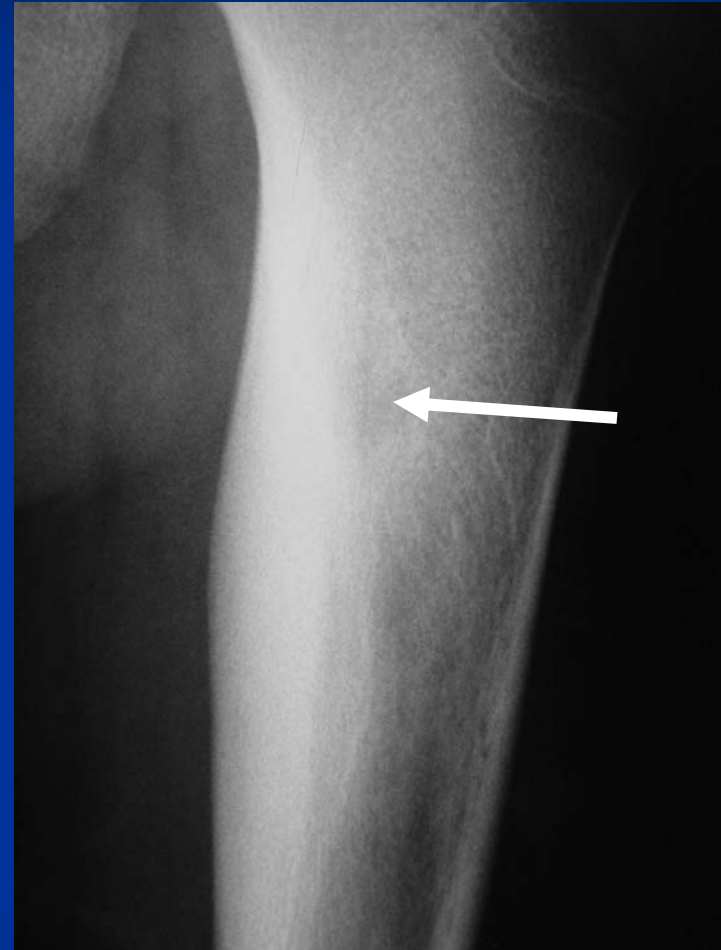


# Osteoid Osteoma Xray



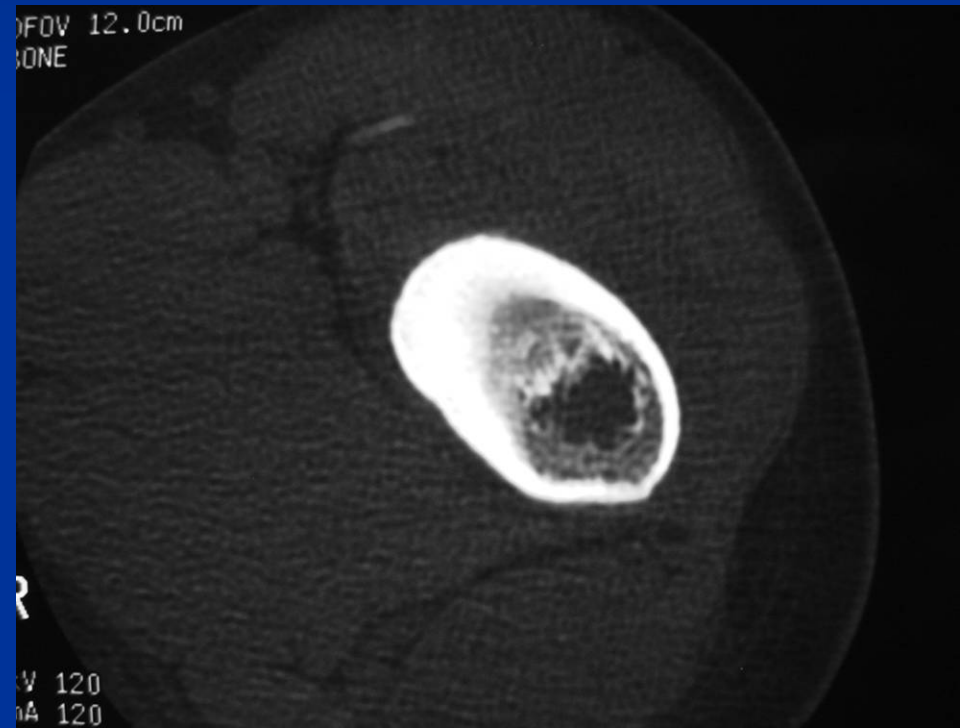
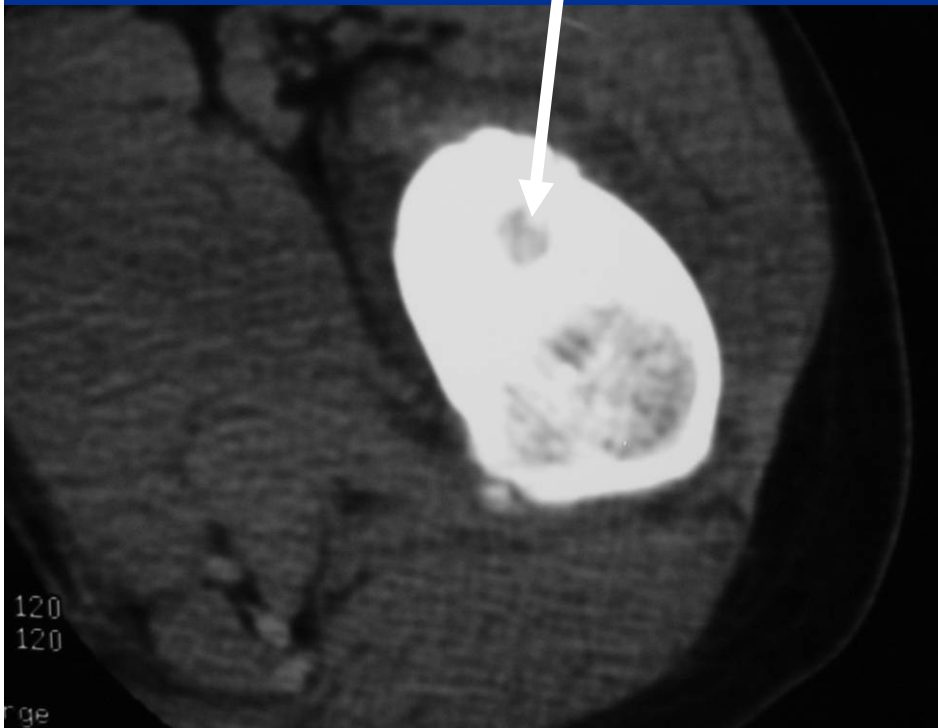
# Osteoid Osteoma

- Radiolucent Nidus  
(arrow)
- Surrounding Sclerosis
- Benign Periosteal  
Reaction causing Cortical  
Thickening

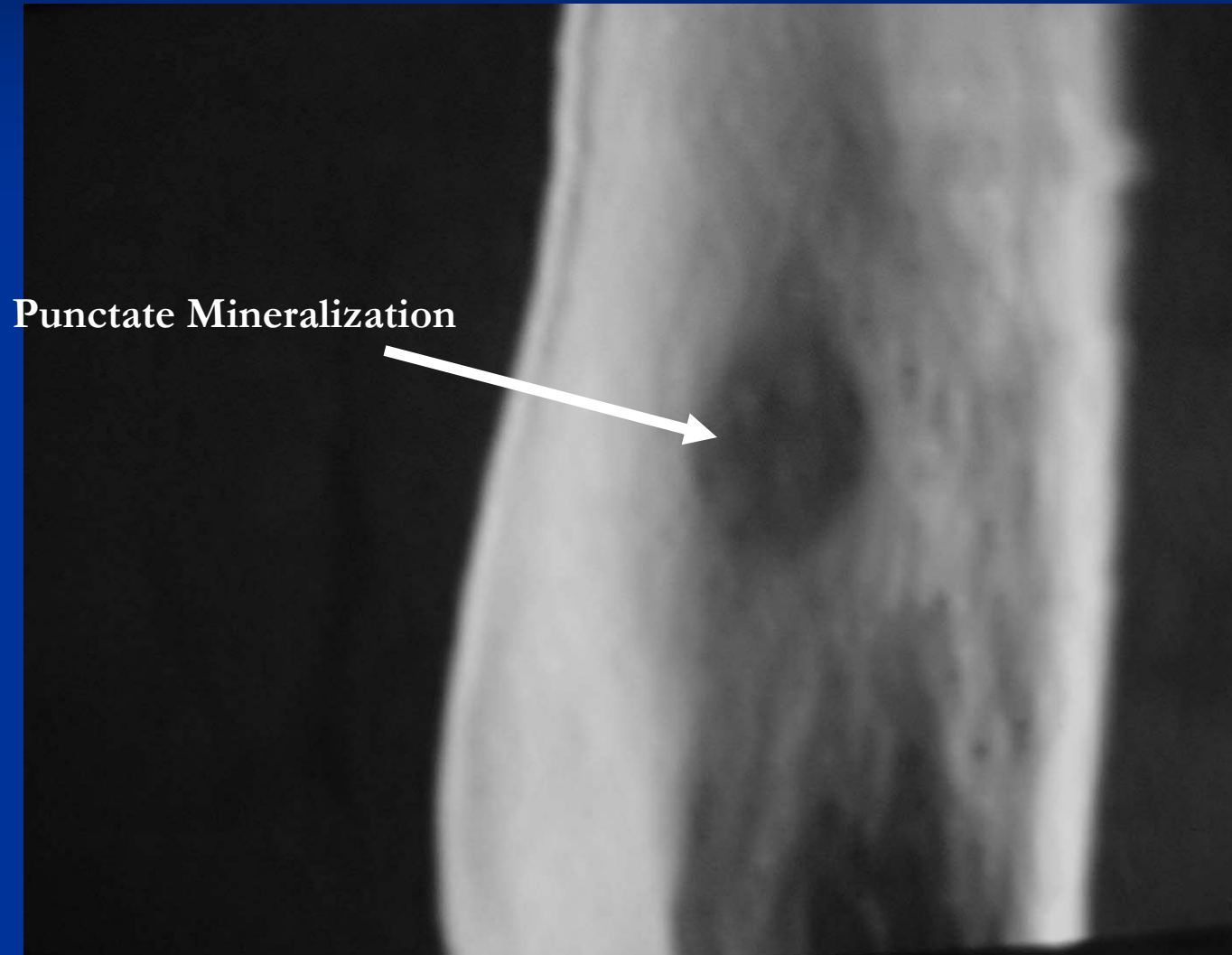

# Osteoid Osteoma CT Scan

Mineralization in Nidus  
Detected on CT

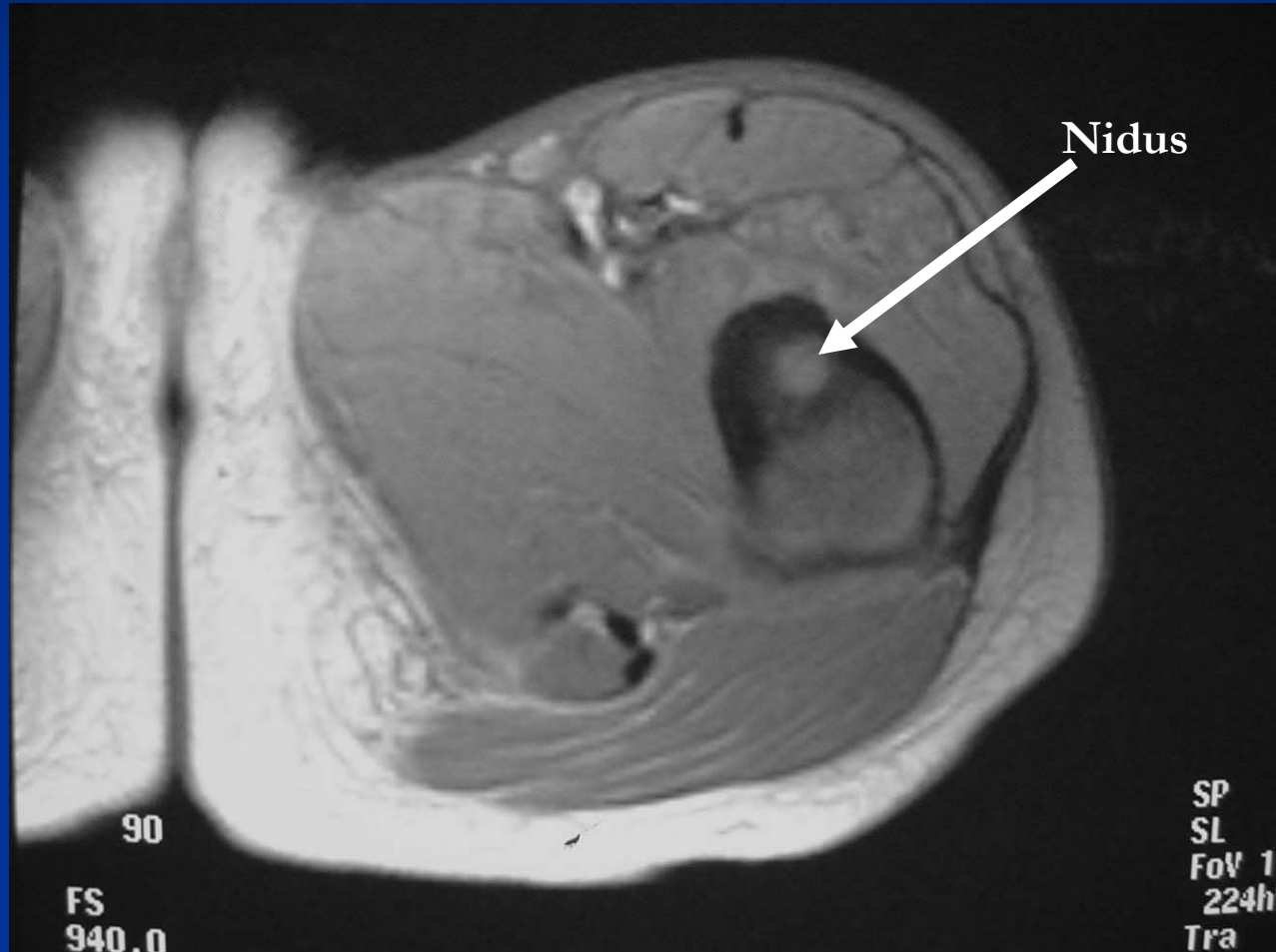


# Osteoid Osteoma CT Reformatted Image

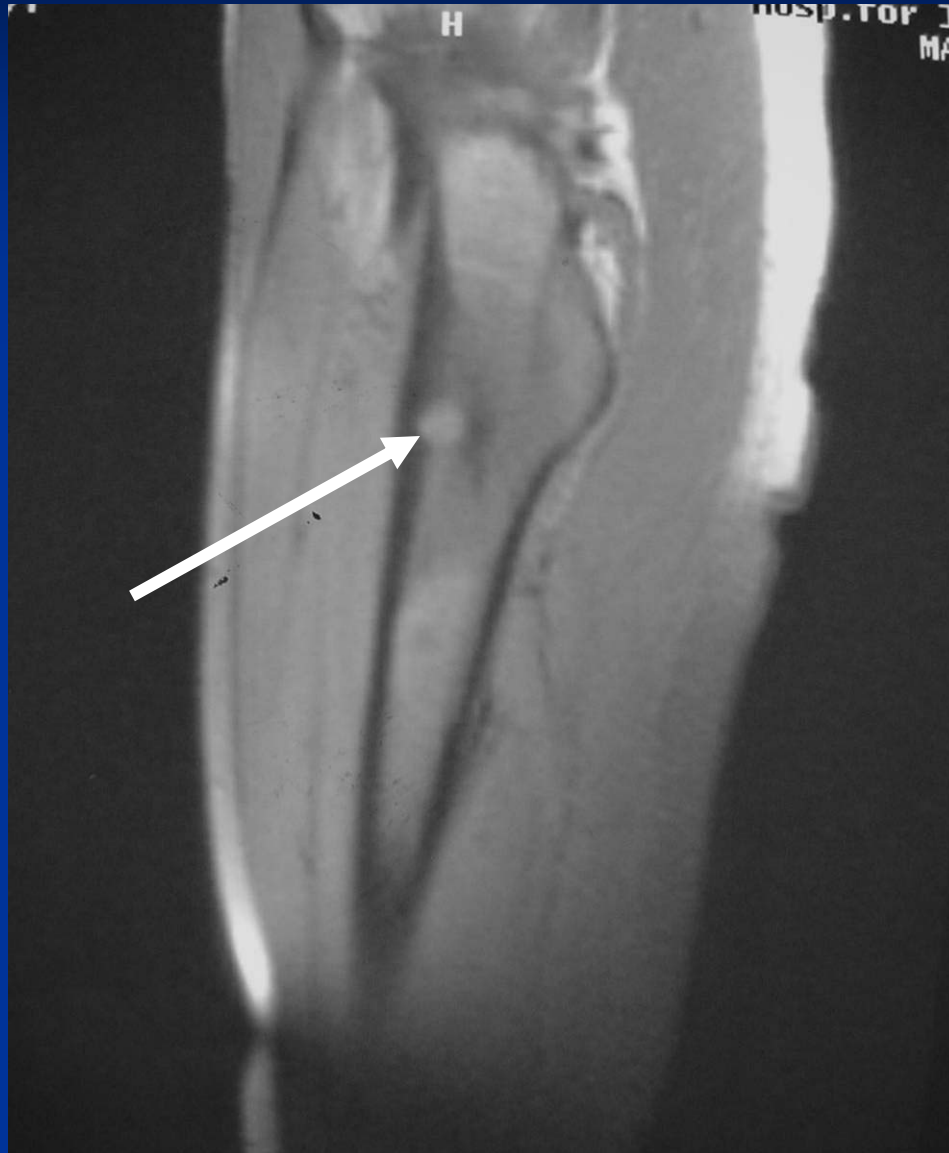



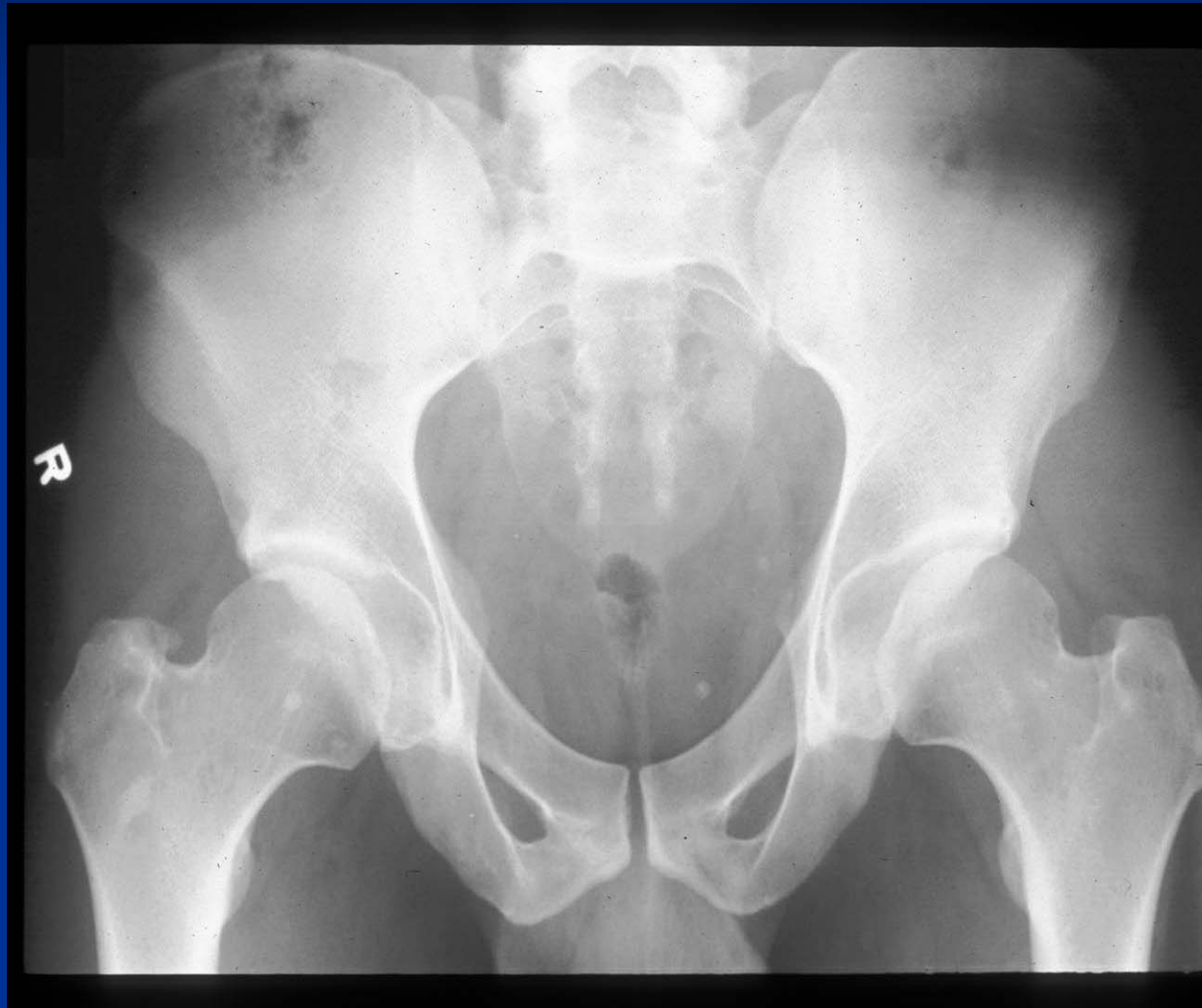# Osteoid Osteoma MRI



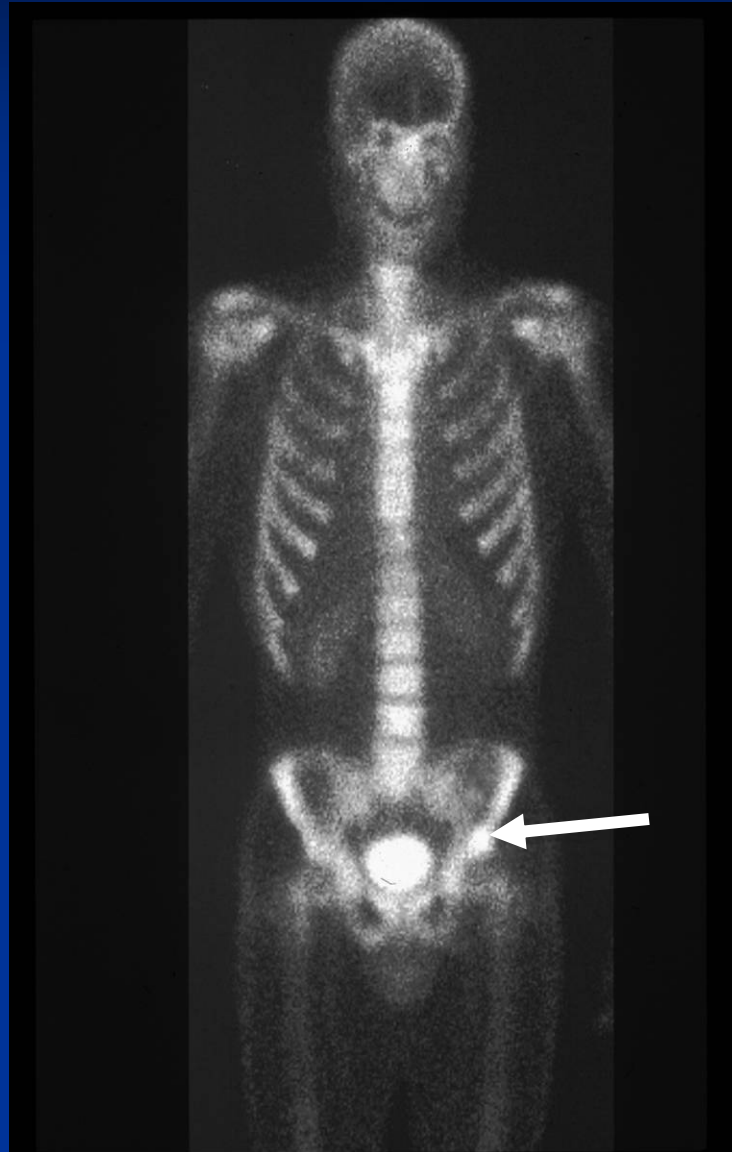# Osteoid Osteoma MRI



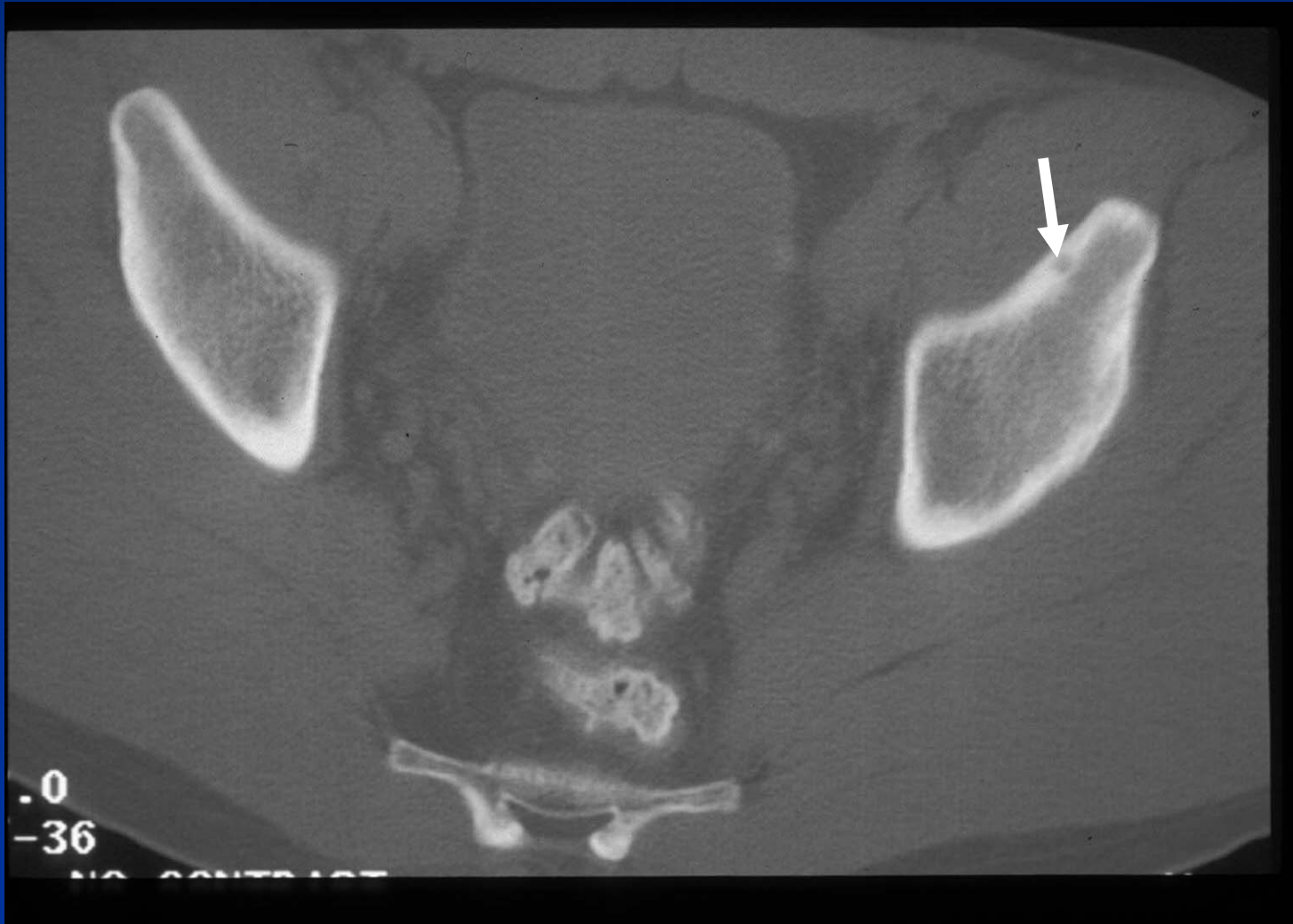# Osteoid Osteoma Xray



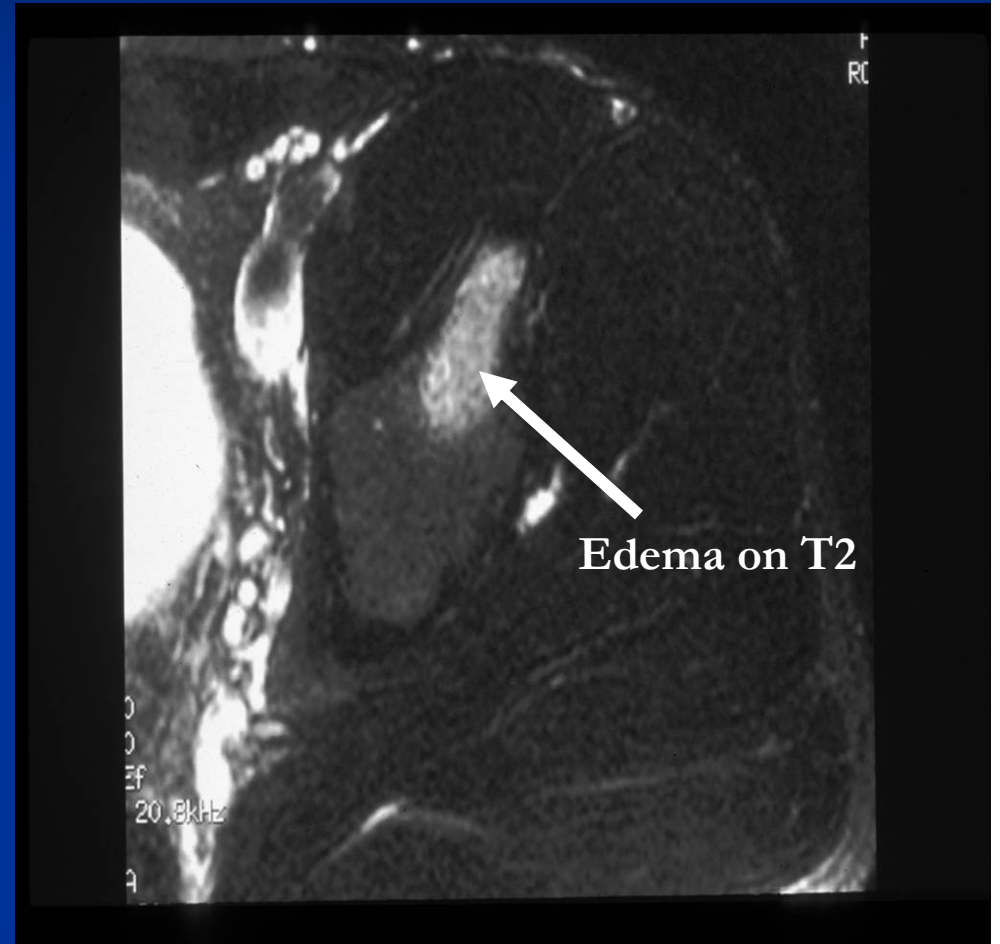
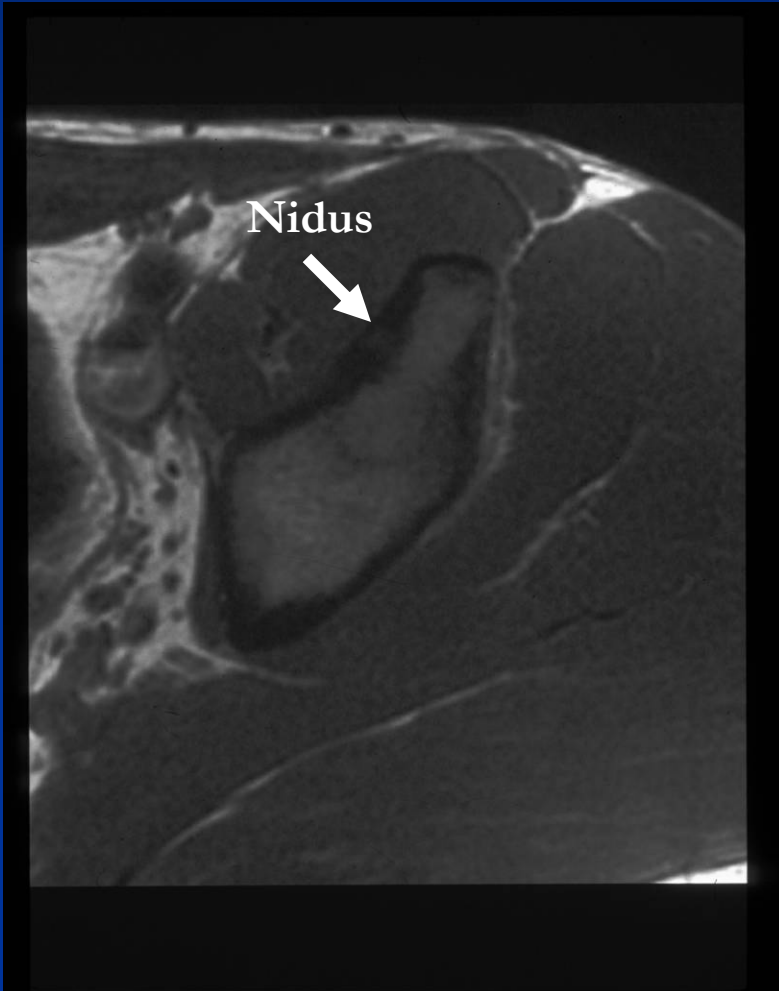
# Osteoid Osteoma Bone Scan



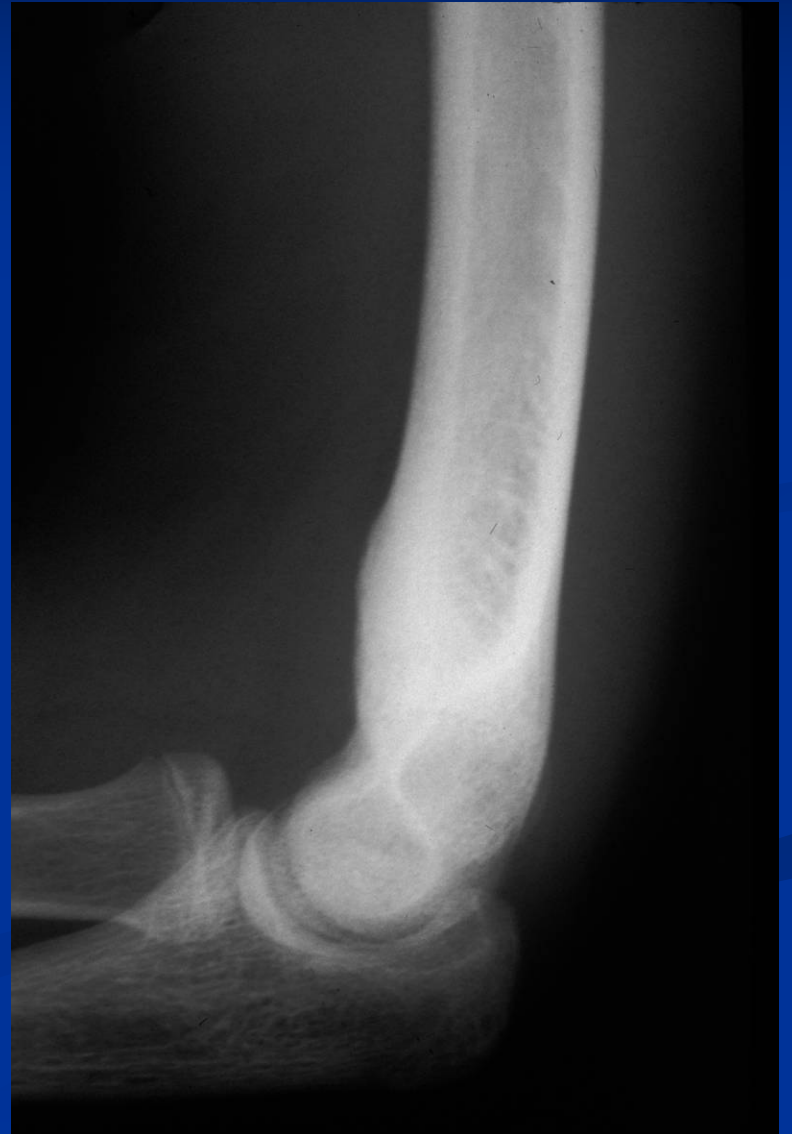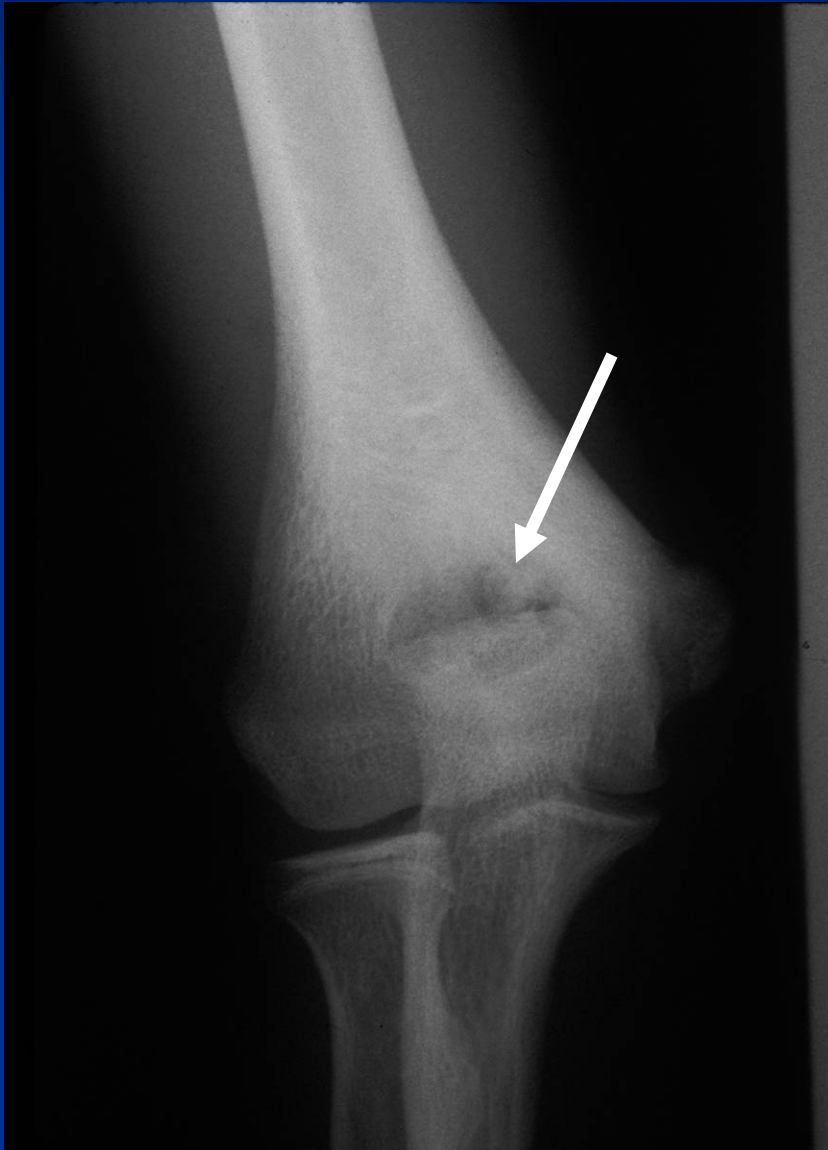
# Osteoid Osteoma CT Scan



# Osteoid Osteoma MRI of Previous Lesion (Nidus not Clearly Visualized)

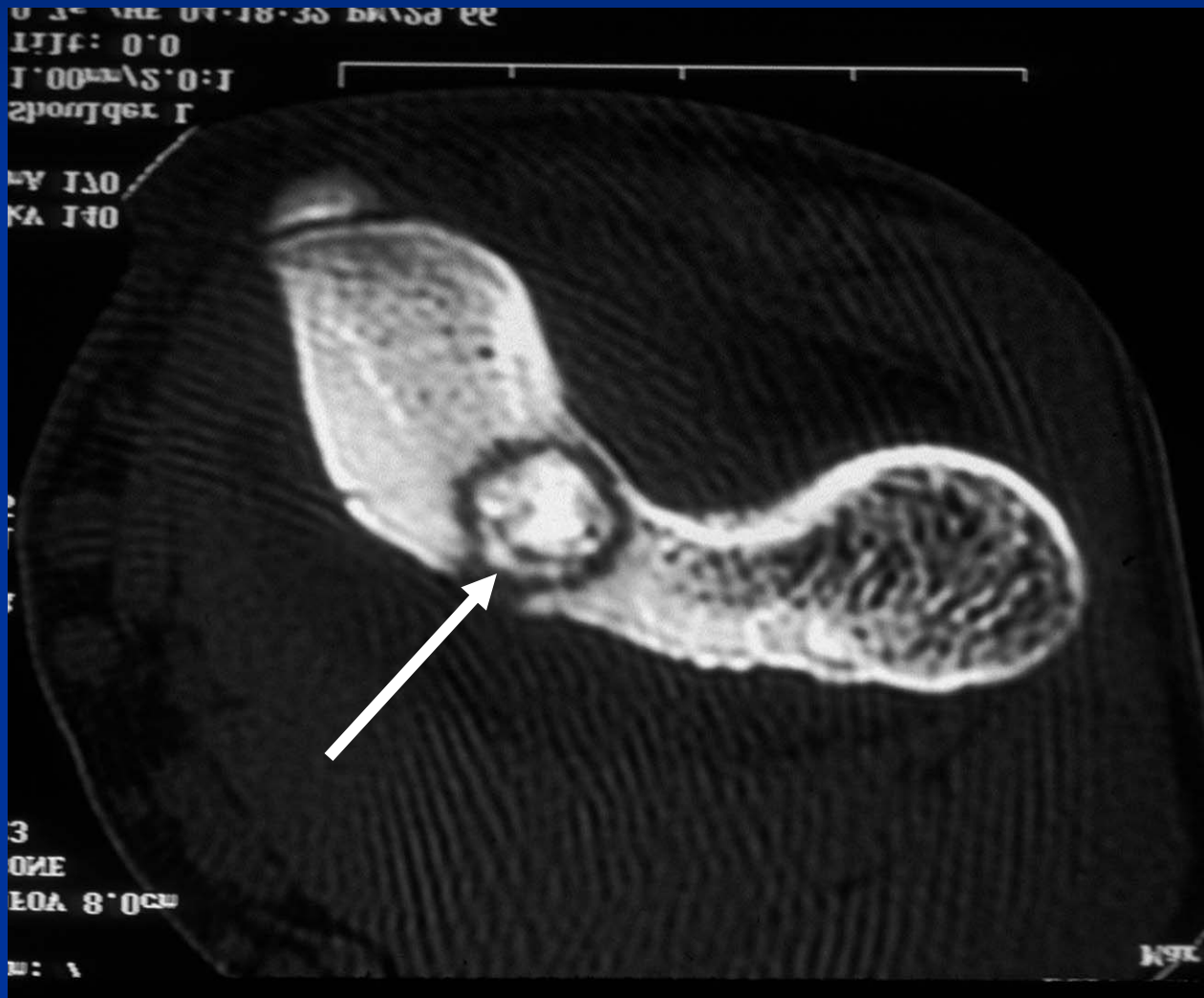

# Osteoid Osteoma



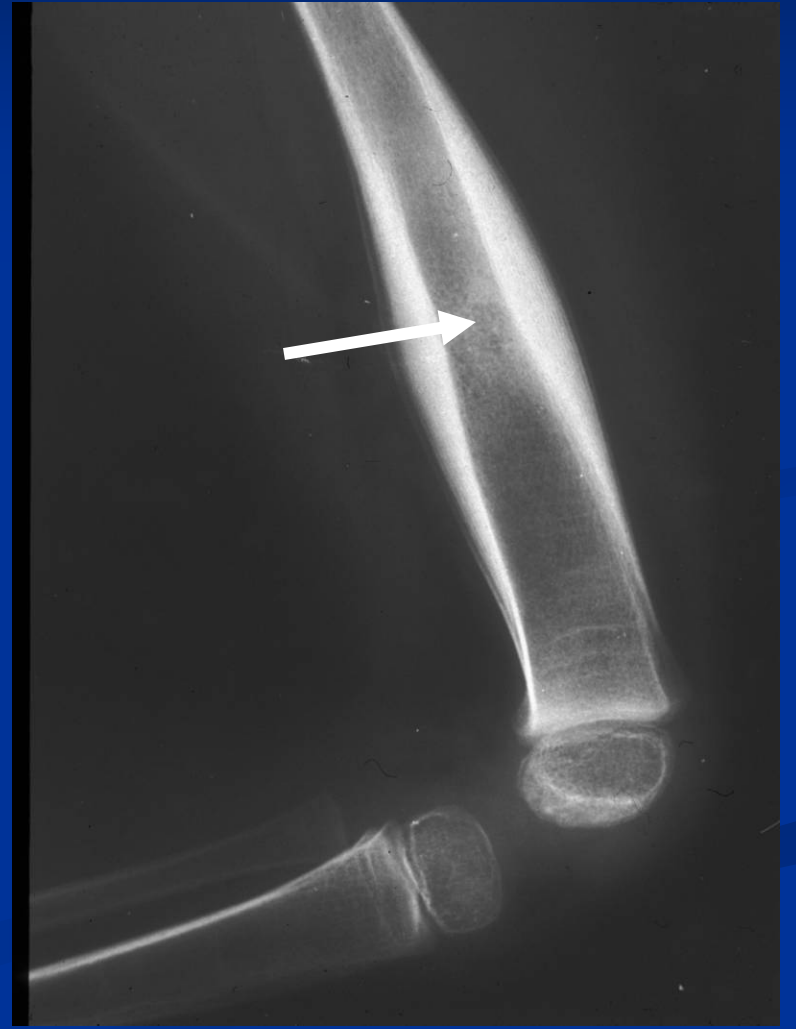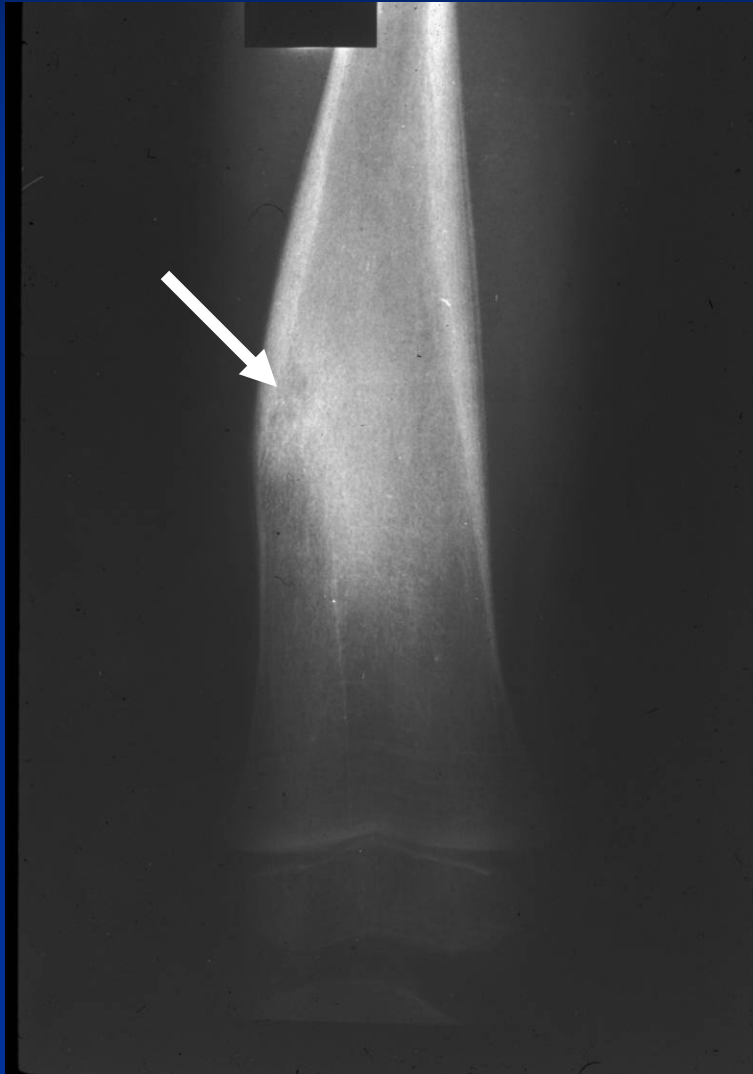# Osteoid Osteoma

## CT Shows Nidus with Extensive Mineralization

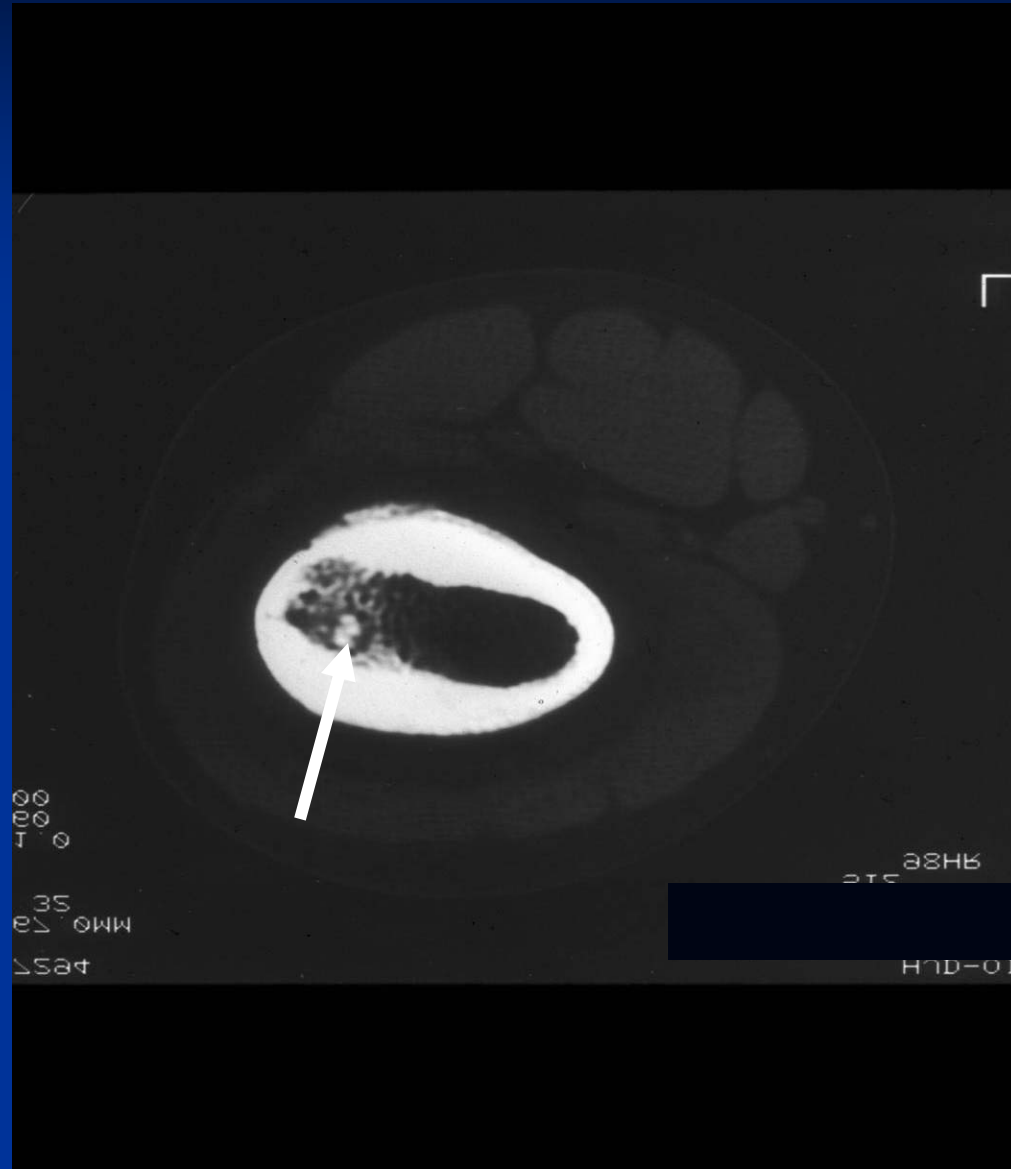




# Osteoid Osteoma



# Osteoid Osteoma



# Osteoid Osteoma

- **Radiology:**
- **Intraarticular/Cancellous Lesions**
  - Reactive sclerosis is often mild or absent
  - Associated joint effusion (lymphofollicular synovitis—can lead to cartilaginous and bone destruction; may see osteopenia, uniform narrowing of joint space; periarticular subperiosteal bone apposition; eventual changes like osteoarthritis)
  - Regional osteoporosis—Disuse osteoporosis
  - May have associated periostitis
  - May be diffusely hot on bone scan
  - Subperiosteal lesions present as juxtacortical masses

# Osteoid Osteoma

- **Osteoid Osteoma of Long Tubular Bones**
  - Usually within the proximal or distal portions of the shafts
  - 50% in lower extremities
    - Femoral neck—most common
    - Tibia—2<sup>nd</sup> most common site
    - Humerus is most commonly affected in upper extremity and the majority occur around the elbow
  - Can lead to overgrowth and/or angular deformity secondary to long standing hyperemia (usually in patients less than 5 years of age)
  - Deformity and leg length discrepancy may disappear after removal of the nidus

# Osteoid Osteoma

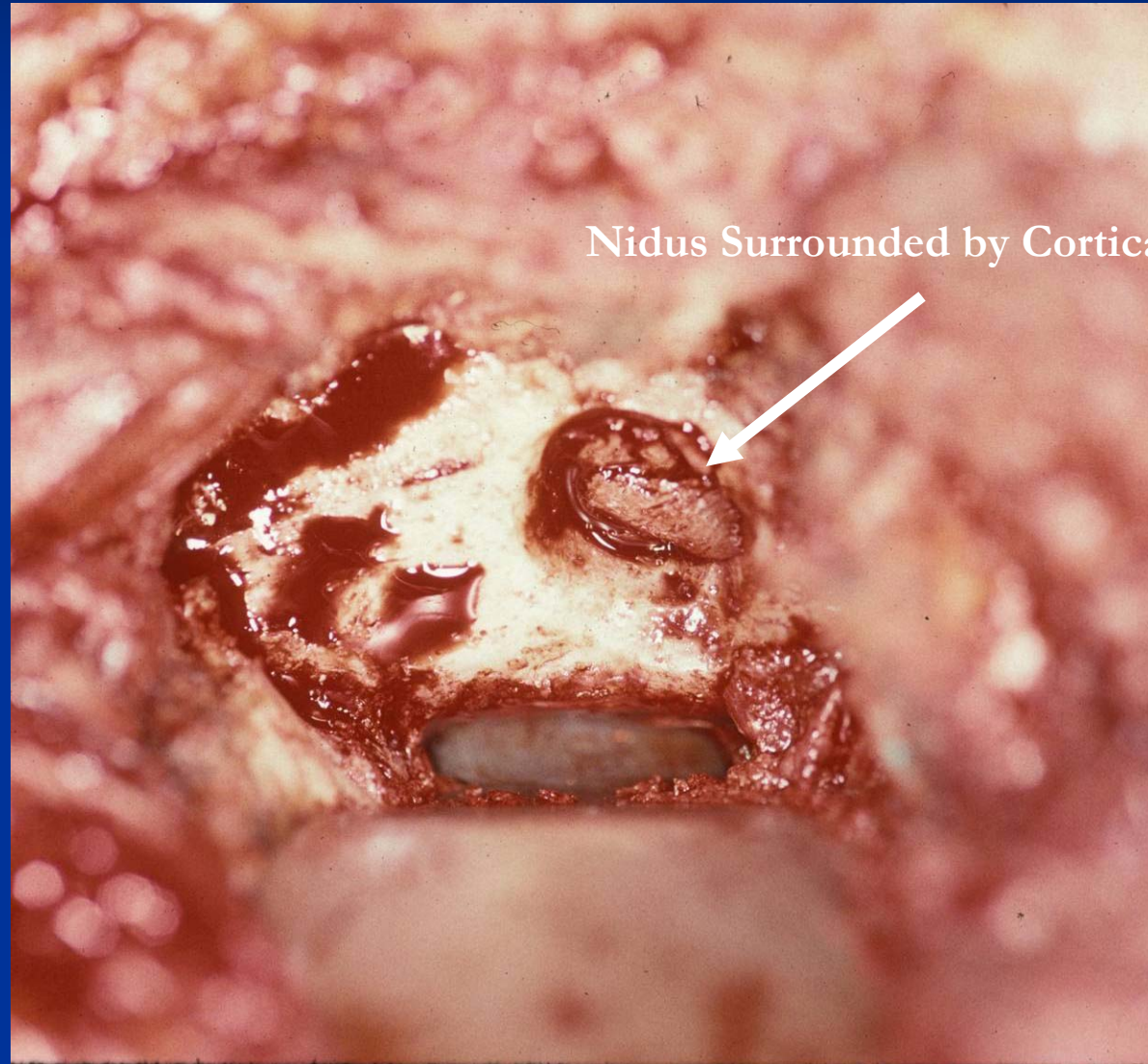
## ■ Pathology:

- Same regardless of anatomic site

## ■ Gross:

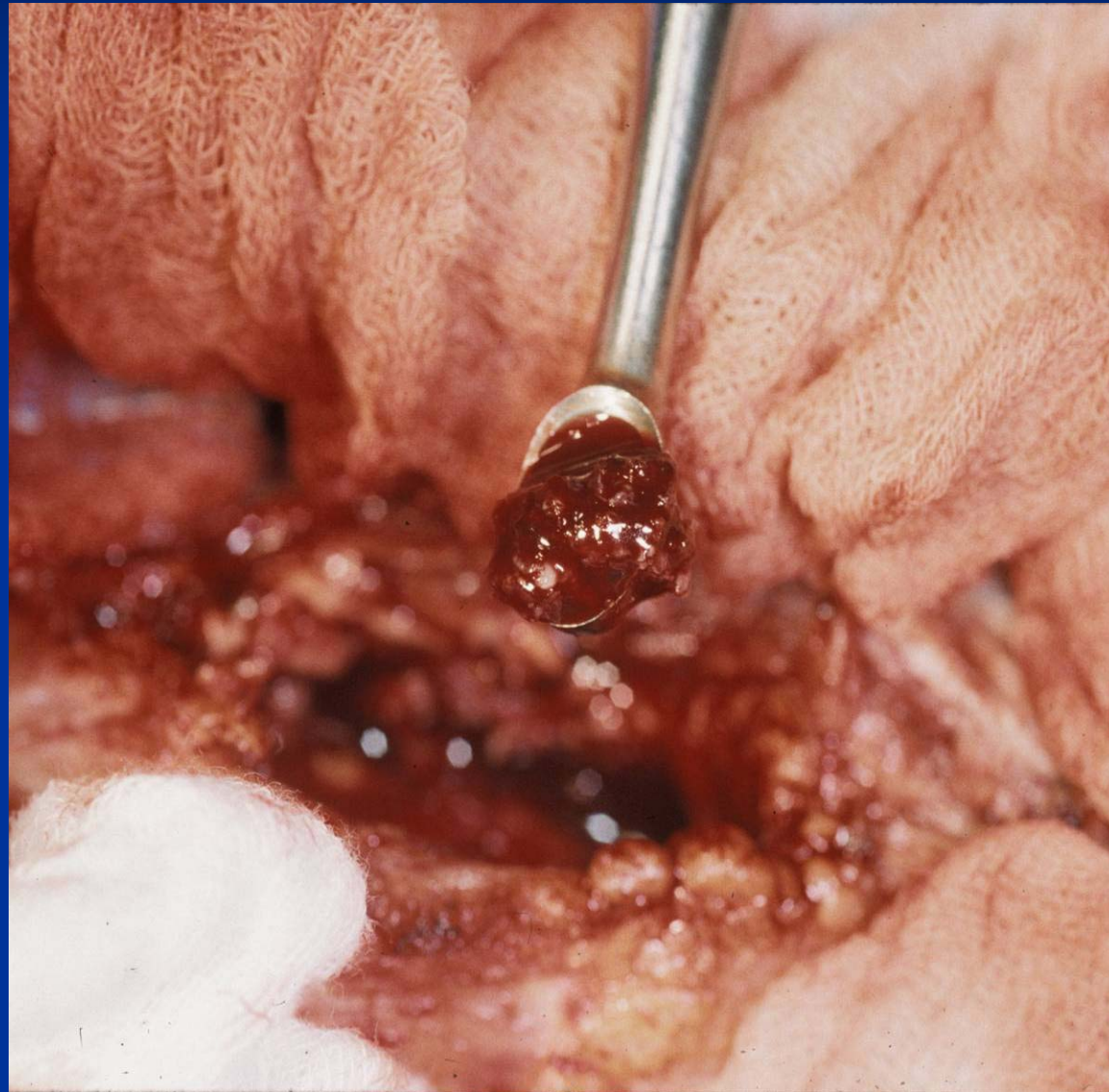- **Nidus:** yellowish to red and the size and shape of a pea; easily separated from its bed
- Friable, soft and granular to densely sclerotic
- Central portion of nidus is sometimes more sclerotic than peripheral portion
- Nidus is usually surrounded by dense sclerotic bone
- Nidus is rarely surrounded by cancellous bone

# Osteoid Osteoma Gross Photograph

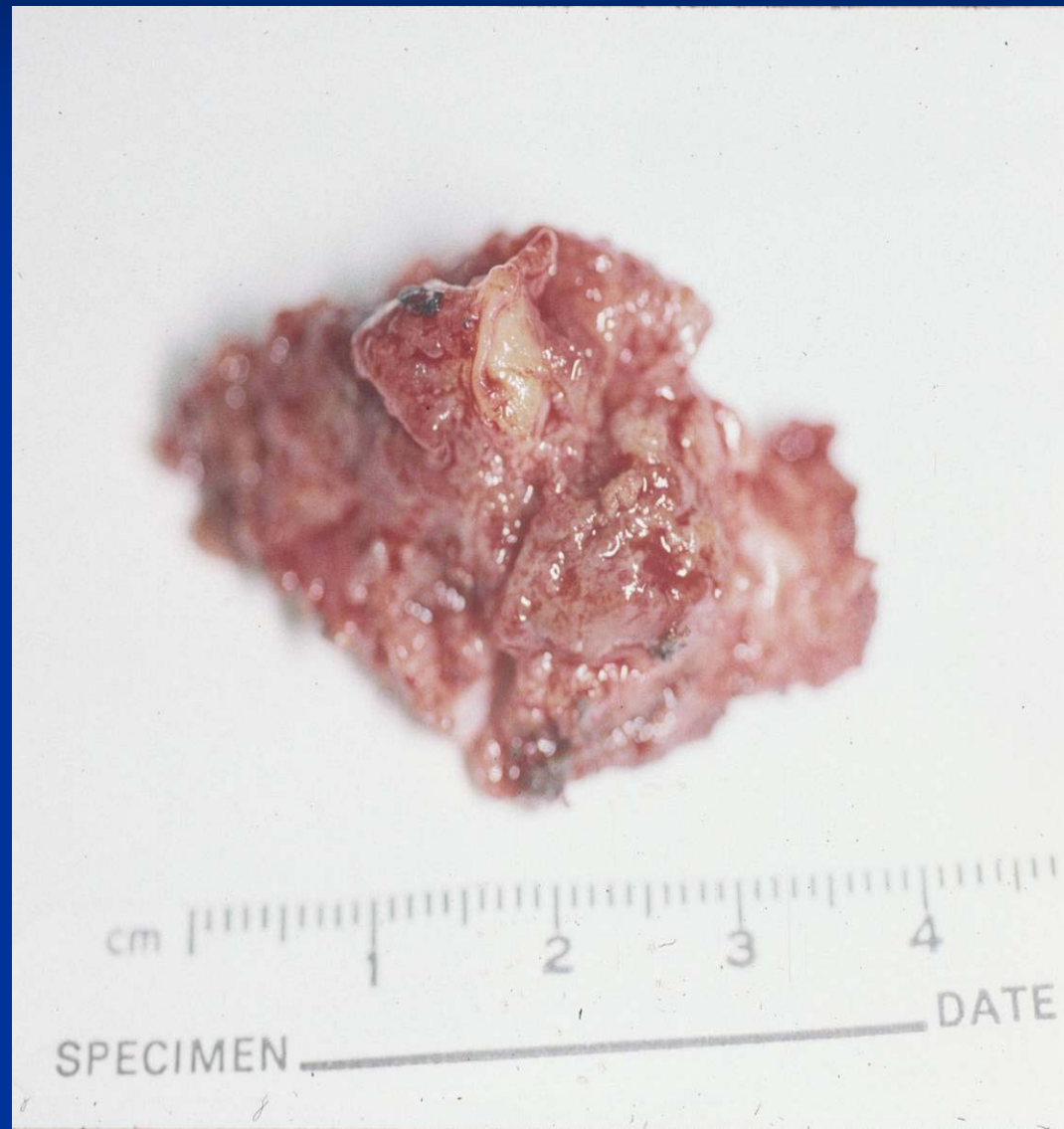

Nidus Surrounded by Cortical Bone

# Osteoid Osteoma Nidus

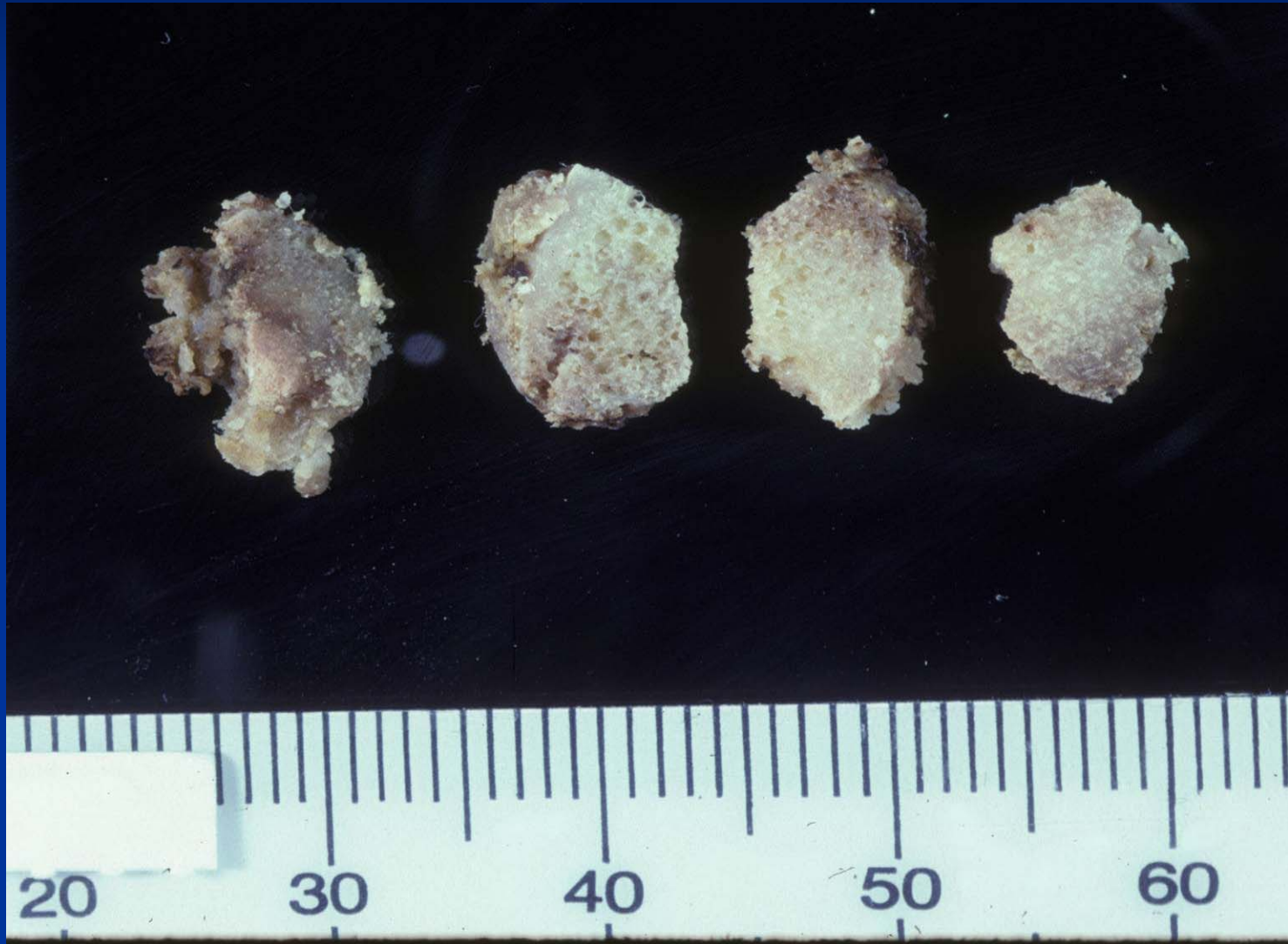

# Osteoid Osteoma





# Osteoid Osteoma



# Osteoid Osteoma

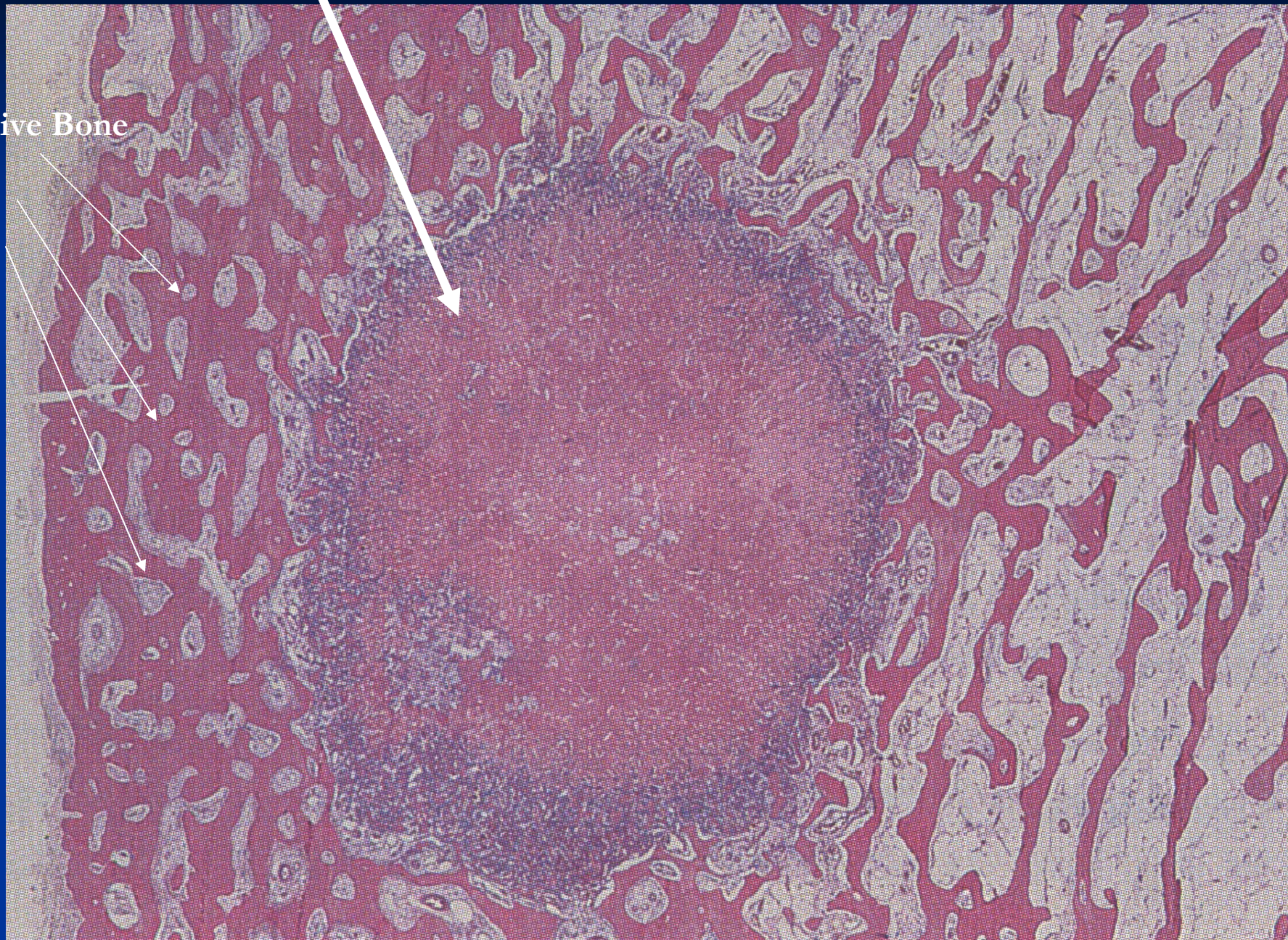
## ■ Pathology:

### ■ Microscopic:

- Interlacing network of trabeculae with different levels of mineralization in background of loose stromal, vascular connective tissue; Woven bone and osteoid with interconnected trabeculae
- Osteoblasts and osteoclasts rim the trabeculae

**Nidus**

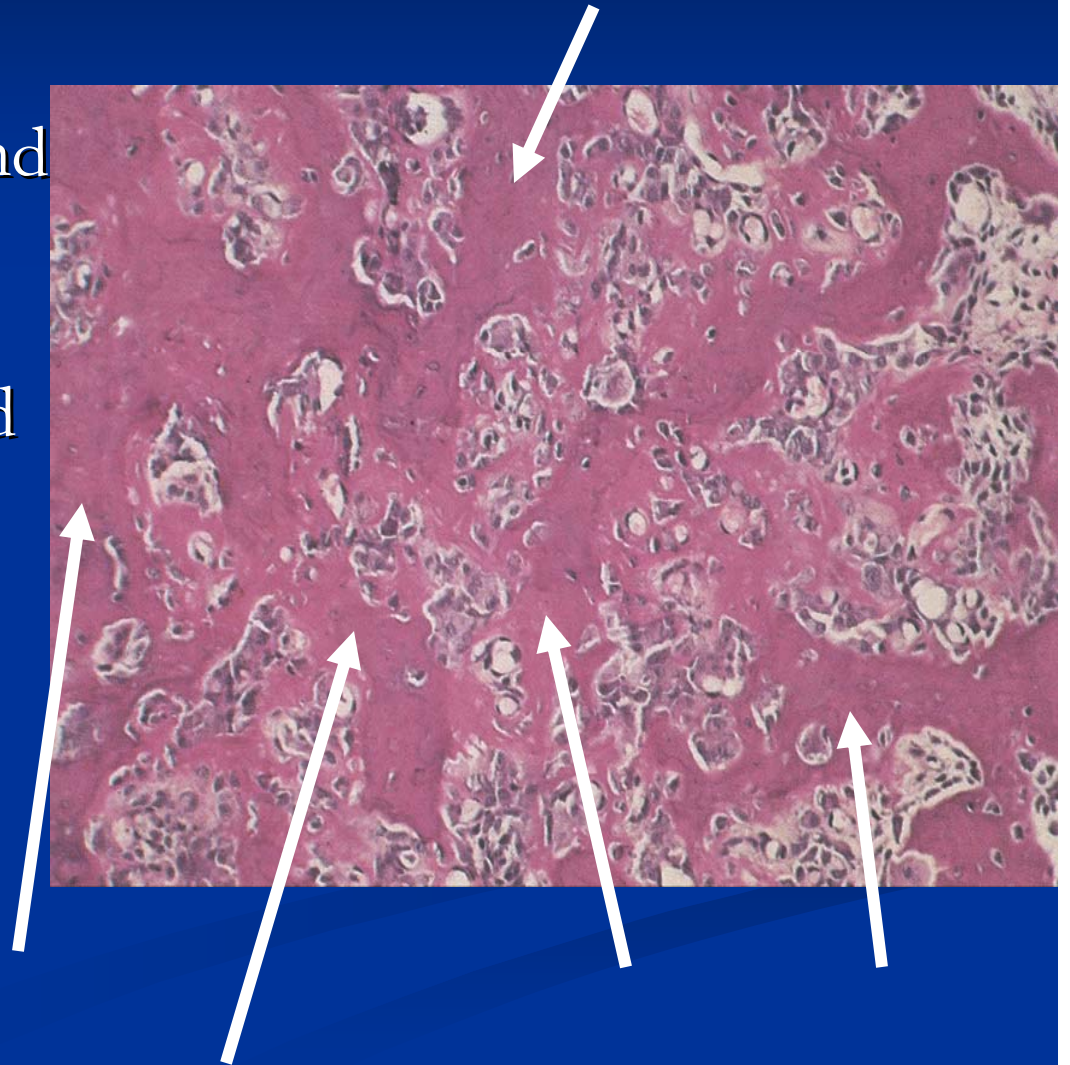
**Reactive Bone**

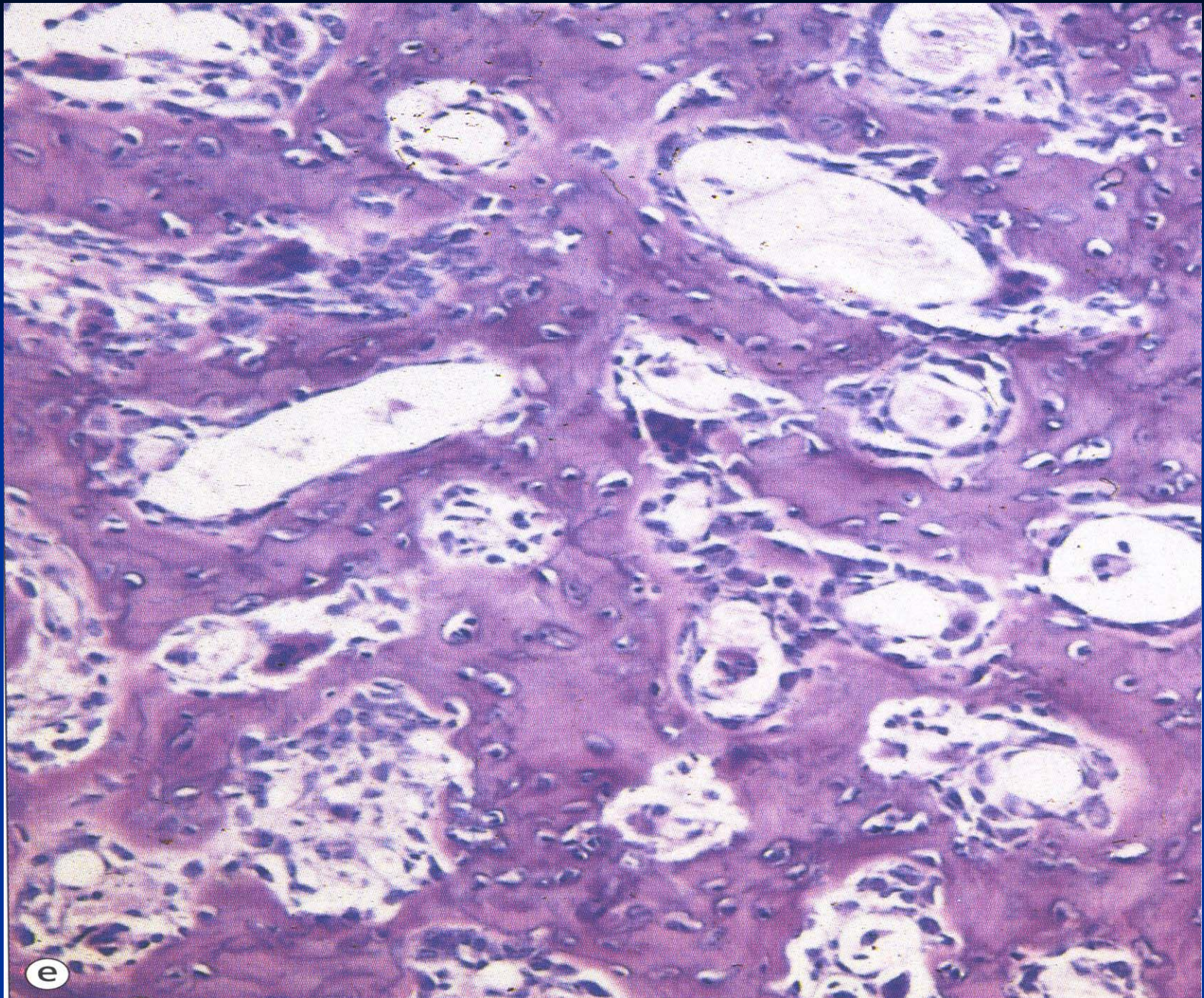


# Pathology Microscopic Osteoid

## Osteoma

- Interlacing trabeculae of woven (immature) bone and osteoid (Arrows)
- Bone is lined by plump, uniform, regularly arranged osteoblasts
- No mitotic figures
- No pleomorphism
- The intervening stroma is very well vascularized

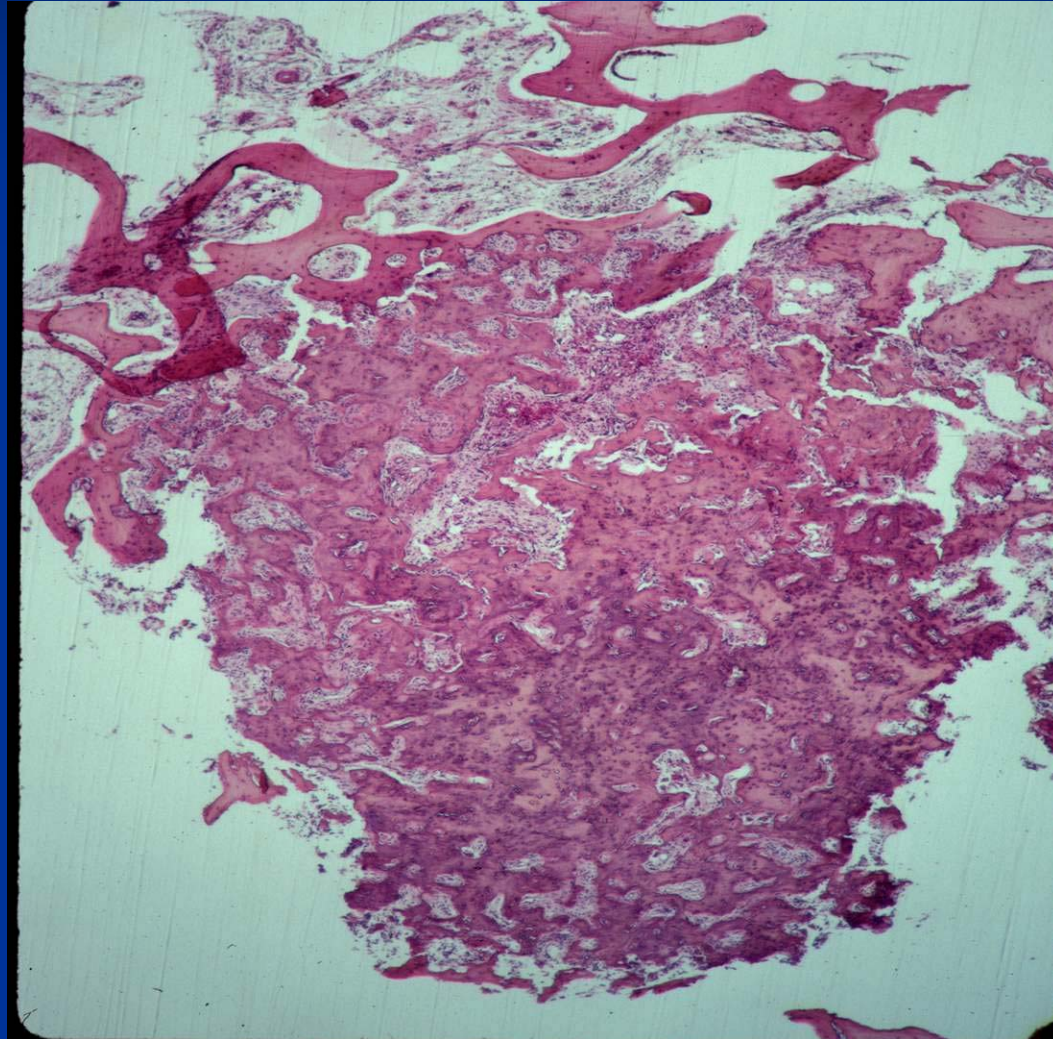




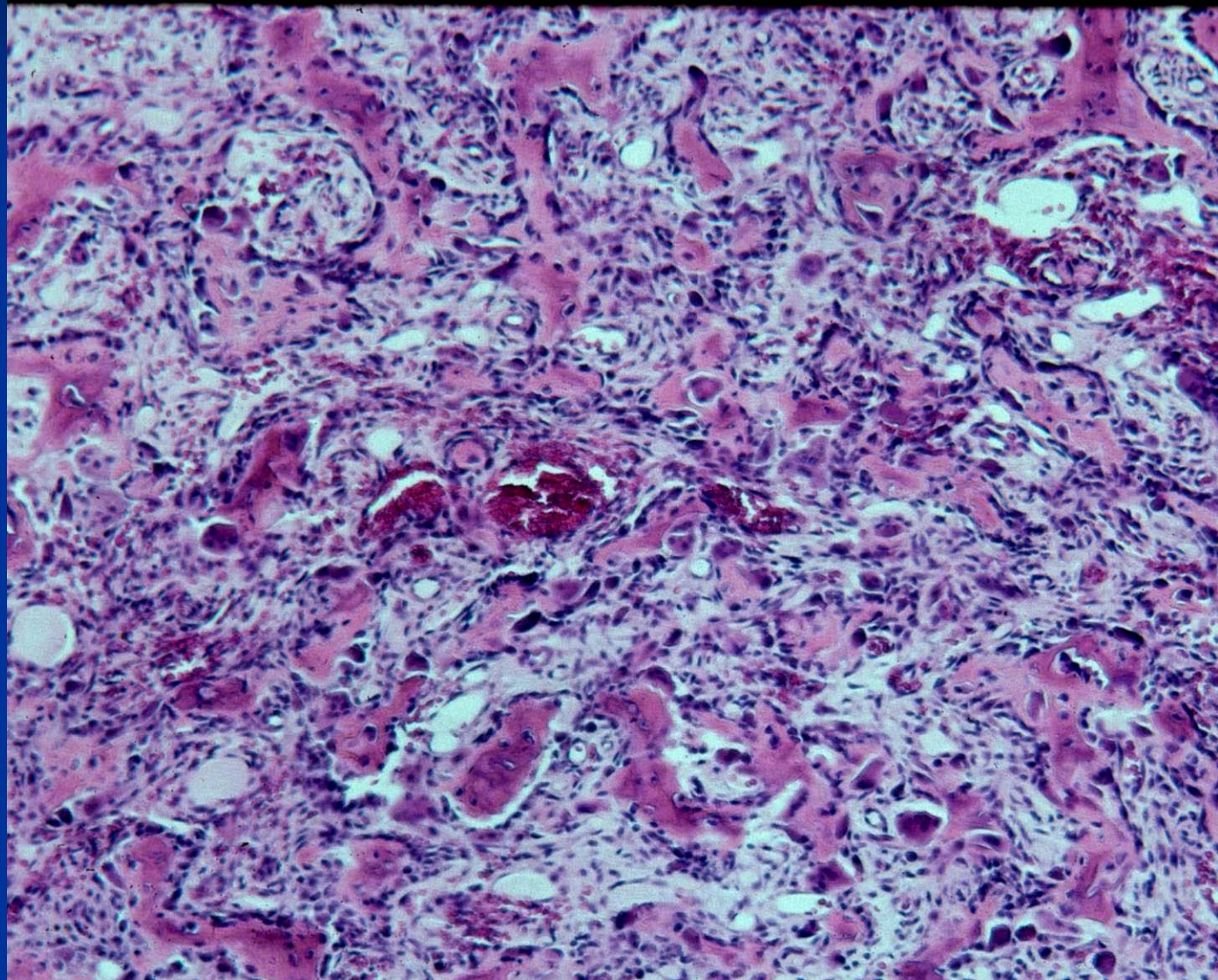
e

# Osteoid Osteoma Nidus

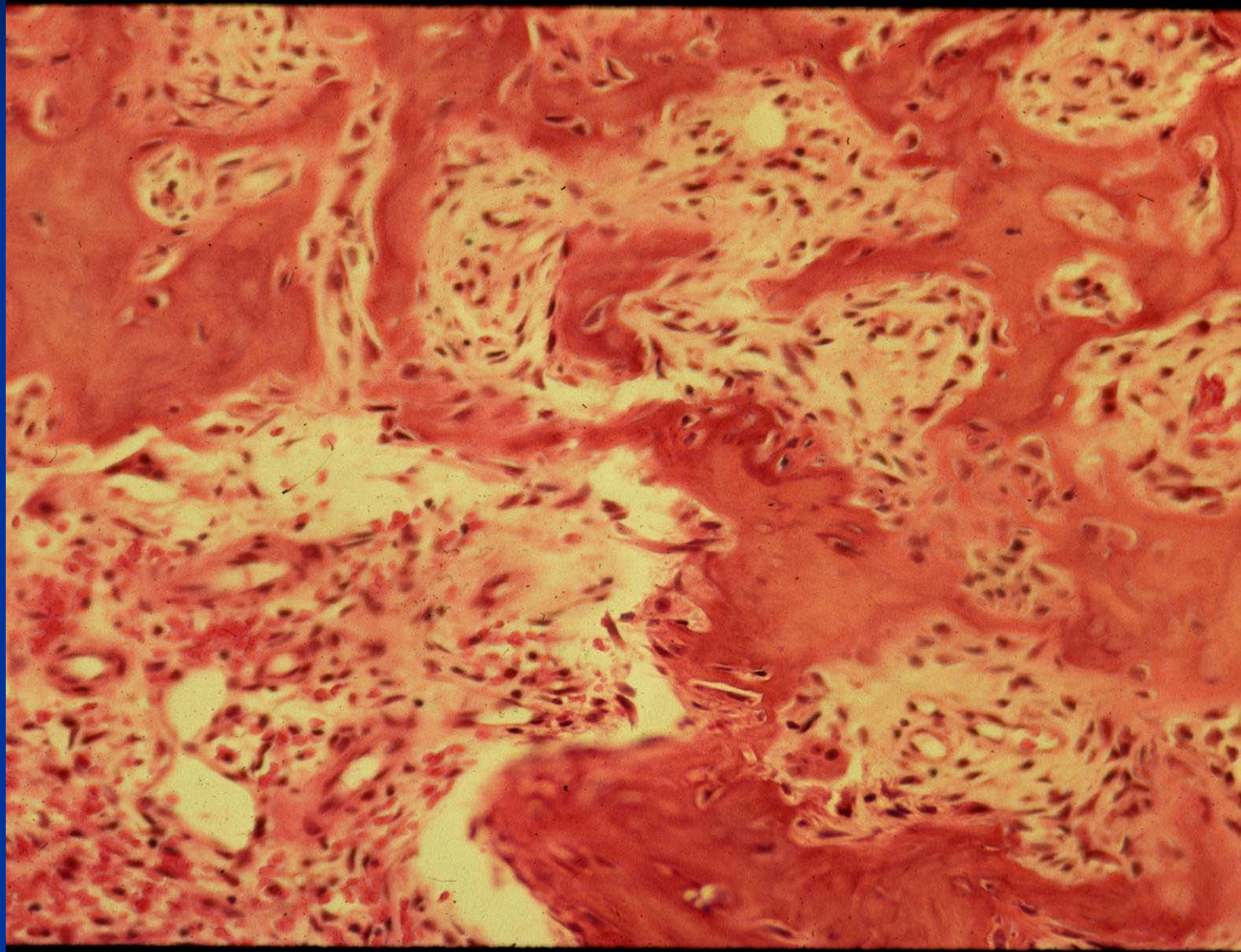
## Low Power



# Osteoid Osteoma Intermediate Power



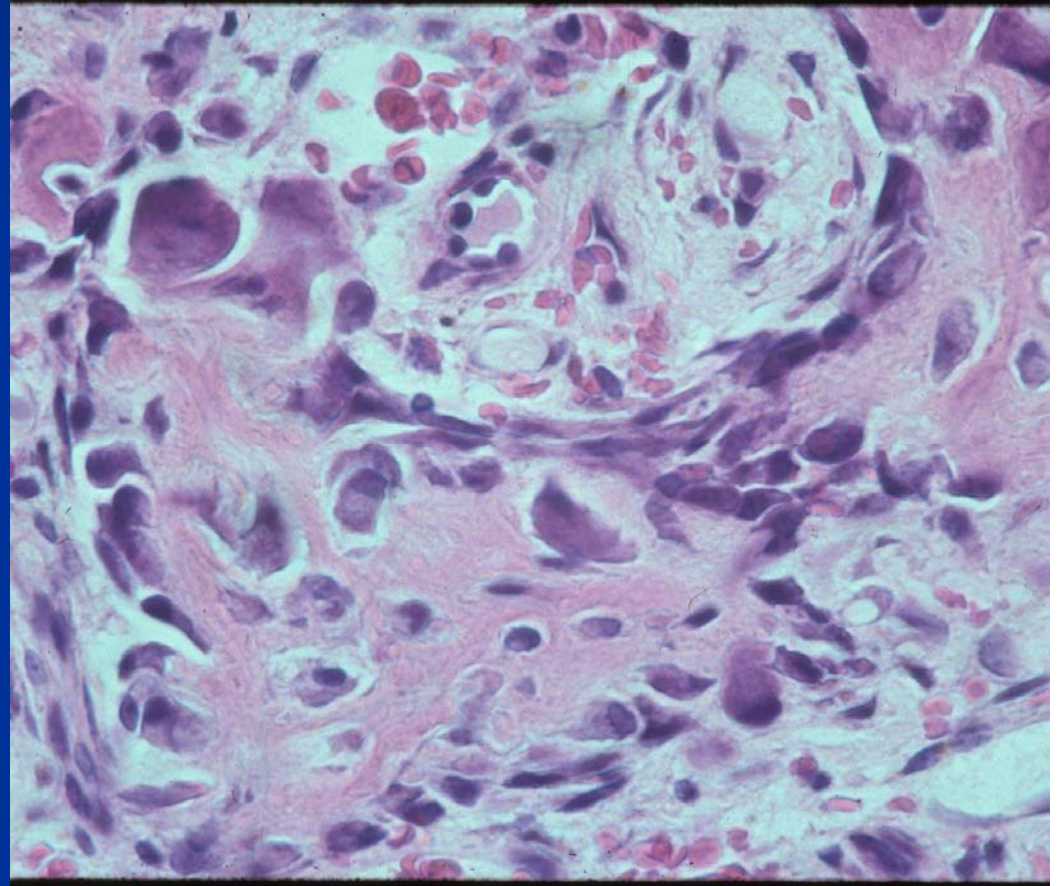
# Osteoid Osteoma



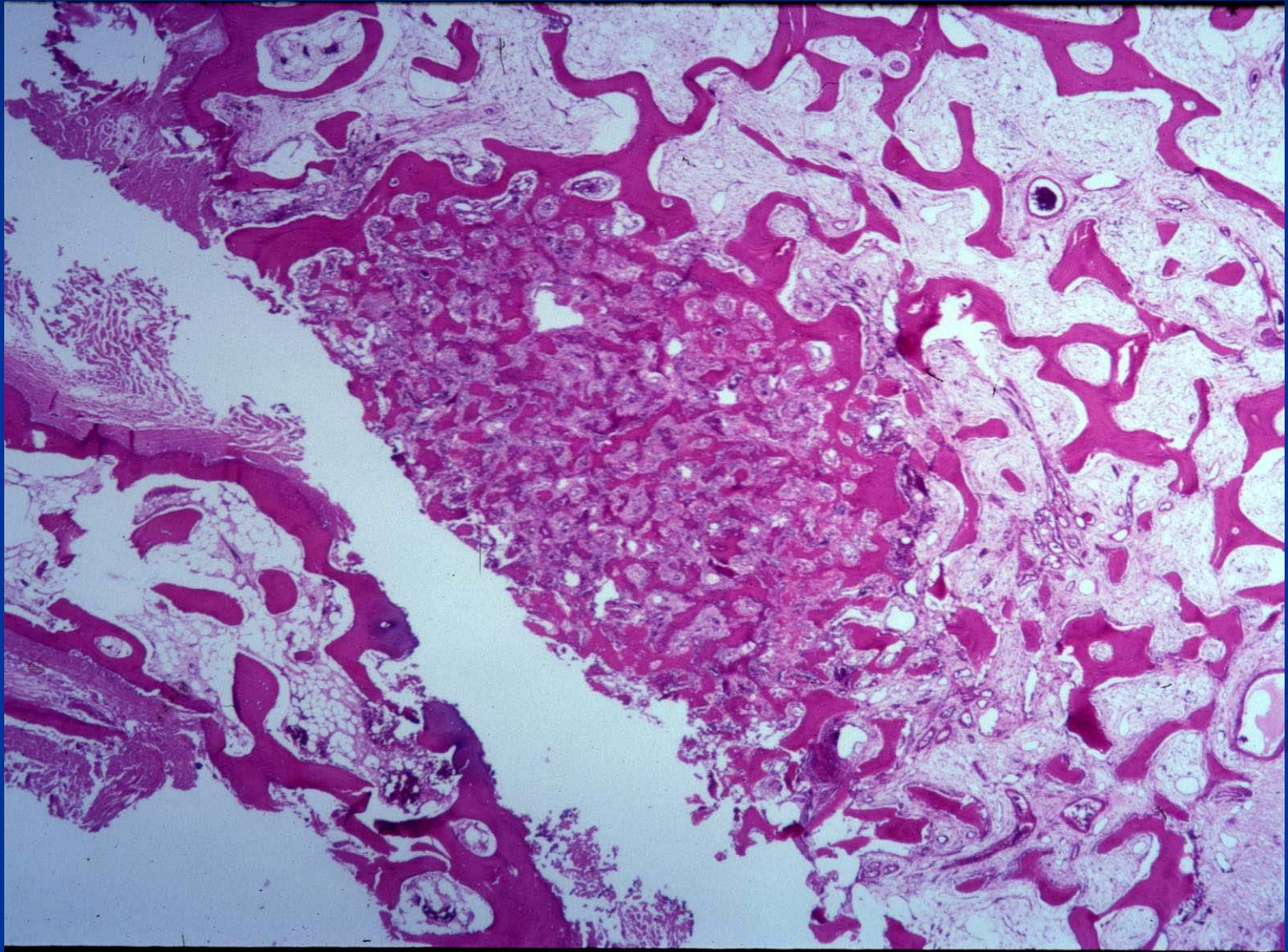


# Osteoid Osteoma High Power

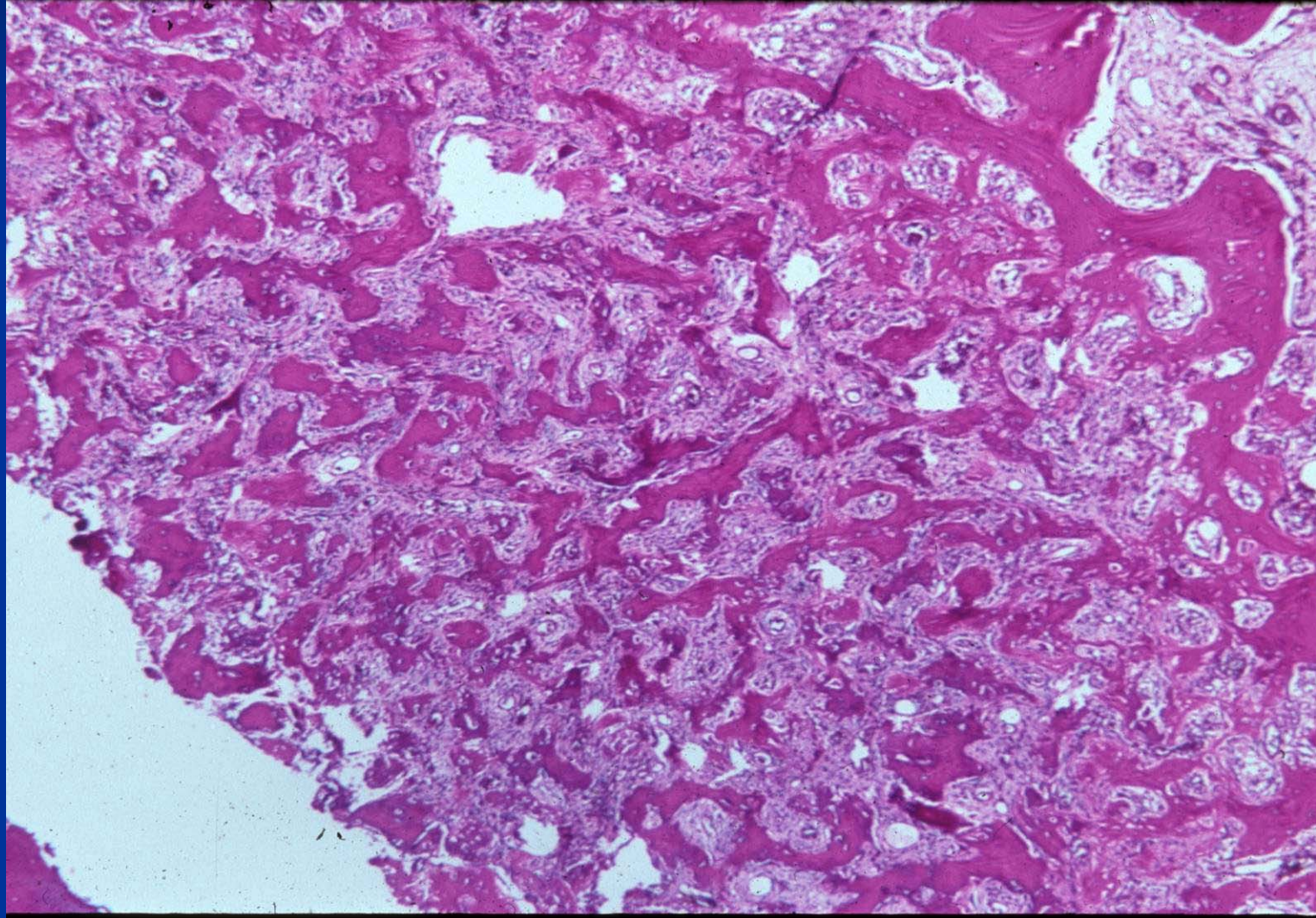
- This is a high power view
- Notice the plump, regularly arranged osteoblasts that surround and line the woven bone
- There are no mitoses and minimal pleomorphism



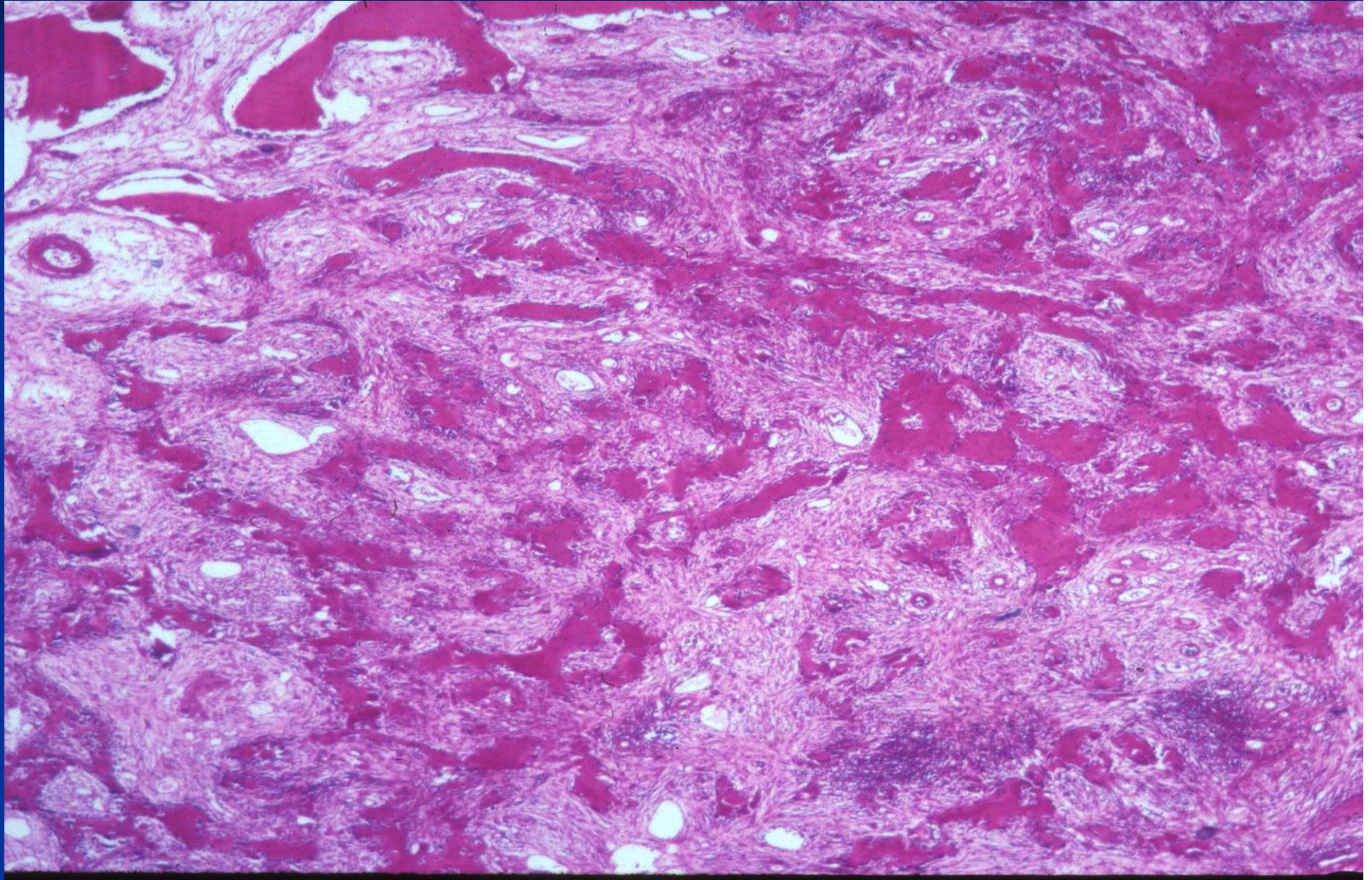
# Osteoid Osteoma



# Osteoid Osteoma



# Osteoid Osteoma



# Osteoid Osteoma

- Differential DX of Cortical Osteoid Osteoma
  - Brodie Abscess
  - Stress Fracture
  - Eosinophilic Granuloma
  - Intracortical Hemangioma
  - Bone Island
  - Stress Fracture
  - Intracortical Osteosarcoma
  - Ewing's Sarcoma

## DIFFERENTIAL DIAGNOSIS

### OSTEIOD OSTEOMA

#### Stress Fracture

radiolucent line perpendicular or at angle to cortex (usually posterior tibia)

#### Brodie Abscess

serpentine tract, lesion close to growth plate

#### Bone Island

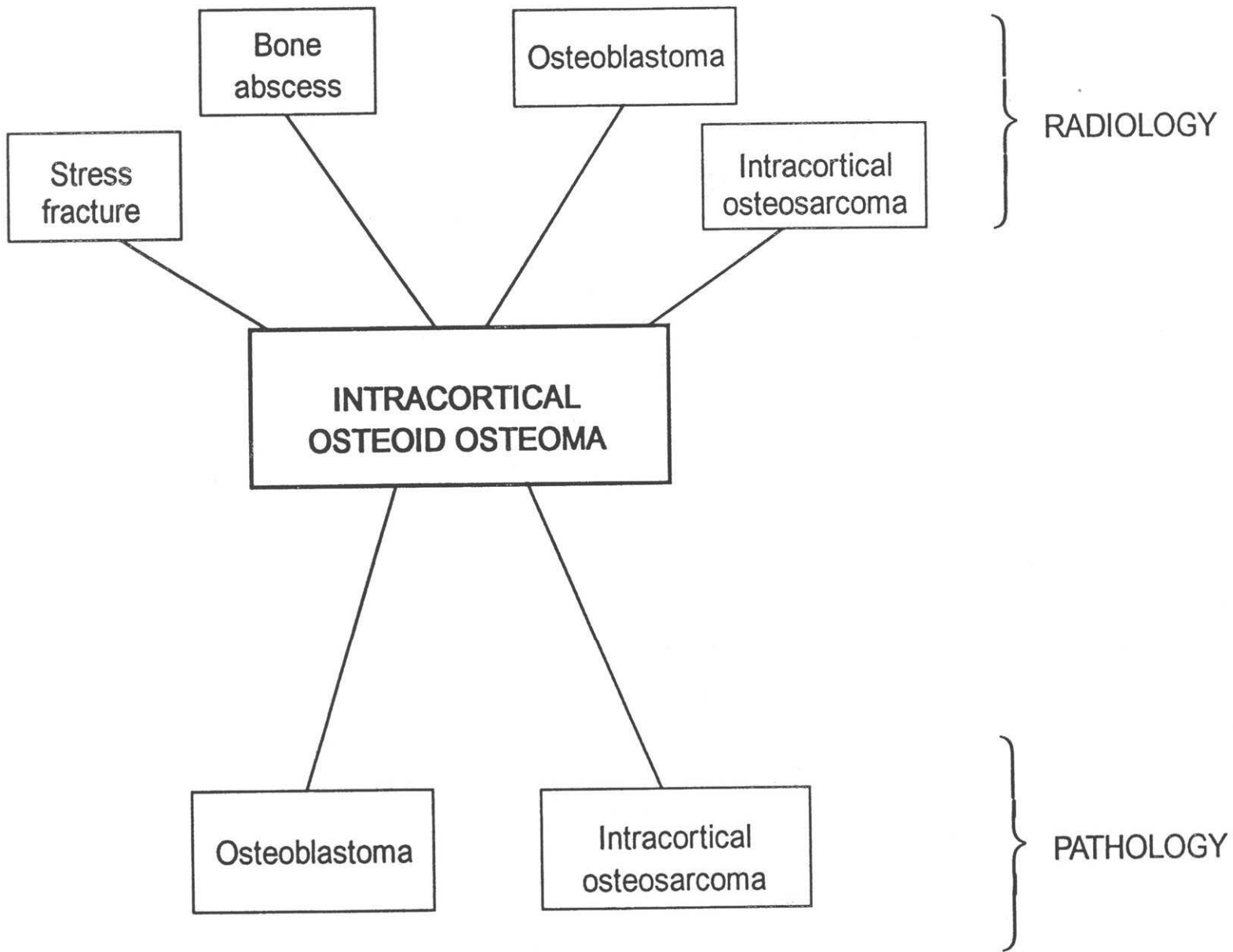
normal bone scan (90% of time)

#### Osteoblastoma

lesion larger than 2 cm, reactive sclerosis not striking

**TABLE 2.** *Differential diagnosis of osteoid osteoma*

Condition (lesions)	Radiologic features	Pathologic features
Cortical osteoid osteoma	Radiolucent nidus, round or elliptical, surrounded by radiodense reactive sclerosis. Solid or laminated (but not interrupted) periosteal reaction. Scintigraphy invariably shows increased uptake of radiotracer. "Double-density" sign.	Nidus composed of osteoid tissue or mineralized immature bone. Osteoid matrix and bone form irregular islets and are surrounded by a richly vascular fibrous stroma. The islets have a trabecular structure, whose thickness ranges from thin and delicate to broad and sclerotic. The stroma shows prominent osteoblastic and osteoclastic activity. Perilesional sclerosis composed of dense bone exhibiting various maturation patterns.
Medullary osteoid osteoma	Radiolucent (or with central calcification) nidus, without or with only minimal perinidal sclerosis. Usually no or only minimal periosteal reaction. Scintigraphy—as above.	
Subperiosteal osteoid osteoma	Central radiolucent or sclerotic nidus with or without reactive sclerosis. Occasionally shaggy, crescent-like focus of periosteal reaction. Scintigraphy—increased uptake of radiotracer.	As above
Intracapsular (periarticular) osteoid osteoma	Periarticular osteoporosis. Premature onset of osteoarthritis. Nidus may or may not be visualized. Scintigraphy—as above.	
Osteoblastoma	See Table 3.	See Table 3.
Stress fracture (cortical)	Linear radiolucency runs perpendicular or at an angle to the cortex. Scintigraphy—increased uptake of radiotracer.	Features of bone repair: osteoid and cartilaginous callus, osteoblastic and osteoclastic activity.
Bone abscess (Brodie)	Irregular in outline radiolucency, usually with a sclerotic rim, associated with serpentine, linear tract. Predilection for metaphysis and the ends of tubular bones. Scintigraphy—increased uptake of radiotracer. MRI—on T1 WI a well-defined low-to-intermediate-signal lesion outlined by a low-intensity rim. On T2 WI a very bright homogeneous signal, outlined by a low-signal rim.	Necrotic tissue, giant cells, granulocytes, lymphocytes, plasma cells, and histiocytes.
Bone island (enostosis)	Homogeneously dense, sclerotic focus in cancellous bone with distinctive radiating streaks (thorny radiation) that blend with the trabeculae of the host bone. Scintigraphy—usually no increased uptake. MRI—low-intensity signal on T1 and T2 WI.	Focus of mature, compact bone with thickened peripheral trabeculae that blend with trabeculae of the spongiosa. Wide bands of parallel or concentric lamellae; marrow spaces resembling Haversian canals.
Intracortical osteosarcoma	Intracortical radiolucent focus surrounded by zone of sclerosis. Occasionally central "fluffy" densities. Cortex thickened or bulged. Scintigraphy—increased uptake of radiotracer.	Consistent with an osteoblastic osteosarcoma with focal evidence of chondroid and fibroblastic differentiation. Permeation of Haversian systems. "Trapping" of lamellar bone within the tumor.

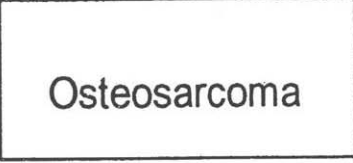
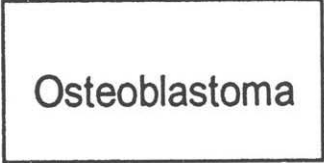
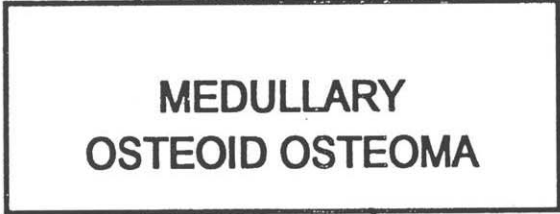


A



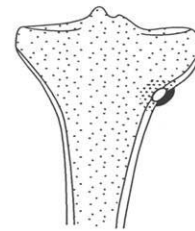


RADIOLOGY

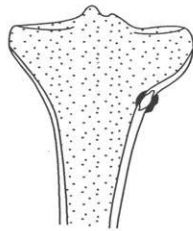


PATHOLOGY

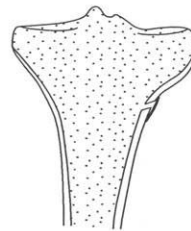
B



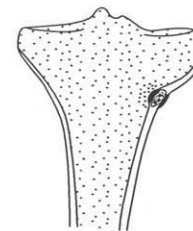
**Cortical  
Osteoid Osteoma**



**Cortical  
Bone Abscess**

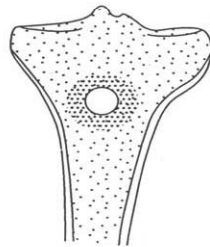


**Stress  
Fracture**

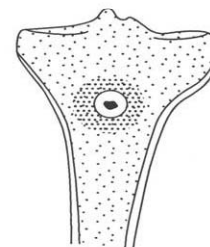


**Intracortical  
Osteosarcoma**

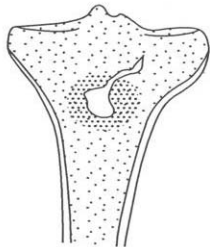
**A**



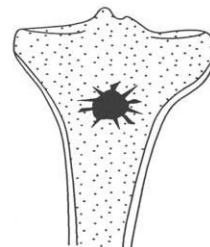
**Medullary  
Osteoid Osteoma**



**Medullary Osteoid Osteoma  
with Sclerotic Center**



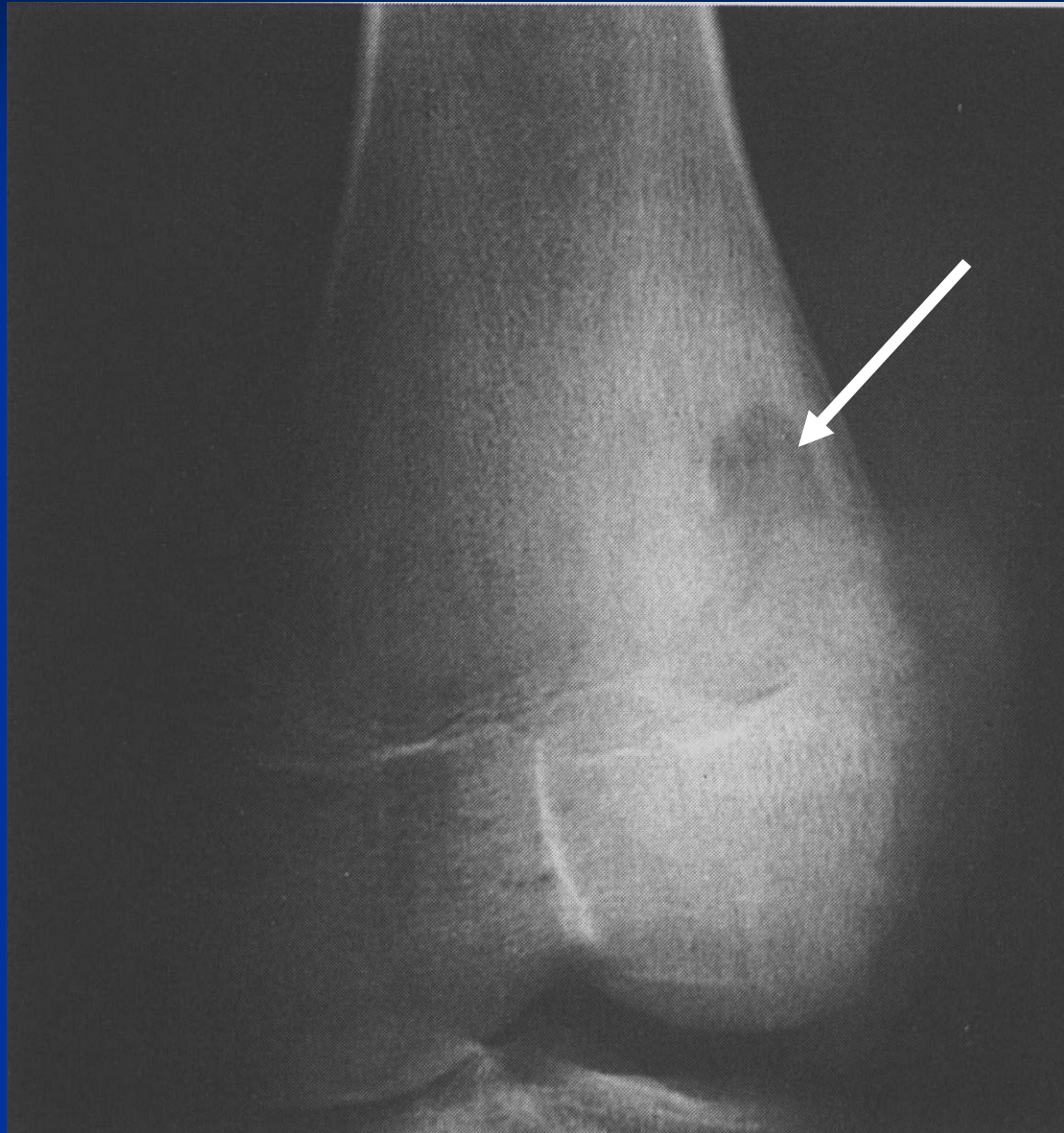
**Brodie Abscess**



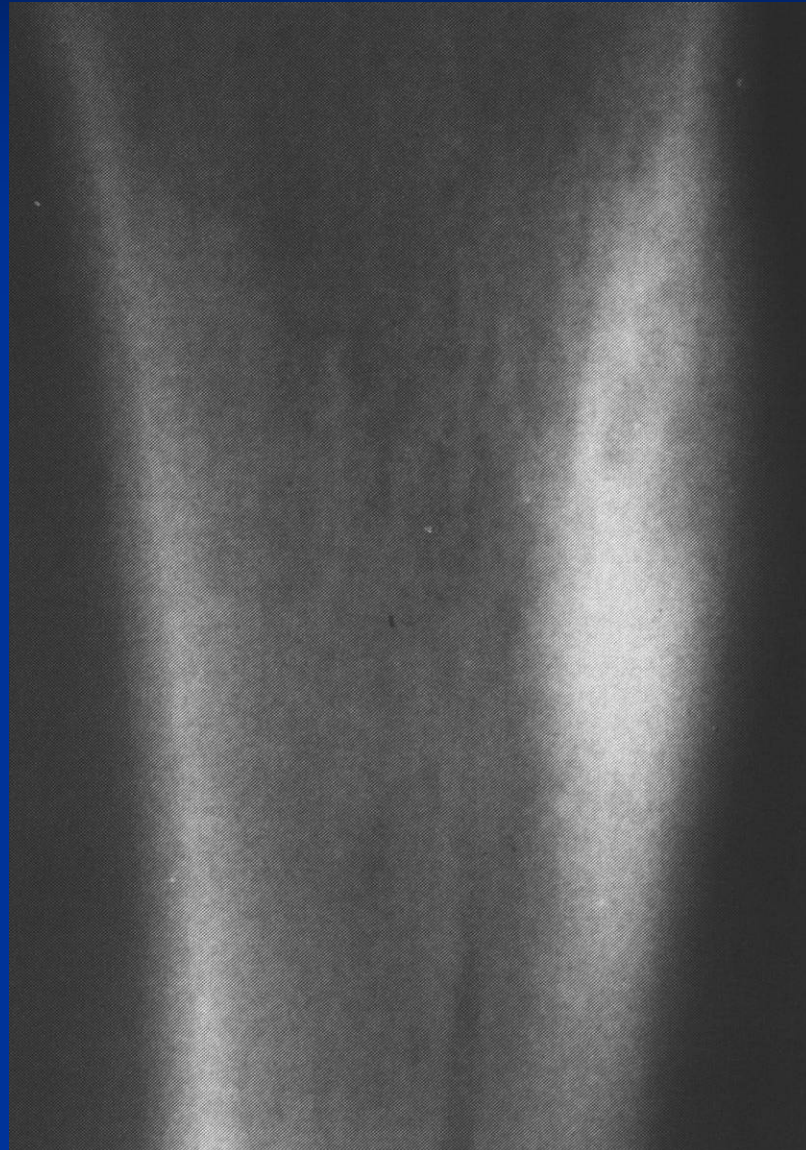
**Bone Island  
(Enostosis)**

**B**

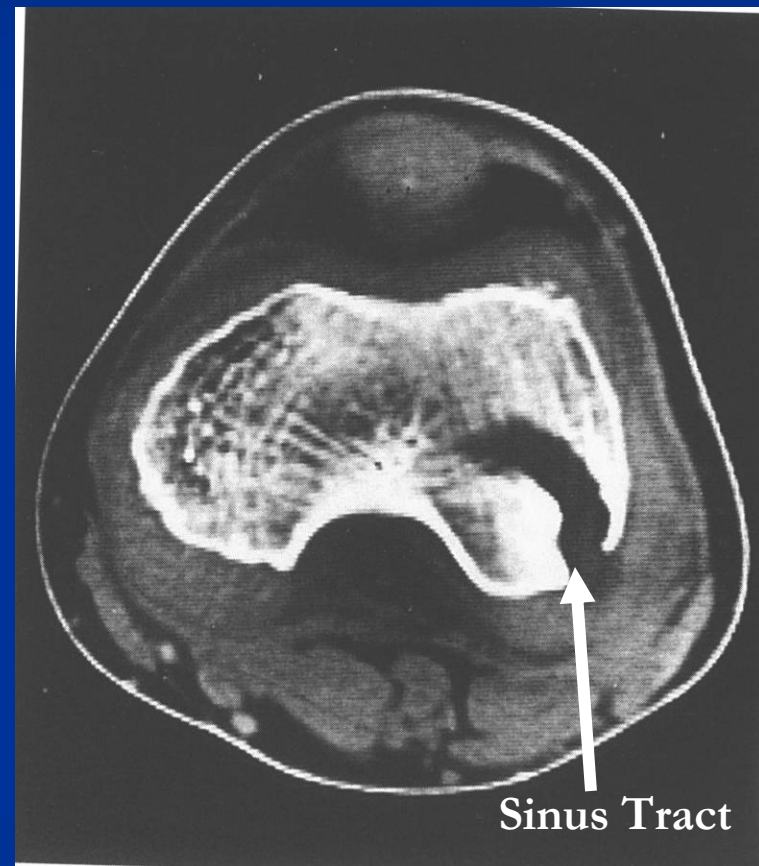
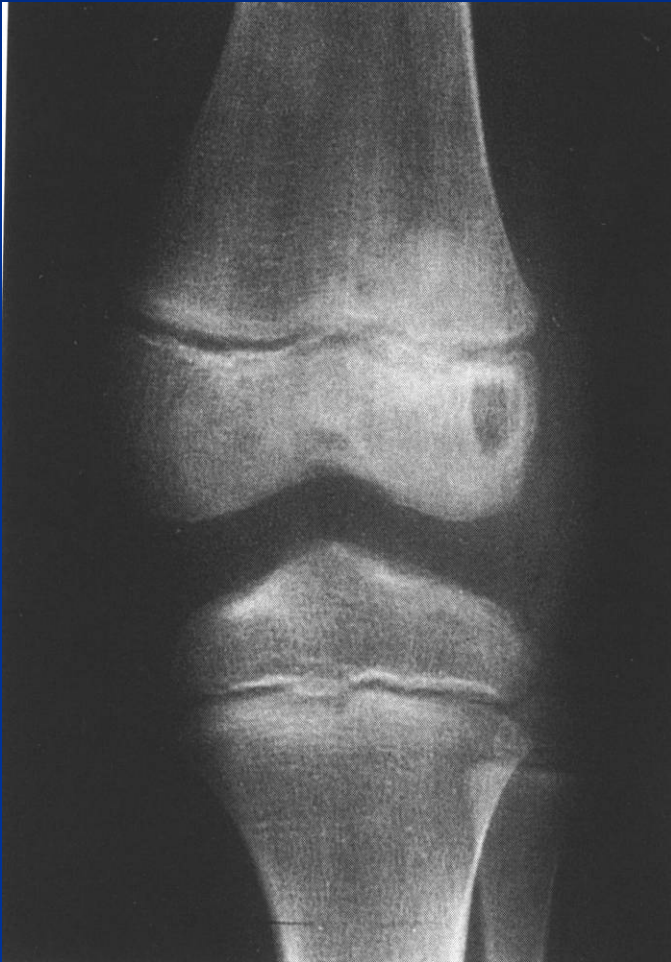# Brodie's Abscess



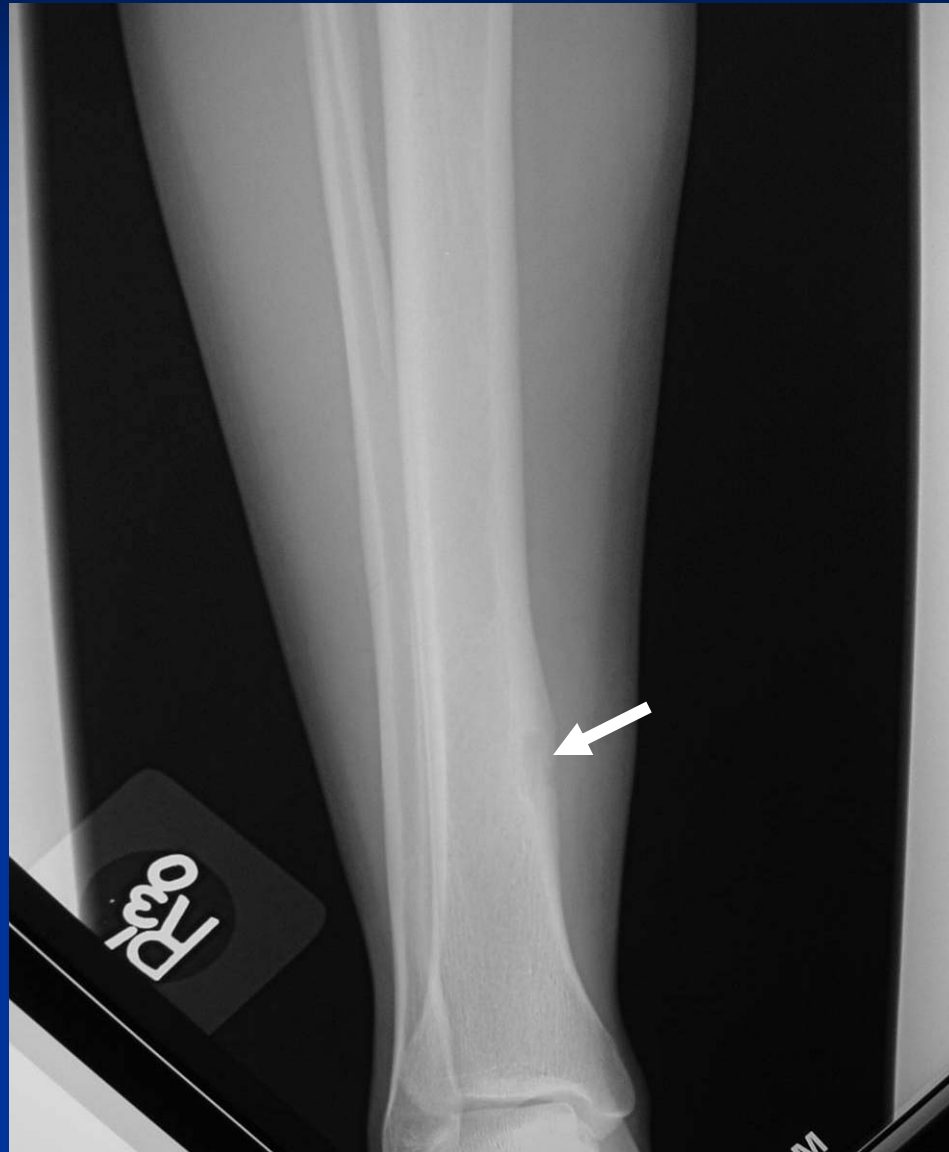# Bone Abscess



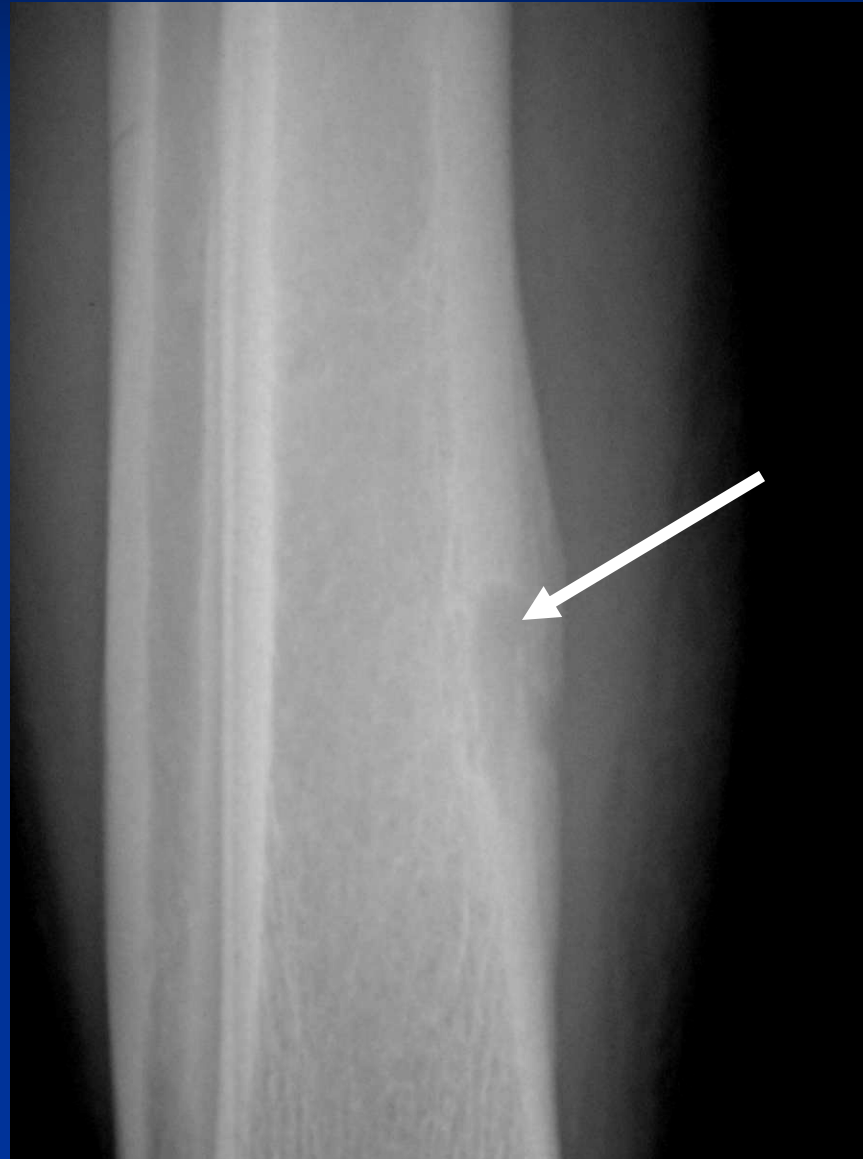
# Bone Abscess



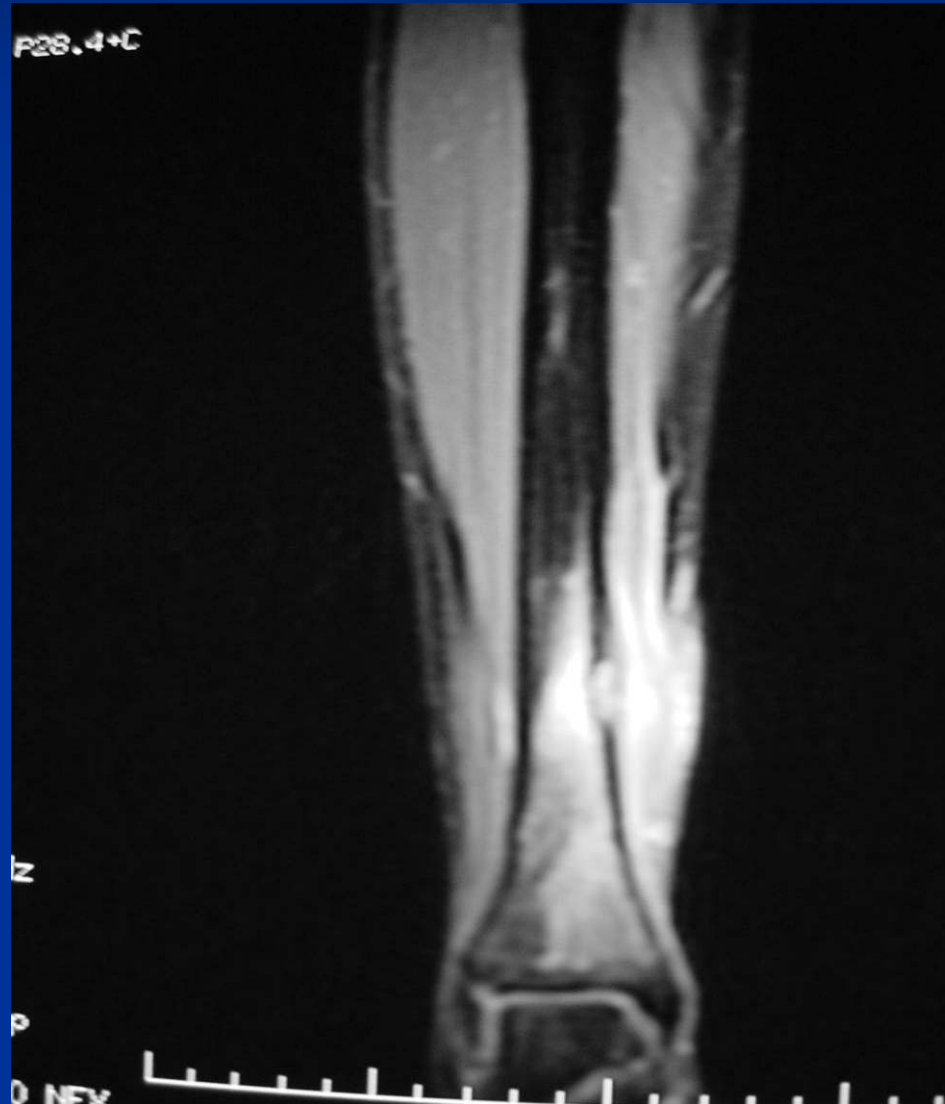
# Brodie's Abscess



# Brodie's Abscess

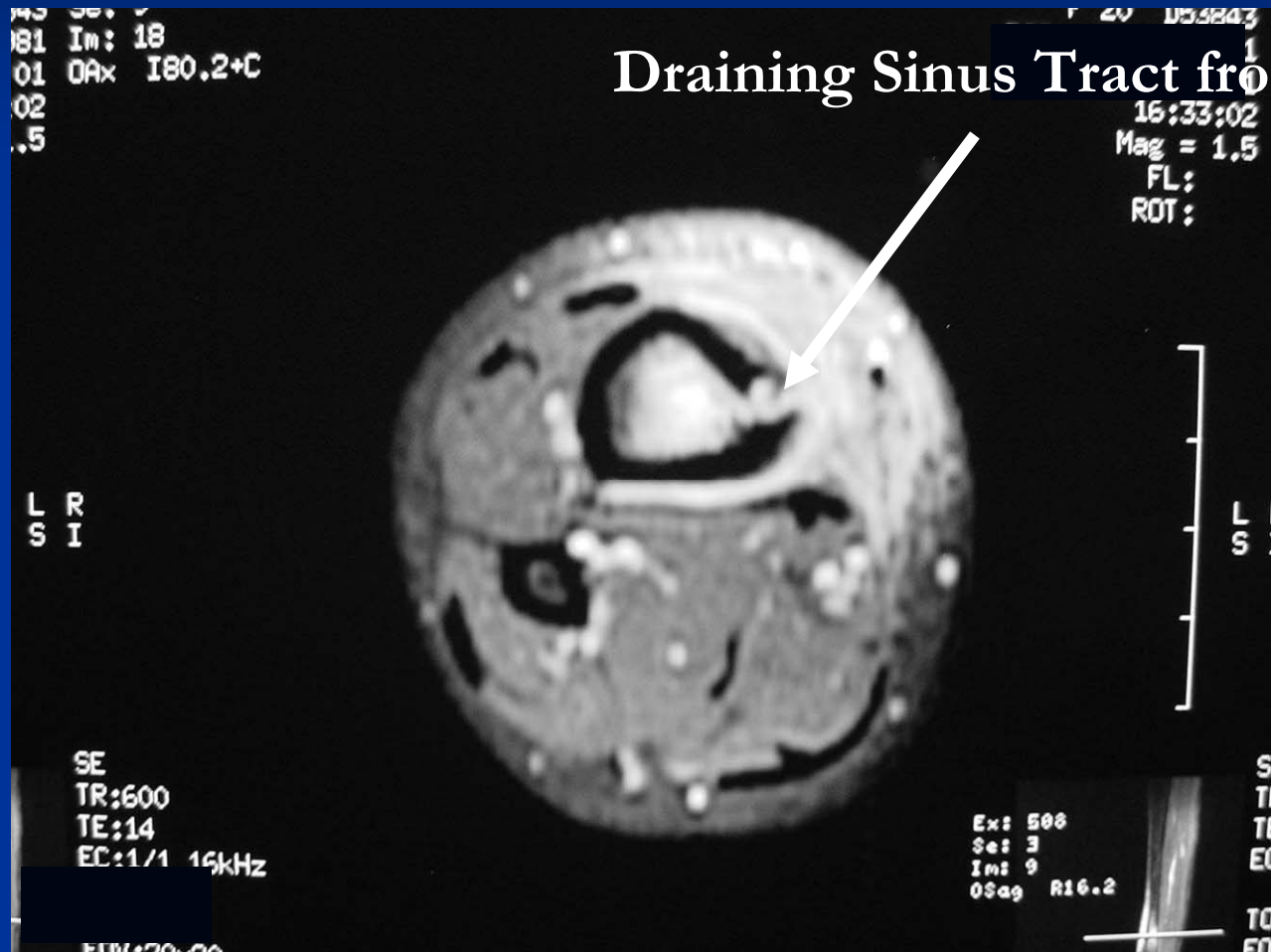


# Brodie's Abscess

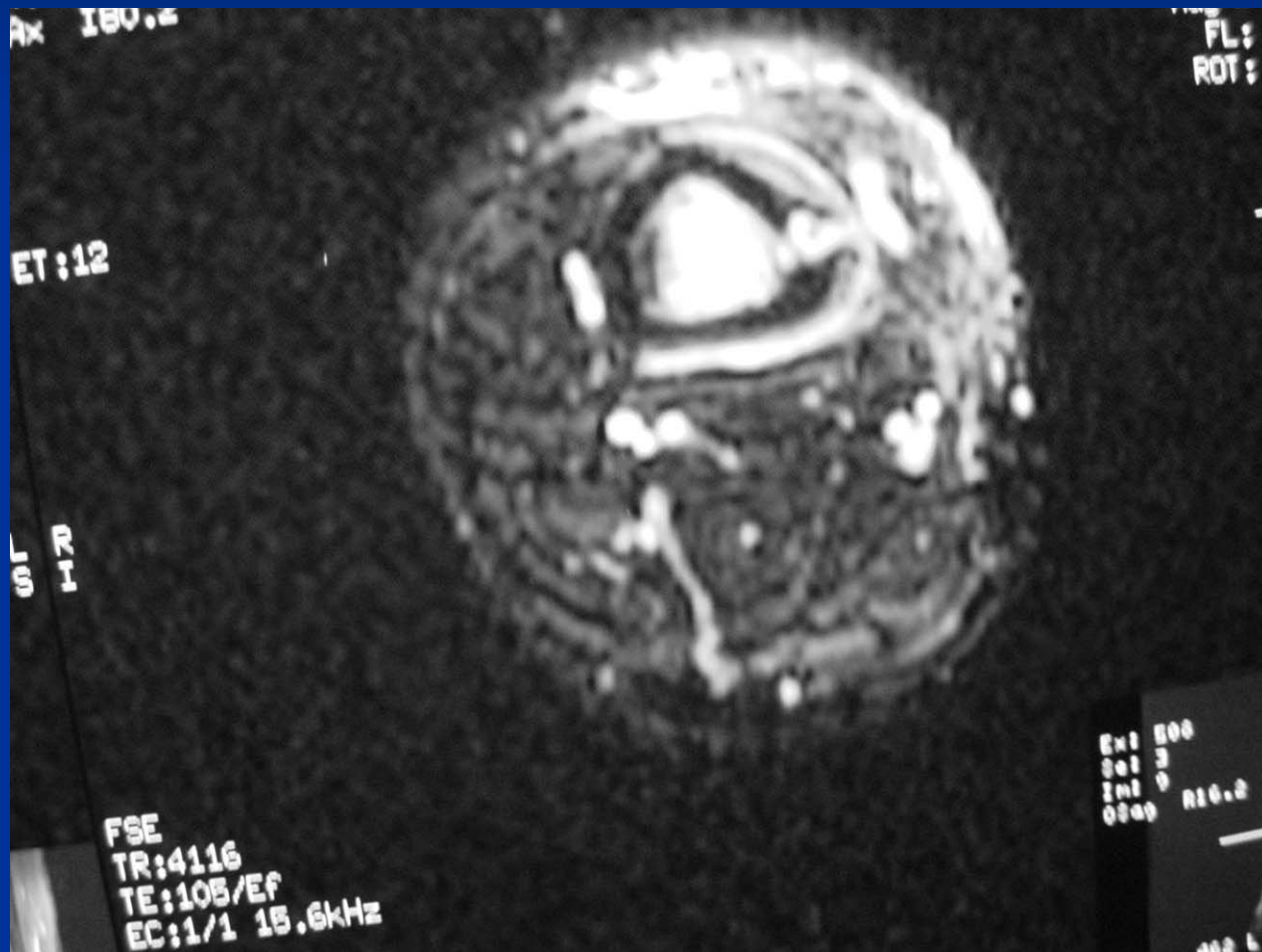




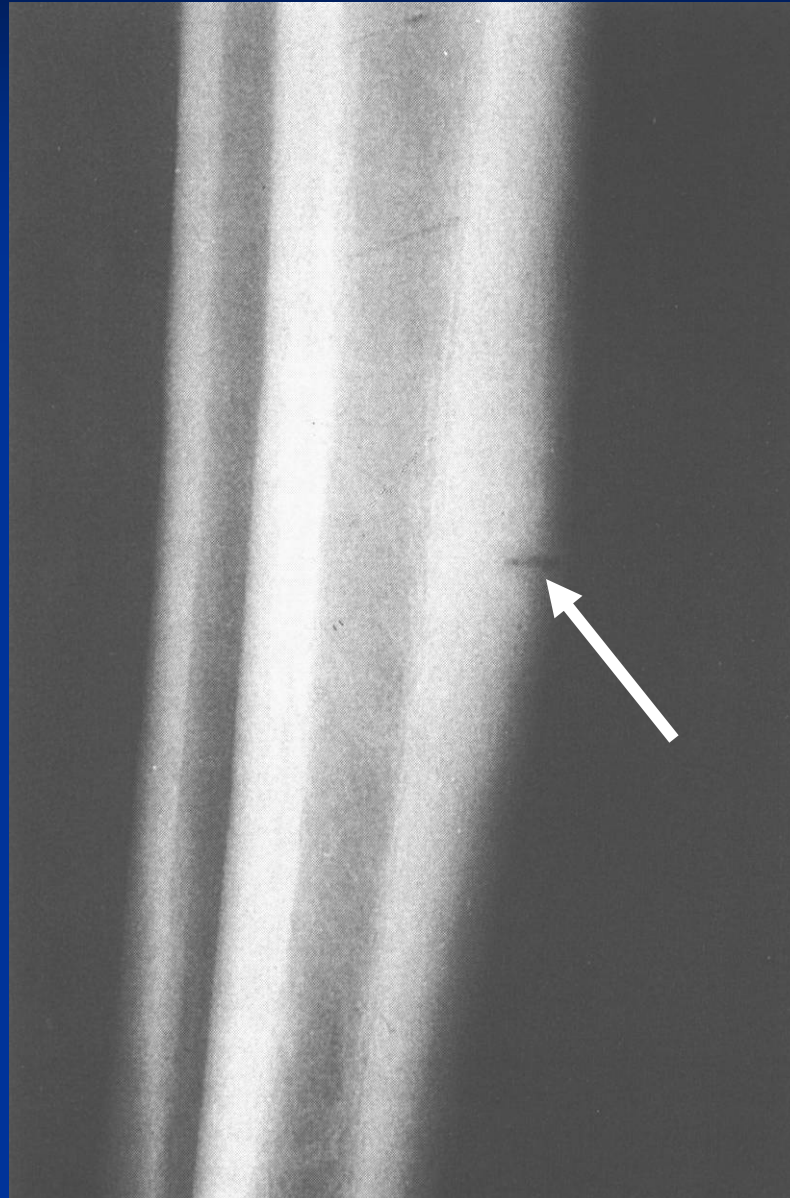
# Brodie's Abscess



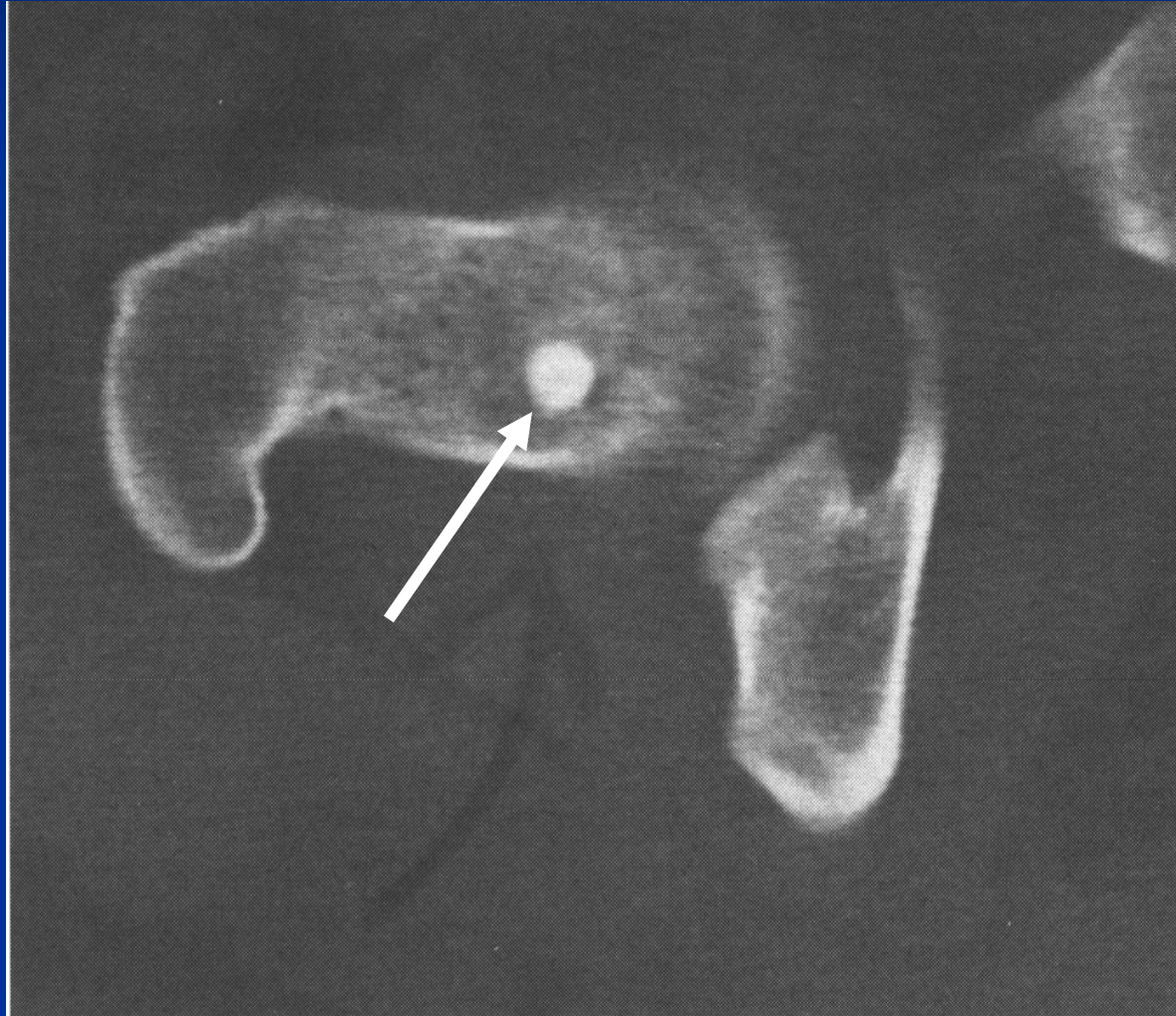
# Brodie's Abscess



# Stress Fracture

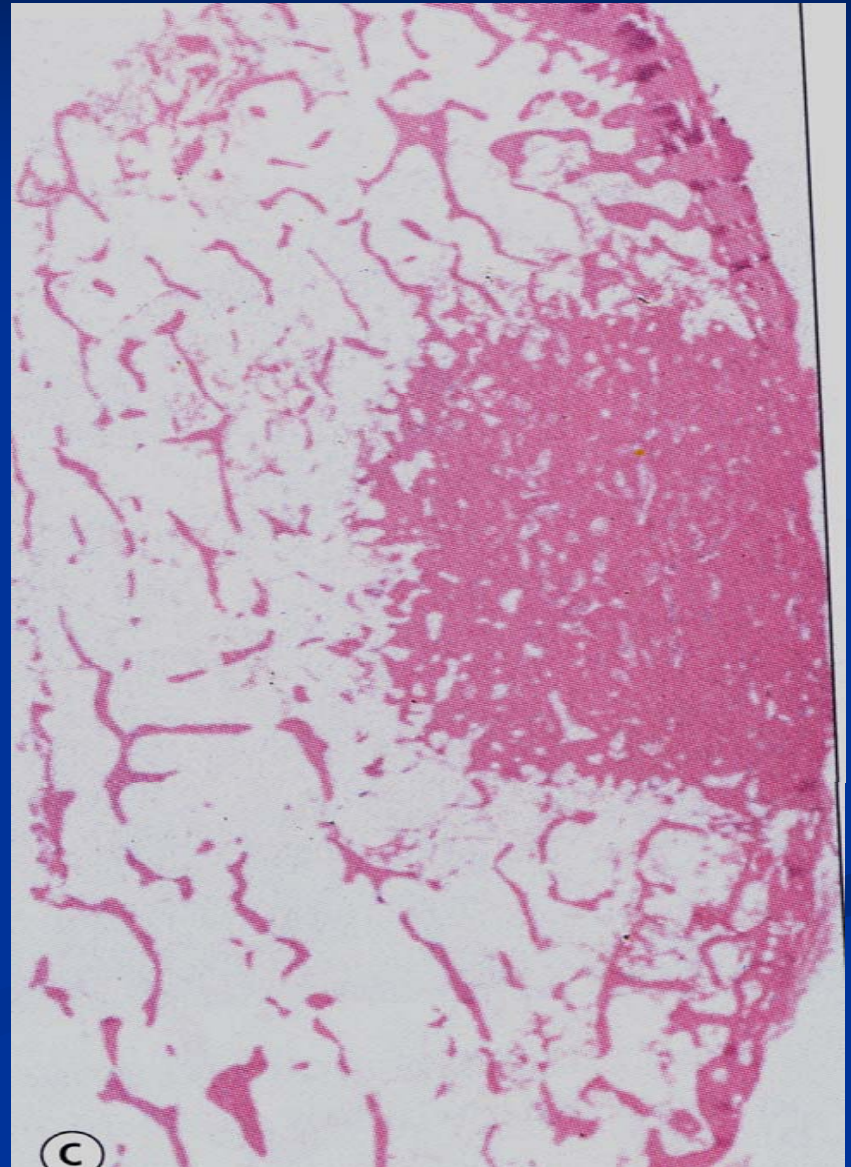


# Bone Island



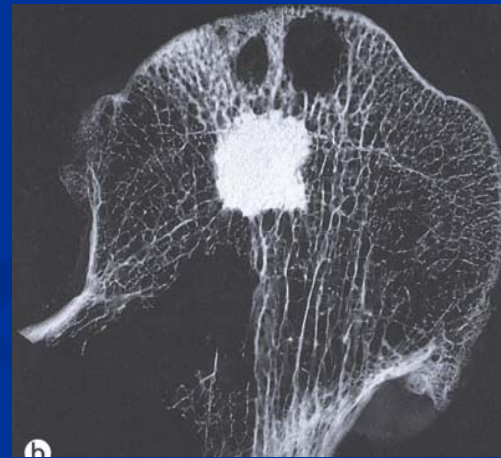
# Bone Island Pathology

- Pathology is same as an osteoma except a bone island occurs within the medullary canal and not on the surface of the bone
- Mature, dense, cortical, compact bone arranged in a lamellar manner around haversian canals
- Sits within medullary canal

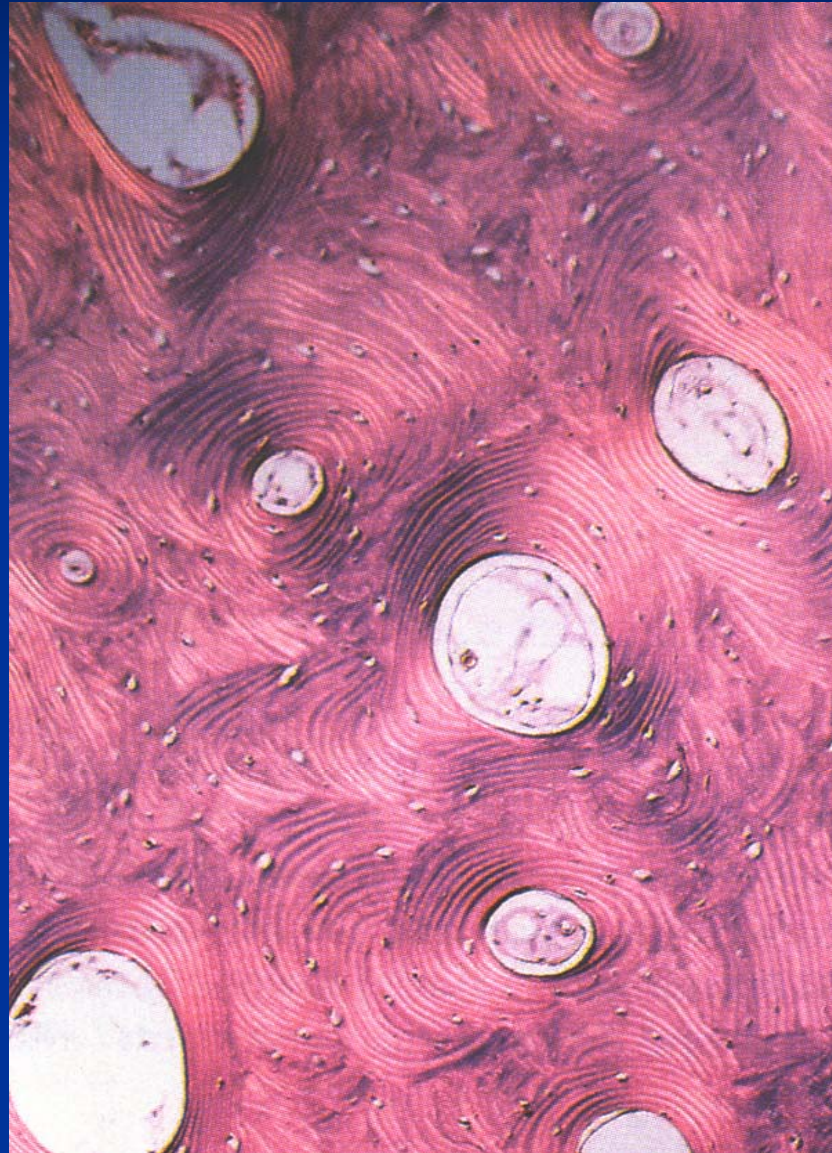


# Bone Island

- The periphery of a bone island extends outward as spicules that blend in with surrounding trabeculae
- CT scan can often demonstrate these spicules



# Pathology of a Bone Island



# Osteoid Osteoma

- Differential Diagnosis of Intraarticular lesions
  - Rheumatoid arthritis
  - JRA
  - Tuberculous arthritis
  - Nonspecific synovitis
  - Septic arthritis
  - Osteoblastoma (especially the spine)



# Osteoid Osteoma

## ■ Behavior and Treatment:

- Rarely grow greater than 1 cm
- Some may spontaneously regress or burn out
- Treatment:
  - Surgically accessible lesions: (problem locating nidus at time of surgery)
    - **Percutaneous Radiofrequency Ablation**---Favored; State of the Art treatment; 90% success rate; requires appropriate facilities, equipment and physician
    - CT guided localization and burr down resection with midas rex—Minimally invasive; less bone removed; 2 Step process
    - En bloc excision (tetracycline labeling)---more bone removed, more morbidity, may require internal fixation and bone grafting; higher risk of fracture
    - Recurrence due to incomplete excision—can cause multiple nidi

# Osteoid Osteoma

## ■ Treatment:

### ■ Surgically Inaccessible Lesions--Rare

- Chronic NSAIDS—usually require around the clock NSAIDS for up to a couple of years; Problems with GI upset and Renal Insufficiency/Failure; Children usually awaken at night—trouble sleeping; personality changes and never get 100% relief of pain; Limb length discrepancy
- Percutaneous radiofrequency ablation if possible

# Osteoblastoma

- **Definition:** Uncommon, benign, primary, osteoid producing tumor of bone
- Consists of well vascularized connective tissue stroma in which there is active production of osteoid and primitive woven bone
- Constitute about 1% of excised primary bone tumors
- Osteosarcoma is 20x more common and osteoid osteoma is 4x more common than osteoblastoma
- Synonym: Giant osteoid osteoma

# Osteoblastoma

## ■ Clinical:

- Patients are young, Median age 18
- 80% are between 10 and 30 years old
- Males:females 2-3:1
- Pain is the most common presenting symptom, less severe than osteoid osteoma
- Pain less pronounced at night and may or may not be relieved by aspirin/NSAIDS
- Spinal lesions may be accompanied by muscle spasms, scoliosis and neurologic manifestations

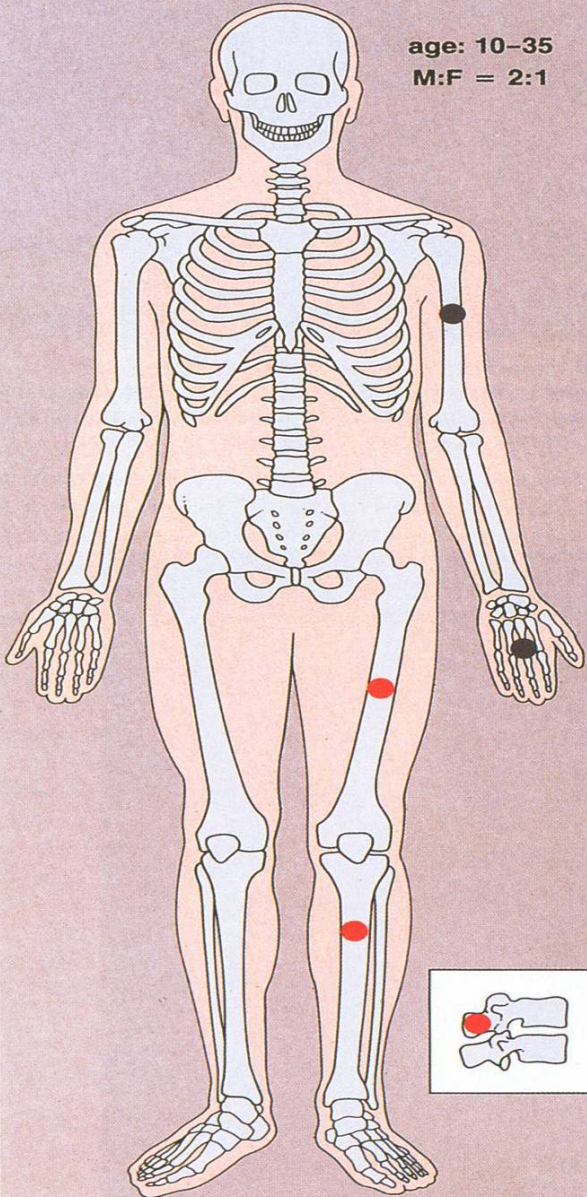
# Osteoblastoma

## ■ Skeletal Distribution:

- Spine (40%), equally distributed cervical through sacrum
  - Occur mainly in the posterior elements
- Long Bones (30%); Most commonly Femur > Tibia
  - Diaphysis (75%)
  - Metaphysis (25%)
- Skull, mandible, maxilla (15%)
- Hands and Feet (10%)
- Pelvis (5%)

# Osteoblastoma

age: 10-35  
M:F = 2:1



- common sites
- less common sites

# Osteoblastoma

## ■ Radiology:

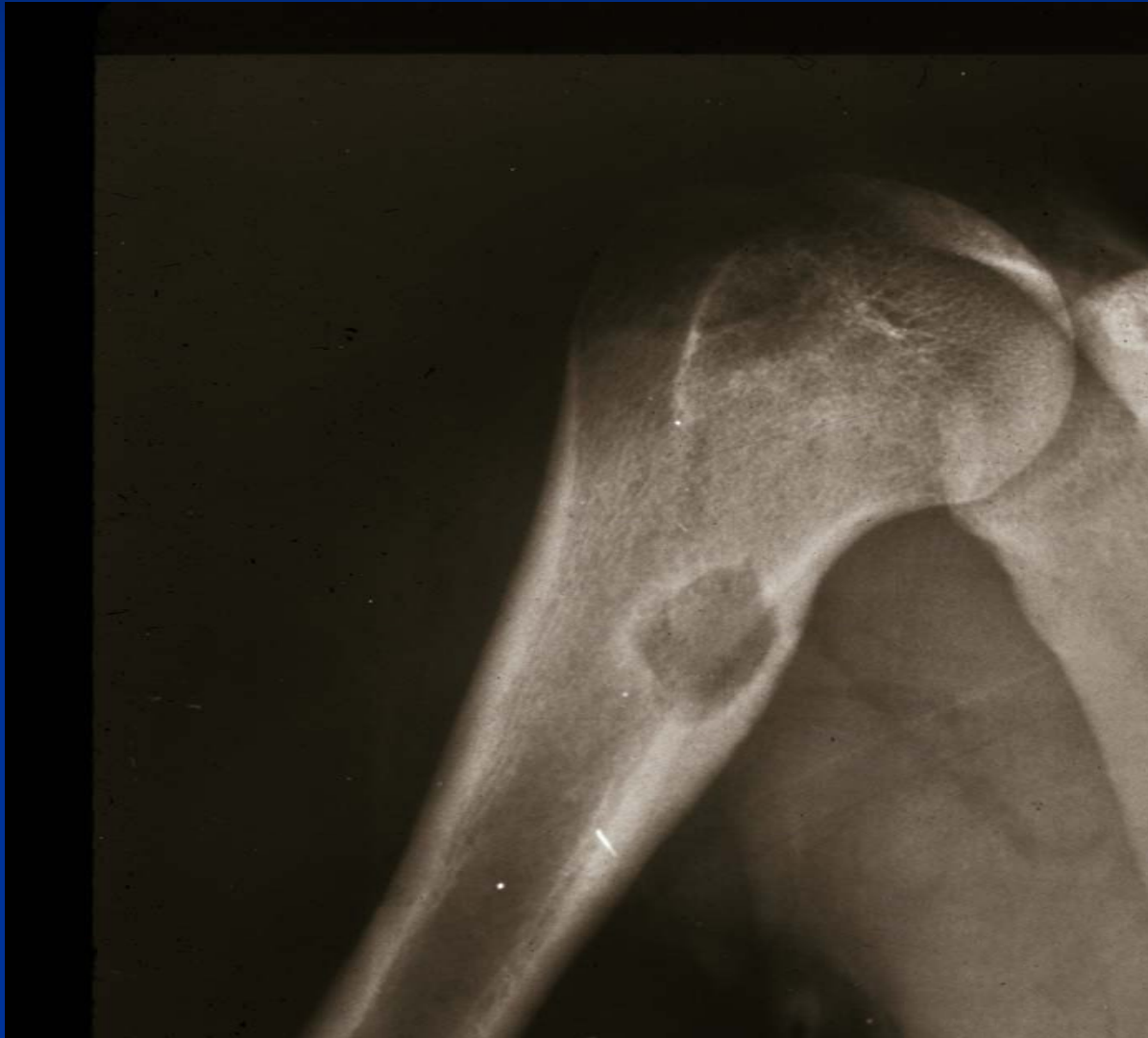- Radiographic features are non diagnostic
- Geographic Pattern of Bone Destruction
- May or may not be mineralized
- Can cause osteolysis, osteosclerosis or a combination of both
- Expansion of bone, cortical thinning and cortical breakthrough with a soft tissue mass may accompany this lesion. The periosteum remains intact around the soft tissue component.
- Mineralization may appear like chondroid tissue, stippled or with arcs and rings but do not see chondroid pathologically
- 16% have an associated ABC (aneurysmal bone cyst) component

# Osteoblastoma

- **Radiology of those affecting long tubular bones, hands and feet and pelvis**
  - Usually medullary or cortical in location, rarely subperiosteal
  - Usually eccentric
  - Diaphysis (75%); Metaphyseal (25%)
  - Usually predominantly osteolytic
  - Areas of calcification or ossification
  - Usually expansile
  - Bone sclerosis and periostitis may be exuberant

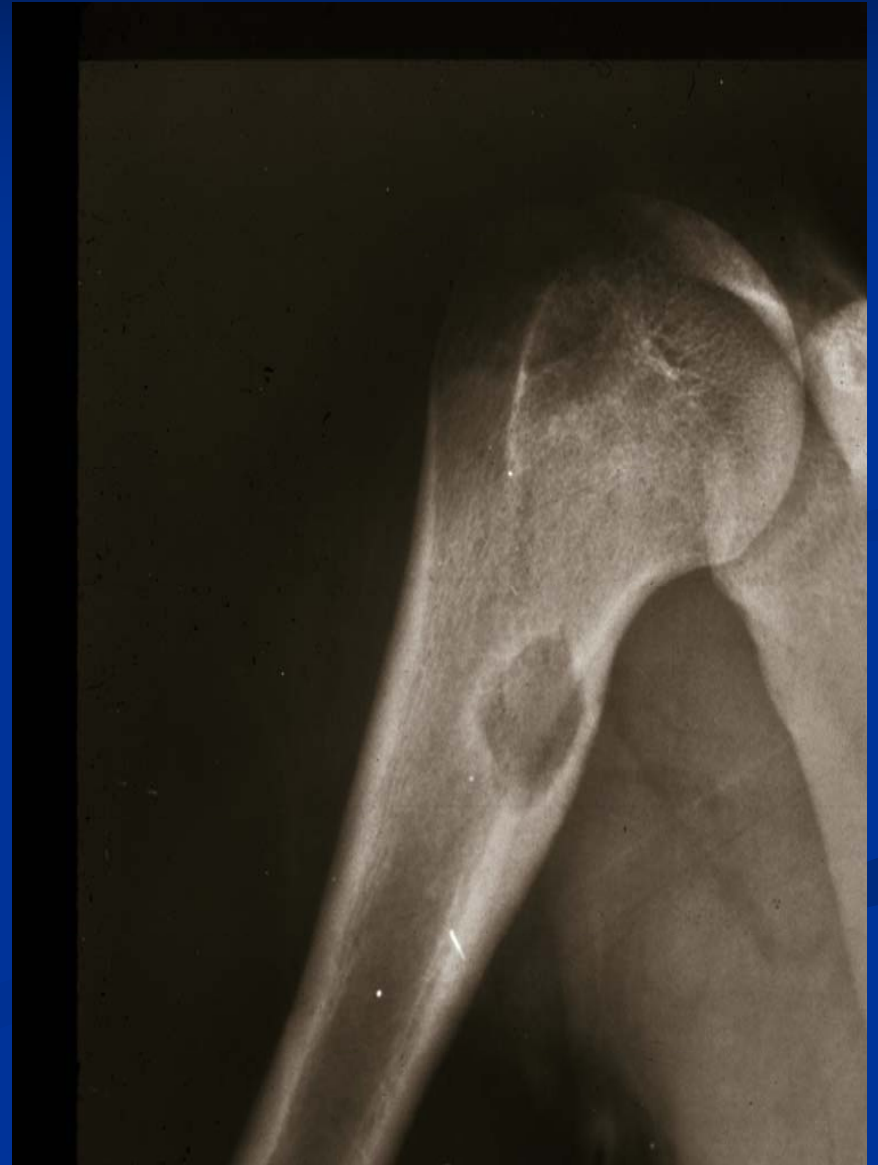

# Osteoblastoma

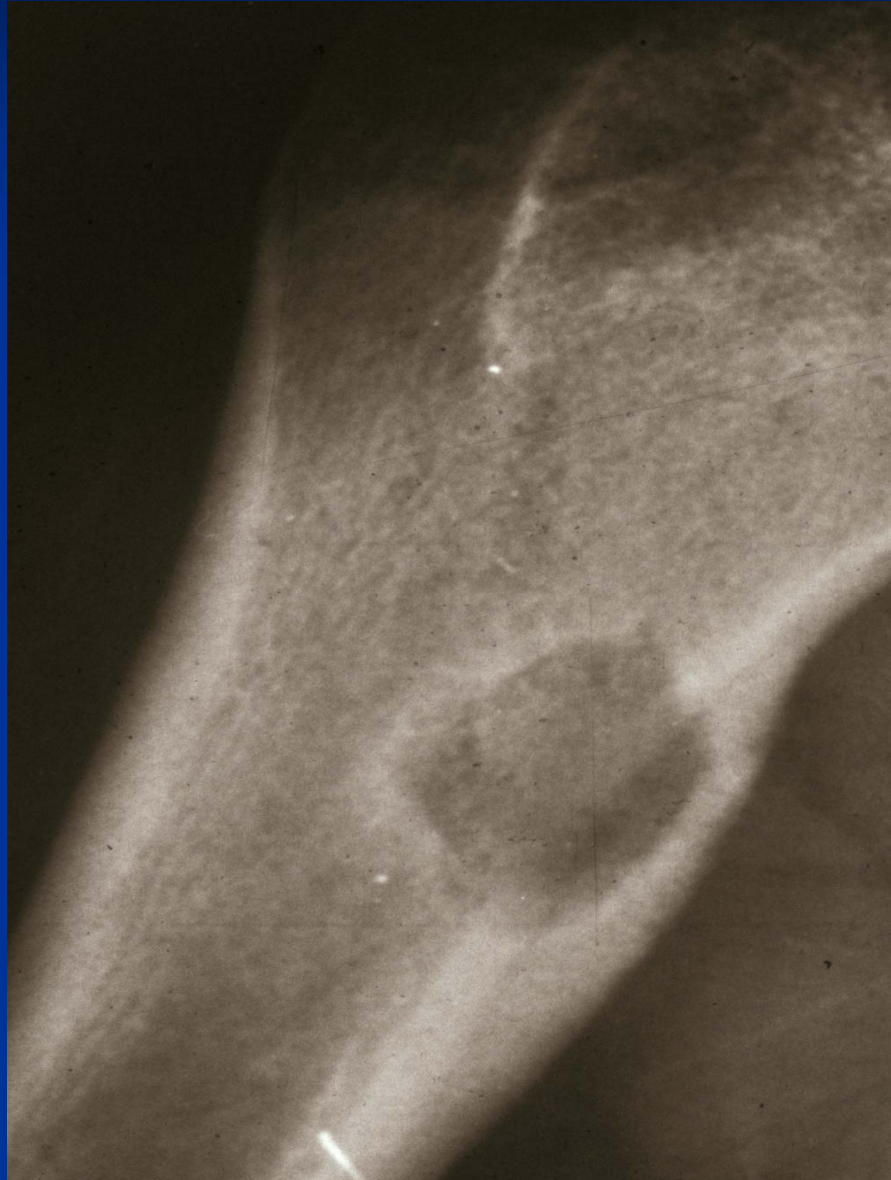

# Osteoblastoma

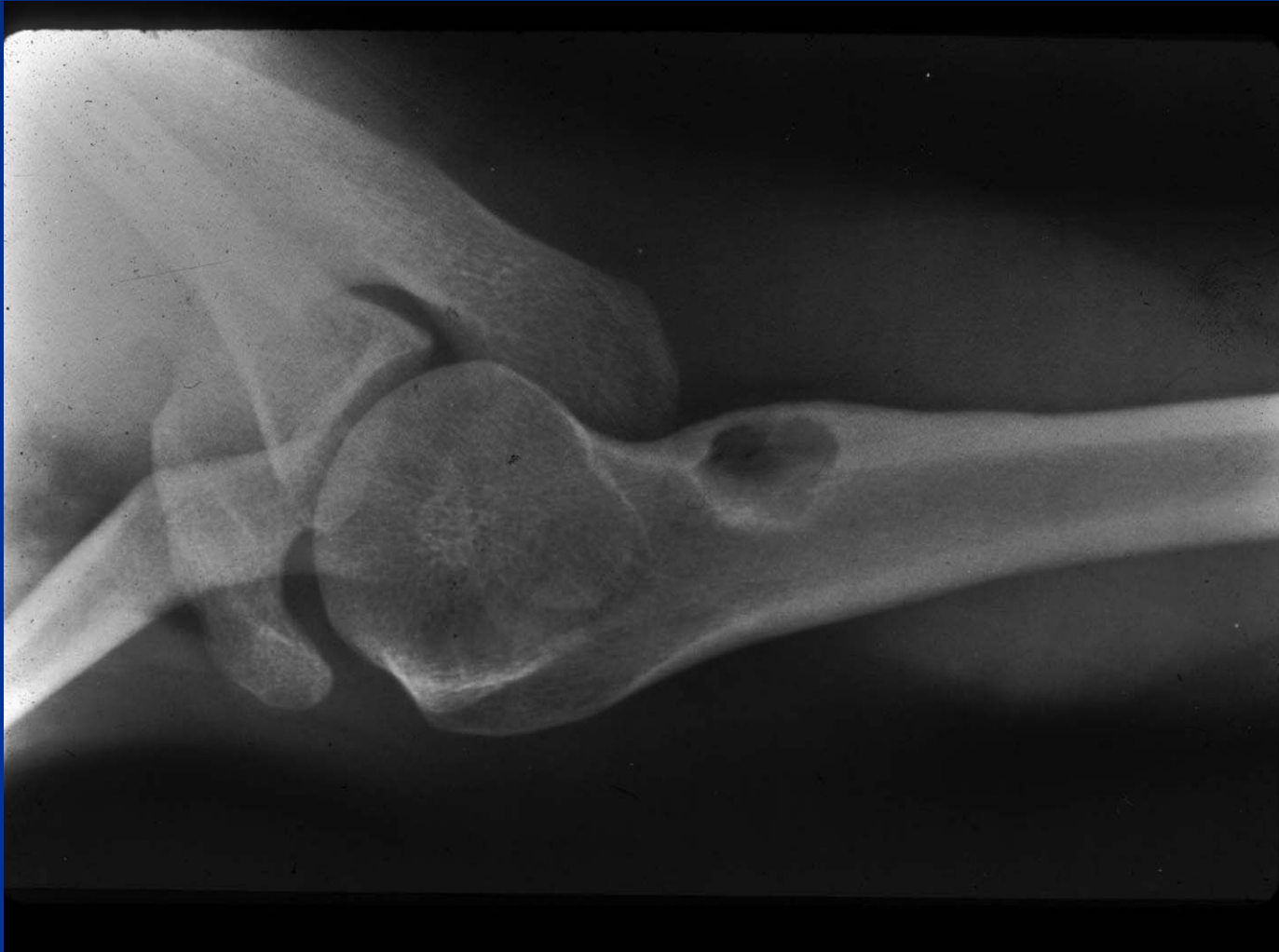- Geographic Pattern of Bone Destruction
- Eccentric
- Sclerotic Margin
- Buttressing, Benign Appearing Periosteal Reaction (Cortical Thickening/Bony Expansion)
- No clear mineralization on Xray



# Osteoblastoma

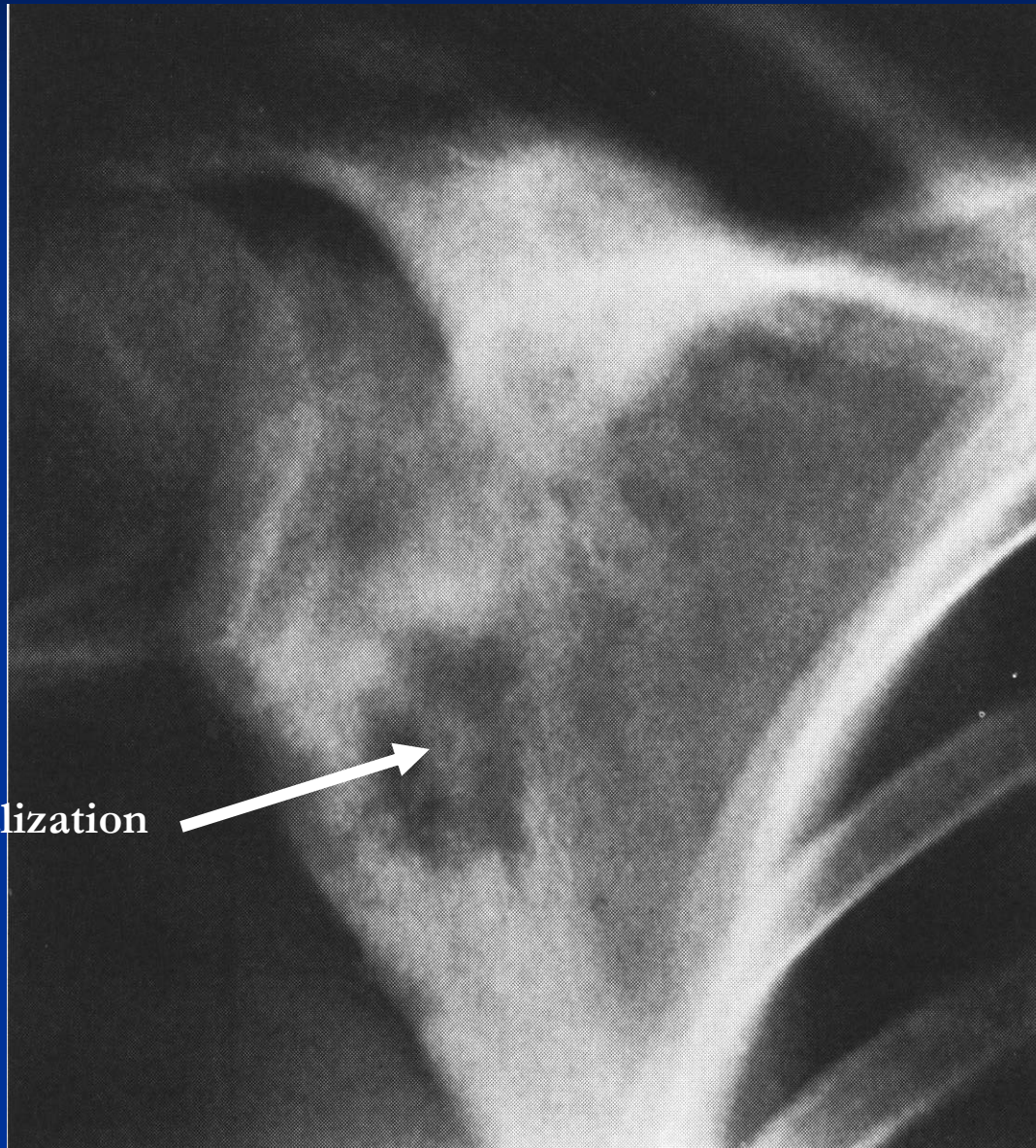



# Osteoblastoma

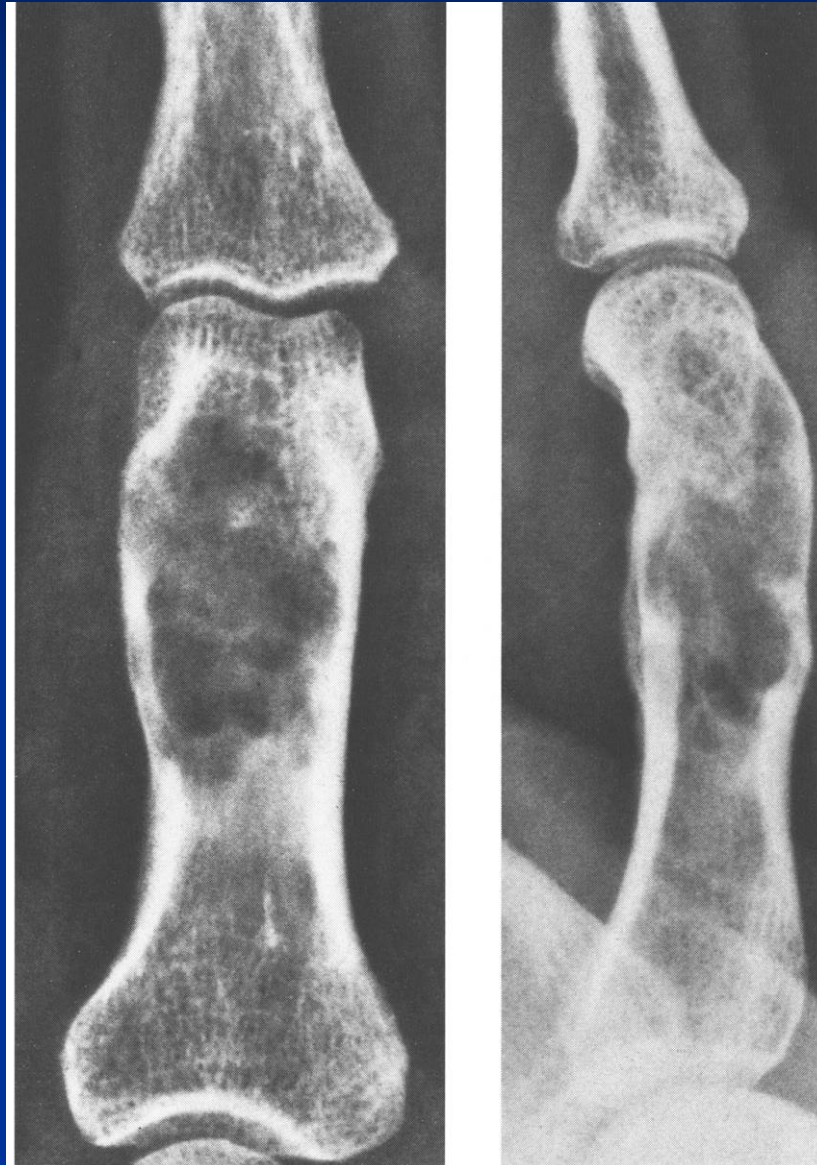

# Osteoblastoma

Mineralization



# Osteoblastoma



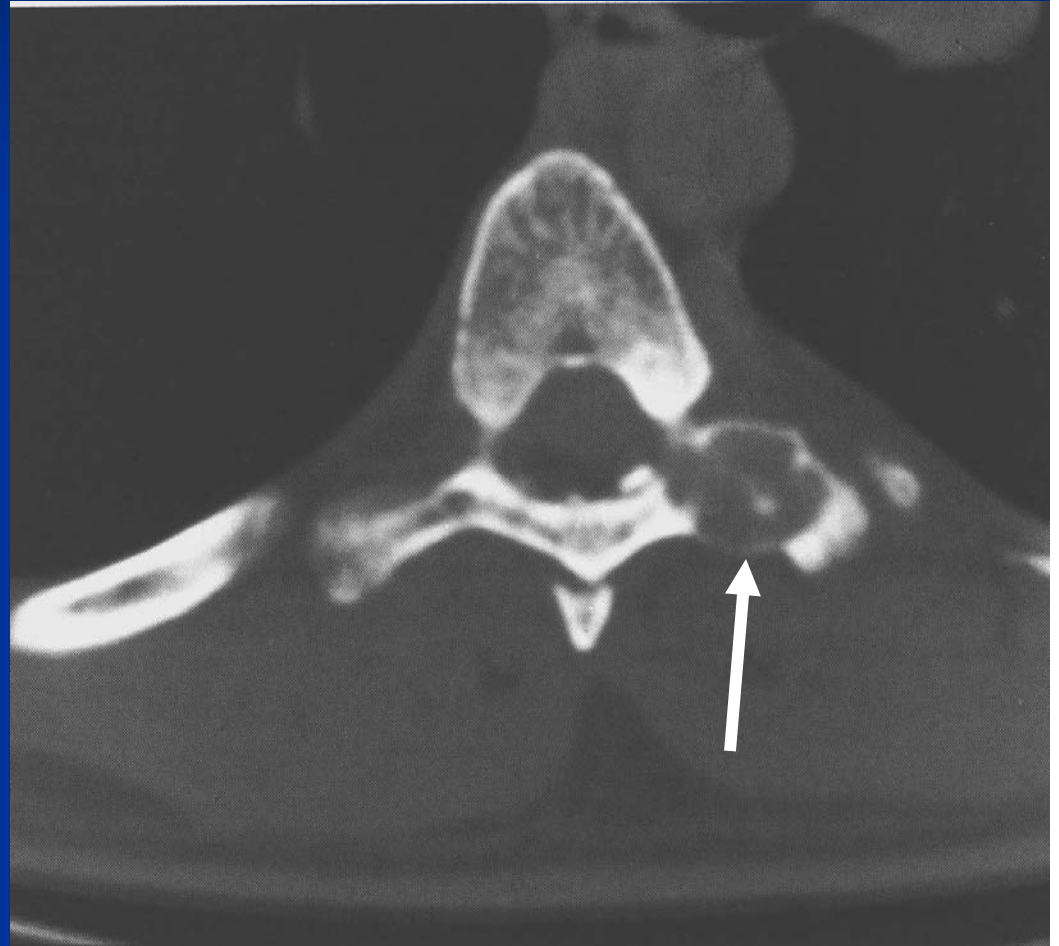
# Osteoblastoma

## ■ Radiology of Spine Lesions:

- Well defined, expansile, geographic, osteolytic lesion that is partially or extensively calcified or ossified
- Posterior elements alone (>60% of cases)
- Posterior elements with extension into vertebral body (25%)
- Vertebral body alone (15%)
- More likely to contain ossification and a soft tissue mass
- Sclerosis less likely than long bones
- Scoliosis less characteristic than osteoid osteoma

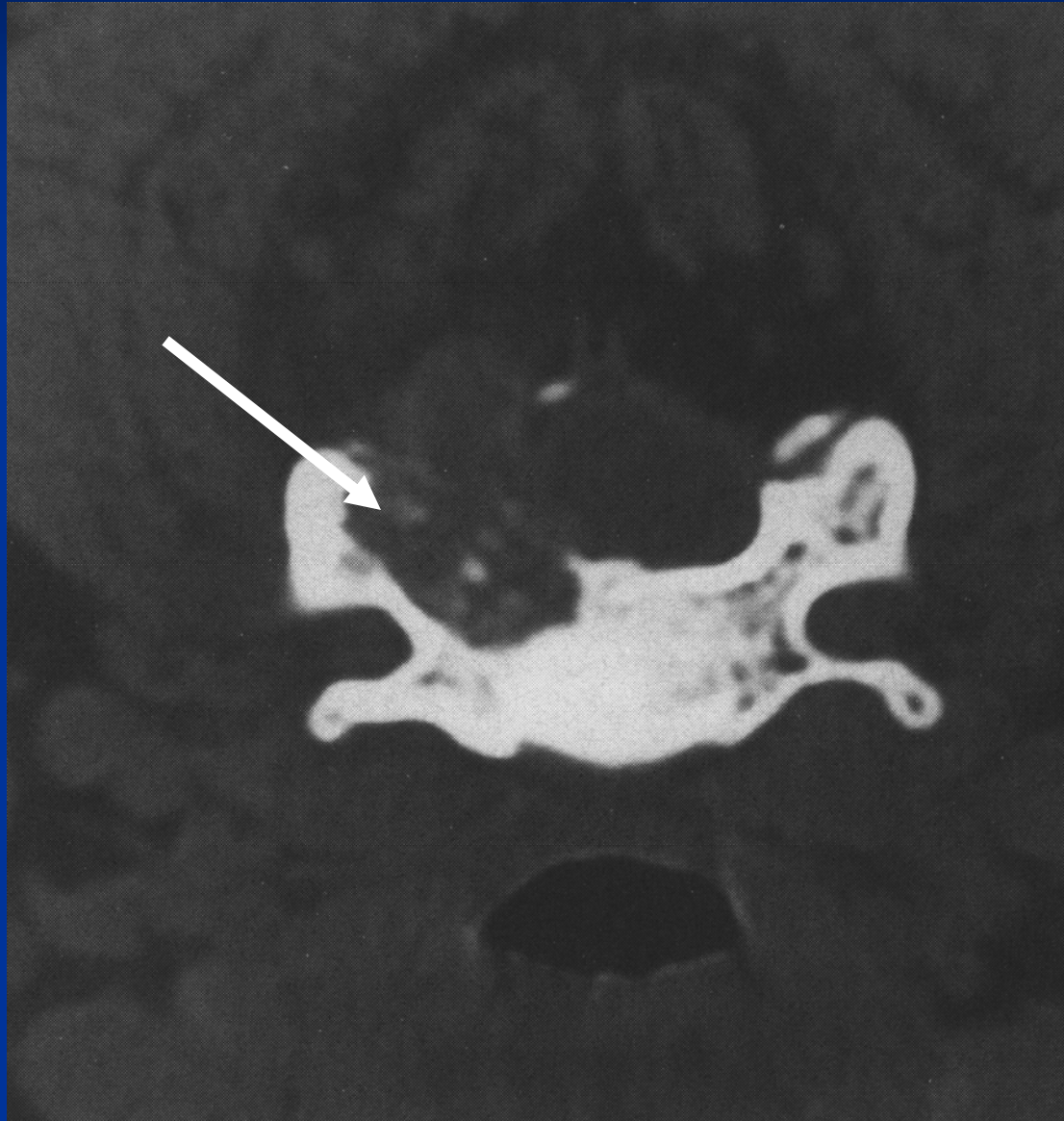
# Osteoblastoma

- Geographic Lesion
- Posterior Elements of Spine
- Bone is Expanded
- The lesion (soft tissue component) is surrounded by and “Egg Shell” rim of calcification indicating the periosteum is intact
- Mineralization present in lesion

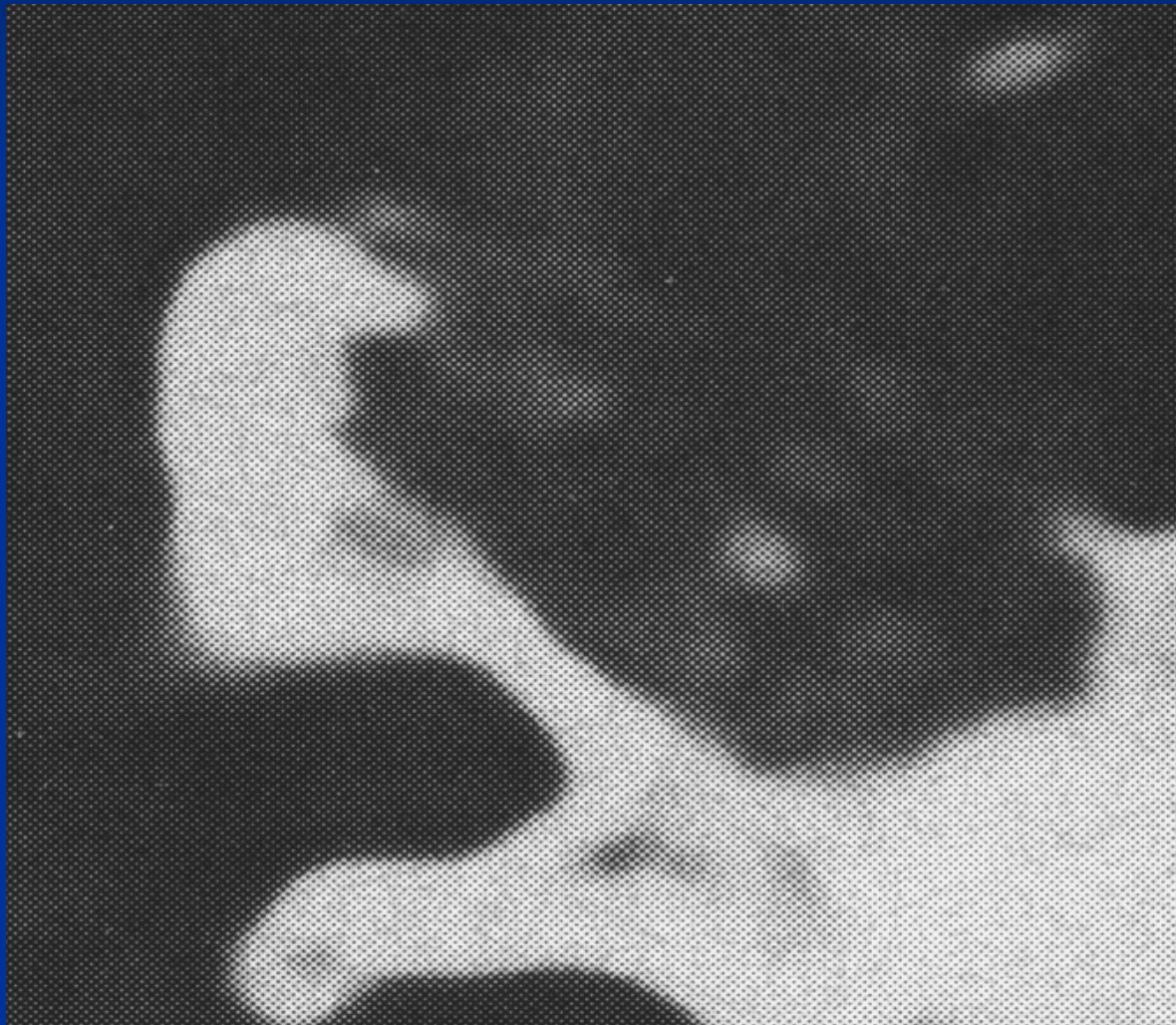



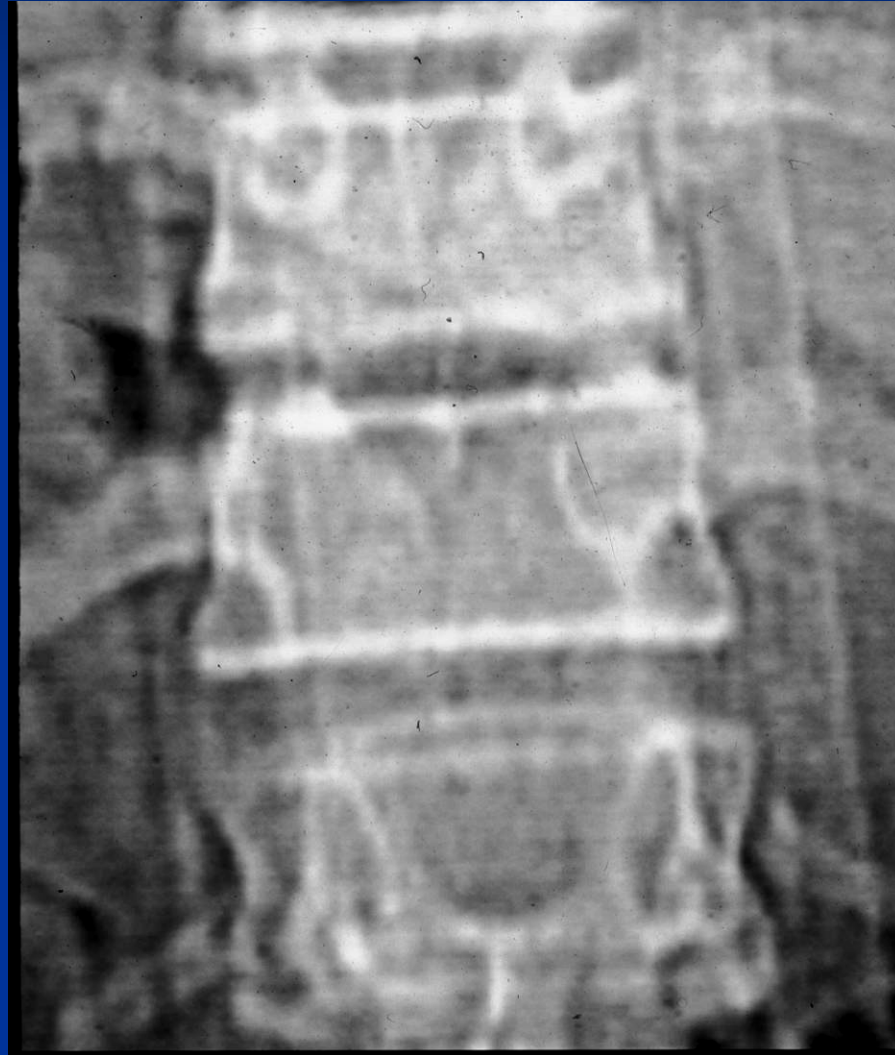# Osteoblastoma



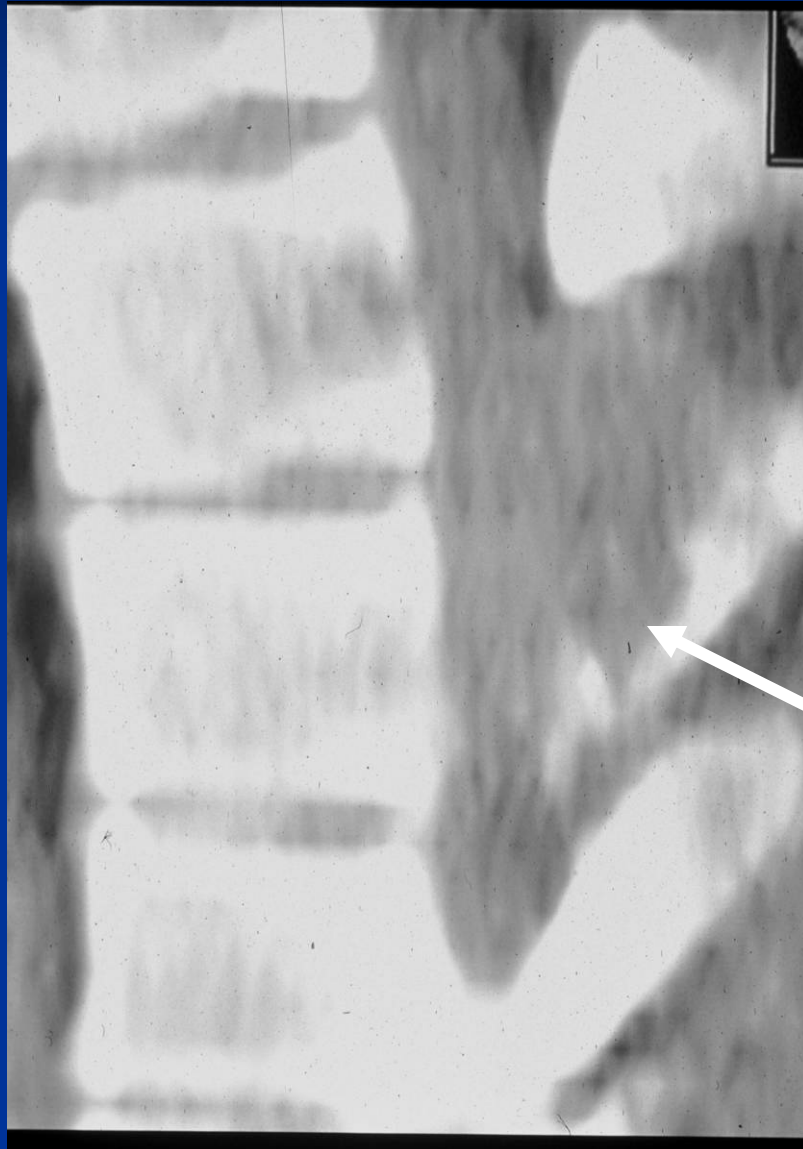
# Osteoblastoma



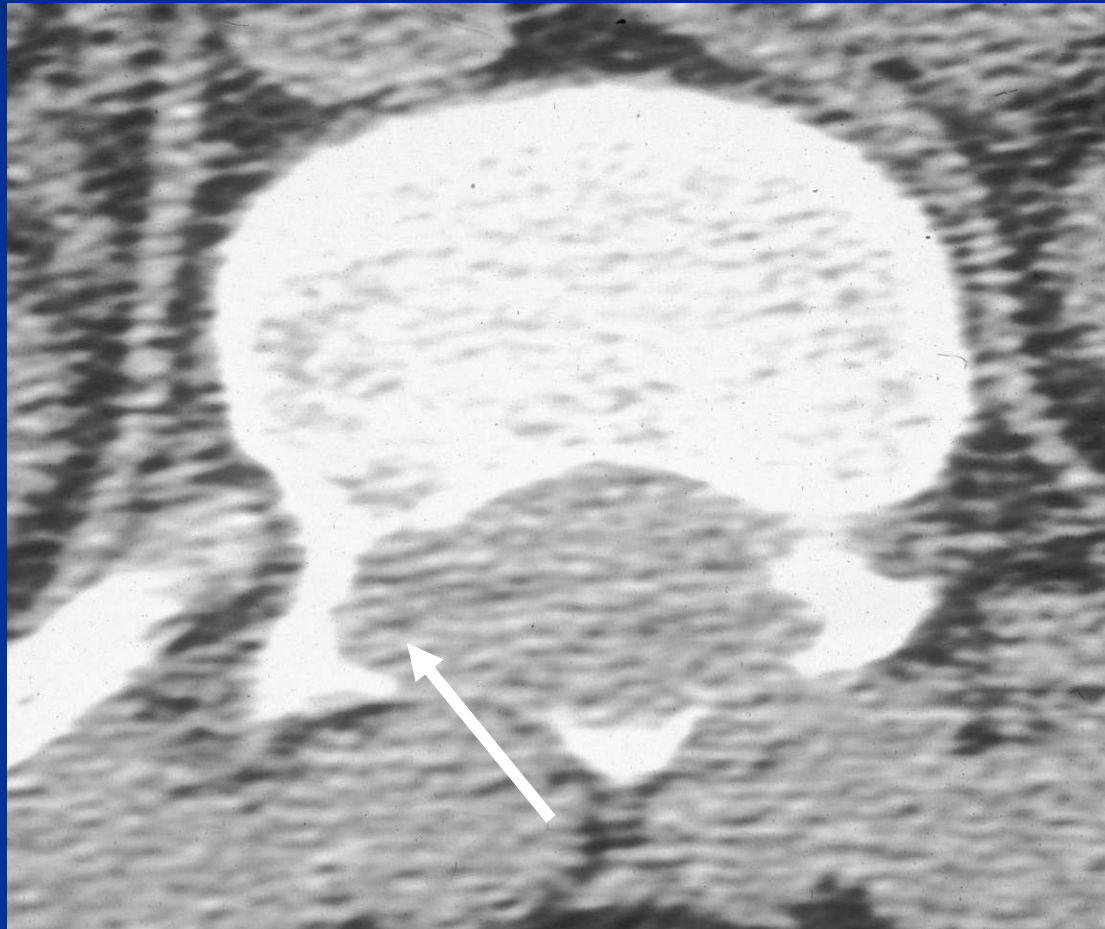# Osteoblastoma



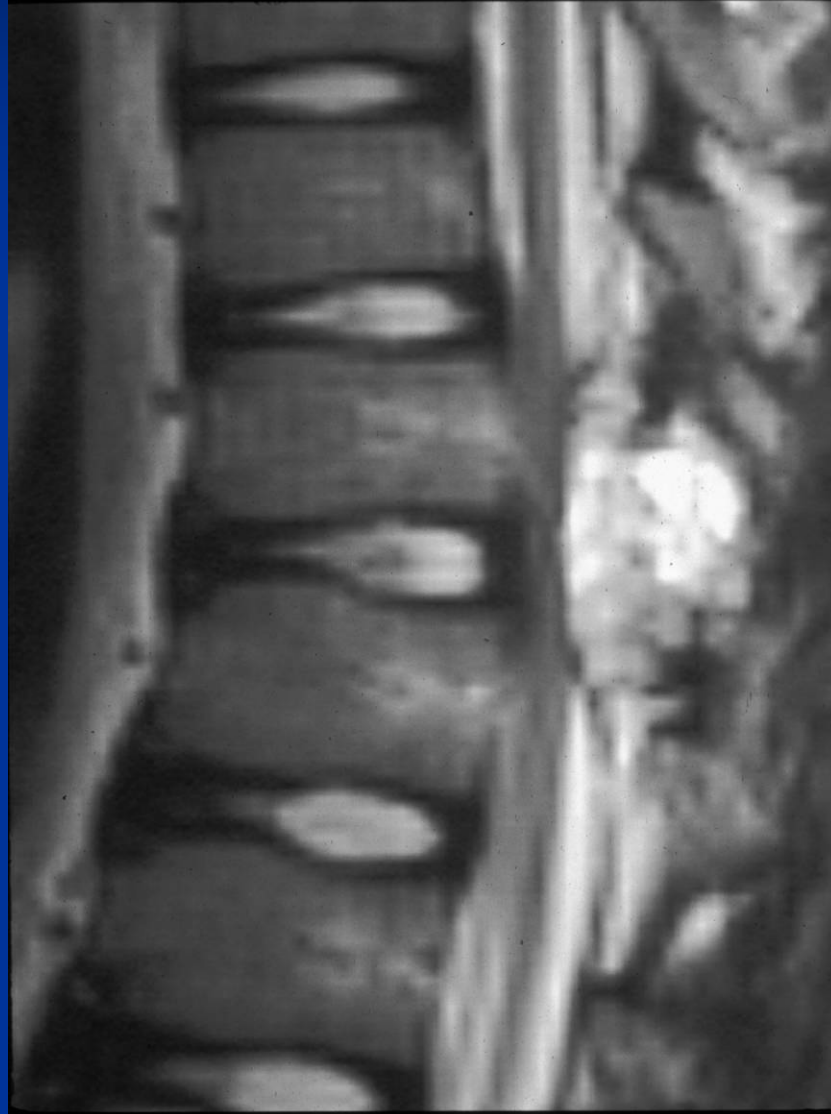# Osteoblastoma



# Osteoblastoma



# Osteoblastoma



# Osteoblastoma

- Bone scan: Increased uptake at the site of the lesion
- CT more useful for detecting mineralization and extent of bone destruction
- MRI also useful in determining extent; alone may lead to a misdiagnosis of a malignant tumor because of an inflammatory reaction in soft tissues

# Osteoblastoma

## ■ Differential between Osteoid Osteoma and Osteoblastoma

### ■ Osteoblastoma

- Size: >1.5-2cm
- Growth: Benign Aggressive Lesion: Continues to grow and destroy bone (osteoid osteoma has a limited growth potential--indolent)
- Soft Tissue Mass with an Osteoblastoma
- Scoliosis and classical symptoms absent with Osteoblastoma
- Matrix is multifocal in an osteoblastoma and not central



# Osteoblastoma

## ■ Differential Diagnosis of Pedicle Sclerosis:

- Lymphoma
- Metastatic carcinoma
- Spondylolysis
- Unusual infection
- Osteoid osteoma
- Absence/hypoplasia of posterior elements
- Malaligned apophyseal joints
- ABC

# Osteoblastoma

- **Differential Diagnosis in Long Bones**
  - Osteoid Osteoma
  - Osteosarcoma
  - ABC
  - Eosinophilic granuloma
  - Enchondroma
  - Fibrous dysplasia
  - Chondromyxofibroma
  - Solitary bone cyst

Condition (lesions)	Radiologic features	Pathologic features
Cortical and medullary osteoid-osteoma-like osteoblastoma (giant osteoid osteoma) Aneurysmal bone cyst-like expansive osteoblastoma	Radiolucent lesion, spherical or oval, with well-defined margins. Frequent perilesional sclerosis. Abundant periosteal reaction. Size of the nidus >2 cm. Blow-out lesion, similar to aneurysmal bone cyst, but with central opacities.	Active formation of osteoid and immature bone trabeculae. Less organized pattern of osteoid and reticular bone distribution than seen in osteoid osteoma. Hypertrophic osteoblasts. Increased vascularity in the stroma. Occasionally spindle-shaped hyperchromatic cells with uniform nuclei and irregular eosinophilic cytoplasm interdispersed among bony trabeculae. Variable number of giant cells on the surface of bone trabeculae.
Aggressive osteoblastoma (stimulating malignant neoplasm)	Ill-defined borders, destruction of the cortex; aggressive-looking periosteal reaction; occasionally soft tissue extension.	Large, "epithelioid" osteoblasts. Rounded cells with large nuclei containing one or more prominent nucleoli; abundant cytoplasm. Bone trabeculae wider and more irregular than in other types of osteoblastoma. Cement lines usually absent. Atypical mitoses. Bone spicules staining dark blue with hematoxylin-eosin.
Periosteal osteoblastoma	Round or ovoid heterogeneous in density mass attached to cortex.	Trabeculae of woven bone, numerous dilated capillaries, exuberant in number osteoblasts, osteoclasts, and occasionally fibroblasts.
Osteoid osteoma Aneurysmal bone cyst	See Table 2. Blow-out, expansive lesion. In long bone buttress of periosteal reaction. Thin shell of reactive bone frequently covers the lesion, but may be absent in rapidly growing lesions. Soft tissue extension may be present.	See Table 2. Multiple blood-filled sinusoid spaces separated by fibrous septae displaying lamellae of primitive woven bone; may contain hemosiderin and reactive foam cells; solid areas composed of fibrous elements containing irregular bone trabeculae and giant cells, sometimes in great numbers.
Osteosarcoma	Permeative or moth-eaten bone destruction; wide zone of transition; tumor-bone cloud-like opacities; aggressive periosteal reaction; soft tissue mass.	Permeation of cortical bone; attenuation and "trapping" of lamellar bone; atypical mitoses or anaplasia; hyperchromatism and pleomorphism of cells and nuclei; tumor bone and tumor cartilage formed by malignant cells.

# Osteoblastoma

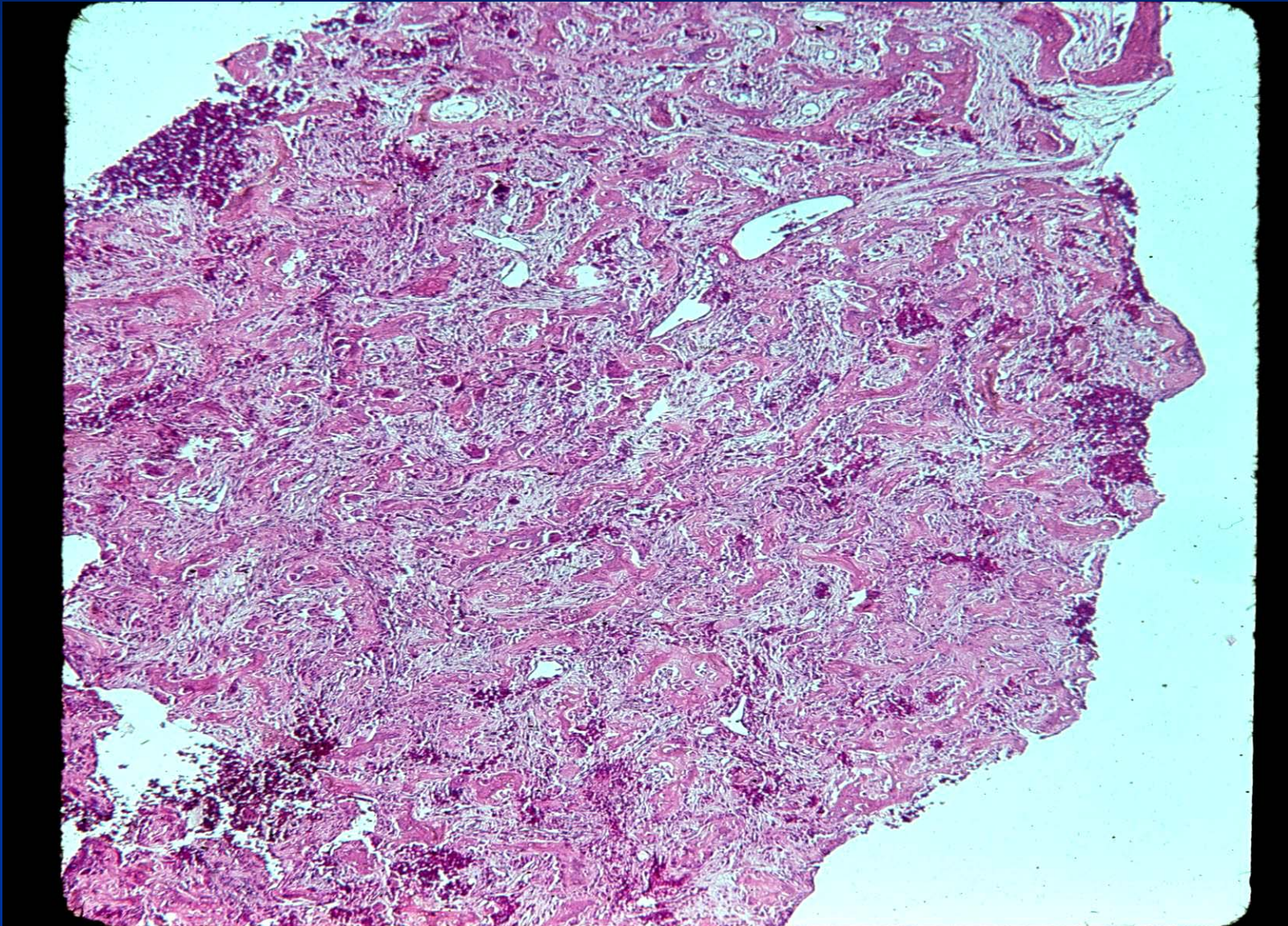
## ■ Pathology

- Indistinguishable from an osteoid osteoma except larger
- **Gross Pathology:** Granular, friable, reddish and may bleed profusely when curetted
- Nidus is well demarcated
- May be hemorrhage and cystic change secondary to ABC formation

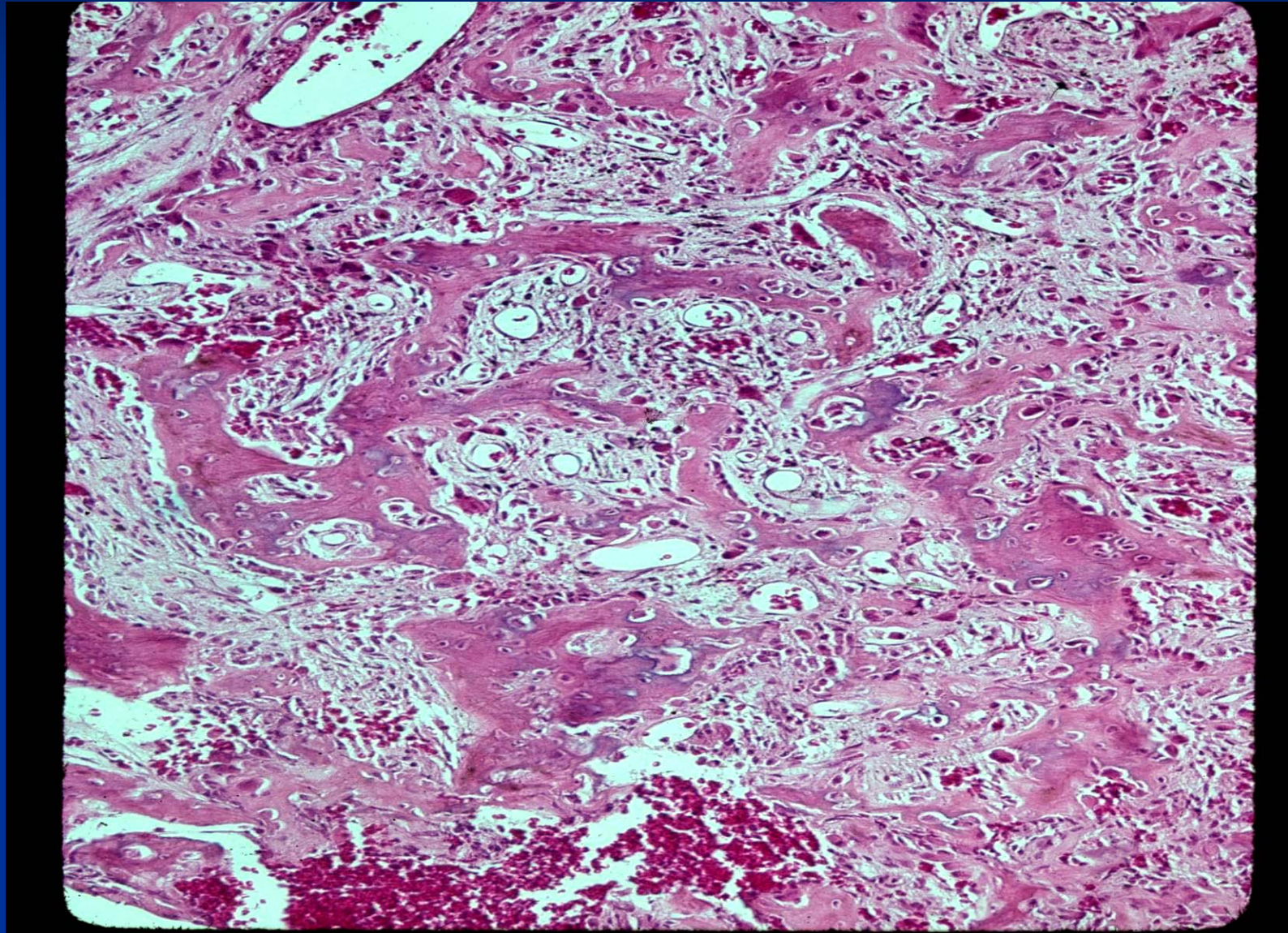
# Osteoblastoma

- **Microscopic Pathology:** Interlacing network of bone trabeculae in a loose fibrovascular stroma with prominent vessels
- **Prominent rimming osteoblasts** and multinucleated giant cells are present (osteoblasts do not form solid sheets that fill the intertrabecular spaces as with an osteosarcoma; they line the trabeculae. In an osteosarcoma, the cells producing osteoid are not uniform and do not line up along trabeculae)
- Mitotic rate can be high but no abnormal mitoses
- Osteoid trabeculae merge gradually with adjacent host bone
- Varying mineralization of osteoid
- Soft tissue component usually surrounded by shell of reactive bone or periosteum
- No cartilage

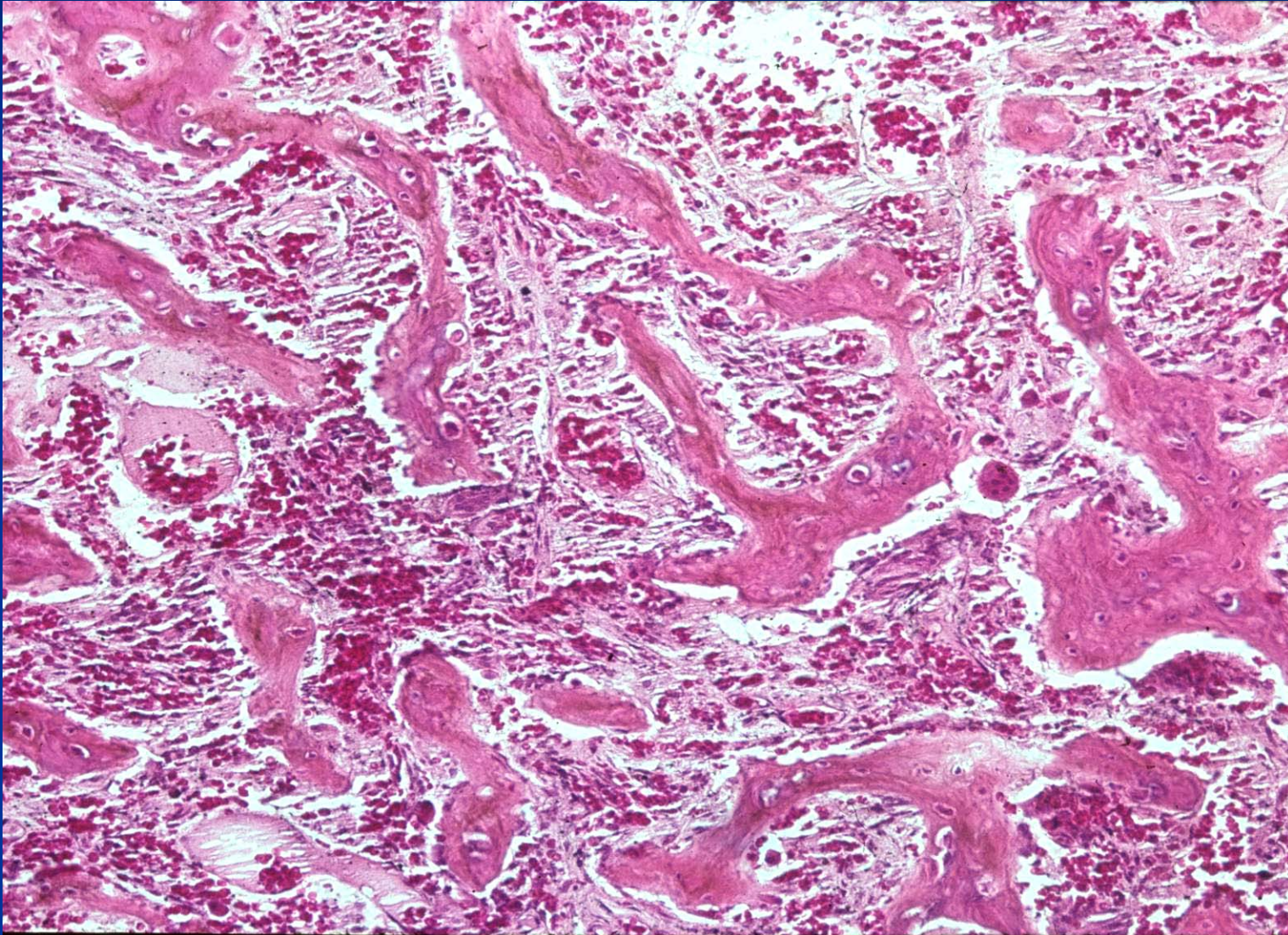
# Osteoblastoma



# Osteoblastoma

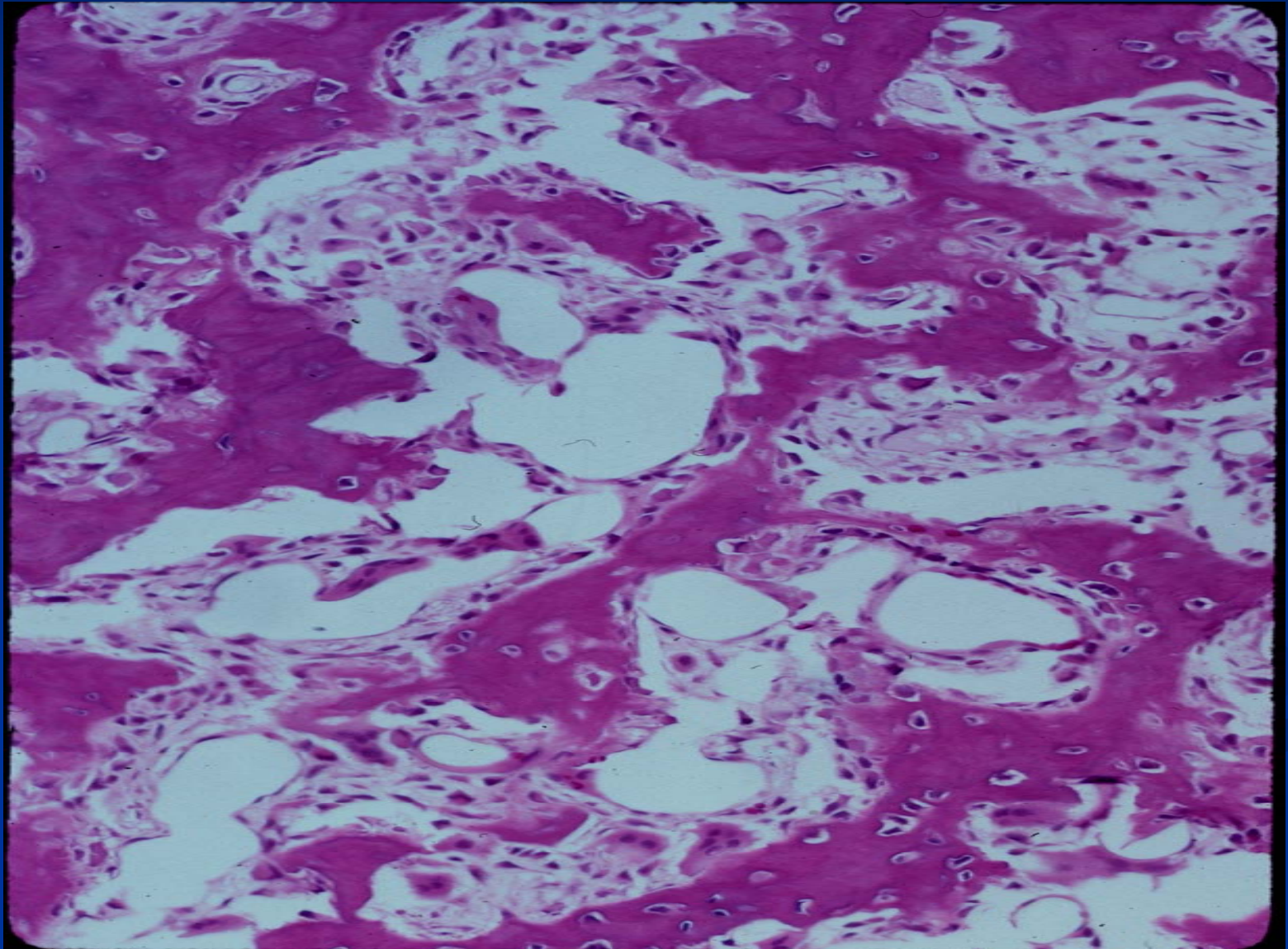


# Osteoblastoma

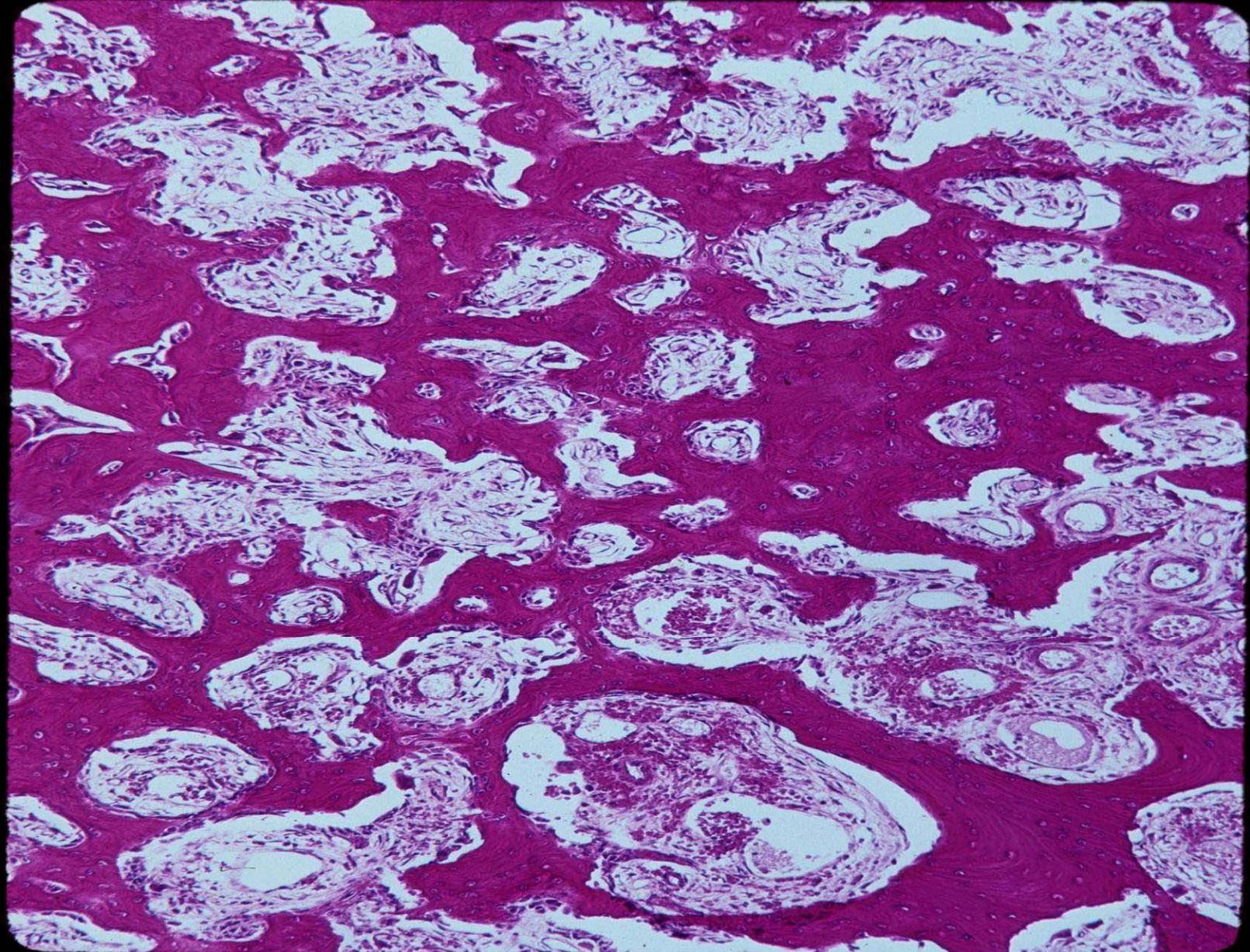


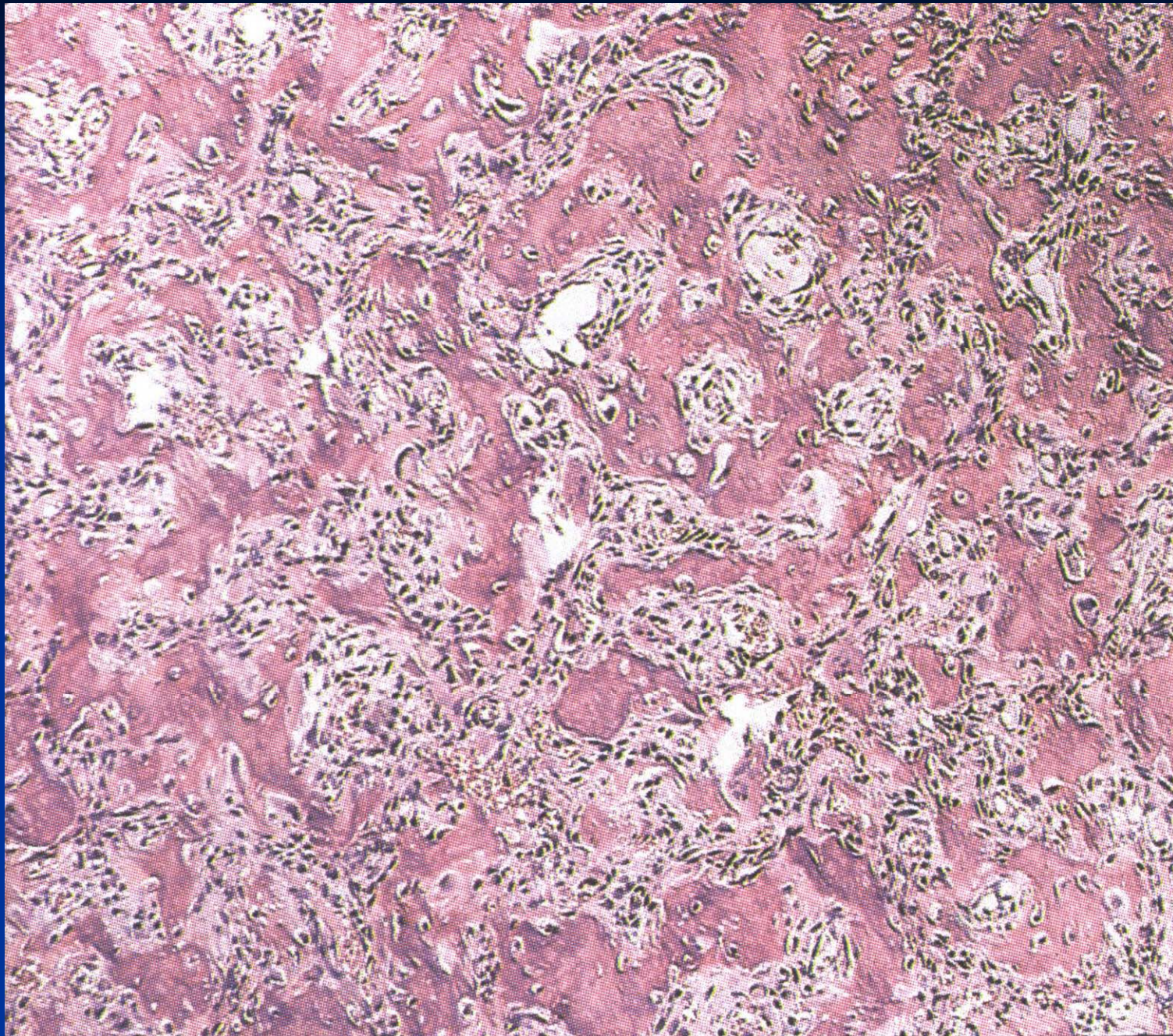


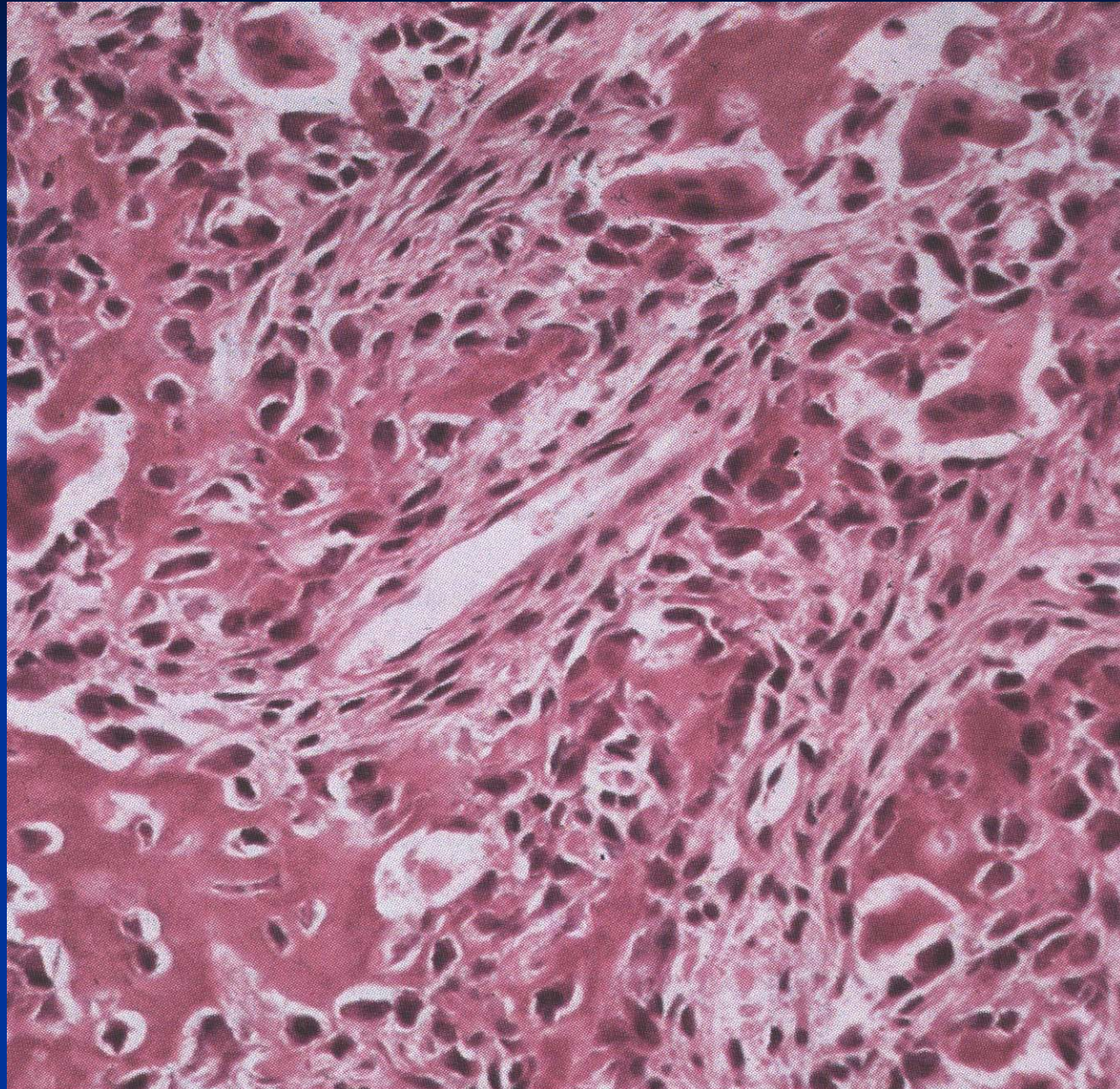
# Osteoblastoma

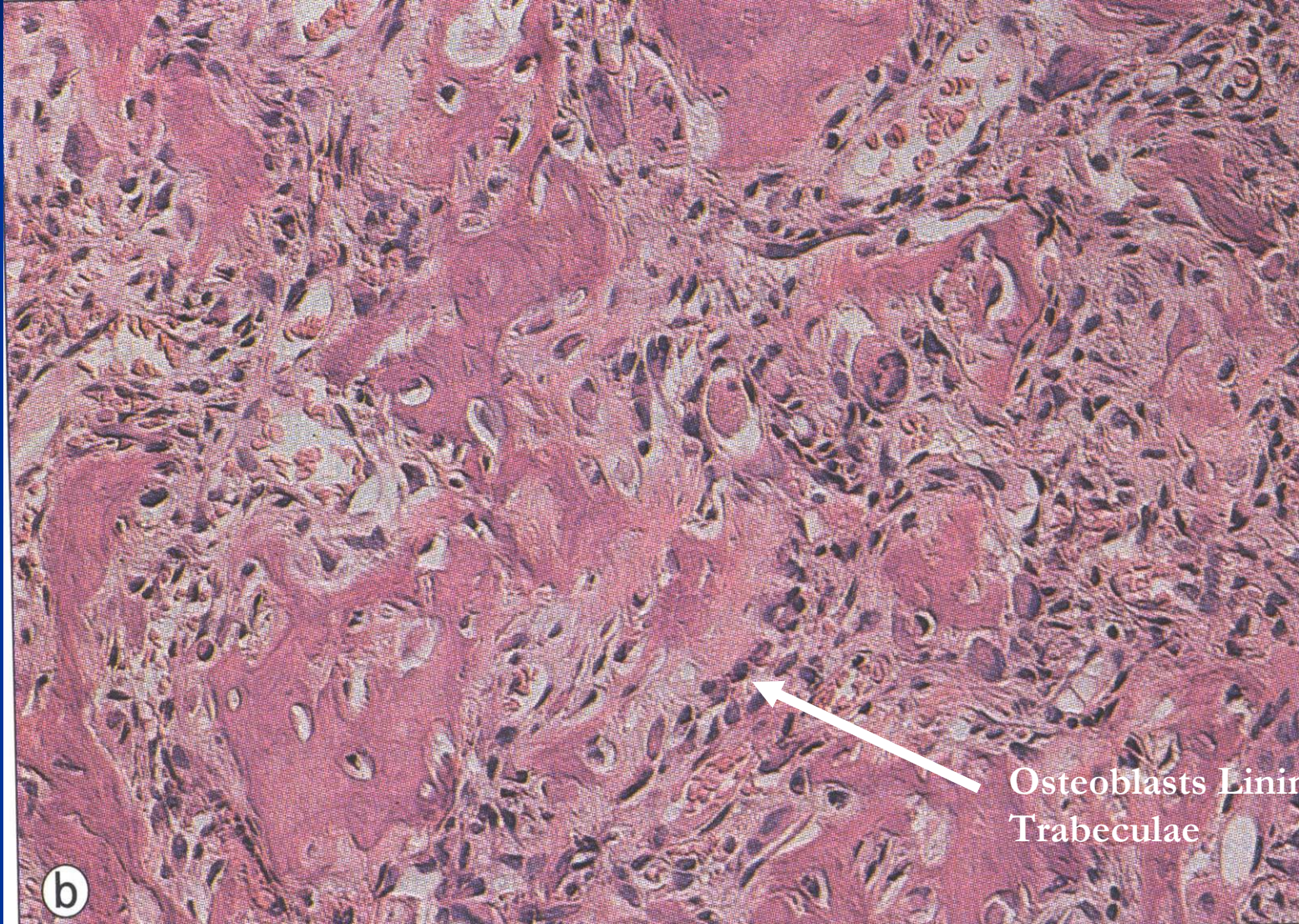


# Osteoblastoma







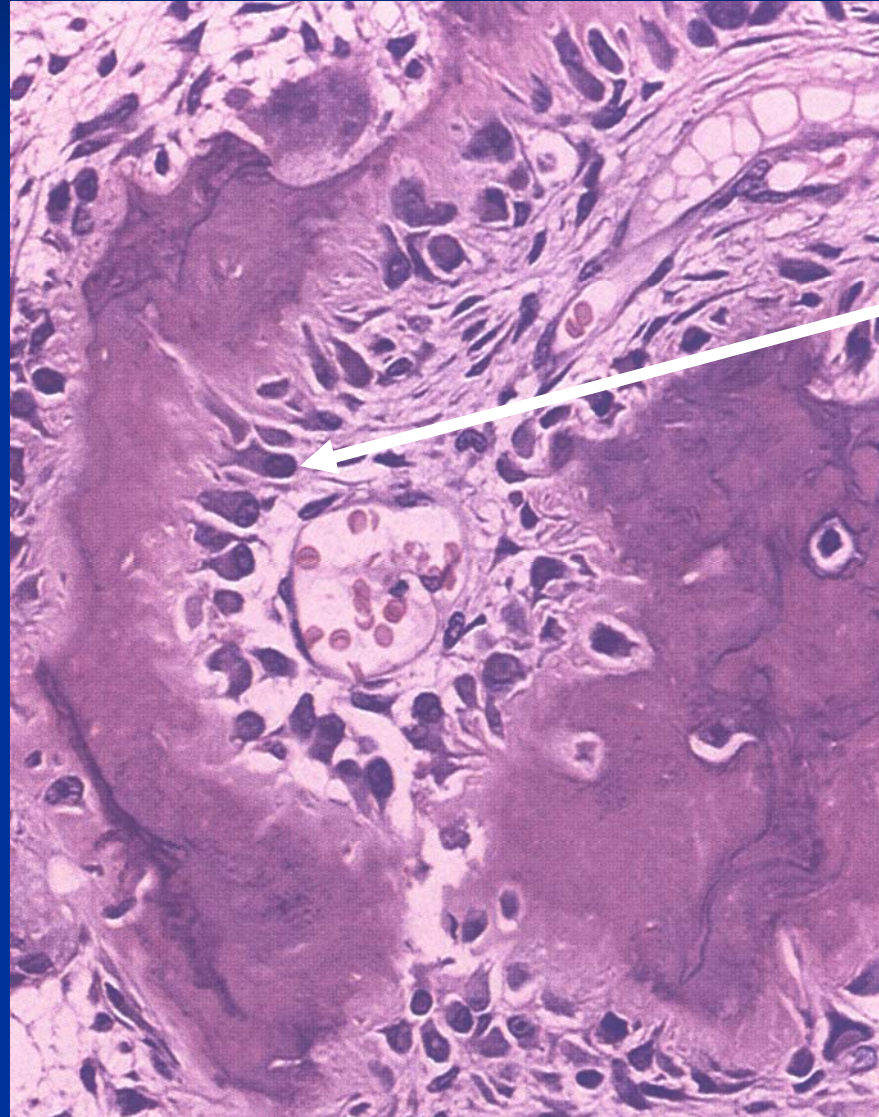


Osteoblasts Lining  
Trabeculae

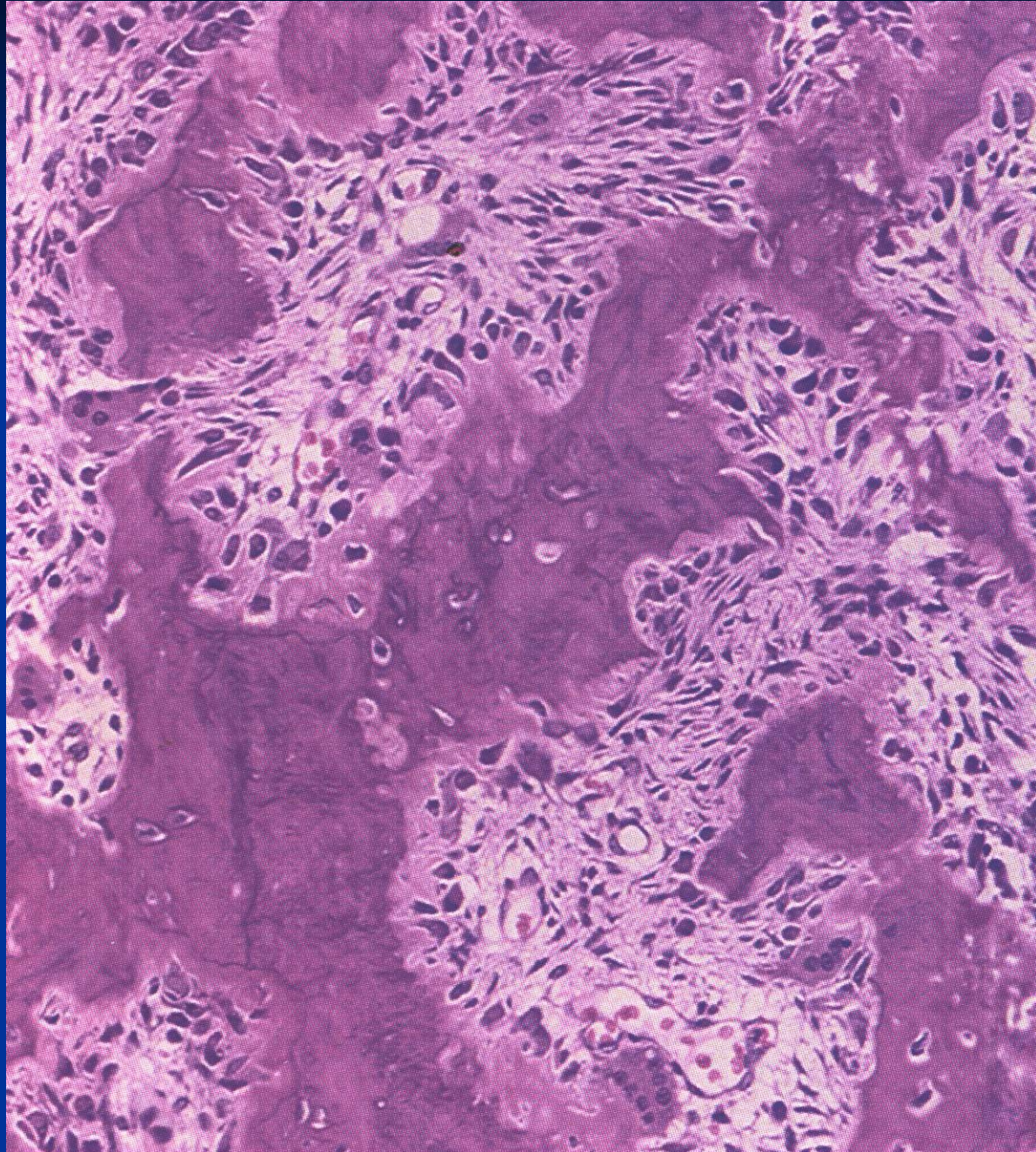
b

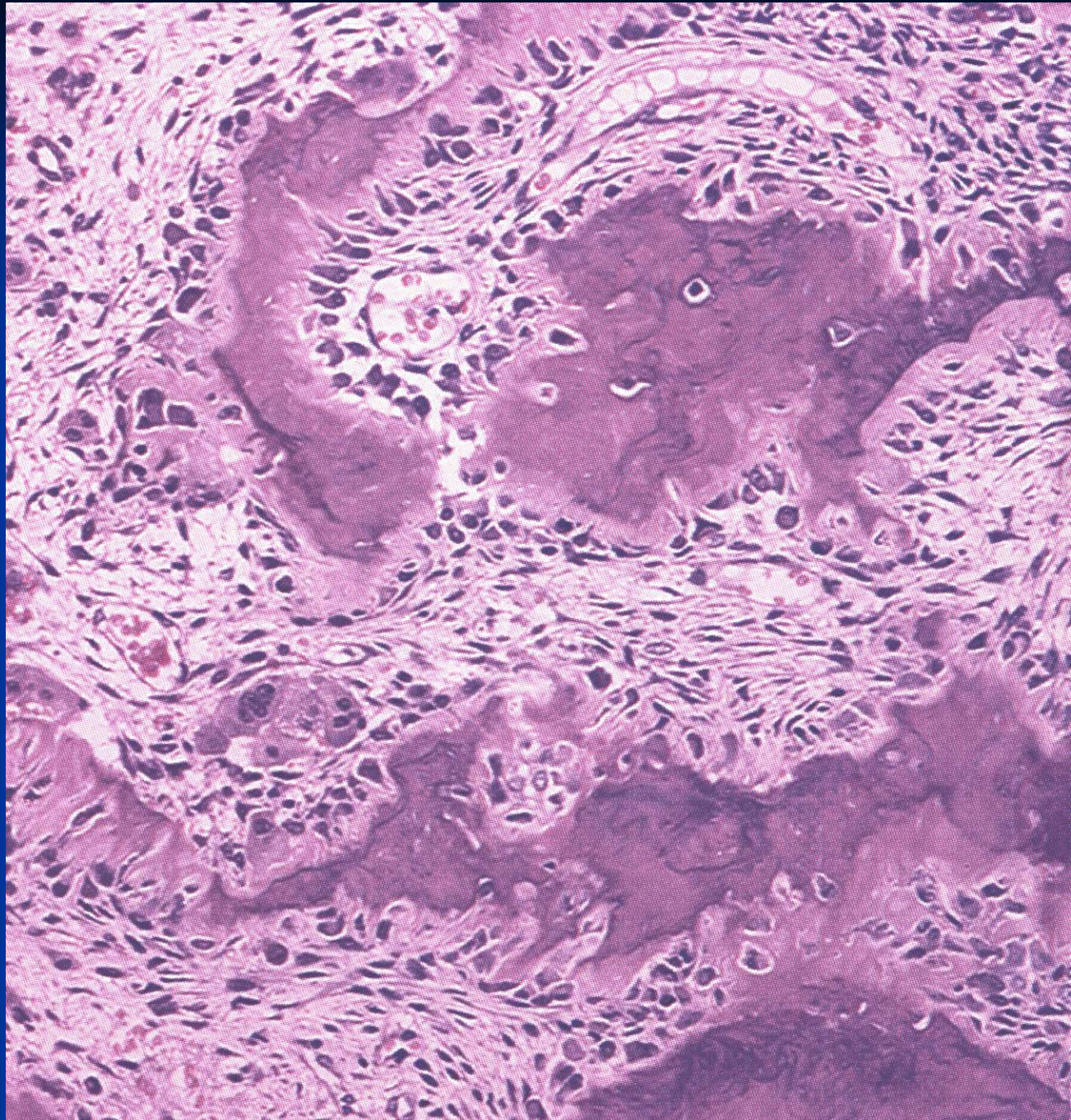
# Osteoblastoma

## Osteoblasts Lining Trabeculae



Uniform, Plump  
Osteoblasts  
Lining  
Trabeculae







# Aggressive Osteoblastoma

- **Definition:** rare tumor that represents a borderline lesion between benign osteoblastoma and osteosarcoma
- More likely to recur in comparison to a typical osteoblastoma
- Do Not metastasize
- Characterized microscopically by epitheloid osteoblasts
- They are not considered precursors to osteosarcoma

# Aggressive Osteoblastoma

## ■ Clinical:

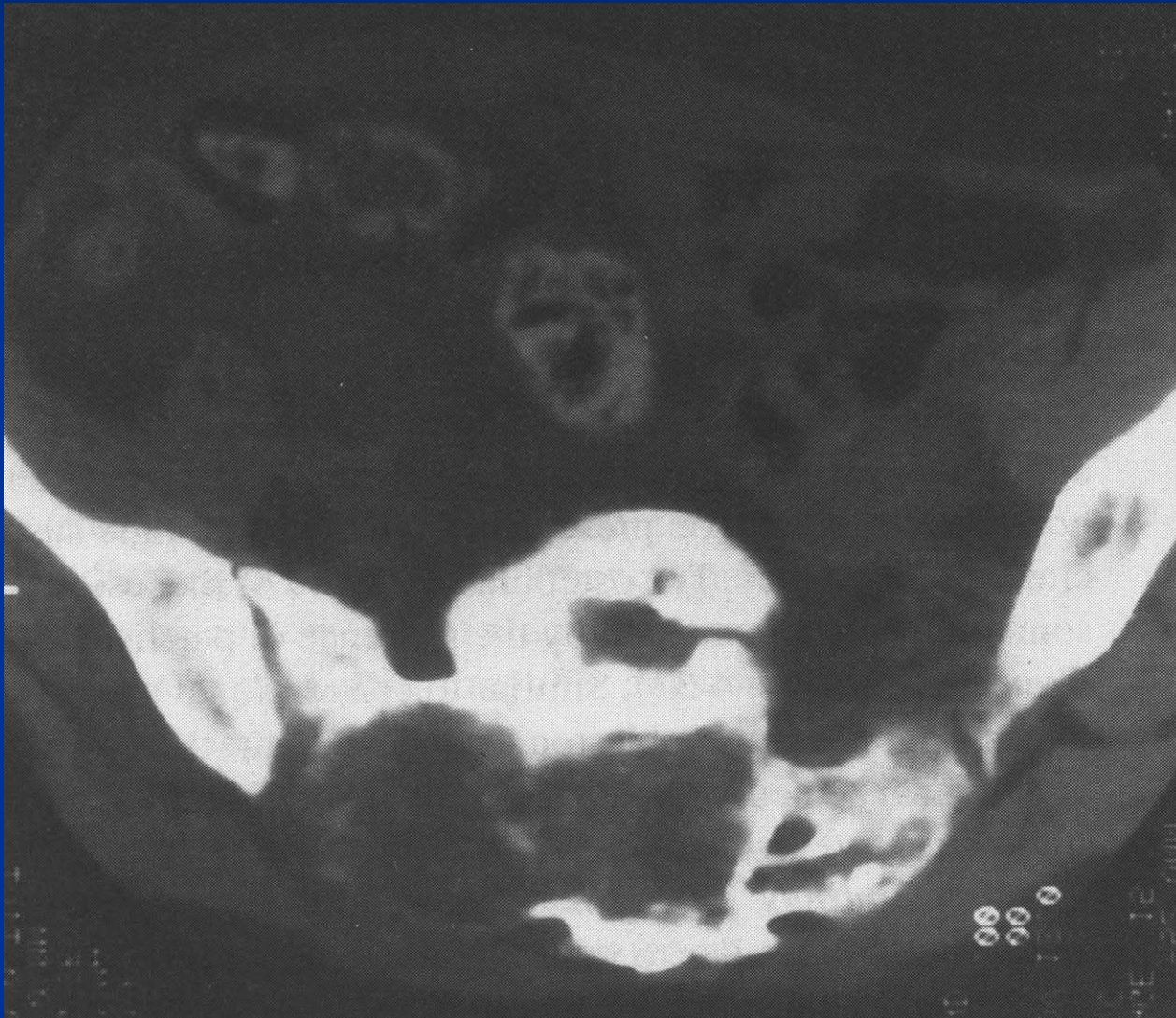- Average age: 33 years; range 7-80 years (older than conventional osteoblastoma)
- Male=Female
- Anatomic sites: same as osteoblastoma (spine, femur, long tubular bones, small bones of hands and feet, etc)

# Aggressive Osteoblastoma

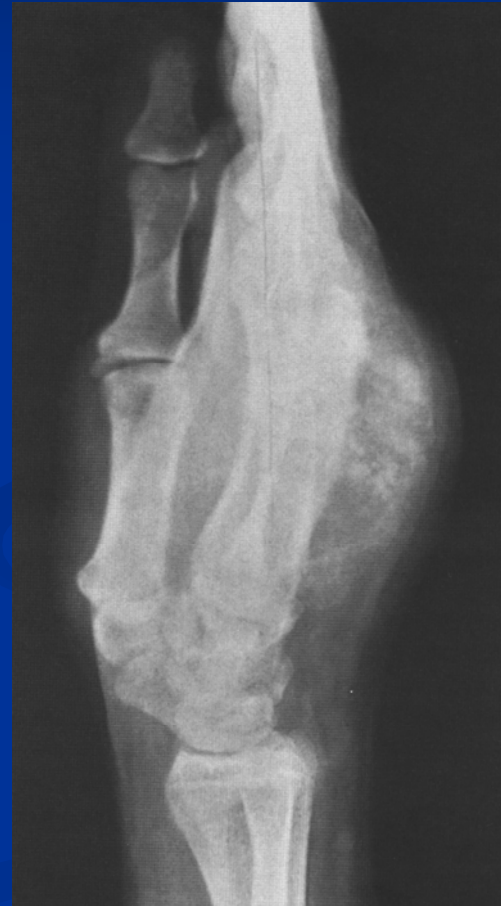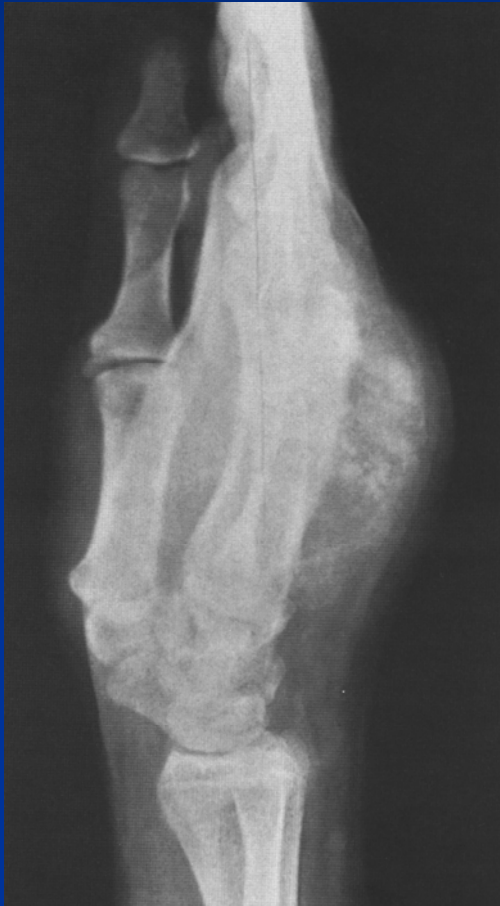## ■ Radiology:

- Circumscribed lytic defect with rim of sclerosis
- Bone may be expanded with rim of reactive bone
- Larger (usually  $>4\text{cm}$ ) and more aggressive on radiographs
- More likely to have a soft tissue component
- ABC component possible

# Aggressive Osteoblastoma



# Aggressive Osteoblastoma



# Aggressive Osteoblastoma

## ■ Pathology:

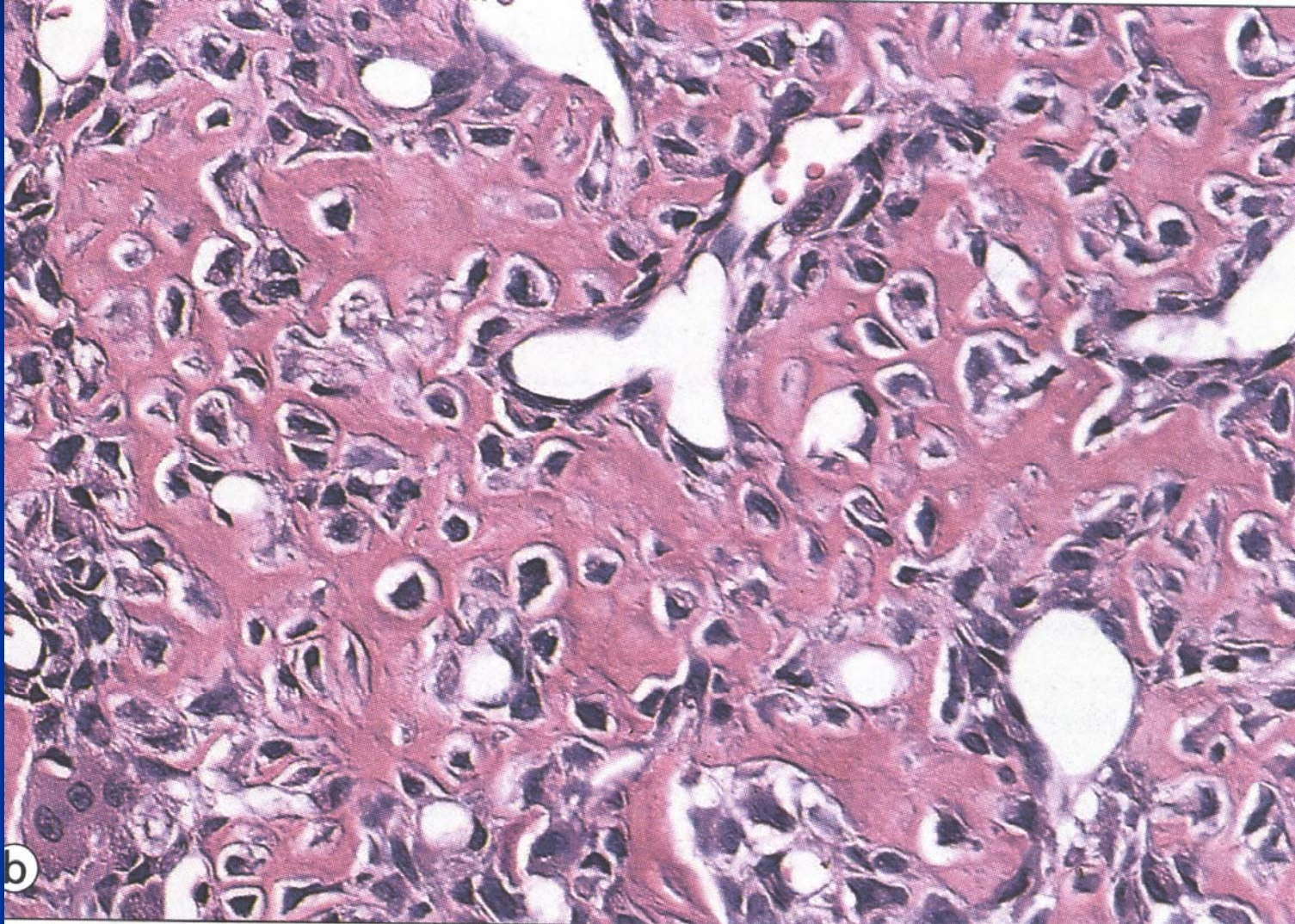
- **Gross pathology** is similar to conventional osteoblastoma

- Granular, friable and reddish

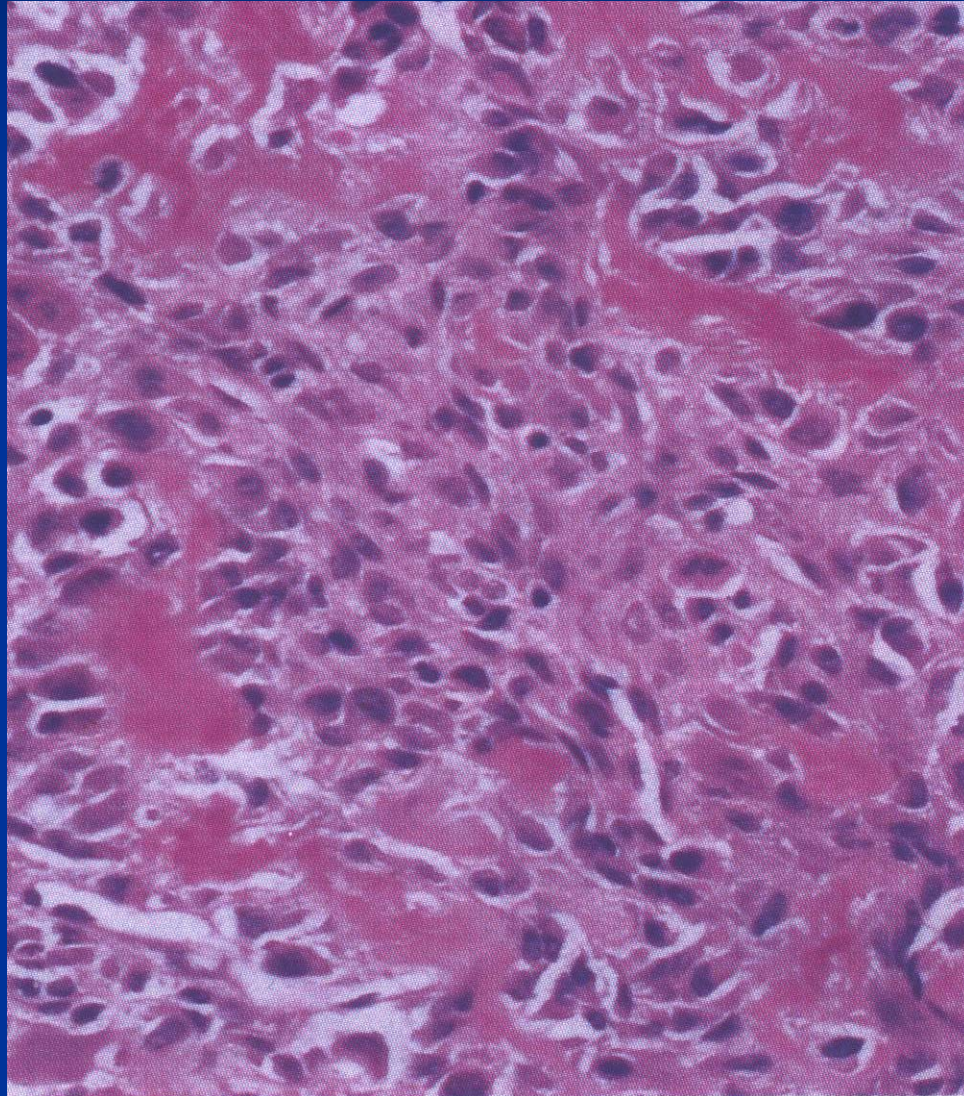
## ■ Microscopic Pathology:

- **Epithelioid osteoblasts** that rim osteoid trabeculae and may form cohesive sheets that fill the intertrabecular spaces (round, 2x size of normal osteoblast, eosinophilic cytoplasm, eccentric, large, oval or round nucleus with prominent nucleolus; 1-4 mitoses per 20 high power field; no mitoses in stromal cells or osteoclast like giant cells)
- Variable mitoses but no atypical features
- Focally the osteoid may be lacelike surrounding individual cells
- Peripheral shell of reactive bone
- Thicker Trabeculae; Osteoid may surround cells
- Can be difficult to differentiate pathologically from an osteosarcoma; must interpret pathology in conjunction with radiological studies

# Aggressive Osteoblastoma

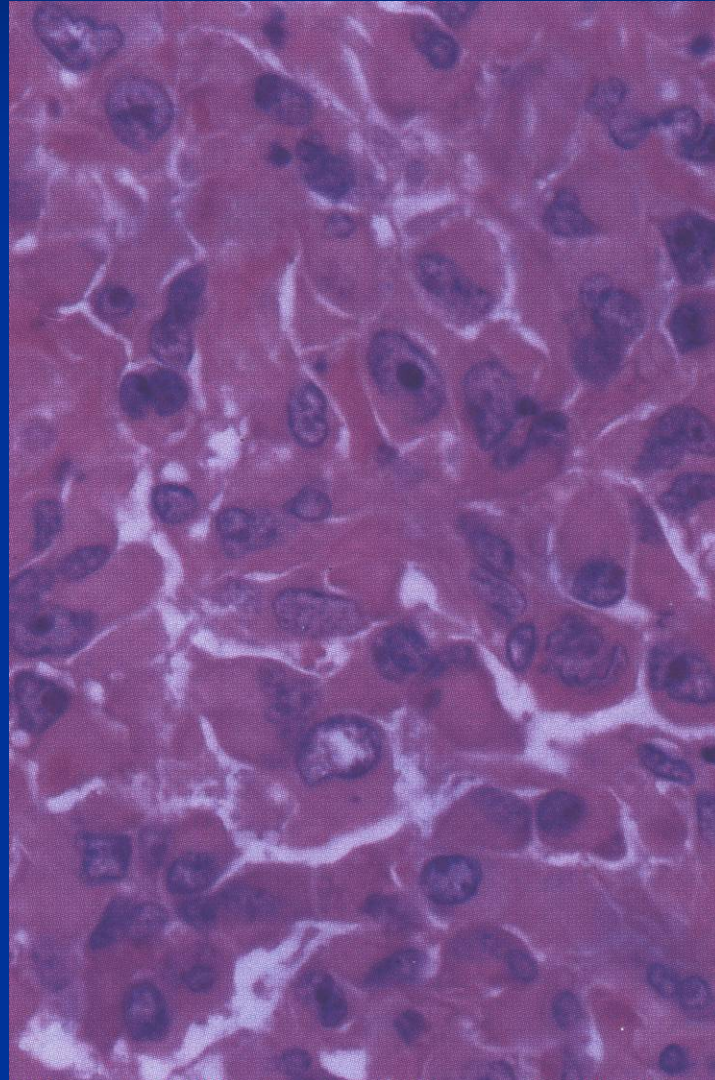


# Aggressive Osteoblastoma

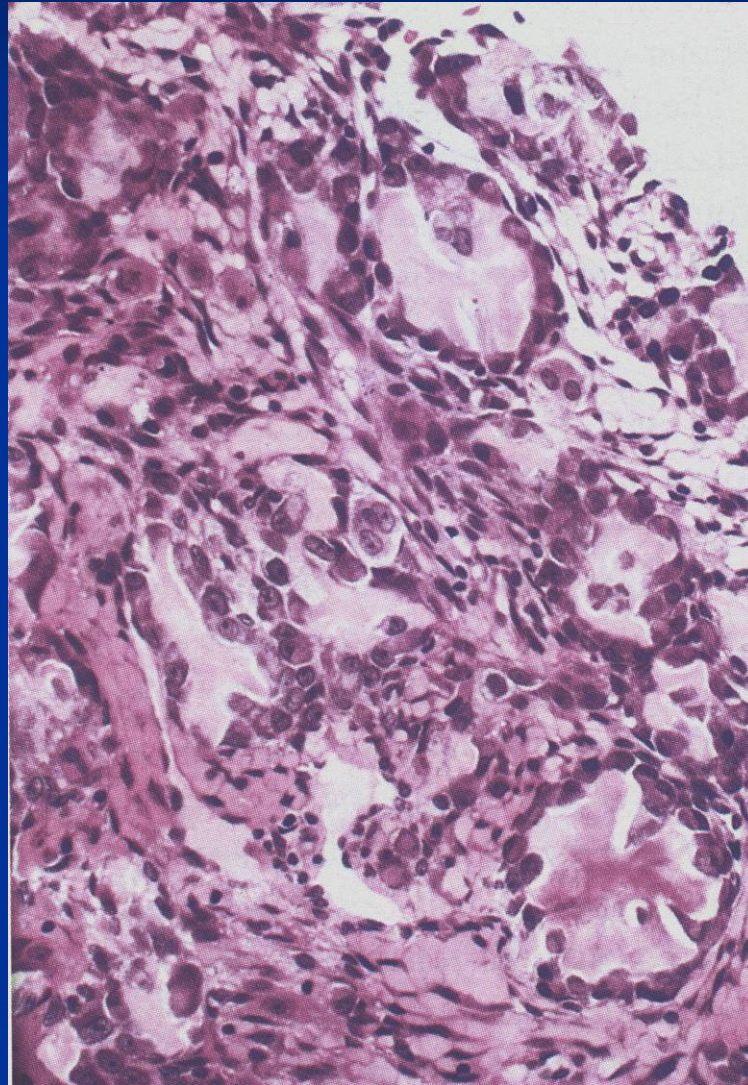




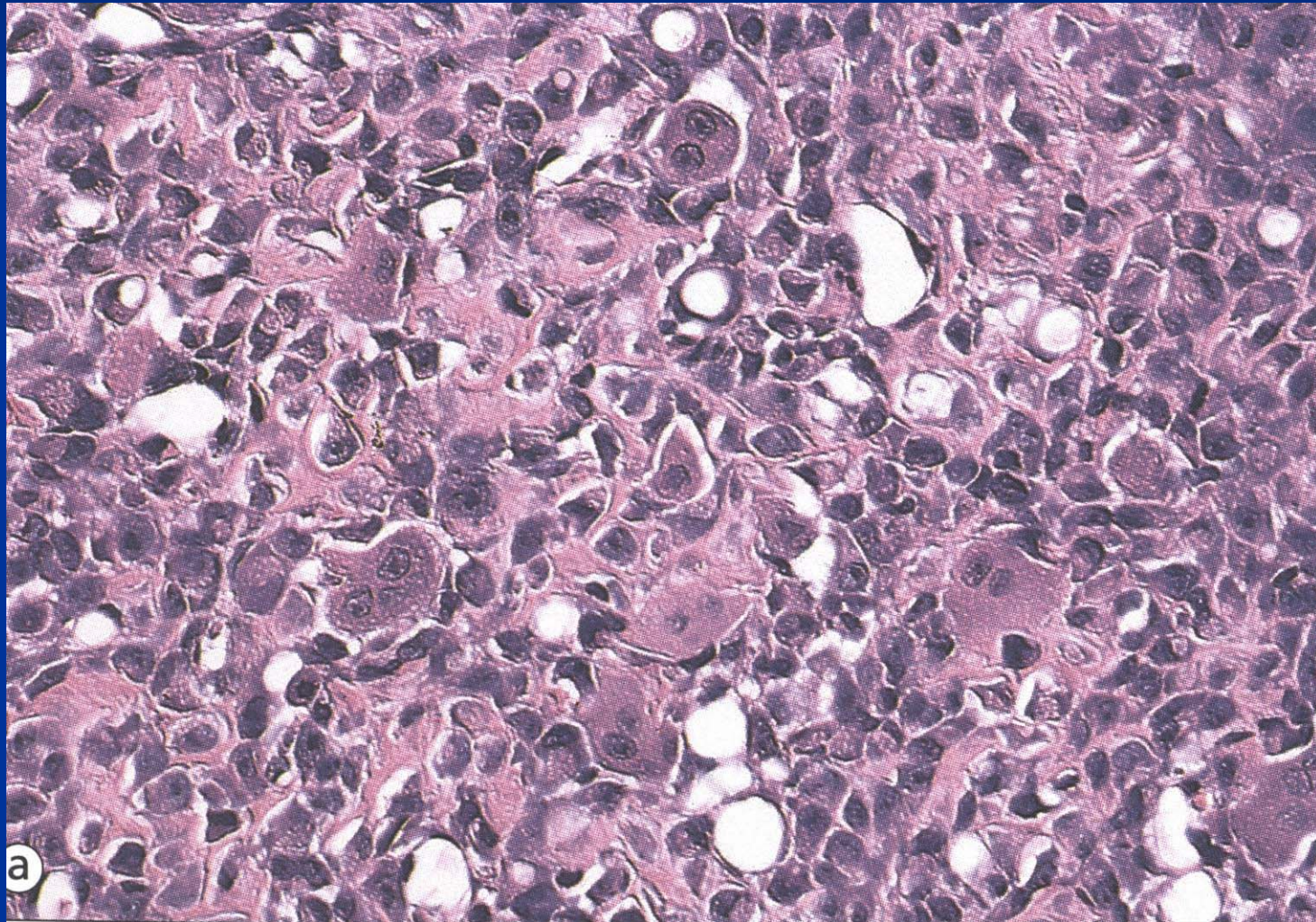
# Epithelioid Osteoblasts



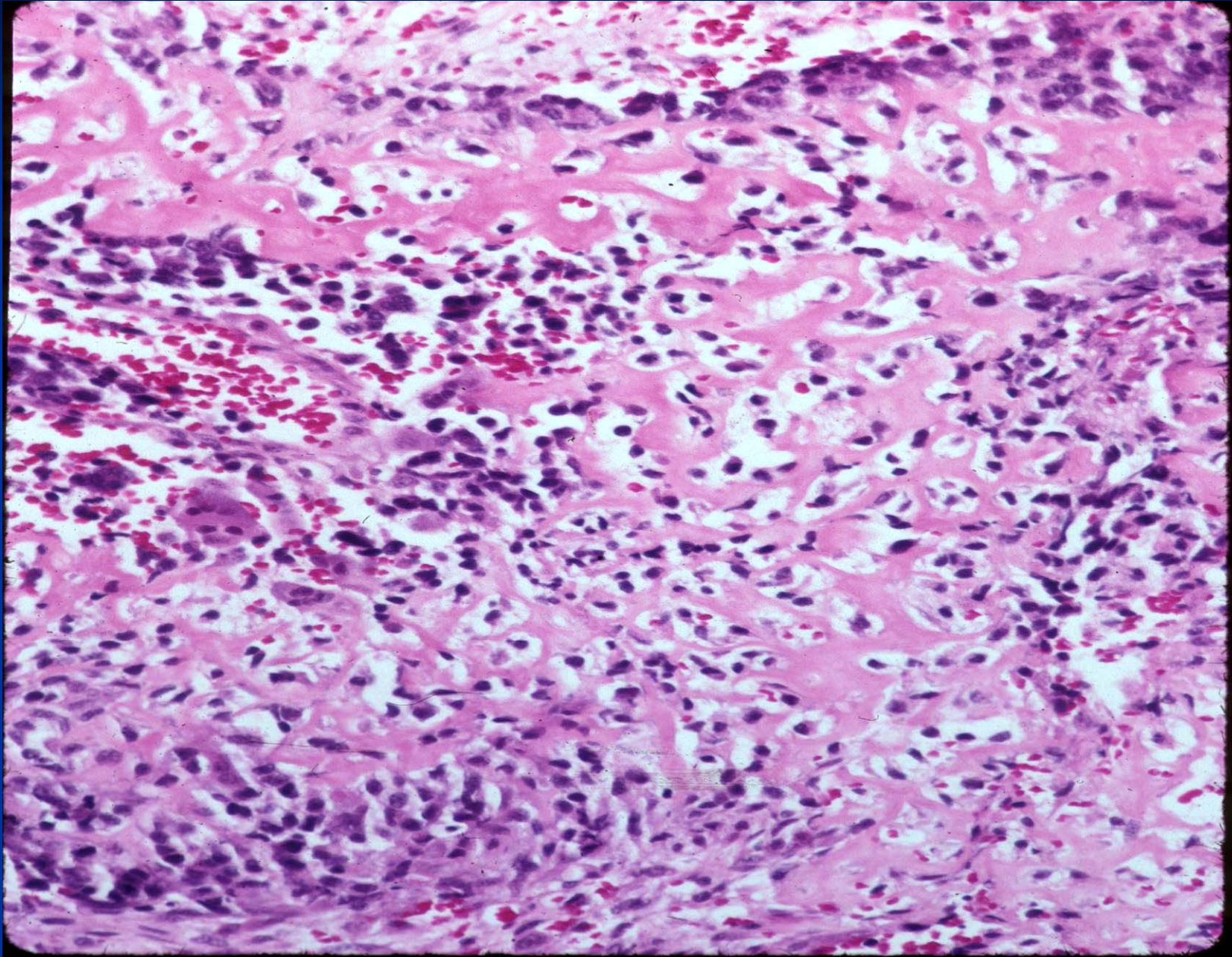
# Aggressive Osteoblastoma



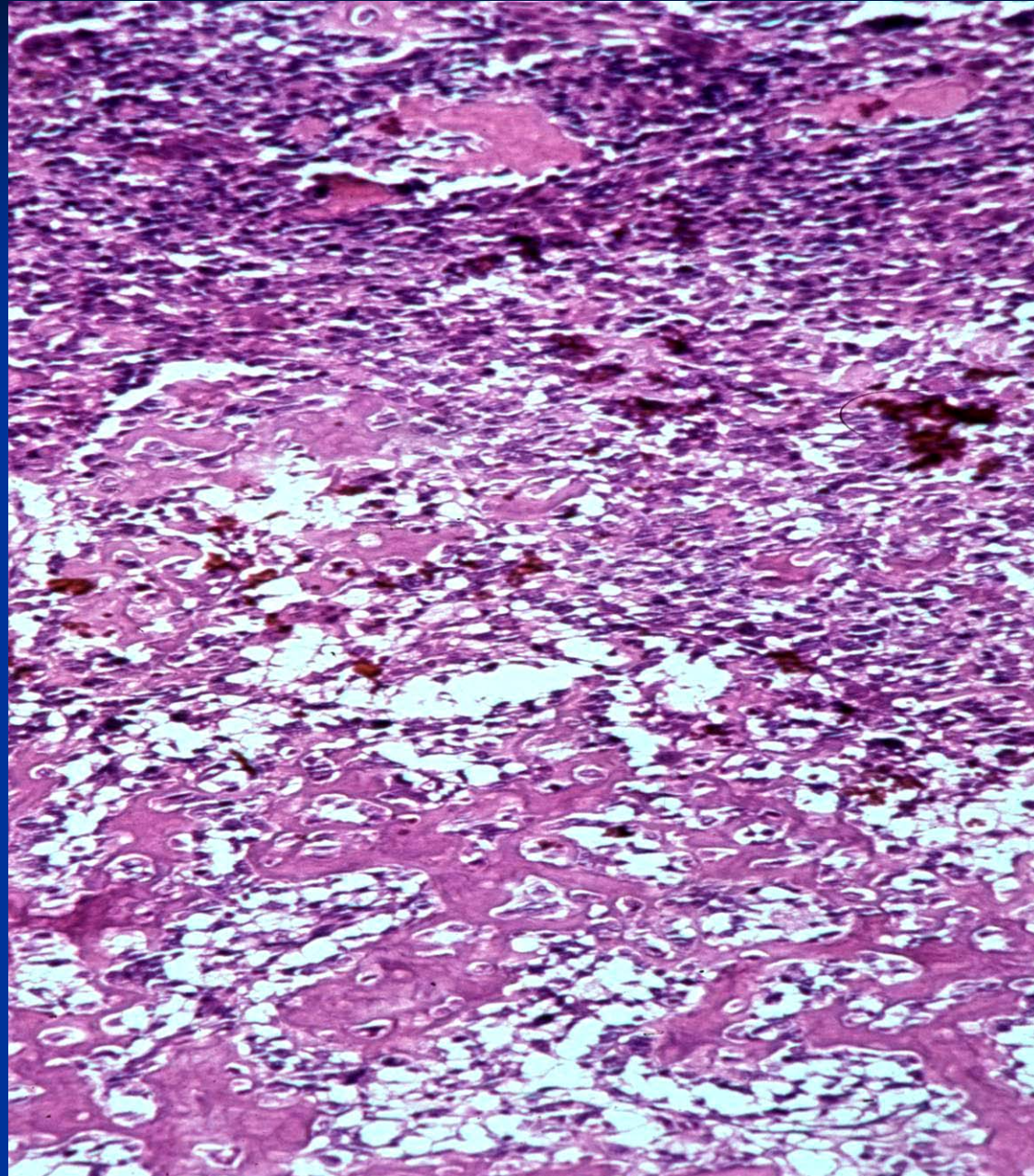
# Epithelioid Osteoblasts



# Aggressive Osteoblastoma



# Aggressive Osteoblastoma



# Aggressive Osteoblastoma

## ■ Differential Diagnosis:

- Osteoid Osteoma
- Conventional Osteoblastoma
- Osteosarcoma

- The differential between osteoid osteoma, conventional osteoblastoma and aggressive osteoblastoma is based on size and the presence of epithelioid osteoblasts. Can have epithelioid osteoblasts in osteoid osteoma and conventional osteoblastoma but they do not occur in cohesive sheets that fill intertrabecular spaces

# Aggressive Osteoblastoma

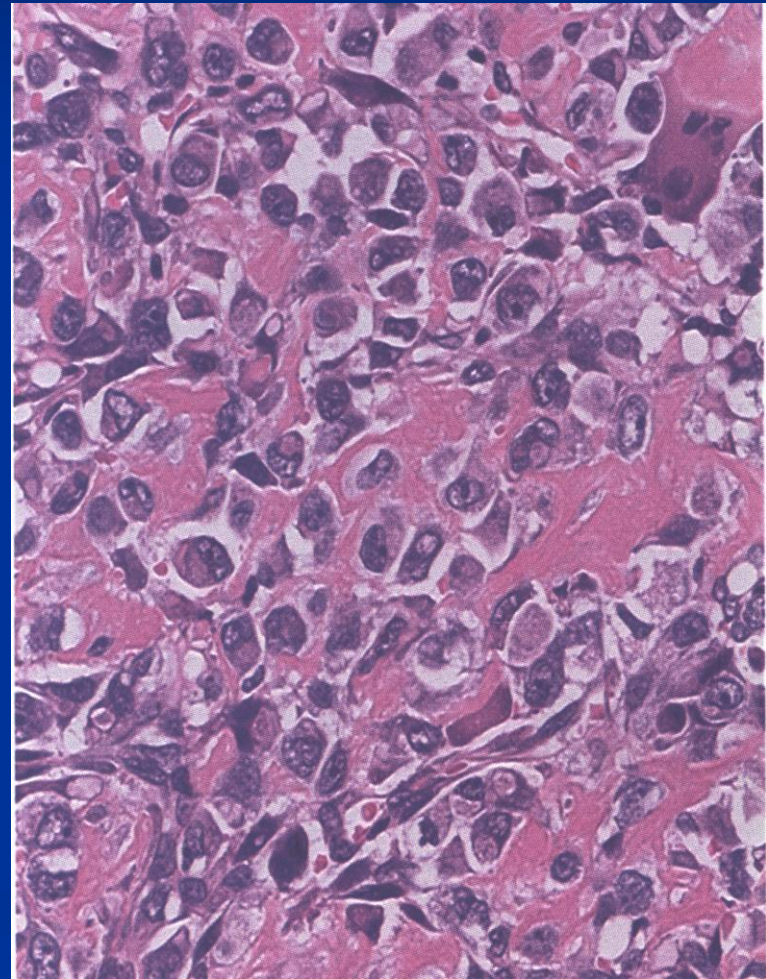
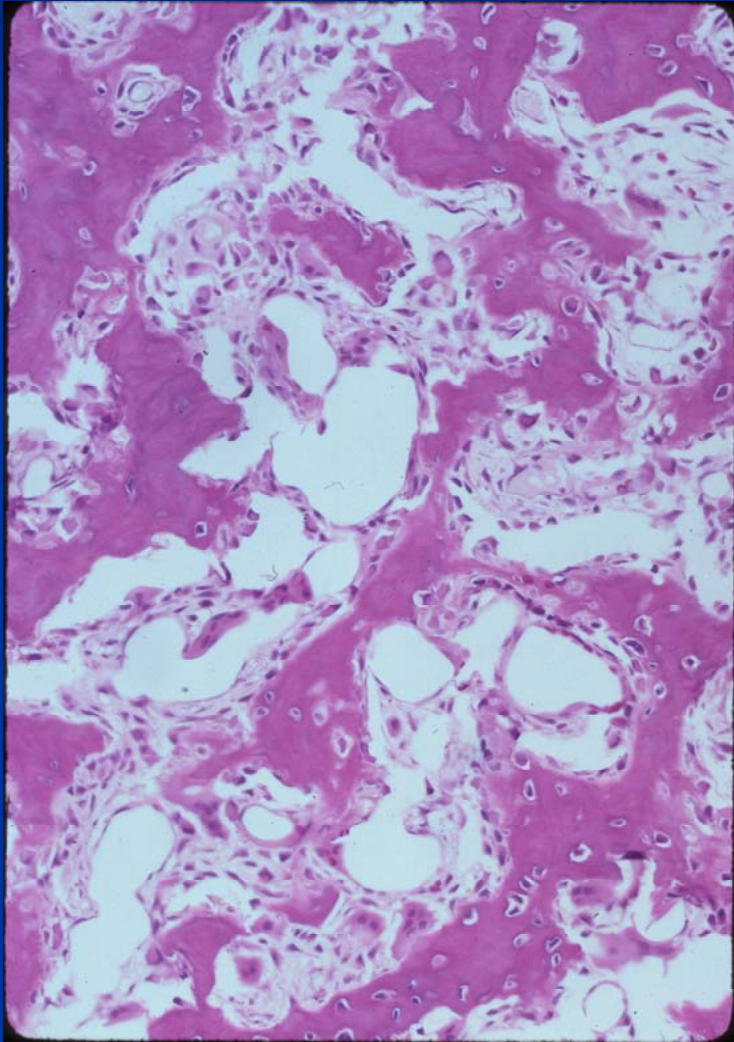
- **Differential Diagnosis: Aggressive osteoblastoma vs. Osteosarcoma**
- **Osteosarcoma:**
  - Cellular atypia
  - High mitotic rate
  - Atypical mitotic figures
  - Abundant lacelike osteoid
  - Permeative growth into adjacent bone and soft tissue
  - Presence of neoplastic cartilage
  - No peripheral shell of reactive bone

# Osteoblastoma

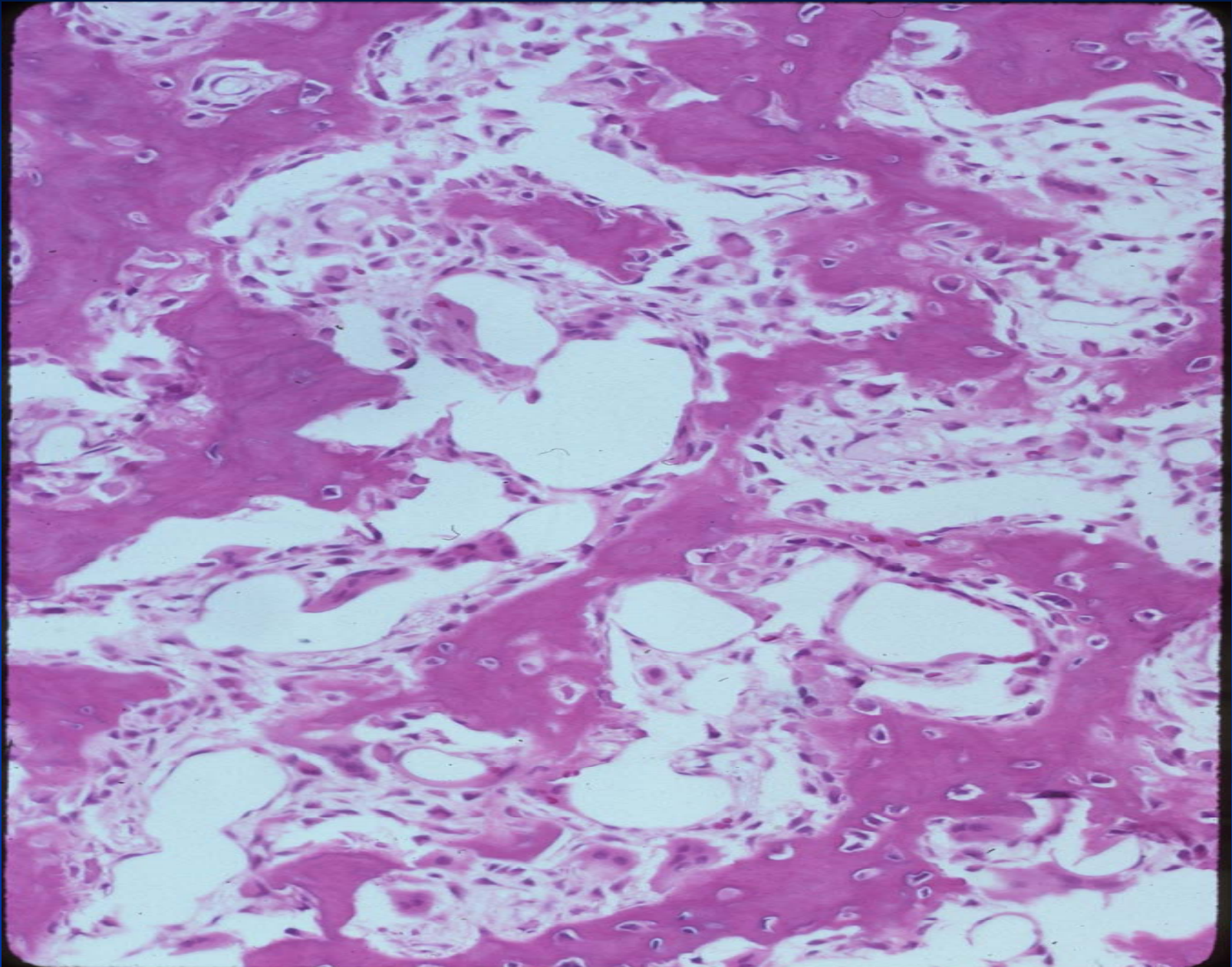
- **Pathology:**
- Differentiation from osteosarcoma
  - Osteoblastomas that are greater than 4 cm and that show prominent periosteal new bone formation may present problems in differentiation from osteosarcoma
  - May have foci of lace-like osteoid, high cellularity and more than a few scattered mitotic figures but these characteristics usually occur independently in an osteoblastoma vs all these atypical characteristics being present in an osteosarcoma



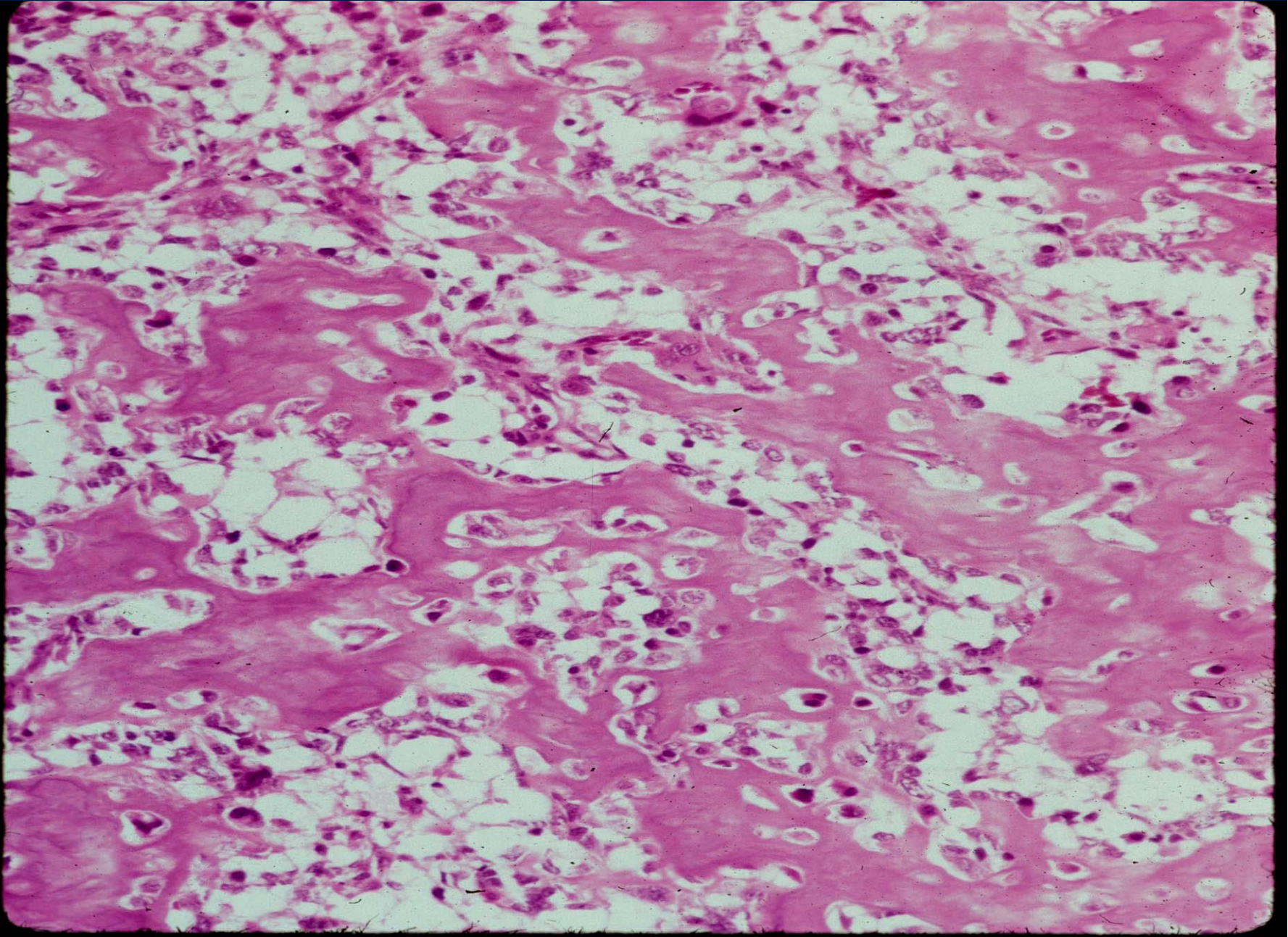
# Osteoblastoma vs. Osteosarcoma



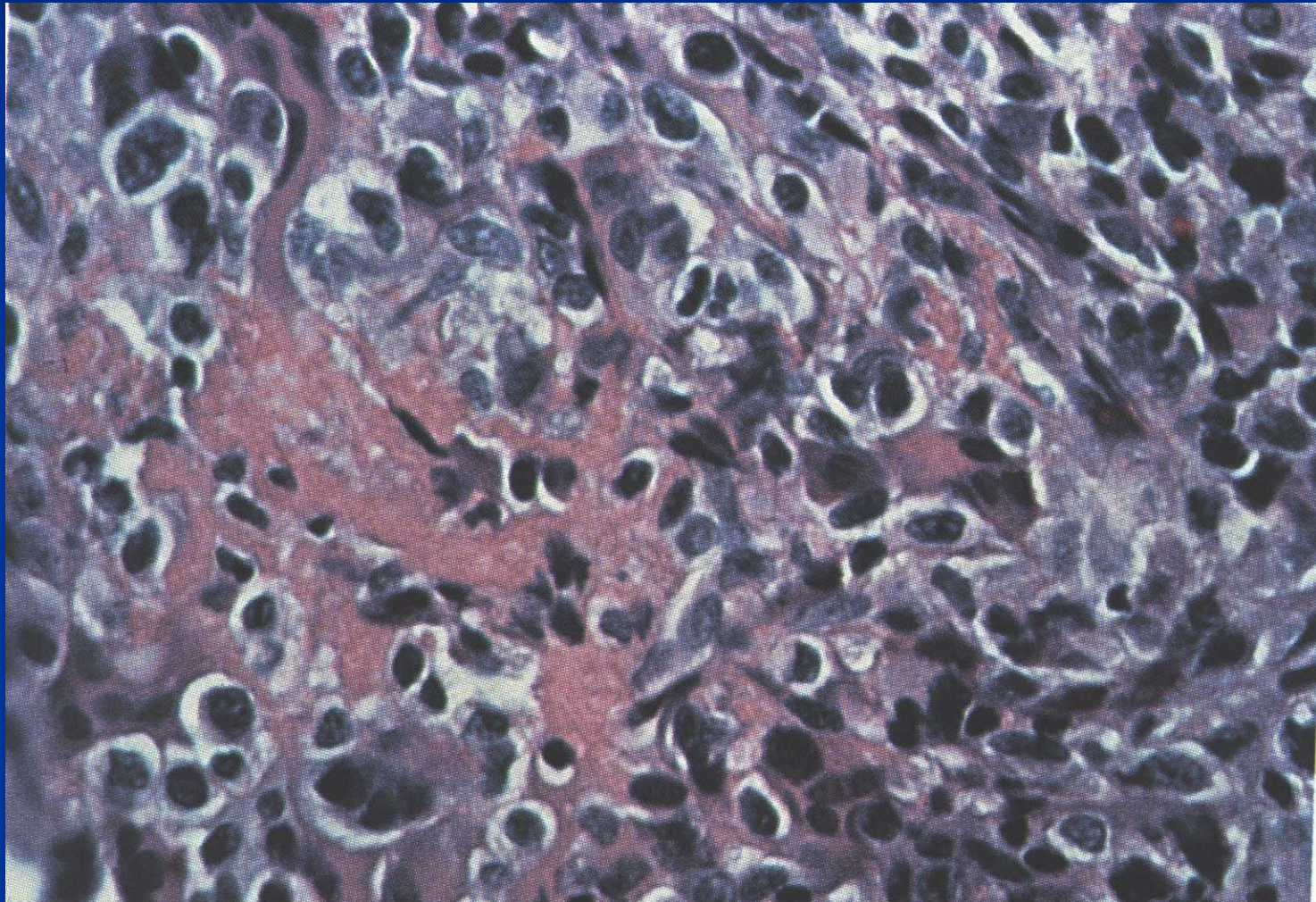
# Osteoblastoma



# Osteosarcoma

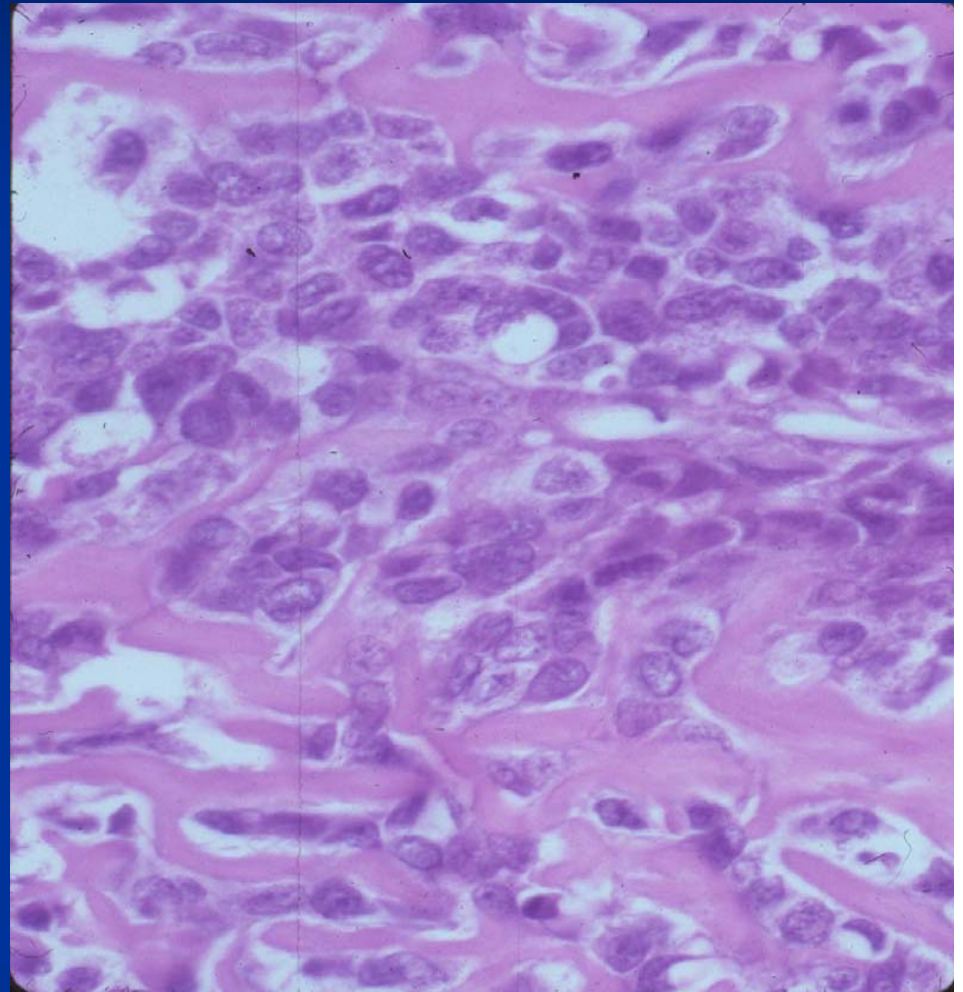


# Osteosarcoma



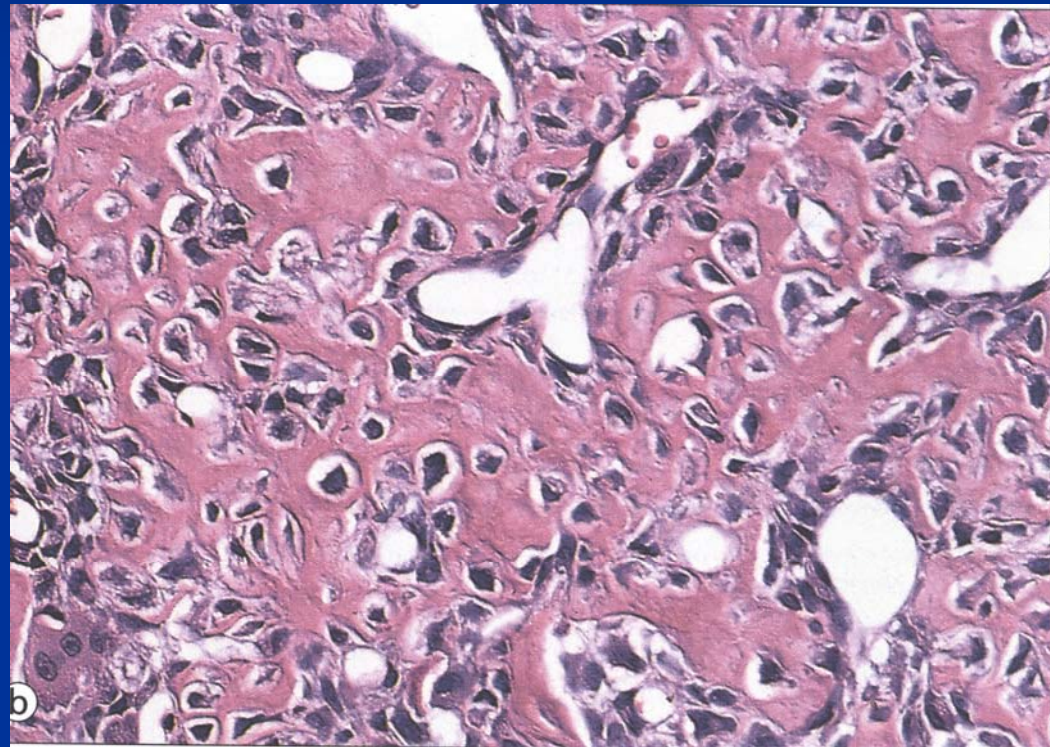
# Osteosarcoma

- Lace-like Osteoid laid down in between cells
- No trabeculae
- Cells are crowded
- High degree of cellular pleomorphism
- Cells do not resemble osteoblasts
- High mitotic rate with atypical mitoses

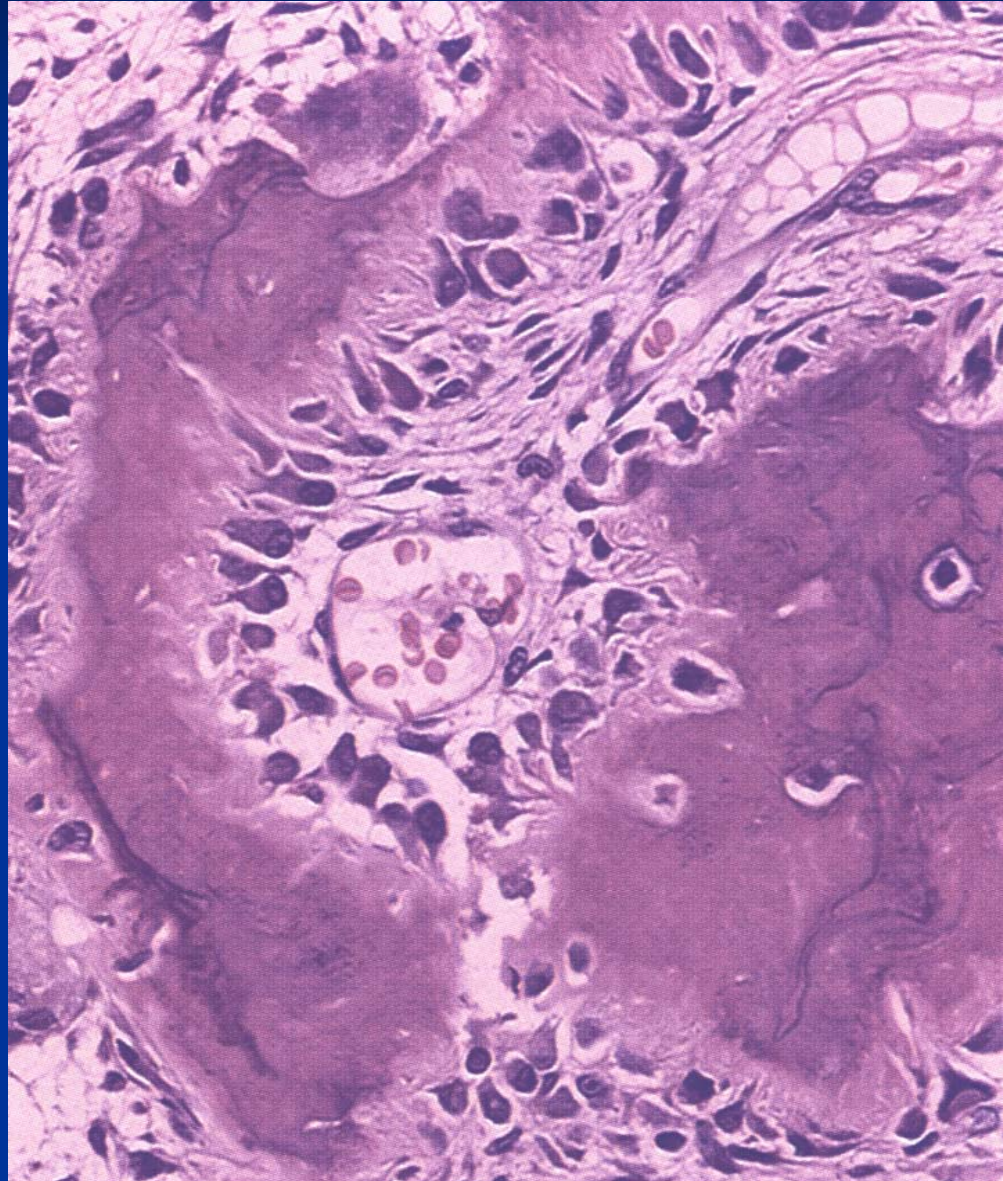


# Aggressive Osteoblastoma

- Cells are more uniform
- Less atypical cells
- Cells tend to line trabeculae
- Less pleomorphism
- Cells look more like osteoblasts and are less cigar and bizarre shaped

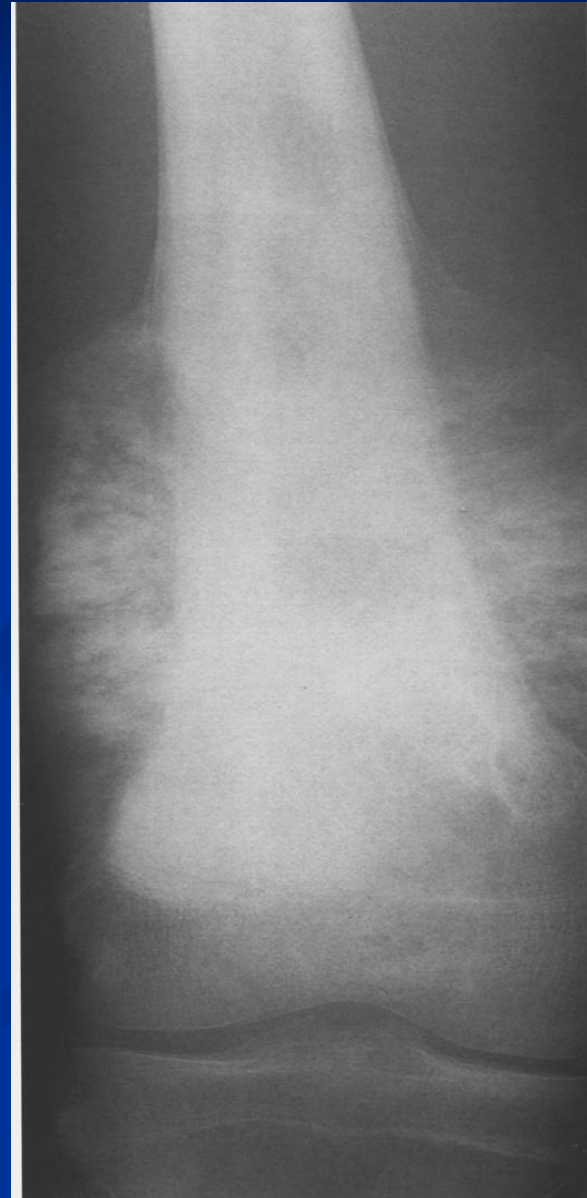


# Osteoblastoma



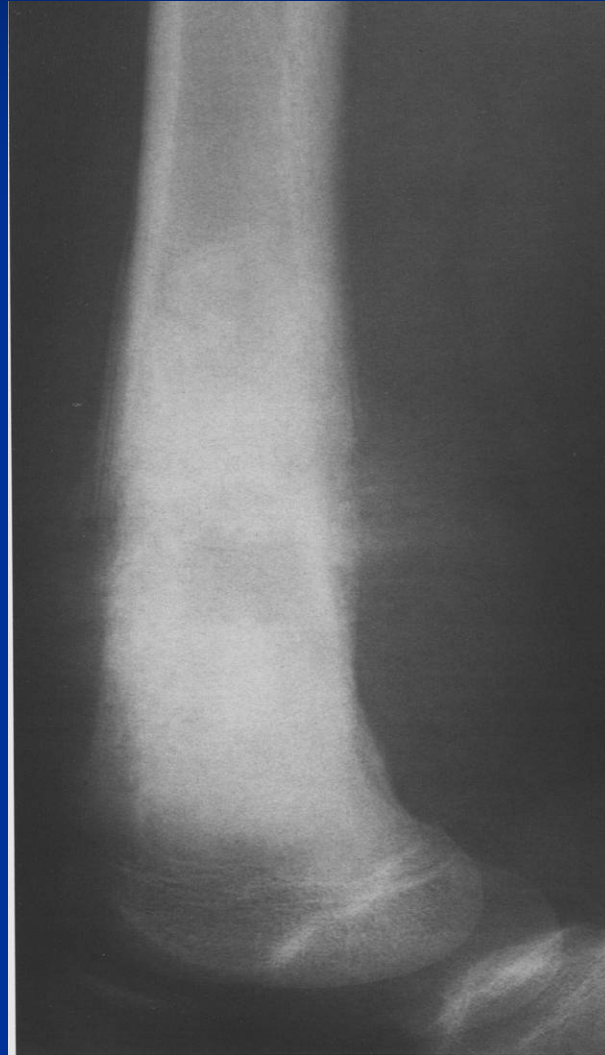# Osteosarcoma

- Permeative lesion (not geographic)
- Codman's Triangle
- Hair on End Periosteal Reaction
- Periosteum destroyed around soft tissue component

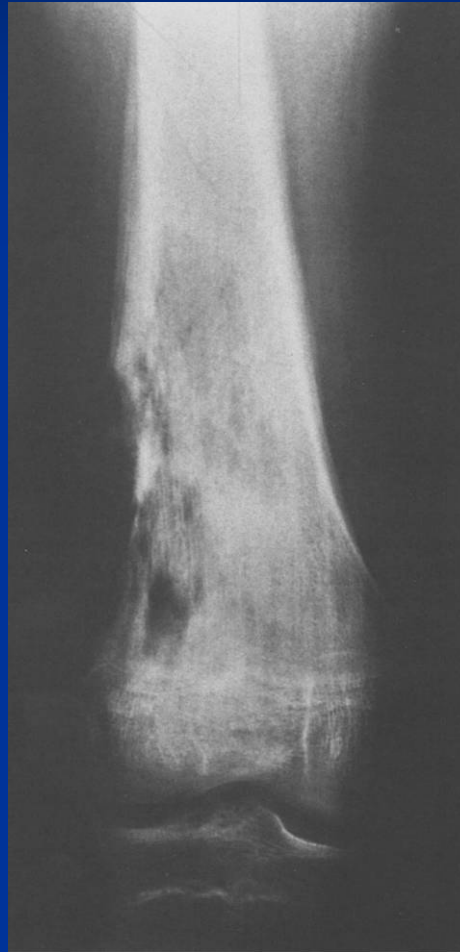




# Osteosarcoma



# Osteosarcoma



# Osteoblastoma

## ■ Natural History and Treatment

- Benign, aggressive tumors; propensity for local recurrence; destroy bone
- Grow slowly and do not metastasize
- Extremity Lesions:
  - Curettage (prefer cryosurgery)
  - En-bloc excision for massive tumors
- Spine lesions:
  - En-bloc resection (recurrence may be as high as 25%)
  - Radiotherapy may be recommended after inadequate removal
  - Rarely—malignant transformation